

[ CASE REPORT ]

## Four Cases of Coronavirus Disease 2019 Transferred from a Cruise Ship

Masahiro Sano<sup>1</sup>, Haruka Nishioka<sup>2</sup>, Jun Yamazaki<sup>3</sup>, Ippei Miyamoto<sup>4</sup> and Takuya Adachi<sup>1</sup>

### Abstract:

An outbreak of coronavirus disease 2019 (COVID-19) that began in Wuhan, China, has spread rapidly to many countries. We herein report four cases of COVID-19 confirmed in Japan among passengers of the cruise ship *Diamond Princess* and describe the clinical features, clinical course, and progression of chest computed tomographic images, chest radiographs, and treatment. Although these four patients had symptoms that included a fever, malaise, runny nose, and cough, one patient had no symptoms on admission. Two of the four patients needed mechanical ventilation due to respiratory deterioration. One of the patients who required mechanical ventilation was transferred to a higher-level medical institution. Except for that patient, the other three patients were able to return home under their own power. Every patient took lopinavir/ritonavir, which was considered the most effective treatment at the time. We used it after receiving approval from the ethics committee in our hospital. In this case report, we emphasize that some patients need to be carefully monitored, even if their respiratory condition is stable at the initial presentation, as their respiratory status may deteriorate rapidly within a few days after oxygen administration begins.

**Key words:** coronavirus disease 2019 (COVID-19), lopinavir/ritonavir, cruise ship

(Intern Med 60: 479-485, 2021)

(DOI: 10.2169/internalmedicine.4939-20)

### Introduction

In December 2019, an outbreak started to spread in Wuhan, China, and there were approximately 29,006,033 infected people and approximately 924,105 dead worldwide as of September 2020 (1). Common symptoms of coronavirus disease 2019 (COVID-19) are a fever (98.6%), fatigue (69.6%), and dry cough (59.4%). Lymphopenia (70.3%), a prolonged prothrombin time (58%), and elevated lactate dehydrogenase levels (39.9%) can be detected in patients (2). However, evidence-based treatments have not yet been established.

The cruise ship *Diamond Princess* left Yokohama port on January 25, 2020; stopped at Kagoshima, Hong Kong, Vietnam, Taiwan, and Okinawa; and returned to Yokohama port on February 3. An outbreak of COVID-19 occurred on this cruise ship, and by February 20, the Japanese government

had tested 4,061 samples from the passengers and crew, with 705 samples found to be positive (3). Individuals with positive results for severe acute respiratory syndrome coronavirus 2 (SARS-CoV-2) polymerase chain reaction (PCR; nasal sample) and symptomatic individuals were urgently transported to our hospital.

We herein report four cases of COVID-19.

### Case Reports

Table shows the characteristics of the four patients with COVID-19. In our hospital, we decided to use a 10-day course of lopinavir/ritonavir (LPV/r, 400 mg/100 mg twice per day) for at-risk patients, including elderly patients and passengers with oxygen demand (4). We defined day 1 as the day symptoms started. We administered oxygen if the patient's oxygen saturation was <93% on room air. However, some patients had a poor respiratory status even before

<sup>1</sup>Department of Infectious Diseases, Tokyo Metropolitan Toshima Hospital, Japan, <sup>2</sup>Junior Resident Program, Tokyo Metropolitan Toshima Hospital, Japan, <sup>3</sup>Department of Gastroenterology, Tokyo Metropolitan Toshima Hospital, Japan and <sup>4</sup>Department of Respiratory Diseases, Tokyo Metropolitan Toshima Hospital, Japan

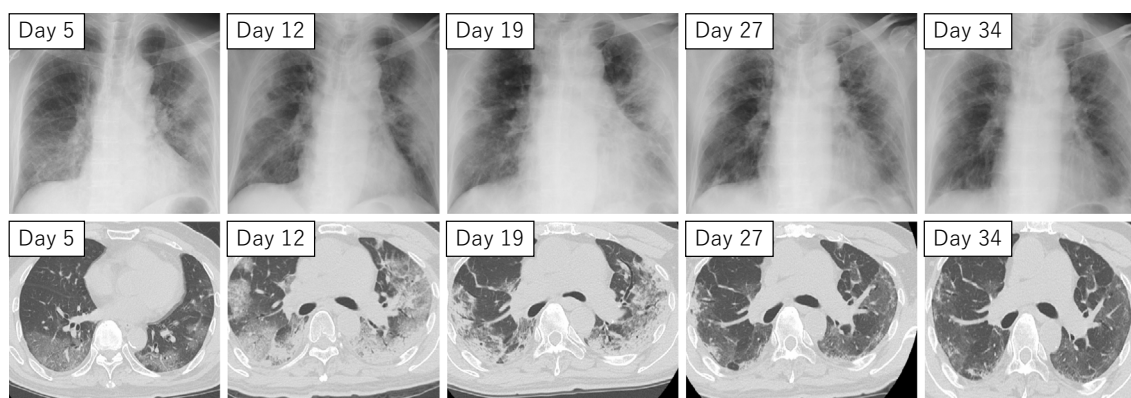
Received: March 25, 2020; Accepted: November 8, 2020; Advance Publication by J-STAGE: December 22, 2020

Correspondence to Dr. Masahiro Sano, masahiro.sano2@gmail.com

**Table.** Characteristics of Four Cases with COVID-19.

Case	Age Sex	Chief complaint	Past medical history	Time of oxygen initiation	Time of mechanical ventilator initiation	Time of mechanical ventilator termination	Time of oxygen termination	Time of negative PCR	Outcome
1	79 male	Fever Malaise (four days before admission)	Hypertension Hyperlipidemia	Day 7  CRP: 15.57mg/dL BT:38.6°C	NA	NA	Day 27  CRP: 5.16mg/dL BT:37.0°C	Days 33, 34  CRP: 0.3mg/dL BT:36.4°C	Discharge Day 41
2	74 male	none	Prostate cancer Migraine	Day 8  CRP: 28.87mg/dL BT:39.3°C	Day 12  CRP: 30.94mg/dL BT:37.7°C	Day 18  CRP: 2.79mg/dL BT:37.0°C	Day 33  CRP: 3.78mg/dL BT:37.0°C	Days 33, 36  CRP: 1.9mg/dL(day36) BT:36.8°C(day36)	Discharge Day 36
3	69 male	Fever Runny nose (five days before admission)	Hypertension Diabetes Hypothyroidism	Day 11  CRP: 11.95mg/dL BT:39.3°C	NA	NA	Day 20  CRP: 0.57mg/dL BT:36.6°C	Days 23, 26  CRP: 0.24mg/dL(day26) BT:36.8°C(day26)	Discharge Day 26
4	81 male	Fever Cough (five days before admission)	Hypertension Renal cancer	Day 10  CRP: 5.43mg/dL BT:38.4°C	Day 13  CRP: 12.74mg/dL BT:38.1°C	NA	NA	NA	Transfer to other Hospital  CRP:37.66mg/dL BT:36.6°C

NA: not applicable, CRP: C-reactive protein, BT: body temperature; and information regarding the timing of each event and some data (CRP and BT).



**Figure 1.** Posteroanterior chest radiographs and chest computed tomographic images of Case 1. Posteroanterior chest radiographs show bilateral ground-glass opacities, and transverse chest CT images show bilateral multiple lobular and subsegmental areas of consolidation. After day 19, those findings gradually improved.

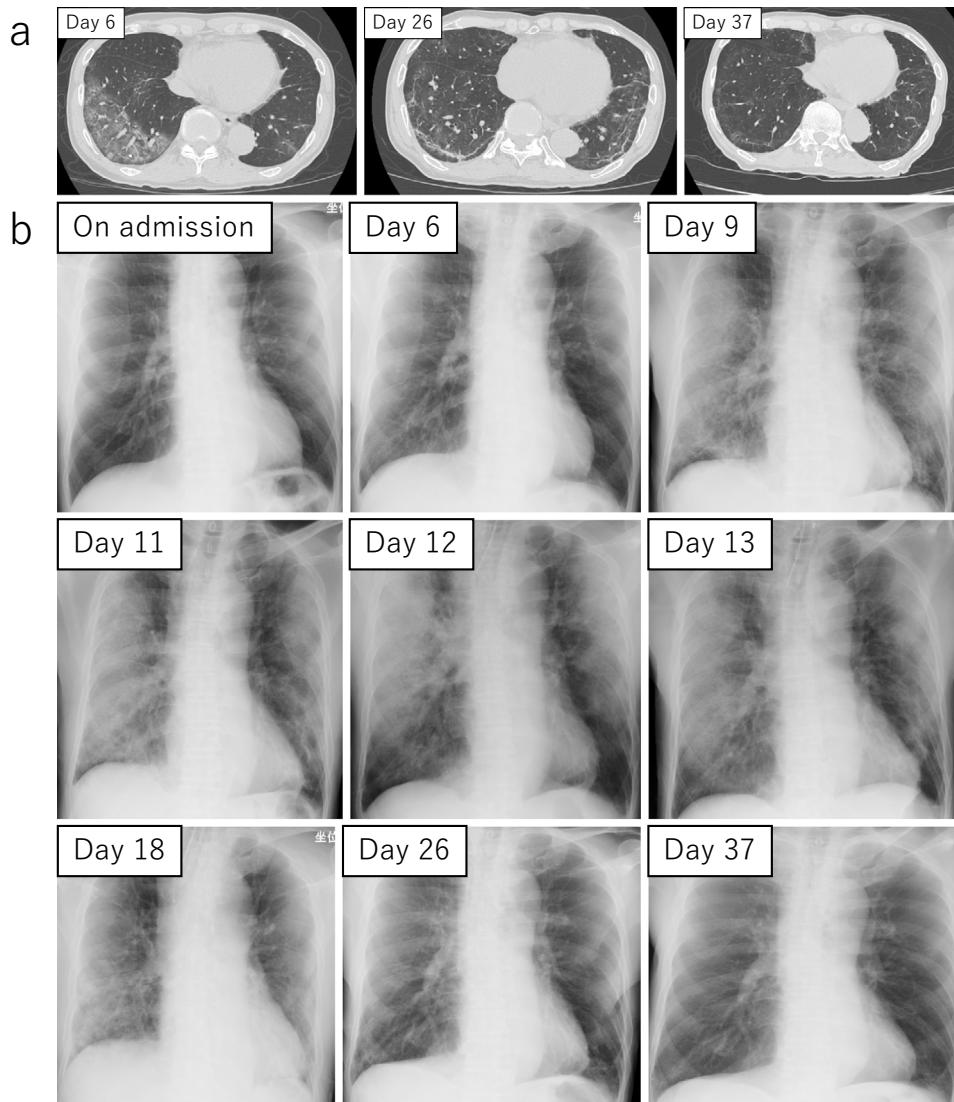
LPV/r was approved by the in-hospital ethics committee.

### Case 1

A 79-year-old American man presented with a 4-day history of a fever and malaise during the cruise. Two days before admission, he started to recognize mild cough but did not have any sputum. Therefore, he was transferred to our hospital from the cruise ship as a symptomatic patient. He did not have contact with any symptomatic patients, and his cruise roommates also did not have respiratory symptoms and later received negative SARS-CoV-2 PCR results.

A physical examination revealed a body temperature of 38.5 °C, blood pressure of 162/92 mmHg, pulse of 100

beats per minute, and oxygen saturation of 96% while the patient was breathing ambient air. Lung auscultation revealed fine crackles. Laboratory findings included a white blood cell (WBC) count of 6,900/ $\mu$ L (Seg 79.7%, Lym 14.2%, Mono 6.1%, Eos 0.0%), aspartate aminotransferase (AST) 56 U/L, alanine aminotransferase (ALT) 45 U/L, lactate dehydrogenase levels (LDH) 492 U/L, blood urea nitrogen (BUN) 12.5 mg/dL, creatinine (Cre) 0.77 mg/dL, c-reactive protein (CRP) 11.61 mg/dL, and D-dimer 136.6  $\mu$ g/mL. A chest radiograph is shown in Fig. 1. We conducted SARS-CoV-2 PCR in our hospital and obtained a positive result. Sputum culture was negative. After hospitalization, the fever persisted, and his cough gradually worsened from



**Figure 2.** (a) Chest computed tomographic images of Case 2. Chest radiography shows a significant ground-glass opacity on the right side on day 6. (b) Posteroanterior chest radiographs of Case 2. Posteroanterior chest radiographs show bilateral ground-glass opacities, and those findings were almost normal on day 37.

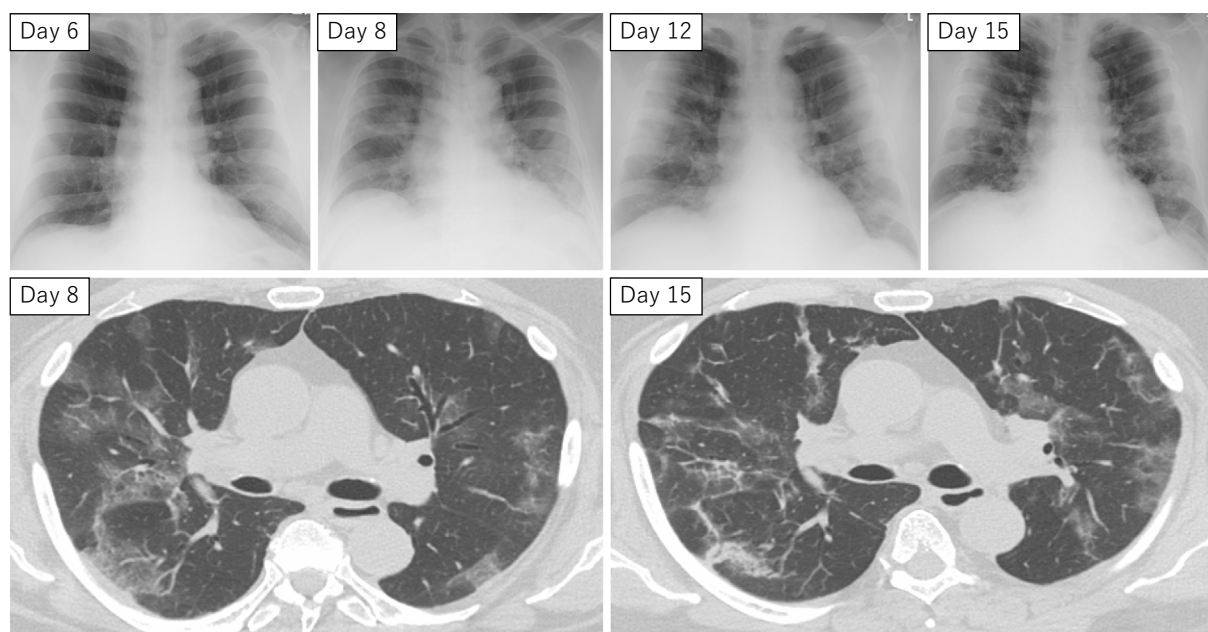
day 7, so dextromethorphan was initiated. At that time, oxygen demand was recognized. We started oxygen administration at 1 L/min. Exacerbation was observed, requiring 3 L/min on day 9 and 7 L/min on day 10. LPV/r was initiated on day 10. Oxygen demand improved after day 11, and oxygen administration was terminated on day 27. Negative results for SARS-CoV-2 PCR were confirmed on days 33 and 34, and the patient was discharged on day 41.

### Case 2

A 74-year-old Japanese man had no symptoms on the cruise ship but had had contact with many symptomatic passengers (we have not been able to determine whether or not those passengers were diagnosed with COVID-19) as well as his wife, who stayed in same ship room but showed a negative SARS-CoV-2 PCR result. The SARS-CoV-2 PCR result of this patient was positive, so he was transferred to our hospital as an asymptomatic patient with COVID-19.

His general condition was not poor, and he was able to exercise indoors after hospitalization.

A physical examination revealed no abnormalities on admission. Laboratory findings included a WBC count of 6,000/ $\mu$ L (Seg 71.1%, Lym 21.4%, Mono 6.9%, Eos 0.3%), AST 17 U/L, ALT 15 U/L, LDH 156 U/L, BUN 14.4 mg/dL, Cre 0.81 mg/dL, and D-dimer 58.6  $\mu$ g/mL. A chest radiograph is shown in Fig. 2. Sputum culture was negative, influenza antigen test was negative, urine *Streptococcus pneumoniae* and urine Legionella antigen tests were negative, and the Mycoplasma antigen test was negative. A fever of 38.0 °C was observed on the third day of hospitalization (day 1). Acetaminophen was administered multiple times. SpO<sub>2</sub> was 88% on day 8, and we started oxygen administration at 1 L/min on day 8 and increased it to 3 L/min on day 9. We also initiated LPV/r on day 9. Oxygen demand gradually increased to 4 L/min on days 10 and 11. The administration was 4 L/min when his vitals were checked in the



**Figure 3.** Posteroanterior chest radiographs and chest computed tomographic images of Case 3. Posteroanterior chest radiographs and chest computed tomographic images show bilateral multifocal ground-glass opacities and mixed consolidation.

morning on day 12, but by the afternoon, it had become impossible to maintain 90% percutaneous oxygen saturation ( $\text{SpO}_2$ ) without 15 L/min. He was placed on a mechanical ventilator on the same day. In addition, levofloxacin 500 mg q24 h (five days) was administered because of suspected atypical pneumonia, and methylprednisolone (120 mg for 6 days, followed by 60 mg for 4 days) was used to treat acute respiratory distress syndrome (ARDS) and hospital-acquired pneumonia. Extubation was performed on day 18 due to improved respiratory readings. His oxygen demand gradually improved, and oxygen administration was terminated on day 33. SARS-CoV-2 PCR was performed on days 36 and 38. Both results were negative, and the patient was discharged on day 38.

### Case 3

A 69-year-old American man presented with a 5-day history of a fever and runny nose. Therefore, he underwent SARS-CoV-2 PCR on the cruise ship, and a positive result was obtained before hospitalization. His wife, who stayed in the same ship room, also had respiratory symptoms and a positive SARS-CoV-2 PCR result. He was transferred to our hospital as a symptomatic patient with COVID-19.

A physical examination revealed a body temperature of 38.4 °C, blood pressure of 165/109 mmHg, pulse of 113 beats per minute, and oxygen saturation of 96% while the patient was breathing ambient air. No abnormal rhonchi were detected. Laboratory findings included a WBC count of 3,700/ $\mu\text{L}$  (Seg 69.1%, Lym 20.6%, Mono 9.7%, Eos 0.3%), AST 34 U/L, ALT 40 U/L, LDH 233 U/L, BUN 19.3 mg/dL, Cre 0.95 mg/dL, CRP 3.67 mg/dL, and hemoglobin (Hb) A1c 6.2%. A chest radiograph is shown in Fig. 3. Sputum culture showed *S. pneumoniae* (Gram stain: Geckler 2).

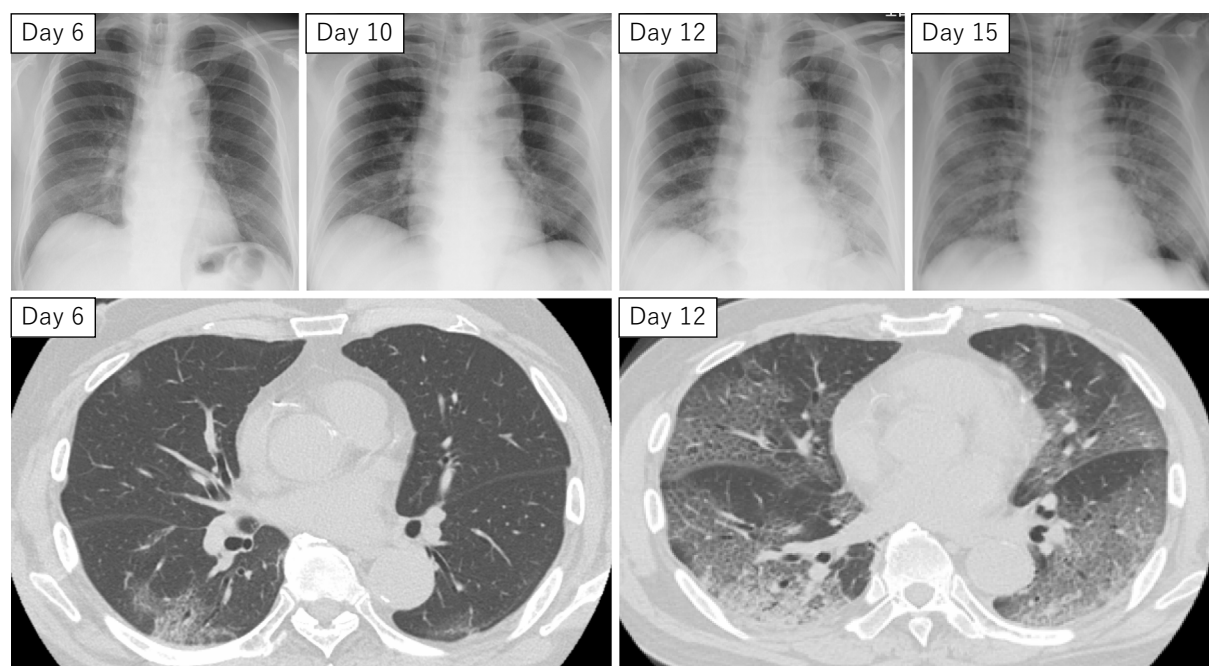
The influenza antigen test was negative, urine *S. pneumoniae* and urine Legionella antigen tests were negative, and the Mycoplasma antigen test was negative. Although the general condition of the patient was good after hospitalization, acetaminophen was administered frequently for his high fever. On day 9, we started antibiotic treatment (ceftriaxone 2 g q24 h for six days followed by amoxicillin/clavulanate 250 mg q8 h for six days) in consideration of the involvement of *S. pneumoniae* detected from sputum culture and deterioration of the chest radiograph and chest computed tomography (CT) findings. The administration of 1 L/min oxygen was started due to oxygen demand on day 11. LPV/r was initiated on day 12. The oxygen level required to meet oxygen demand worsened to 3 L/min on day 15, but the dose was gradually decreased and terminated on day 20. Therefore, SARS-CoV-2 PCR was performed on days 23 and 26. Both results were negative, and the patient was discharged on day 26.

### Case 4

An 81-year-old Japanese man presented with a 5-day history of a fever and cough before hospitalization. He was transferred to our hospital because his SARS-CoV-2 PCR was positive. His wife, who had stayed in the same ship room, also had respiratory symptoms and a positive SARS-CoV-2 PCR result.

A physical examination revealed a body temperature of 37.2 °C, blood pressure of 122/75 mmHg, pulse of 93 beats per minute, and oxygen saturation of 96% while the patient was breathing ambient air. Lung auscultation revealed fine crackles. Laboratory findings included a WBC count of 5,800/ $\mu\text{L}$  (Seg 85.8%, Lym 6.9%, Mono 7.3%, Eos 0.0%), AST 48 U/L, ALT 33 U/L, LDH 274 U/L, BUN 31.8 mg/





**Figure 4.** Posteroanterior chest radiographs and chest computed tomographic images of Case 4. Posteroanterior chest radiographs and chest computed tomographic images show bilateral multifocal ground-glass opacities.

dL, Cre 1.59 mg/dL, CRP 8.10 mg/dL, and D-dimer 3.9  $\mu$ g/mL. A chest radiograph is shown in Fig. 4. The influenza antigen test was negative, urine *S. pneumoniae* and urine Legionella antigen tests were negative, the Mycoplasma antigen test was negative, and the sputum culture was also negative. The patient had watery diarrhea on day 9 that persisted until the day of transfer. Oxygen administration was 1-3 L/min on day 10, 4-6 L/min on day 11, 7-8 L/min on day 12, and finally 15 L/min on day 13. At this time, we started LPV/r with the approval of our ethics committee. Noradrenaline, vasopressin, piperacillin/tazobactam 2.25 g q 8 h, and hydrocortisone 200 mg per day were also initiated for vital shock. Continuous hemodiafiltration was needed. His systolic blood pressure was maintained at 90 mmHg with high-dose noradrenaline and vasopressin. Since there was no improvement in the respiratory and cardiology conditions, he was transferred to a higher-level medical institution on day 15.

## Discussion

From January to February 2020 in Japan, many hospitals, including our hospital, were in charge of passengers from cruise ships, such as the *Diamond Princess*. In February 2020, four patients were transferred to Toshima Hospital. When each patient initially visited our hospital, their general condition was not sick. After consultation with the ethics committee, we decided to suggest LPV/r (400 mg/100 mg) twice per day for the high-risk patients, including elderly patients and those needing oxygen, indicating pneumonia. However, there is a lack of high-quality evidence regarding

the use of LPV/r for unknown infectious diseases, and opinions were divided among those in the Department of Infectious Diseases. The discussions about whether or not to use LPV/r were difficult. We informed the patients that the level of evidence regarding the use of LPV/r was not high and that they would need to be carefully monitored after the start of treatment. We comprehensively assessed the situation and took into account the guidance of the Japanese Association for Infectious Diseases (4) as well as the wishes of the patients.

Four patients with COVID-19 received LPV/r (400 mg/100 mg) twice per day. From days 7-10, oxygen administration was required. Two of the four patients had to be equipped with mechanical ventilation on day 12 or 13 (cases 2 and 4). No adverse side effects of LPV/r were observed in any of these four patients. In some patients, respiratory distress developed several days after the onset of illness (5). The WBC count, neutrophil count, D-dimer, BUN, and Cre in nonsurvivors were higher than those in survivors (2). In our patients, there was no link between the laboratory results on the day of admission and the severity of illness. As shown in Table, there seemed to be a correlation between improvements in the respiratory status and the CRP value, but it is dangerous to judge the therapeutic effect based on the CRP level alone, as complications of bacterial infection may occur. The duration after the onset of illness until dyspnea (8 days), hospitalization (7 days), shortness of breath (8 days), acute respiratory distress syndrome (ARDS) (9 days), mechanical ventilation (10.5 days), and intensive-care unit admission (10.5 days) was recorded (6). We consider it very important to follow patients with regard to their symptoms

for 10-14 days after they appear, if possible. Regarding case 3, it should be noted that oxygen administration may be required 10 days or longer after the onset of symptoms.

In patients with COVID-19 pneumonia, four stages of evolution in chest CT findings were detected: early stage (0-4 days); progressive stage (5-8 days); peak stage (10-13 days); and absorption stage ( $\geq 14$  days). The severity of lung disease on CT was the worst at 10 days after the onset of the initial symptoms, and improvement in chest CT findings started at approximately 14 days after the symptom onset (7). Extensive ground-glass opacity, such as that seen on CT in case 4, may be characteristic of critically ill patients, but in our four cases, additional imaging tests did not change the treatment policy or our response. Therefore, oxygenation monitoring is very important to avoid delaying intubation, but frequent imaging as a matter of routine may not be very important, especially in situations in which patients are frequently hospitalized or discharged, such as during the pandemic.

It is difficult to distinguish COVID-19 from the common cold, bacterial pneumonia, and influenza by a patient's medical history, physical examination findings, or chest X-ray images at the first visit to a doctor. As the most common symptoms at the onset of COVID-19 were a fever (98.6%), fatigue (69.6%), dry cough (59.4%), myalgia (34.8%), and dyspnea (31.2%) (2), clinicians need to consider the possibility of COVID-19 when no other cause has been quickly identified. Antibiotic treatments were administered to three of the four patients because of bacterial pneumonia (case 2-4). In case 3, although we detected *S. pneumoniae* in the sputum, it was unclear how it affected his oxygen demand, and we decided to administer antibiotics before the respiratory condition worsened. Recent research has shown that many pathogens, such as *S. pneumoniae* and *Mycoplasma pneumoniae*, can be coinfectious causes, so we need to consider respiratory illness caused by various pathogens (8). Steroid administration in two of the four patients was started to treat ARDS or septic shock (case 2, 4). However, current evidence regarding SARS and middle east respiratory syndrome (MERS) suggests that receiving corticosteroids has no important role in mortality but rather delays viral clearance (9).

Although no supportive data had yet been published at the time that we treated these four cases, we currently administer dexamethasone for the treatment of COVID-19 patients with an oxygen demand. According to the RECOVERY Collaborative Group, in patients with COVID-19, the administration of dexamethasone for up to 10 days resulted in a lower 28-day mortality among those who were receiving either invasive mechanical ventilation or inhaled oxygen at the time of randomization, but not among those receiving no respiratory support (10). Therefore, it is important not to choose long-term administration.

Although there are no established treatment options for COVID-19, there are some case reports and expert consensus on COVID-19 and MERS treatment, with viable options

including oseltamivir (2, 6, 11), chloroquine (12), and remdesivir (13). Some institutions, including our hospital, selected LPV/r for the treatment of COVID-19 (14, 15); however, in hospitalized adult patients with severe COVID-19, no benefit from LPV/r was observed (16). Therefore, we may consider other treatment options, and LPV/r is not administered at present; instead, we administer remdesivir for patients with oxygen demand (17). Supportive care and mental support are also essential for patients with COVID-19 (18).

We herein described four cases of COVID-19 among passengers from a cruise ship. Some patients demonstrated an acute deterioration from the onset of oxygen administration. In summary, this case report emphasizes the need to closely monitor and observe the patients respiratory condition from 10 days to 14 days after the onset of symptoms in confirmed or suspected patients with COVID-19 since this the most common period to observe a worsening of their symptoms.

Informed consent was obtained for the publication of this case report.

**The authors state that they have no Conflict of Interest (COI).**

#### Acknowledgement

We would like to thank all cruise staff, local government officials, and public health centers.

#### References

1. COVID-19 Dashboard by the Center for Systems Science and Engineering at Johns Hopkins University [Internet]. [cited 2020 Sep 14]. Available from: <https://coronavirus.jhu.edu/map.html>.
2. Wang D, Hu B, Hu C, et al. Clinical characteristics of 138 hospitalized patients with 2019 novel coronavirus-infected pneumonia in Wuhan, China. *JAMA* **323**: 1061-1069, 2020.
3. Ministry of Health. Labour and Welfare, Japan. Regarding COVID-19 cases on a cruise ship, 2020 Feb 26 [in Japanese] [Internet]. [cited 2020 Feb 26]. Available from: [https://www.mhlw.go.jp/stf/newpage\\_09783.html](https://www.mhlw.go.jp/stf/newpage_09783.html).
4. The Japanese Association for Infectious Diseases. Concept of treatment with antiviral drugs for COVID-19 first edition [in Japanese] [Internet]. [cited 2020 Feb 27]. Available from: [http://www.kansensho.or.jp/uploads/files/topics/2019ncov/covid19\\_antiviral\\_drug\\_200227.pdf](http://www.kansensho.or.jp/uploads/files/topics/2019ncov/covid19_antiviral_drug_200227.pdf).
5. Zhu N, Zhang D, Wang W, et al. A novel coronavirus from patients with pneumonia in China, 2019. *N Engl J Med* **382**: 727-733, 2020.
6. Huang C, Wang Y, Li X, et al. Clinical features of patients infected with 2019 novel coronavirus in wuhan, china. *Lancet* **395**: 497-506, 2020.
7. Pan F, Ye T, Sun P, et al. Time course of lung changes on chest CT during recovery from 2019 novel coronavirus (COVID-19) pneumonia. *Radiology* **295**: 715-721, 2020.
8. Lai CC, Wang CY, Hsueh PR. Co-infections among patients with COVID-19: The need for combination therapy with non-anti-SARS-CoV-2 agents? *J Microbiol Immunol Infect* **53**: 505-512, 2020.
9. Clinical WHO, Who W. World Health Organization. Clinical management of severe acute respiratory infection when novel coro-

- navirus (2019-nCoV) infection is suspected: interim guidance. 2020: 1-11.
10. Horby P, Lim WS, Emberson J, et al.; RECOVERY Collaborative Group. Dexamethasone in hospitalized patients with Covid-19 - preliminary report. *N Engl J Med*. Forthcoming.
  11. Bleibtreu A, Jaureguierry S, Houhou N, et al. Clinical management of respiratory syndrome in patients hospitalized for suspected middle east respiratory syndrome coronavirus infection in the Paris area from 2013 to 2016. *BMC Infect Dis* **18**: 1-9, 2018.
  12. [Expert consensus on chloroquine phosphate for the treatment of novel coronavirus pneumonia]. *Zhonghua jie he he hu xi za zhi* (Chinese J Tuberc Respir Dis) **43**: 185-188, 2020 (in Chinese, Abstract in English).
  13. Holshue ML, DeBolt C, Lindquist S, et al. First case of 2019 novel coronavirus in the United States. *N Engl J Med* **382**: 929-936, 2020.
  14. Chu CM, Cheng VCC, Hung IFN, et al. Role of lopinavir/ritonavir in the treatment of SARS: initial virological and clinical findings. *Thorax* **59**: 252-256, 2004.
  15. The General Office of National Health Commission. Diagnosis and treatment protocol for novel coronavirus pneumonia trial version7 (released by National Health Commission & State administration of Traditional Chinese Medicine on March 3,2020).
  16. Cao B, Wang Y, Wen D, et al. A trial of lopinavir-ritonavir in adults hospitalized with severe Covid-19 **382**: 1787-1799, 2020.
  17. Beigel JH, Tomashek KM, Dodd LE, et al. Remdesivir for the treatment of Covid-19 - preliminary report. *N Engl J Med* **383**: 1813-1826, 2020.
  18. Brooks SK, Webster RK, Smith LE, et al. The psychological impact of quarantine and how to reduce it: rapid review of the evidence. *Lancet* **395**: 912-920, 2020.

The Internal Medicine is an Open Access journal distributed under the Creative Commons Attribution-NonCommercial-NoDerivatives 4.0 International License. To view the details of this license, please visit (<https://creativecommons.org/licenses/by-nc-nd/4.0/>).