



## Case report

## Trans-arterial therapy for Fibrolamellar carcinoma: A case report and literature review

M.M. Bernon<sup>a,\*</sup>, K. Gandhi<sup>c</sup>, H. Allam<sup>a</sup>, S. Singh<sup>b</sup>, J. Kloppers<sup>a</sup>, E. Jonas<sup>a</sup><sup>a</sup> Surgical Gastroenterology Unit, Division of General Surgery, University of Cape Town Health Sciences Faculty and Groote Schuur Hospital, Cape Town, South Africa<sup>b</sup> Division of Anatomical Pathology, University of Cape Town Health Sciences Faculty and Groote Schuur Hospital, Cape Town, South Africa<sup>c</sup> Department of Surgery, Aga Khan University Hospital, Nairobi, Kenya

## ARTICLE INFO

## Keywords:

Fibrolamellar carcinoma  
 Trans-arterial embolization  
 Trans-arterial chemo-embolization  
 Trans-arterial radio-embolization

## ABSTRACT

**Introduction:** Fibrolamellar carcinoma (FLC) is a rare pathologically distinct primary liver cancer. Surgical resection is the only treatment associated with prolonged survival. Trans-arterial embolization (TAE), which is a recognised treatment for hepatocellular carcinoma has been used to treat FLC. We present a case and performed a literature review of patients with FLC treated with TAE.

**Case presentation:** We present a 19-year old female with a large potentially resectable FLC which was initially treated with trans-arterial chemo-embolization (TACE) with drug eluting beads. The TACE was followed by surgical resection. Histology confirmed tumour necrosis related to the previous TACE.

**Discussion & literature review:** We identified seven case reports and one case series of TAE for FLC. TAE was either used as a neo-adjuvant therapy to facilitate subsequent tumour resection or as a palliative treatment modality. We propose an algorithm for the treatment of FLC that includes TAE.

**Conclusion:** The rarity of FLC and the paucity of data precludes establishing clear evidence-based standards of care. We propose an algorithm for the treatment of FLC. The establishment of an international registry may facilitate the collection of better quality evidence.

## 1. Introduction

Fibrolamellar carcinoma (FLC), first described by Edmondson in 1956, is a rare pathologically distinct primary liver cancer that occurs in adolescents and young adults and is not associated with cirrhosis or underlying liver disease [1]. Fibrolamellar carcinoma is histologically characterised by large eosinophilic, hepatocyte-like polygonal cells, with prominent nucleoli and pale inclusion bodies surrounded by abundant fibrotic bands (lamellae) [1,2] and was initially described as a variant of hepatocellular carcinoma (HCC). Genomic sequencing has however shown clear molecular differences between FLC and HCC. Fusion of the DNAJB1 and PRKACA genes due to a deletion on chromosome 19 which activates protein kinase A has been demonstrated in FLC with a specificity of 100% [3]. There is less male predominance (male/female ratio 1.7), than in HCC (male/female ratio 3.2) and a number of studies have suggested that FLC has a better prognosis compared to HCC [4].

For curative intent, surgical resection is the treatment of choice.

There are, however, a few reports of orthotopic liver transplantation for patients with irresectable disease [5,6]. Data on systemic therapy for FLC are sparse and the role of chemotherapy in the neo-adjuvant, adjuvant and palliative settings remains unclear [7]. Similar to HCC, FLC has predominantly an arterial supply which makes trans-arterial embolisation (TAE) including bland embolisation, trans-arterial chemo-embolisation (TACE) and trans-arterial radio-embolisation (TARE) feasible. We report on a case and performed a literature review of the use of TAE for FLC.

This case report has been reported according to the SCARE criteria [8]. The literature review was conducted according to the PRISMA guidelines [9] and registered in the PROSPERO register (ID: CRD42020193665).

## 2. Presentation of case

A 19-year-old female presented to an HPB unit in an academic hospital with a one-month history of upper abdominal pain and

\* Corresponding author at: Division of General Surgery, University of Cape Town Health Sciences Faculty, Anzio Road, Observatory, Cape Town 7925, South Africa.

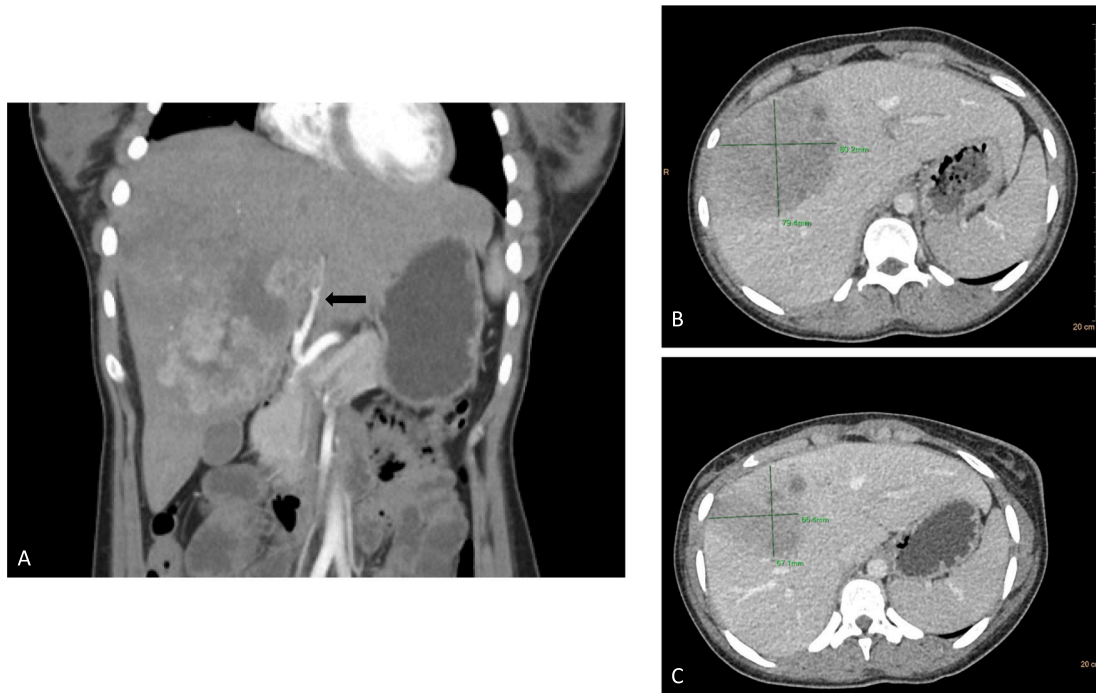
E-mail address: [mm.bernon@uct.ac.za](mailto:mm.bernon@uct.ac.za) (M.M. Bernon).

<https://doi.org/10.1016/j.ijscr.2022.106980>

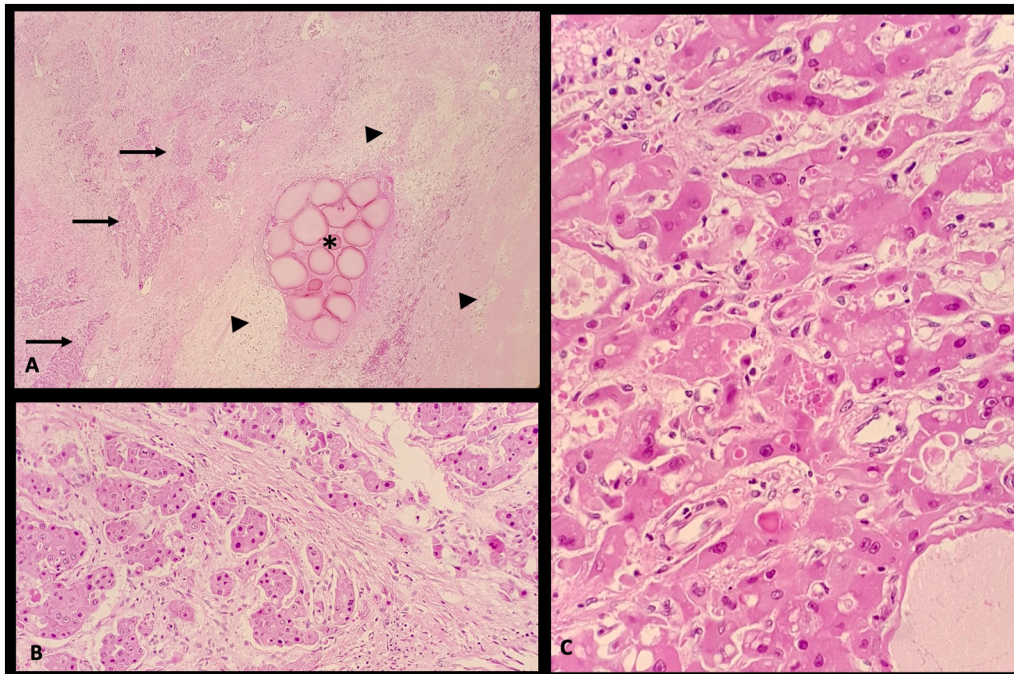
Received 31 January 2022; Received in revised form 14 March 2022; Accepted 24 March 2022

Available online 29 March 2022

2210-2612/© 2022 The Authors. Published by Elsevier Ltd on behalf of IJS Publishing Group Ltd. This is an open access article under the CC BY-NC-ND license (<http://creativecommons.org/licenses/by-nc-nd/4.0/>).



**Fig. 1.** A) CT scan, coronal view, arterial phase: demonstrating a hypervascular tumour with areas of hypodensity. The arrow points to the area where the tumour abuts the left hepatic artery. B) CT scan, axial view, portal venous phase: showing dimensions of tumour prior to TACE C) CT scan, axial view, portal venous phase: showing decrease in size 3 months after the TACE.



**Fig. 2.** Low power magnification showed: A) Intravascular embolization material (\*) with surrounding necrosis (arrow heads) but also viable tumour (arrows); B) The tumour arranged as nests and acinar structures with intervening hyalinization; C) Large polygonal tumour cells with abundant eosinophilic cytoplasm.

unintentional weight loss (five kilograms over the preceding three months). She had no history of previous medical conditions or surgical interventions. She was a non-smoker and did not use alcohol. Her general examination was unremarkable. On abdominal examination a hard, non-tender epigastric mass could be palpated. Laboratory examinations showed a normal full blood count, normal liver function tests, positive hepatitis B surface antibody in keeping with previous immunization,

negative hepatitis C and HIV serology and an AFP of 4.5 ku/L. An abdominal and chest contrast-enhanced (CE) CT scan and MRI with hepatocyte-specific contrast (Gd-EOB-DTPA, Primovist®, Bayer Schering Pharma, Berlin, Germany) were performed which showed a centrally located tumour, 90 mm in largest diameter, situated in segments IV, V, VI & VIII. The tumour involved the right portal vein & right hepatic artery and was closely related to the left hepatic artery (Fig. 1a). At a

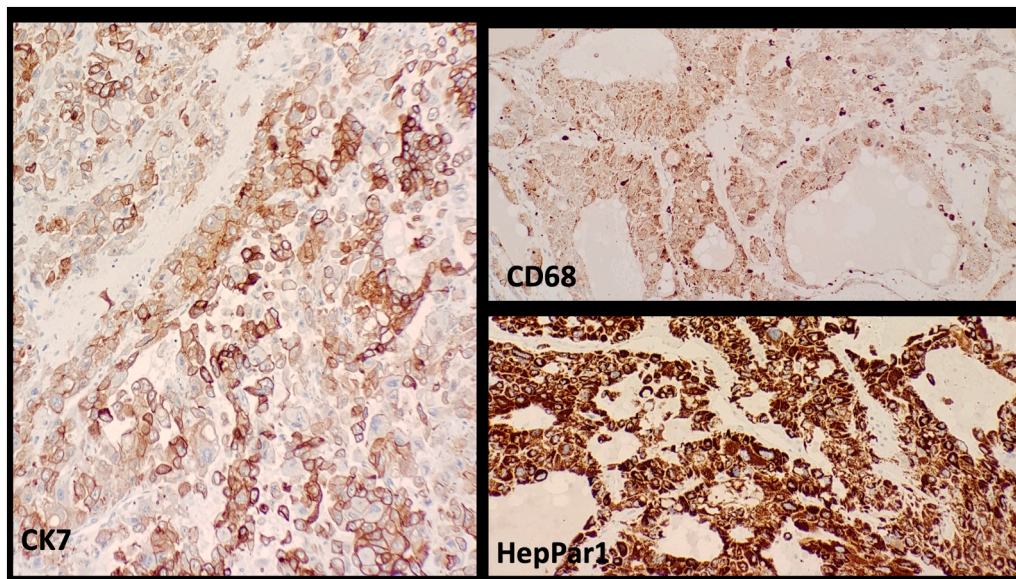


Fig. 3. On immunohistochemical staining the cells displayed HepPar1, CK7 and CD68 immunopositivity and immune-negativity for AFP.

**Table 1**  
Included studies, patient and tumour characteristics.

Publication	Year	Country	Patients with FLC treated with TAA	Age (years)	Gender	Position of tumour	Tumour size (mm)*
Spence RA, et al. [34]	1987	South Africa	1	19	M	Left liver	NR
Wang Y, et al. [35]	1999	China	5	NR	NR	NR	NR
Chang YC, et al. [36]	2003	Taiwan	1	72	M	Right liver	120
Czauderna P, et al. [37]	2006	Poland	1	7	F	Bilateral and multifocal	110
Hasiguchi M, et al. [38]	2013	Japan	1	16	F	Right liver	100
Eng J, et al. [39]	2018	Malaysia	1	46	F	Right liver	200
Mafeld S, et al. [40]	2018	UK	1	52	F	Central (segments 1, 4a, 7, 8)	95
Polavarapu AD, et al. [41]	2019	USA	1	37	M	Left liver	80
Current case	2020	South Africa	1	19	F	Right liver	90

NR not reported \*If multifocal – largest tumour size reported.

**Table 2**  
Therapeutic interventions and results.

Authors	Intent	Type of TAE	Surgical resection	Response		Survival
				Radiological	Histological	
Spence RA, et al. [34]	Palliative	Lipiodol, doxorubicin, gelfoam	NA	Yes	NA	38 months at time of publication
Wang Y, et al. [35]	Palliative (1)	Lipiodol	No	Yes	NR	Median survival 25 months
	Downsizing (4)		4 – no detail	Yes	NR	5-year survival 25%
Chang YC, et al. [36]	Palliative	Lipiodol and doxorubicin, gelfoam	NA	NR	NA	24 months at time of publication
Czauderna P, et al. [37]	Downsizing	Lipiodol and doxorubicin + mitomycin, gelfoam	No	Yes	N/A	Died from TACE complication
Hasiguchi M, et al. [38]	Downsizing	Lipiodol and epirubicin + mitomycin	Extended right hemihepatectomy	Yes	Yes	63 months at time of publication
Eng J, et al. [39]	Downsizing	Drug eluting beads, doxorubicin	Extended right hemihepatectomy	NR	NR	24 months at time of publication
Mafeld S, et al. [40]	Downsizing	Drug eluting beads, doxorubicin followed by trans arterial radio-embolisation	Extended left hemihepatectomy	Yes	Yes	2 months at time of publication
Polavarapu AD, et al. [41]	Bleeding control	Gelfoam	Left hemihepatectomy	Yes	Yes	NR
Current case	Downsizing	Drug eluting beads, doxorubicin	Extended right hemihepatectomy	Yes	Yes	18 months at time of publication

multidisciplinary team meeting an extended right hepatectomy was recommended. Due to concern of the close relationship of the tumour to the left portal structures a TACE using drug eluting beads was recommended. Following the TACE she developed a transient post

embolectomy syndrome and a liver abscess that was treated with percutaneous aspiration and antibiotics. A follow-up CE-CT scan three months after the TACE confirmed response (Fig. 1b & c). An extended right-sided hemihepatectomy was performed and the postoperative

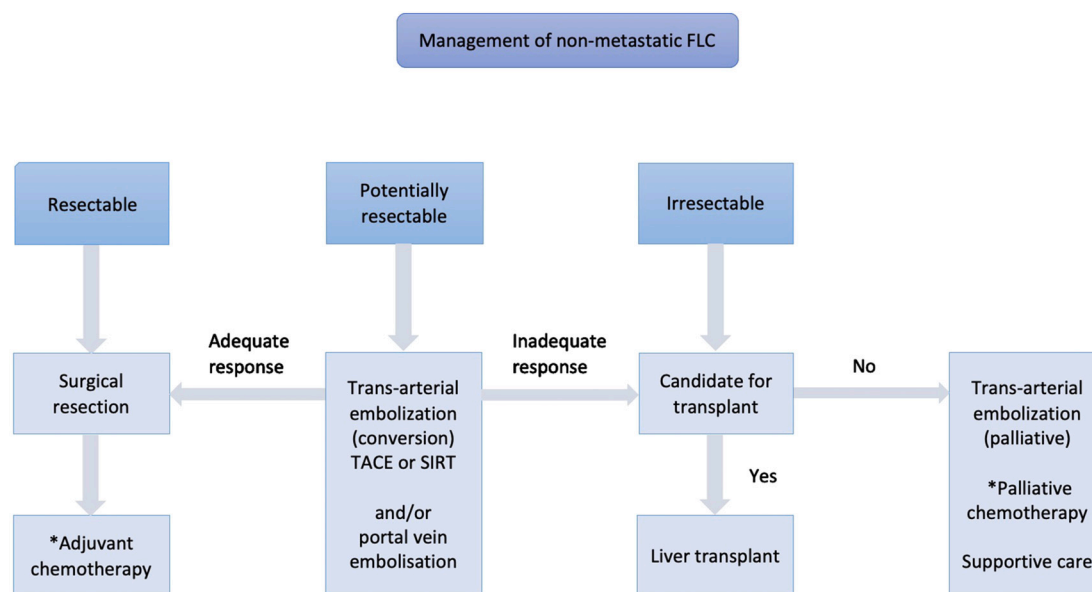


Fig. 4. Suggested treatment algorithm (\*ideally as part of a clinical trial).

course was uneventful. The surgery was performed by an experienced consultant HPB surgeon assisted by two fellows. The patient was discharged on post-operative day seven. Histology showed findings typical for FLC with evidence of tumour necrosis related to the previous TACE (Figs. 2 and 3). The patient is recurrence free 18 months after the procedure.

### 3. Discussion

The literature review identified seven case reports and one case series of patients with FLC treated with TAE [10–17]. We included this case report in the analysis (Tables 1 & 2). Details of the literature review can be found in the attached supplementary material.

Treatments used for HCC, including resection, liver transplantation and TAE have been extended to FLC with little supporting evidence. There are no guidelines for resection of FLC, but in general patients would be considered as candidates for resection if there is no evidence of extrahepatic disease and the tumour is macroscopically resectable with preservation of a sufficient future liver remnant. Five-year survival rates ranging from 28 to 76% following surgical resection have been reported for FLC [18–20]. Extensive resections are often possible due to the younger age of patients and the absence of underlying liver disease. These factors may account for the better outcomes reported compared to patients with HCC, rather than the previously hypothesized more indolent behaviour of FLC. Five-year survival rates following liver transplantation of 43–55% have been reported which is worse than transplantation for HCC within most criteria [5,6,18]. This discrepancy may be due to more advanced FLC tumours being transplanted, but a more aggressive tumour biology, possibly aggravated by post-transplantation immunosuppression cannot be excluded.

Conceptually TAE such as TACE and TARE are attractive, as similar to HCC, FLCs are generally hypervascular. As opposed to HCC, where the value of TAE has been established and its role is well defined, the benefit and indications in FLC are less clear. Trans-arterial embolisation causes selective tumour necrosis by disrupting the arterial supply to the tumour. Due to the dual arterial and portal venous blood supply, necrosis of the surrounding liver parenchyma is rare. The tumour necrosis caused by arterial deprivation is augmented by high concentrations of chemotherapeutic agent in TACE and localised radiation in TARE. In the majority of studies reporting on TAE in FLC the indication was for downsizing tumours to facilitate resection [10–17].

We propose an algorithm for the treatment of FLC (Fig. 4) which includes TAE. Patients with clearly resectable disease should have a surgical resection. Trans-arterial embolisation can be used to facilitate surgical resection in patients with large tumours. Volume manipulation such as portal vein embolisation may be required in some patients to ensure an adequate functional liver remnant. Patients with irresectable disease confined to the liver should be considered for transplant. TAE can also be used as a palliative modality if the disease is confined to the liver. There are a number of new immuno-therapies targeting the DNAJB1-PRKACA oncogene that are currently being investigated [3]. The role of systemic therapy remains unclear and regardless of indication should preferably be used in the setting of clinical trials.

### 4. Conclusion

Due to the rarity of the tumour, evidence on optimal management is limited. Trans arterial therapies such as TACE and TARE may have a role in the management of patients with FLC. Registries, preferably international, would allow for larger patient cohorts in whom the role of not only TAE but also systemic therapies in neo-adjuvant, adjuvant and palliative settings can be assessed.

### Consent

Written informed consent was obtained from the patient for publication of this case report and accompanying images. A copy of the written consent is available for review by the Editor-in-Chief of this journal on request.

### Ethical approval

Ethics approval for systematic reviews and case reports are waived by the Human Research Ethics Committee of the University of Cape Town.

### Funding

None.

**Guarantor**

M Bernon.

**Provenance and peer review**

Not commissioned, externally peer-reviewed.

**Research registration number**PROSPERO registry: [https://www.crd.york.ac.uk/prospero/display\\_record.php?ID=CRD42020193665](https://www.crd.york.ac.uk/prospero/display_record.php?ID=CRD42020193665).**CRediT authorship contribution statement**

MM Bernon: conception and design of the study, drafting the article, and final approval.

K Gandhi &amp; H Ali: data curation and literature review.

C Kloppers, S Singh: writing, reviewing and editing.

E Jonas: supervision and writing, reviewing and editing.

**Declaration of competing interest**

None.

**Appendix A. Supplementary data**Supplementary data to this article can be found online at <https://doi.org/10.1016/j.ijscr.2022.106980>.**References**

- [1] H.A. Edmondson, Differential diagnosis of tumors and tumor-like lesions of liver in infancy and childhood, *AMA J. Dis. Child.* 91 (2) (1956) 168–186.
- [2] M.M. Berman, N.P. Libbey, J.H. Foster, Hepatocellular carcinoma. Polygonal cell type with fibrous stroma—an atypical variant with a favorable prognosis, *Cancer* 46 (6) (1980) 1448–1455.
- [3] R.P. Graham, et al., Molecular testing for the clinical diagnosis of fibrolamellar carcinoma, *Mod. Pathol.* 31 (1) (2018) 141–149.
- [4] T. Eggert, et al., Fibrolamellar hepatocellular carcinoma in the USA, 2000–2010: a detailed report on frequency, treatment and outcome based on the surveillance, epidemiology, and end results database, *United European Gastroenterol J* 1 (5) (2013) 351–357.
- [5] F. Stipa, et al., Outcome of patients with fibrolamellar hepatocellular carcinoma, *Cancer* 106 (6) (2006) 1331–1338.
- [6] G. El-Gazzaz, et al., Outcome of liver resection and transplantation for fibrolamellar hepatocellular carcinoma, *Transpl. Int.* 13 (Suppl. 1) (2000) S406–S409.
- [7] W.T. Kassahun, Contemporary management of fibrolamellar hepatocellular carcinoma: diagnosis, treatment, outcome, prognostic factors, and recent developments, *World J. Surg. Oncol.* 14 (1) (2016) 151.
- [8] R.A. Agha, et al., The SCARE 2020 guideline: updating consensus surgical Case Report (SCARE) guidelines, *Int. J. Surg.* 84 (2020) 226–230.
- [9] M.J. Page, et al., The PRISMA 2020 statement: an updated guideline for reporting systematic reviews, *BMJ* 372 (2021), n71.
- [10] R.A. Spence, et al., Unresectable fibrolamellar hepatocellular carcinoma treated with intra-arterial lipiodolised doxorubicin. A case report, *S. Afr. Med. J.* 72 (10) (1987) 701–703.
- [11] Y. Wang, J. Zhang, Y. Gao, M. Yu, Y. Gong, G. Yu, Therapeutic efficacy of transcatheter arterial embolization of primary hepatocellular carcinoma: discrepancy in different histopathologic subtypes, *Chin. Med. J.* 112 (3) (1999) 264–268.
- [12] Y.C. Chang, Y.C. Dai, N.H. Chow, Fibrolamellar hepatocellular carcinoma with a recurrence of classic hepatocellular carcinoma: a case report and review of oriental cases, *Hepato-Gastroenterology* 50 (53) (2003) 1637–1640.
- [13] P. Czuderna, et al., Preliminary experience with arterial chemoembolization for hepatoblastoma and hepatocellular carcinoma in children, *Pediatr. Blood Cancer* 46 (7) (2006) 825–828.
- [14] M. Hasiyuchi, S. Ueno, M. Sakoda, S. Lini, K. Minami, K. Andou, Y. Mataka, K. Maemure, H. Shinchi, S. Natsugoe, A long-term survivor with fibrolamellar hepatocellular carcinoma receiving aggressive surgery in combination with portal vein embolization, *Jpn. J. Gastroenterol. Surg.* 46 (11) (2013) 822–829.
- [15] J.Y. Eng, S.Y. Soon, H.Y. Winnie Ling, Curative lung metastectomy and complete pathological response after neo-adjuvant GEMOX chemotherapy for relapse fibrolamellar hepatocellular carcinoma, *Med J Malaysia* 73 (1) (2018) 46–48.
- [16] S. Mafeld, et al., Fibrolamellar hepatocellular carcinoma: treatment with Yttrium-90 and subsequent surgical resection, *Cardiovasc. Intervent. Radiol.* 41 (5) (2018) 816–820.
- [17] A.D. Polavarapu, et al., Spontaneous rupture of fibrolamellar variant hepatocellular carcinoma, *Gastroenterology Res.* 12 (3) (2019) 166–170.
- [18] A.D. Pinna, et al., Treatment of fibrolamellar hepatoma with subtotal hepatectomy or transplantation, *Hepatology* 26 (4) (1997) 877–883.
- [19] P. Herman, et al., Surgical treatment of fibrolamellar hepatocellular carcinoma: an underestimated malignant tumor? *Hepatobiliary Pancreat. Dis. Int.* 13 (6) (2014) 618–621.
- [20] F. Bhaijee, M.L. Locketz, J.E. Krige, Fibrolamellar hepatocellular carcinoma at a tertiary Centre in South Africa: a case series, *S. Afr. J. Surg.* 47 (4) (2009) 108–111.