

Utilisation of musculoskeletal ultrasonography for the evaluation of septic arthritis in a patient presenting to the emergency department with fever during the era of COVID-19

Jiodany Perez , Stefani Sorensen, Michael Rosselli

Department of Emergency Medicine, Mount Sinai Medical Center, Miami Beach, Florida, USA

Correspondence to
Dr Jiodany Perez;
jjoperezmd@gmail.com

Accepted 6 April 2021

SUMMARY

Prompt recognition and treatment of septic arthritis are crucial to prevent significant morbidity and mortality in affected patients. During the current COVID-19 pandemic, anchoring bias may make an already challenging diagnosis like septic arthritis more difficult to diagnose quickly and efficiently. Musculoskeletal (MSK) point of care ultrasonography (POCUS) is an imaging modality that can be used to quickly and efficiently obtain objective findings that may help a clinician establish the diagnosis of septic arthritis. We report a case where MSK POCUS was a key element in establishing the diagnosis of glenohumeral joint septic arthritis and subdeltoid septic bursitis for a patient that presented to the emergency department with a fever during the era of the COVID-19 pandemic.

BACKGROUND

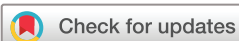Mortality rates for septic arthritis have been documented to be between 3% and 25%.¹⁻⁴ The incidence of septic arthritis varies in the literature; however, 4–60 cases per 100 000 population per year is suggested.¹⁻⁵ Rutherford *et al* described how the incidence of septic arthritis has been climbing, with a reported rise of 43% between 1998 and 2013 (5.5/100 000 to 7.3/100 000). The largest increase in incidence was noted to be in patients >75 years of age.⁴ The primary symptoms of this disease process include monoarticular joint pain, erythema, warmth and limited mobility. However, these symptoms have a broad differential diagnosis including trauma, microcrystalline arthritis, rheumatoid arthritis, avascular necrosis, Lyme disease, osteomyelitis, malignancy, transient synovitis, lupus and others.⁶ The associated constitutional symptoms of fever, chills and rigours may help in making the diagnosis if present. However, history and clinical examination findings alone have been found to be poorly sensitive for the diagnosis of acute septic arthritis.⁷

Further complicating the early recognition of this infectious process is the COVID-19 pandemic. Multiple case reports have demonstrated how cognitive bias has led to the delayed diagnosis and treatment of time sensitive disease processes that present with similar symptoms as a COVID-19 viral illness.^{8,9} The use of musculoskeletal (MSK) point of care ultrasonography (POCUS) has been shown to be an effective tool in the diagnosis of

both septic arthritis and septic bursitis. MSK POCUS not only allows one to directly image the joint and bursa affected, but it improves the success rate of needle-guided arthrocentesis.¹⁰ The latter is critical in establishing the definitive diagnosis, as identifying an offending organism via synovial fluid culture will distinguish septic arthritis from the other arthropathies listed above.¹¹ In this article, we discuss a case where POCUS of the shoulder assisted in the evaluation of a patient presenting with the chief complaint of fever in the era of the COVID-19 pandemic.

THE CASE

A 79-year-old man with a significant medical history remarkable for diabetes mellitus, hypertension and coronary artery disease presented to the emergency department complaining of fever. Review of systems was positive for mild shortness of breath, chills, myalgias and arthralgias for the past 2 days. The patient stated that he sought medical care in the emergency department today because he was concerned that he was infected with the COVID-19 virus. Given his possible exposure during a recent hospital admission just 3 days prior for stent placement following an ST elevation myocardial infarction, he believed himself to be at increased risk. The patient otherwise denied recent trauma, rash, travel or sick contacts at home. On physical examination, the patient's initial vital signs included a blood pressure of 122/62 mm Hg, pulse of 103 beats per minute, oral temperature of 38.4°C, respiratory rate of 21 breaths per minute and an O₂ saturation of 93% on room air. The patient was not in any acute distress on initial evaluation. He was found to be tachypneic with lung sounds clear to auscultation bilaterally. Cardiac examination demonstrated a tachycardic regular rhythm without murmurs, rubs or gallops. Pulses were 2+ in the bilateral radial, dorsalis pedis and posterior tibial arteries. MSK examination was remarkable for slight tenderness to palpation of the anterior and lateral aspect of his right shoulder. He had decreased range of motion of his right shoulder in abduction, flexion and extension with associated pain. His right upper extremity was noted to be swollen compared with his left without any associated warmth or erythema. Neurologically, grip strength and sensory function were grossly intact bilaterally.



© BMJ Publishing Group Limited 2021. No commercial re-use. See rights and permissions. Published by BMJ.

To cite: Perez J, Sorensen S, Rosselli M. *BMJ Case Rep* 2021;**14**:e242370. doi:10.1136/bcr-2021-242370

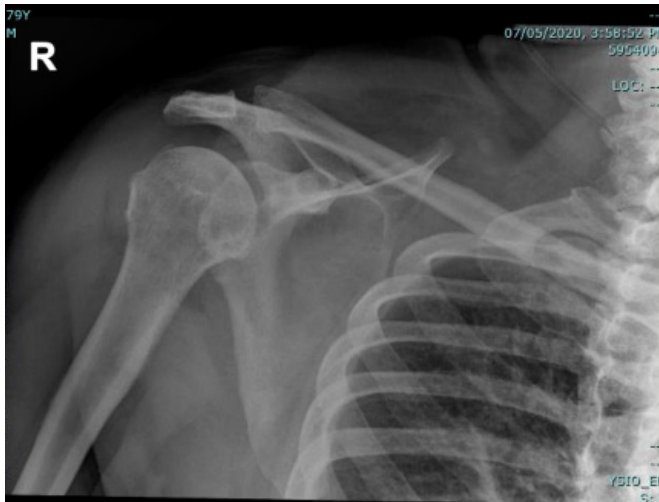

Figure 1 Anteroposterior-X-ray of right shoulder with a radiological interpretation of mild acromioclavicular and glenohumeral arthrosis, and rotator cuff calcific tendinitis without fracture or dislocation.

INVESTIGATIONS

The patient had a normal leucocyte count, lactic acid was 2.0 mmol/L (0.4–2.0 mmol/L), C-Reactive Protein was 332 mg/L (0.00–3.00 mg/L) and erythrocyte sedimentation rate was 102 mm/h (0–20 mm/hour). The patient had an unremarkable chest X-ray, CT abdomen/pelvis, urinalysis and negative COVID-19 PCR. A right upper extremity duplex ultrasound was performed to evaluate for deep vein thrombosis in light of the mild right upper extremity swelling noted on the examination, which was unremarkable. Considering no clear source of the fever was identified, further patient history was ascertained. It was at that point that the patient verbalised having gradually worsening right shoulder pain over the past few months. The patient had recently been evaluated by his primary care physician for that pain and he was diagnosed with glenohumeral osteoarthritis. Patient did not follow-up with an orthopedist or

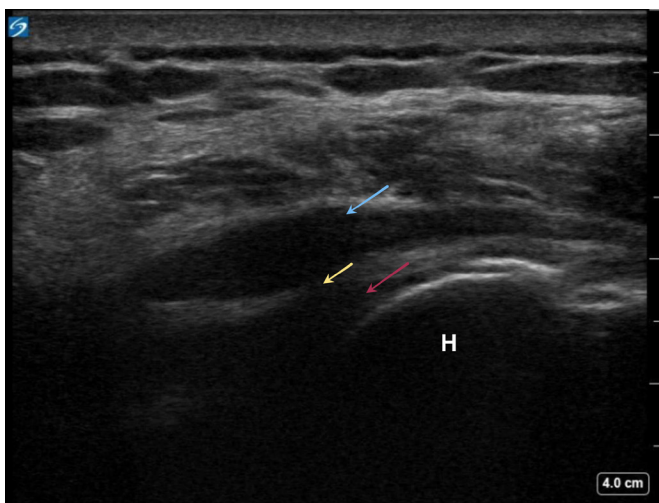


Figure 2 Ultrasonography evaluation of the right subdeltoid bursa. Position 4 from the Jacobson 5-position shoulder protocol revealing a distended hypoechoic subdeltoid bursa (blue arrow), a glenohumeral joint effusion (red arrow) and a communication between these two fluid collections suggesting an infraspinatus rotator cuff tear (yellow arrow). The humeral head is also identified in this image (H).

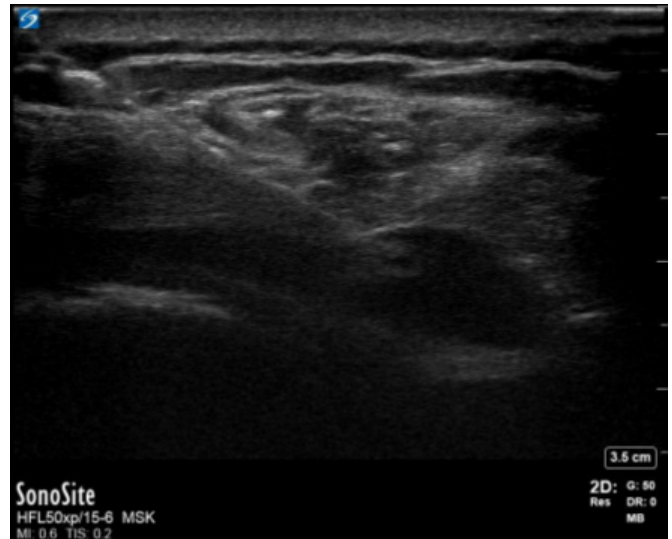

Figure 3 Ultrasound-guided needle aspiration of the right subdeltoid bursa. Position 4 in the Jacobson 5-position shoulder ultrasonography evaluation. The orientation of the probe was rotated 180° compared with figure 2 to facilitate in plane needle guidance.

rheumatologist, nor did he have a subacromial or intra-articular steroid injection.

With no clear aetiology of his fever, a right shoulder X-ray was performed ([figure 1](#)) which demonstrated chronic, mild acromioclavicular and glenohumeral arthrosis with rotator cuff calcific tendinitis. A SonoSite X-Porte ultrasound machine with a 15-6 MHz wide-footprint linear transducer was selected for point of care ultrasound of the right posterior shoulder girdle. The MSK setting available on the SonoSite X-Porte was selected in order to optimise image display. For our case, we used a limited glenohumeral joint point assessment based on the five-position ultrasound examination of the shoulder described in Jon A. Jacobson's *Fundamentals of Musculoskeletal Ultrasound*. The five positions being: position 1: evaluation of the biceps brachii long head; position 2: evaluation of the subscapularis and for biceps tendon dislocation; position 3: evaluation of the supraspinatus and infraspinatus; position 4: evaluation of the acromioclavicular joint, subacromial-subdeltoid bursa with dynamic evaluation; and finally position 5: evaluation of the infraspinatus, teres minor and the posterior glenoid labrum.¹² Using positions 4 and 5, a distended, hypoechoic subdeltoid bursa was identified, along with a glenohumeral joint effusion. Communication between these two fluid collections was seen, suggesting that a significant rotator cuff tear was present. These findings were identified by the emergency medicine resident performing the ultrasound under direct supervision of an emergency medicine/sports medicine trained attending physician ([figure 2](#)). Ultrasound-guided needle aspiration of the right subdeltoid bursa was subsequently performed ([figure 3](#)), which yielded 20 mL of yellow purulent fluid. Fluid analysis demonstrated 199 294 nucleated cells/ μ L, 0 red blood cells and calcium pyrophosphate crystals. Cultures of this aspirate went on to grow methicillin-resistant *Staphylococcus aureus*, which were additionally present in the patient's blood cultures on day 1 of hospitalisation.

TREATMENT

The patient was treated in the emergency department with 1750 mg of vancomycin and 2 g of cefepime intravenously and

admitted with the diagnosis of septic bursitis. 1250 mg of intravenous vancomycin was continued every 12 hours throughout the patient's hospitalisation under the guidance of infectious disease. Cefepime was discontinued on day 2 given that both blood and synovial fluid cultures were growing staphylococcus. An orthopaedic surgeon was consulted in the emergency department, and he subsequently took the patient to the operating room the following day. He performed a right arthroscopic glenohumeral joint irrigation and debridement with synovectomy and subacromial decompression. Documented findings from the procedure included purulent fluid in the glenohumeral joint, massive rotator cuff tears involving the supraspinatus and infraspinatus, severe glenohumeral arthritis with near loss of the articular cartilage, florid bursitis and labral fraying. Synovial fluid analysis yielded many neutrophils, many gram positive cocci in pairs and clusters and an isolated strain of methicillin-resistant *S. aureus*. The patient additionally underwent a transesophageal echocardiogram (TEE) to assess for the possibility of infective endocarditis in the setting of his recent admission for a myocardial infarction and now gram-positive bacteremia. The TEE performed did not show any evidence of infective endocarditis.

OUTCOME

The patient's condition improved throughout his hospital stay. He was ultimately discharged on his 10th day of hospitalisation to a skilled nursing facility with a prescription for 6 weeks of oral vancomycin 1250 mg every 12 hours and instructions to follow-up with his primary care physician and orthopaedic surgeon in 1 week. The patient was subsequently readmitted to the hospital 1 month later for hypoxia secondary to COVID-19 infection. He recovered and was discharged home with home healthcare after 8 days. He completed his course of oral vancomycin during this admission. His blood cultures were negative throughout the entirety of this hospitalisation, and he was noted to have resolution of his right upper extremity pain and swelling. At 6-month follow-up, patient was not having right shoulder pain or swelling and his range of motion was dramatically improved.

DISCUSSION

In our initially undifferentiated patient, there was no classic constellation of symptoms identified on his presentation to strongly suggest that septic arthritis would be his ultimate diagnosis. He admitted to intermittently taking ibuprofen as needed for pain, but he had not taken the medication recently and had no other identifiable factors that may be masking the severity of his presentation. This speaks to the point that Carpenter *et al* emphasised in their study, when they highlighted the poor sensitivity of the history and physical for the diagnosis of septic arthritis. Carpenter *et al* stressed that a high index of suspicion must be present for a clinician to make this time-sensitive diagnosis.⁷

Further complicating an already difficult clinical diagnosis is the current COVID-19 pandemic. Multiple case reports have demonstrated how the current COVID-19 pandemic has increased the risk of anchoring bias in clinicians caring for patients presenting with similar symptoms as a COVID-19 viral illness.^{8,9} Di Matteo *et al* assert the importance of maintaining POCUS services during the COVID-19 pandemic for this reason.¹³

On reflection, our patient had several predisposing factors for the development of septic arthritis. First, he had severe osteoarthritis of the right shoulder. Septic arthritis usually does present as a monoarticular arthritis most commonly affecting the knee,

followed by the hip, shoulder and elbow. Septic arthritis of the shoulder accounts for 5%–12% of all cases of septic arthritis with the overall incidence being 3200 cases per year in the USA.^{14–16} Jiang *et al* reviewed 7145 cases of native shoulder septic arthritis in the USA, finding that the overall inpatient mortality rate was 2.6% for these patients, while other studies have reported mortality rates as high as 11%–17%.^{16–19} The percentage of patients afflicted by septicemia and septic shock were also reported in Jiang *et al*'s study at 24.2% and 2.3%, respectively.¹⁶ Hematogenous spread from bacteremia is the most common cause of septic arthritis representing roughly 70% of cases, and bacteremia is more likely to affect a large joint with pre-existing arthritis.² Therefore, the patient's underlying osteoarthritis put him at higher risk for hematogenous seeding of this joint. Second, our patient was found to have calcium pyrophosphate crystals in his synovial fluid aspirate. Although our patient had not admitted to prior attacks of pseudogout, he could have had an underlying crystal-induced arthropathy compounding a second inflammatory process to the already arthritic glenohumeral joint. Third, our patient had a significant rotator cuff tear. In addition to hematogenous spread from bacteremia, other potential causes of septic arthritis include direct inoculation from trauma, recent surgical procedures and contiguous spread from local infections including bursitis, cellulitis and osteomyelitis.⁶ Despite the patient being unable to recall a specific incident, there could have been a trauma to the rotator cuff also encouraging direct inoculation. Finally, the patient was of advanced age and had a history of diabetes mellitus. Both of these characteristics have not only been proven to be risk factors for the development of septic arthritis, but they are also risk factors for mortality secondary to septic arthritis.^{20,21}

It is important to note that the subdeltoid bursa was aspirated in the emergency department in this case, not the glenohumeral joint. Unlike septic arthritis, deep septic bursitis is rarely the result of hematogenous dissemination, making it critical to exclude a contiguous septic arthritis under this circumstance.²² While the patient did also have a glenohumeral effusion visualised by ultrasound, the communication between the glenohumeral effusion and the subdeltoid bursa suggested that the process affecting the subdeltoid bursa was likely also affecting the glenohumeral joint. Our hypothesis was proven to be true intraoperatively. The bursa was selected for aspiration given its ease of access visualised on ultrasound, in addition to a greater anticipated yield of fluid for analysis as compared with the glenohumeral joint.

It is crucial that clinicians use the tools available to them in order to make the time sensitive diagnosis of septic arthritis. POCUS has become an integral part of the emergency department and its use in the evaluation of the undifferentiated patient has been proven to positively influence patient outcomes.²³ With that being said, the ability to acquire and interpret ultrasound images are skills that require knowledge of anatomy and ultrasound mechanics. One common limitation of the use of ultrasound is that it is operator-dependent. Implementing a curriculum for training physicians to learn how to effectively use MSK POCUS may help increase user reliability and reproducibility of objective findings that may be obtained through POCUS. Larrivée *et al* were able to create and implement an MSK POCUS curriculum which demonstrated improvement in resident physician knowledge, skills and confidence with MSK POCUS.²⁴ Similar curriculums may be created and implemented during training for different specialties where MSK POCUS can aid in the evaluation of the undifferentiated patient.

SUMMARY

In this case, we demonstrated how the use of MSK POCUS helped in the evaluation of an emergency department patient with the presumed diagnosis of COVID-19 viral illness. The use of MSK POCUS also assisted in the guidance of the bursal aspiration necessary to establish the definitive diagnosis.

Learning points

- ▶ Septic arthritis is a time sensitive diagnosis where a delay in making the diagnosis and initiation of treatment can lead to high morbidity or mortality.
- ▶ Since the history and physical examination are poorly sensitive for the diagnosis of septic arthritis, the use of musculoskeletal point of care ultrasonography provides objective findings that assist a clinician in making this time-sensitive diagnosis, which ultimately depends on the results of a synovial fluid analysis.
- ▶ Anchoring bias is a well-recognised risk for diagnosticians. In the era of the COVID-19 pandemic, it is important for clinicians to recognise this bias and maintain a broad differential diagnosis when managing a patient with the presumed diagnosis of COVID-19 viral illness.

Contributors JP, SS and MR contributed to the preparation and review of the initial manuscript. All authors approved the final version.

Funding The authors have not declared a specific grant for this research from any funding agency in the public, commercial or not-for-profit sectors.

Competing interests None declared.

Patient consent for publication Obtained.

Provenance and peer review Not commissioned; externally peer reviewed.

This article is made freely available for use in accordance with BMJ's website terms and conditions for the duration of the covid-19 pandemic or until otherwise determined by BMJ. You may use, download and print the article for any lawful, non-commercial purpose (including text and data mining) provided that all copyright notices and trade marks are retained.

ORCID iD

Jiodany Perez <http://orcid.org/0000-0002-9502-7833>

REFERENCES

- 1 Goldenberg DL. Infectious arthritis complicating rheumatoid arthritis and other chronic rheumatic disorders. *Arthritis Rheum* 1989;32:496–502.
- 2 Kaandorp CJ, Dinant HJ, van de Laar MAFJ, *et al.* Incidence and sources of native and prosthetic joint infection: a community based prospective survey. *Ann Rheum Dis* 1997;56:470–5.
- 3 Cooper C, Cawley MI. Bacterial arthritis in an English health district: a 10 year review. *Ann Rheum Dis* 1986;45:458–63.
- 4 Rutherford AI, Subesinghe S, Bharucha T, *et al.* A population study of the reported incidence of native joint septic arthritis in the United Kingdom between 1998 and 2013. *Rheumatology* 2016;55:2176–80.
- 5 Morgan DS, Fisher D, Merianos A, *et al.* An 18 year clinical review of septic arthritis from tropical Australia. *Epidemiol Infect* 1996;117:423–8.
- 6 Long B, Koyfman A, Gottlieb M. Evaluation and management of septic arthritis and its mimics in the emergency department. *West J Emerg Med* 2019;20:331–41.
- 7 Carpenter CR, Schuur JD, Everett WW, *et al.* Evidence-Based diagnostics: adult septic arthritis. *Acad Emerg Med* 2011;18:781–96.
- 8 Harada T, Watari T, Miyagami T, *et al.* COVID blindness: delayed diagnosis of aseptic meningitis in the COVID-19 era. *Eur J Case Rep Intern Med* 2020;7:001940.
- 9 Harada Y, Shimizu T. Delayed diagnosis of pulmonary thromboembolism due to Overfocus on COVID-19. *Eur J Case Rep Intern Med* 2020;7:002002.
- 10 Papatheodorou A, Ellinas P, Takis F, *et al.* Us of the shoulder: rotator cuff and non-rotator cuff disorders. *Radiographics* 2006;26:e23.
- 11 Horowitz DL, Katzap E, Horowitz S, *et al.* Approach to septic arthritis. *Am Fam Physician* 2011;84:653–60.
- 12 Jacobson JA. *Fundamentals of musculoskeletal ultrasound*. Philadelphia, PA: Elsevier/Saunders, 2013.
- 13 Di Matteo A, Mankia K, Filippucci E, *et al.* Facing the challenges of running a rheumatology-based ultrasound service in the COVID-19 era. *Rheumatology* 2021;60:1013–5.
- 14 Kaandorp CJ, Dinant HJ, van de Laar MA, *et al.* Incidence and sources of native and prosthetic joint infection: a community based prospective survey. *Ann Rheum Dis* 1997;56:470–5.
- 15 Le Dantec L, Maury F, Flipo RM, *et al.* Peripheral pyogenic arthritis. A study of one hundred seventy-nine cases. *Rev Rhum Engl Ed* 1996;63:103–10.
- 16 Jiang JJ, Pilonov HI, Mass DP, *et al.* Septic arthritis of the shoulder: a comparison of treatment methods. *J Am Acad Orthop Surg* 2017;25:e175–84.
- 17 Leslie BM, Harris JM, Driscoll D. Septic arthritis of the shoulder in adults. *J Bone Joint Surg Am* 1989;71:1516–22.
- 18 Abdel MP, Perry KI, Morrey ME, *et al.* Arthroscopic management of native shoulder septic arthritis. *J Shoulder Elbow Surg* 2013;22:418–21.
- 19 Duncan SFM, Sperling JW. Treatment of primary isolated shoulder sepsis in the adult patient. *Clin Orthop Relat Res* 2008;466:1392–6.
- 20 Kaandorp C, Schaardenburg D, Krijnen P. Risk factors for septic arthritis in patients with joint disease 2005.
- 21 Ferrand J, El Samad Y, Brunschweiler B. *Morbimortality in adult patients with septic arthritis: a three-year hospital-based study*, 2016.
- 22 Small LN, Ross JJ. Suppurative tenosynovitis and septic bursitis. *Infect Dis Clin North Am* 2005;19:991–1005.
- 23 Whitson MR, Mayo PH. Ultrasonography in the emergency department. *Crit Care* 2016;20:227.
- 24 Larrivée S, Rodger R, Larouche P, *et al.* Orthopaedic residents demonstrate retention of point of care ultrasound knowledge after a brief educational session: a Quasi experimental study. *BMC Med Educ* 2019;19:1–9.

Copyright 2021 BMJ Publishing Group. All rights reserved. For permission to reuse any of this content visit <https://www.bmj.com/company/products-services/rights-and-licensing/permissions/>
BMJ Case Report Fellows may re-use this article for personal use and teaching without any further permission.

Become a Fellow of BMJ Case Reports today and you can:

- ▶ Submit as many cases as you like
- ▶ Enjoy fast sympathetic peer review and rapid publication of accepted articles
- ▶ Access all the published articles
- ▶ Re-use any of the published material for personal use and teaching without further permission

Customer Service

If you have any further queries about your subscription, please contact our customer services team on +44 (0) 207111 1105 or via email at support@bmj.com.

Visit casereports.bmj.com for more articles like this and to become a Fellow