



ELSEVIER

Contents lists available at [ScienceDirect](https://www.sciencedirect.com)

## Trauma Case Reports

journal homepage: [www.elsevier.com/locate/tcr](http://www.elsevier.com/locate/tcr)

## Case Report

## Open tibial shaft fracture in a boy with autism spectrum disorder treated using a ring external fixator: A case report

Motoki Mita<sup>\*</sup>, Koji Nozaka, Naohisa Miyakoshi, Yoichi Shimada

Department of Orthopaedic Surgery, Akita University Graduate School of Medicine, Japan

## ARTICLE INFO

## Keywords:

Autism spectrum disorder  
 Pediatric open tibial shaft fracture  
 Surgical treatment  
 Ring external fixator

## ABSTRACT

Autism spectrum disorder covers a group of behaviorally defined disorders that may result in the patient having difficulty staying calm during medical treatments, due to anxiety-related over-reactions. Tibial fractures are the third most common pediatric long-bone fracture. Conservative treatment is selected in many cases, but surgical treatment may be selected in cases of open fracture and no treatment policy has been established. We described the case of a 6-year-old boy with autism spectrum disorder who was unable to stay calm due to anxiety and required sedation. We diagnosed open tibial shaft fracture (Orthopaedic Trauma Association classification 42A1, 4F2A; Gustilo classification type 1). On the day of injury, we performed osteosynthesis using a ring external fixator and primary closure of the open wound. Full weight-bearing was permitted from immediately after surgery. No significant complications were observed postoperatively, and the external fixator was removed 84 days postoperatively. No abnormal alignment of the lower leg, leg-length discrepancy or range of motion disorder was identified. To the best of our knowledge, no other reports have described use of a ring external fixator for open tibial shaft fractures in children with autism spectrum disorder. Using a ring external fixator appears helpful for open tibial shaft fractures in children who are unable to stay calm due to autism spectrum disorder, because there is no need to limit weight-bearing immediately after surgery. For Gustilo classification type 1 pediatric open fracture, primary closure of the open wound is safe after sufficient bone fixation.

## Introduction

Autism spectrum disorder (ASD) represents a group of behaviorally defined disorders that present in the early developmental period and manifest as various symptoms [1]. Anxiety is one of the most common symptoms in children with ASD [2]. Children with ASD may experience difficulty staying calm during medical treatment, because they may overreact due to anxiety.

Tibial shaft fracture is a typical pediatric fracture, but no clear treatment policy has yet been established. Surgical treatment is considered for open fractures, and options such as elastic intramedullary nails, external fixators and plating are available [3,4]. Each treatment method offers specific advantages. The ring external fixator has the advantage of allowing full weight-bearing from immediately after surgery, with no need for rest limitations because the fixator is a biomechanically stable construct [5,6].

Although no reports have discussed the treatment of fractures in children who cannot stay calm due to ASD, fracture treatment with sufficient strength and that does not require rest limitation may be considered necessary. We report a case with open tibial shaft

<sup>\*</sup> Corresponding author at: 44-2 Hasunuma, Hiroomote, Akita city, Akita 010-8543, Japan.  
 E-mail address: [mmita@med.akita-u.ac.jp](mailto:mmita@med.akita-u.ac.jp) (M. Mita).

<https://doi.org/10.1016/j.tcr.2021.100502>

Accepted 14 June 2021

Available online 16 June 2021

2352-6440/© 2021 The Authors. Published by Elsevier Ltd. This is an open access article under the CC BY-NC-ND license

(<http://creativecommons.org/licenses/by-nc-nd/4.0/>).

fracture (Orthopaedic Trauma Association classification 42A1, 4F2A; Gustilo classification type 1) in a 6-year-old boy who had ASD and was expected to have difficulty staying calm, and thus was successfully treated using a ring external fixator.

### Case presentation

A 6-year-old boy with ASD was hit by a truck at a speed of about 20 km/h and was brought to the emergency department. After emergency transportation, the patient was anxious and could not stay calm, so sedation was deemed necessary. The patient complained of pain in the right lower leg and an open wound about 5 mm in length was apparent on the inside of the right lower leg over the tibia. Radiography and computed tomography (CT) showed fractures of the right tibia and fibula (Figs. 1, 2), and open fracture of the right tibial shaft was diagnosed (Orthopaedic Trauma Association classification 42A1, 4F2A). We performed surgery for osteosynthesis and debridement the same day. After irrigating and disinfecting the open wound, we performed closed reduction and obtained good alignment. The tibia was temporarily fixed using a 2.0-mm Kirschner wire, then osteosynthesis was performed using a ring external fixator (Fig. 3). We used two rings, fixing each ring with three wires. Gustilo classification type I was diagnosed and primary closure of the open wound was performed after irrigation. Intravenous antibiotics were continued until postoperative day (POD)2. The patient was allowed full weight-bearing from POD1. As of 3 weeks after surgery, the patient was performing full weight-bearing with no problems in daily activities. Pin-site infection was observed during outpatient follow-up, but was successfully treated with oral antibiotics. As of POD84, the external fixator was removed. At 6 months postoperatively, the patient showed no problems in activities of daily living, no abnormal alignment of the lower leg, and no leg-length discrepancy (Fig. 4).

### Discussion

To the best of our knowledge, no previous reports have described the use of a ring external fixator for open tibial shaft fractures in children with ASD. We found that ring external fixation was effective in this case of open tibial shaft fracture in a boy with ASD. In addition, when osteosynthesis is performed with sufficient strength, primary closure of the open wound may be safe for low-grade open fractures such as Gustilo classification type 1.

Tibial fractures are among the most common pediatric long-bone fractures, but no conclusive evidence or best practice guidelines have been described for their management. Pediatric tibial fractures have generally been treated non-surgically with reduction, casting and immobilization. However, surgical treatment is recommended in various cases such as open fracture [3,4]. Surgical stabilization of tibial fractures in the pediatric population requires implants that do not disrupt the open epiphyses. Elastic intramedullary nails, external fixation, and plating are all potential options [4]. Some reports have compared options, but conclusions regarding the superiority or inferiority of methods remain difficult to reach [7].

Two types of external fixator are available: the monolateral external fixator, and the ring external fixator. The monolateral fixator is considered to have the advantage of technically easier application when compared to the ring external fixator, but concerns have been raised regarding an increased risk of loss of reduction [5]. On the other hand, the ring external fixator has a stable structure and

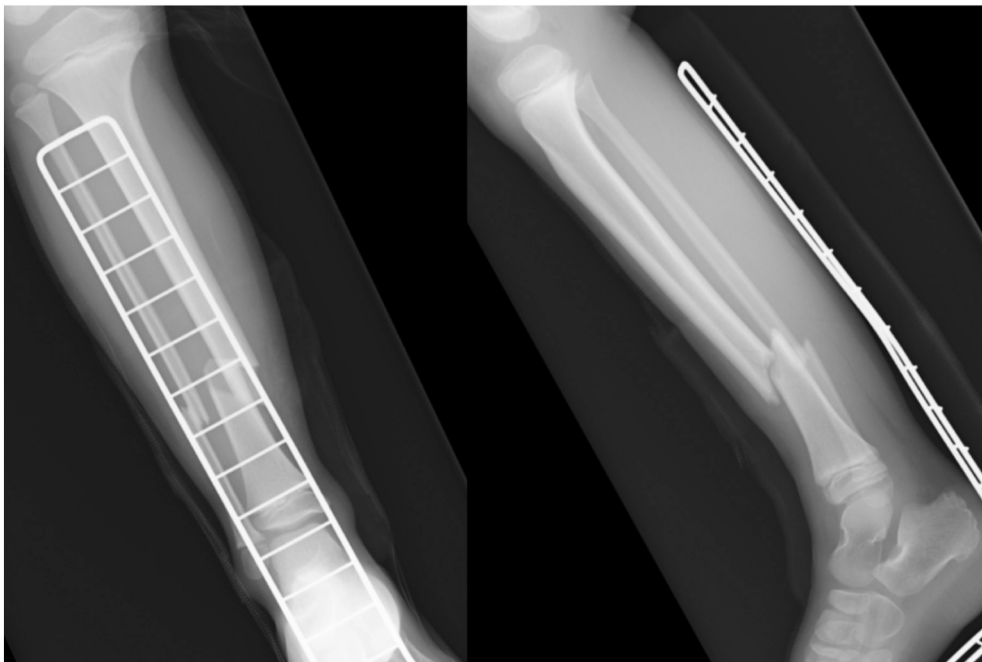
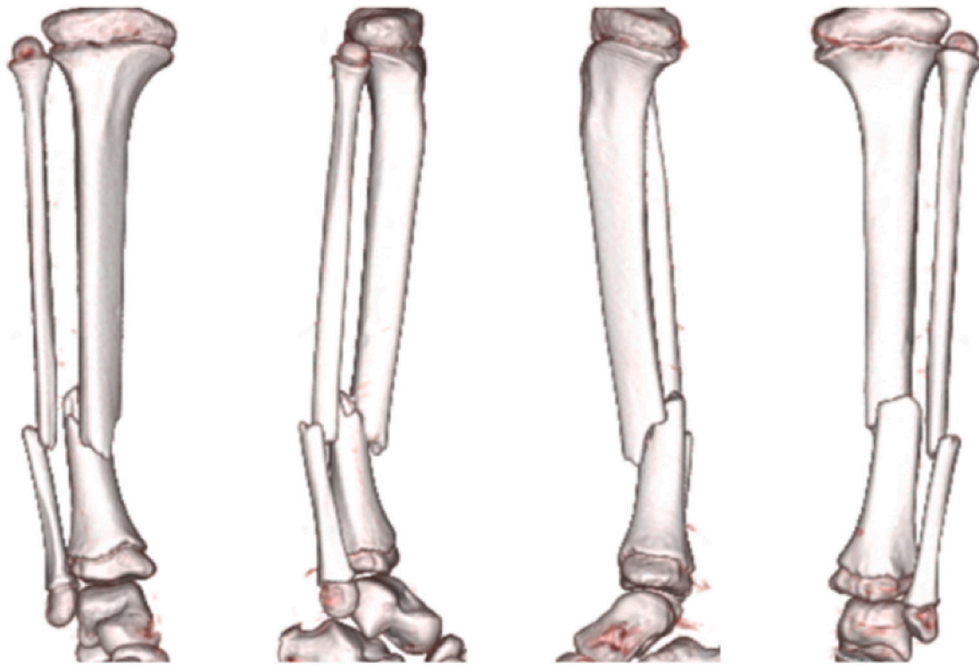



Fig. 1. Radiographs on admission, showing fractures of the tibial and fibular shafts.



**Fig. 2.** Three-dimensional CT on admission, showing spiral fracture of the tibial shaft and simple fracture of the fibular shaft. We diagnosed Orthopaedic Trauma Association classification 42A1, 4F2A.



**Fig. 3.** Postoperative radiographs of the tibial shaft fracture treated using the ring external fixator.

stronger fixing force than the monolateral external fixator, resulting in a lower risk of loss of reduction and the advantage that full weight-bearing can be applied from immediately postoperatively [5,6]. In addition, the ring external fixator offers the advantage of minimizing damage to soft tissues, as the device is fixed with wires. When ring and monolateral external fixators were compared in the treatment of pediatric tibial fractures, a significantly greater proportion of patients with monolateral external fixators experienced a loss of reduction and developed malunion [8]. The use of a ring external fixator for pediatric open tibial shaft fracture appears useful from the perspective of fixation strength and soft-tissue protection.

Since this case involved a simple fracture, we used two rings, fixing each ring with three wires. However, if the fracture is unstable, additional rings or wires should be considered, and fractures near the joint would require fixation bridging the joint.

Pediatric open fractures of the limbs are said to show a lower infection rate than those in adults, due to the generally better production of granulation tissue and abundant blood circulation. Due to this lower infection rate, pediatric open fractures of the tibial

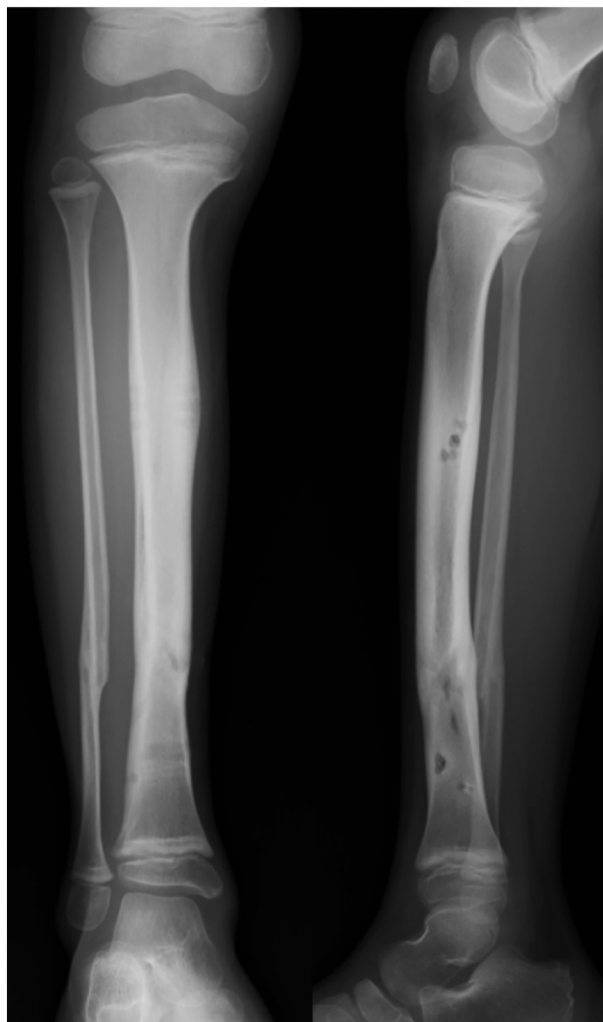


Fig. 4. Radiographs show healing of the fracture at 6 months postoperatively.

shaft are thought to be safe for primary closure of the open wound after debridement if the injury is of lower grade, such as Gustilo classification type 1 [9,10].

In our hospital, patients and their families are instructed to perform pin-site care by thorough showering after surgery, which may have contributed to the successful treatment of pin-site infection in this case.

This case involved a pediatric open tibial shaft fracture in a child with ASD. We determined that surgical treatment was indicated in this case because of the open fracture. As the patient had ASD and maintaining postoperative rest may have been difficult, selection of a treatment method that allowed maximal weight-bearing immediately after surgery was considered helpful. As elastic intramedullary nails require non-weight-bearing for 2–3 weeks and plate fixation was difficult because of the open wound inside the tibia, we used a ring external fixator. In this case, good bone union was considered obtainable based on three factors. First, no loss of reduction was recognized from fixation using the ring external fixator. Second, immediate and full weight-bearing was allowed and circulation around the fracture was maintained. Third, pediatric osteogenic activity is generally extremely high. Regarding the open wound, no significant infection was evident even after primary closure, because the infection rate of open fractures in children is low and the soft tissue around the open wound would be firmly stabilized by the ring external fixator.

### Conclusions

Use of a ring external fixator appears to represent a good option for open tibial shaft fractures of children who may experience difficulty staying calm due to ASD, because bed rest does not need to be maintained after surgery. For pediatric, low-grade open fractures such as Gustilo classification type I, primary closure of the open wound after sufficient bone fixation is safe.

## References

- [1] A.M. Neumeyer, J.A. O'Rourke, A. Massa, et al., Brief report: bone fractures in children and adults with autism spectrum disorders, *J. Autism Dev. Disord.* 45 (3) (2015) 881–887.
- [2] R.A. Vasa, M.O. Mazurek, R. Mahajan, et al., Assessment and treatment of anxiety in youth with autism spectrum disorders, *Pediatrics* 137 (2) (2016) S115–S123.
- [3] H. Aslani, A. Tabrizi, A. Sadighi, et al., Treatment of open pediatric tibial fractures by external fixation versus flexible intramedullary nailing: a comparative study, *Arch. Trauma Res.* 2 (3) (2013) 108–112.
- [4] N.K. Patel, J. Horstman, V. Kuester, et al., Pediatric tibial shaft fractures, *Indian J. Orthop.* 52 (5) (2018) 522–528.
- [5] S. Tafazal, S.S. Madan, F. Ali, et al., Management of paediatric tibial fractures using two types of circular external fixator: Taylor spatial frame and Ilizarov circular fixator, *J. Child. Orthop.* 8 (3) (2014) 273–279.
- [6] K. Nozaka, Y. Shimada, N. Miyakoshi, et al., Pathological fracture of the femur in Alagille syndrome that was treated with low-intensity pulsed ultrasound stimulation and an Ilizarov ring fixator: a case report, *BMC Musculoskelet. Disord.* 15 (2014), 225.
- [7] R.A. Ramasubbu, B.M. Ramasubbu, Surgical stabilization for open tibial fractures in children: external fixation or elastic stable intramedullary nail - which method is optimal? *Indian J. Orthop.* 50 (5) (2016) 455–463.
- [8] M.J. Al-Sayyad, Taylor spatial frame in the treatment of open tibial shaft fractures, *Indian J. Orthop.* 42 (4) (2008) 431–438.
- [9] N.E. Gougoulias, A. Khanna, N. Maffulini, Open tibial fractures. Are children small adults? *Hippokratia* 13 (3) (2009) 147–153.
- [10] A. Irwin, P. Gibson, P. Ashcroft, Open fractures of the tibia in children, *Injury* 26 (1995) 21–24.