



Contents lists available at [ScienceDirect](https://www.sciencedirect.com)

JPRAS Open

journal homepage: [www.elsevier.com/locate/jpra](http://www.elsevier.com/locate/jpra)



## An Extensive Volar Forearm Laceration – The Spaghetti Wrist: A Systematic Review<sup>☆</sup>

Kiron Koshy<sup>a</sup>, Rohan Prakash<sup>b</sup>, Andrzej Luckiewicz<sup>c,\*</sup>,  
Reza Alamouti<sup>d</sup>, Dariush Nikkhah<sup>d</sup>

<sup>a</sup>Brighton and Sussex University Hospitals, Brighton, UK

<sup>b</sup>Royal Free Hospital, Hampstead, UK

<sup>c</sup>University College London, Medical Sciences, University College London, Gower Street, London

<sup>d</sup>Queen Victoria Hospital, East Grinstead, UK

### ARTICLE INFO

#### Article history:

Received 17 April 2018

Accepted 28 June 2018

Available online 11 July 2018

#### Keywords:

Injury

Spaghetti

Systematic

Tendon

Trauma

### ABSTRACT

**Purpose:** ‘Spaghetti wrist’ is an extensive laceration that involves multiple structures in the volar wrist, including tendons, nerves and arteries. This injury is frequently encountered in trauma units, but despite its complex nature, management is often handled by junior surgeons.

Furthermore, the guidance on how to approach these injuries is limited, with a relatively poor evidence base on management and outcomes.

**Methods:** In this article, we perform a systematic review of the literature on the management and outcomes of the spaghetti wrist injury. Patient demographics, definitions of spaghetti wrist, mechanism of injury, operative and rehabilitative techniques and surgical outcomes are discussed.

**Results:** Results from this study show significant physical, functional, psychological and financial impacts of spaghetti wrist injuries. Operative technique appears relatively consistent; even

<sup>☆</sup> Use of figures: We would like to acknowledge Guirgis Award, MSc, MRCS, for his contribution to this study.

\* Corresponding author: Andrzej Luckiewicz, BSc(Hons), University College London, Medical Sciences, University College London, Gower Street, London WC1E6BT, United Kingdom. Phone: 07540824090.

E-mail address: [andrzej.luckiewicz.13@ucl.ac.uk](mailto:andrzej.luckiewicz.13@ucl.ac.uk) (A. Luckiewicz).

<https://doi.org/10.1016/j.jpra.2018.06.003>

2352-5878/© 2018 The Authors. Published by Elsevier Ltd on behalf of British Association of Plastic, Reconstructive and Aesthetic Surgeons. This is an open access article under the CC BY-NC-ND license.

(<http://creativecommons.org/licenses/by-nc-nd/4.0/>)

though reporting of injuries and outcomes was heterogeneous, no current classification system is in common usage.

**Conclusions:** An increased focus on the standardisation of assessment, management and rehabilitation and on overcoming the obstacles to care will serve as a guidance to the operative and post-operative management of the spaghetti wrist injury. The use of a single definition and classification system has been proposed to standardise outcome measures and improve inter-observer reliability.

**Type of study/level of evidence:** Systematic Review: Level IIa evidence

© 2018 The Authors. Published by Elsevier Ltd on behalf of British Association of Plastic, Reconstructive and Aesthetic Surgeons.

This is an open access article under the CC BY-NC-ND license. (<http://creativecommons.org/licenses/by-nc-nd/4.0/>)

## Introduction

The superficial position of flexor tendons, median and ulnar nerves and blood vessels in the volar wrist places them at a high risk of direct injury. This pattern of injury has been coined as ‘spaghetti wrist’ or ‘full-house syndrome’; however, there is no clear consensus on what constitutes a spaghetti wrist injury, with authors defining division of as few as three structures with either tendon, nerve or artery to up to at least 10 structures.<sup>1</sup>

Despite spaghetti wrist injuries being common, only limited literature is available on their classification, intra-operative management and post-operative care. Despite the complex nature of spaghetti wrist injuries, their management is often handled by junior surgeons.

No standardised protocol exists on the assessment of spaghetti wrist injuries and on the reporting of post-operative recovery.

In this study, we have performed a systematic review of the literature regarding the management of spaghetti wrist injuries with the aim of providing a summary of the available literature regarding the management, rehabilitation methods and reported outcome measures of this cohort.

## Methods

### *Literature Search and Data Extraction*

The literature search was carried out between September 2017 and October 2017. The literature search was performed using Embase, MEDLINE, CINAHL, Google Scholar, Cochrane Library and NICE database. Data extracted included patients’ demographics, length of study, authors’ definition of spaghetti wrist, aetiology of injuries, operative techniques, post-operative functional outcomes, complications and rehabilitative methods.

Please see [Appendix A](#) for a list of search terms and further strategy used. Data were not specifically assessed for risk of bias.

Relevant natural language and controlled vocabulary terms were selected and combined. Final result sets were de-duplicated and reviewed for relevance by the searcher, with irrelevant results being discarded. The articles were then screened by title and abstract. The full text of 15 articles was reviewed. A meta-analysis was not carried out due to the heterogeneity of the data.

### *Study selection criteria*

#### *Inclusion criteria*

1. Studies involving patients with volar forearm injuries.

**Table 1**  
Reasons for Exclusion of Studies.

Reference	Reasons for Exclusion
(2)	Studies with a low sample size (n<10).
(3)	Studies that do not report outcome measures relevant to the present study.
(4)	Studies with a low sample size (n<10).
(5)	Studies that do not separate outcomes of non-spaghetti wrist injuries – outcomes reported following further exploratory surgery.
(6)	Studies that do not separate outcomes of non-spaghetti wrist injuries.
(7)	Full paper not available because of delayed release (till 01/12/2017).
(8)	Unable to access full text.

2. Studies involving damage to more than one structure in the forearm.
3. Studies published from 1996 to 2016.
4. Any language text publication.

*Exclusion criteria:*

1. Studies involving non-human participants.
2. Studies that do not include operative management.
3. Studies with a low sample size (n<10).
4. Studies published before 1996 (20 year study range).
5. Studies that do not report outcome measures relevant to the present study.
6. Studies that do not separate outcomes of non-spaghetti wrist injuries.

## Results

### *Search Results*

A total of 32 studies were retrieved through collation of all database searches. Detailed search results are given in [Appendix B](#). Eight studies met the inclusion criteria and were included in the qualitative analysis ([Figure 1](#)). The reasons for the exclusion of full-text abstracts are given in [Table 1](#).

### *Outcome measures*

A full list of outcome measures for the studies included is displayed (Tables 2 to 4).

### *Patient number and demographics*

The total number of patients studied in the reviewed articles was 359.  
The sample size of each included study ranged from 11 to 124.  
The age of patients ranged from 2 to 62 years.

### *Definition of Spaghetti Wrist*

Various definitions of spaghetti wrist have been used in the studies analysed ([Table 5](#)).

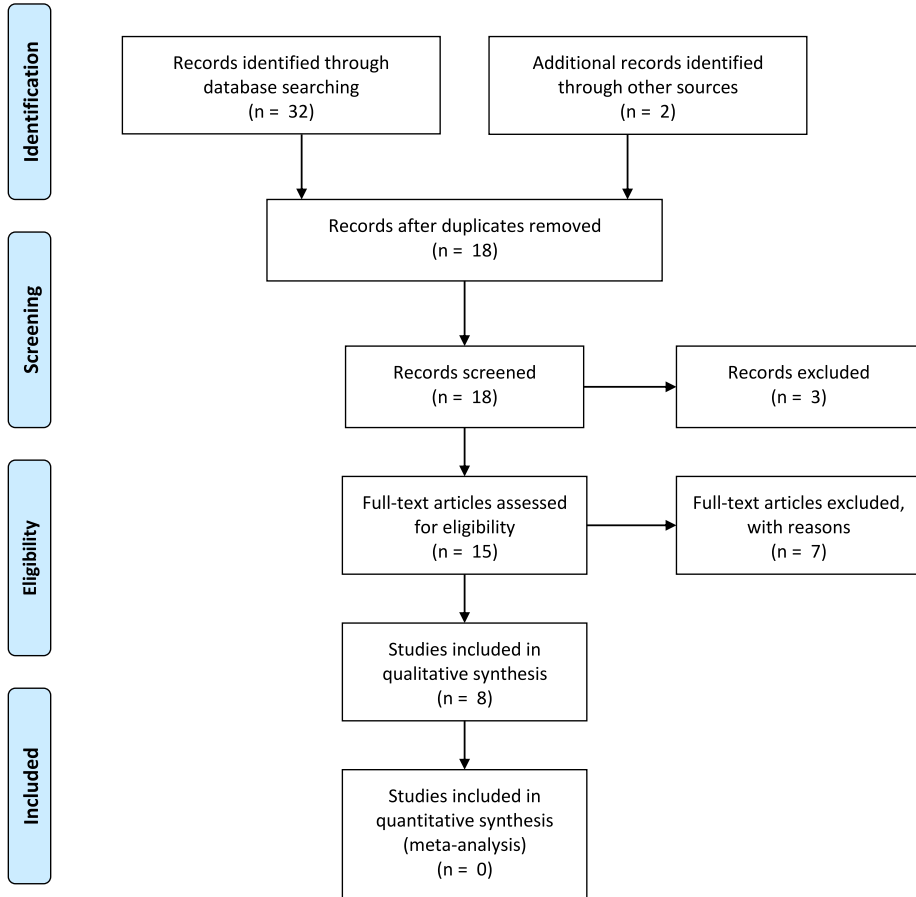
### *Aetiology of Injury*

Various mechanisms of injury were reported. The top three are mentioned below:

1. Accidental<sup>1,9,12,14</sup>
2. Fight/assault<sup>10</sup>
3. Glass injury<sup>1,11,13–15</sup>



## PRISMA 2009 Flow Diagram



From: Moher D, Liberati A, Tetzlaff J, Altman DG, The PRISMA Group (2009). Preferred Reporting Items for Systematic Reviews and Meta-Analyses: The PRISMA Statement. PLoS Med 6(7): e1000097. doi:10.1371/journal.pmed1000097

For more information, visit [www.prisma-statement.org](http://www.prisma-statement.org).

**Figure 1.** PRISMA Flowchart.

### Surgical Procedure

The surgical procedure was outlined in six of the eight studies included in the final analysis.<sup>1,9–11,14,18</sup> The operative technique was not standard, but common themes included identifying and repairing structures from deep to superficial.<sup>1,9,11,14</sup> Structures were identified and tagged<sup>1,9</sup> during

exploration by one author using syringe needles to mark proximal and distal ends.<sup>1</sup> Tendons were repaired before neurovascular structures were repaired.<sup>11</sup> Wrist flexors were repaired with the wrist in flexion.<sup>1</sup>

### Rehabilitative Methods

Rehabilitative methods were detailed in six studies.<sup>1,9–11,14,18</sup> The hand was most often stabilised using a dorsal splint with wrist at approximately 30° of flexion and the metacarpophalangeal joints (MCPJs) at 40–60° of flexion, with interphalangeal joints at the neutral position.<sup>1,9–11,14</sup> Mafi et al., however, kept the wrist stabilised with the splint at 15° of flexion and the MCPJs at 20° of flexion.<sup>18</sup>

The wrist was generally kept immobile for the first 3 days,<sup>9,10</sup> with one study commencing motion from day 2.<sup>18</sup> However, all authors advocated active finger extension and passive flexion from 0 to 4 weeks.<sup>1,9–11,14,18</sup> Passive traction was used on day 3.<sup>9</sup>

At 4–6 weeks, the wrist was kept in an approximately neutral position<sup>17</sup> with MCPJs at 40° of flexion. Other authors advocated removing the splint at 4–6 weeks.<sup>1,11,14</sup> General rehabilitation most commonly included early protective motion from 4 to 6 weeks.<sup>1,11,14</sup> From 6 to 8 weeks, tendon gliding exercises were recommended,<sup>1</sup> with active movements encouraged on cast removal (1 and 10). From 8 weeks, blocking and light resistance exercises were encouraged, with prohibition of full resistance.<sup>1,11,14</sup> Normal activity was generally advised at 12 weeks.<sup>1,11,14</sup>

### Follow-up

Follow-up ranged from 6 months<sup>10</sup> to 10 years<sup>13</sup> following the initial injury.

### Reported Outcome measures

Results are summarised in [Tables 2–4](#)

Functional outcome measures:

- Range of motion (El-Lamie et al. 2006).<sup>1,9–11,14,15</sup>
- Sensation by two-point discrimination (S2PD)<sup>1,9–11,14,15</sup> measurements; Bell-Krotoski method<sup>13</sup> described in.<sup>19</sup>
- Motor Function – Medical Research Council (MRC) grading system;<sup>10,12,13</sup> manual muscle strength tests;<sup>9,13</sup> grip and tip strength;<sup>13,14</sup> fingertip-to-distal palm crease distance;<sup>15</sup> Lister's technique,<sup>12,14</sup> described in.<sup>20</sup>
- Vascular function – Allen's test.<sup>14</sup>

### Patient-Reported Outcome Measures (PROMs)

- Patient-reported outcome measures (PROMs) – Mean functional symptom score;<sup>13</sup> Disabilities of the Arm, Shoulder and Hand questionnaire (DASH) 2.0;<sup>13,14</sup> Impact of event scale;<sup>13</sup> Return to work time.<sup>13</sup>

### Functional Impairment

#### Range of motion

Range of motion was a commonly used outcome measure. Studies rated results as 'excellent' to 'poor'.

Range of motion was reported as excellent in 20%<sup>11</sup> to 100%<sup>9</sup> of patients.

#### Motor Function

All the studies included reported on motor function, but this was assessed through a variety of outcome measures. Results were, however, also usually rated as 'excellent' to 'poor'. Excellent functional results were found in 46%<sup>10</sup> to 58% of patients.<sup>12</sup> Poor results were found in 10% to 15%<sup>10</sup> and to 39%<sup>12</sup> of patients.

**Table 2**  
Patient factors.

Reference	Patient number and age range	Definition	Aetiology and geographical region	Operative technique
(9)	11 patients (pts) over a 2 year period	At least one nerve and five tendons damaged.	Accidental glass injury most common. No suicide attempts.	Ends of tendons and nerves tagged. Repair of tendons ranging from deep to superficial.
(10)	Age range 22-54 33 pts	Injury between the distal wrist crease and the flexor musculotendinous junctions involving at least three completely transected structures, including at least one nerve and often a vessel.	Egypt 23 – fights and broken glass (2 – razor and rest through fighting)	All injured structures simultaneously repaired. Tourniquet in 4 out of 33 pts. Tendons: modified Kessler technique. Epitenon – Wrist in 20-30° of flexion, fingers in 60-70° of flexion
(11)	Average age 24.5 (18-39)  60 pts	Injury between distal wrist crease and flexor musculocutaneous tendon junctions. At least three completely transected structures, including a nerve and often a vessel.	10 – Work and home accidents Turkey Glass lacerations (61.0%), knife wounds (23.7%) and suicide attempts (8.5%)	Deep to superficial structures identified; proximal and distal ends tagged with sutures; Finger flexor tendons repaired using 4 nylon sutures of 4 Ticron, using the figure of 8 technique or modified Kessler technique. Thereafter, neurovascular structures repaired under microscope. Final structures of wrist flexures to be repaired, with wrist in flexion.
(12)	Age range 5-54 18 pts over a 6-year period	Volar laceration of the forearm between the flexor musculotendinous junction and distal wrist crease, involving a major nerve and a total of at least three structures.	Chicago, USA Injuries were self-inflicted in 22% (n=4), related to assault in 28% (n=5) or accidental/work related in 50% (n=9).	Not detailed
(13)	Age range 14-54 50 completed questionnaires and	Injury at the wrist level located between the distal wrist crease	San Francisco Glass 32 (64%)	Not reported

(continued on next page)

**Table 2** (continued)

Reference	Patient number and age range	Definition	Aetiology and geographical region	Operative technique
(1)	43 attended follow-up reviews	and the flexor musculotendinous junctions with	Knife 7 (14%)	
	Age 8-58	(1) simultaneous laceration of both the median and ulnar nerves with flexor tendons at the wrist and/or	Other 11 (22%)	
	Mean 29.1	(2) at least 10 divided structures including the median and/or ulnar nerve.	Erasmus Medical Center, University	
	Follow-up average 10 years (2-18 years)		Medical Center Rotterdam, Netherlands	
	42 pts,	Lacerations occurring between the distal wrist crease and the flexor musculotendinous junctions involving at least three completely transected structures, including at least a nerve and often a vessel.	Accidental glass lacerations (55%), knife wounds (24%) and electrical saw injuries (11%).	Structures are identified from deep to superficial, and a checklist of lacerated structures
	38 pts followed up after an average of 46 months.		Egypt	is recorded. The proximal and distal ends of the injured structures are marked and caught by syringe needles as they are identified. Finger flexor tendons are repaired in a deep-to-superficial
	Age range 2-40			fashion with 4-0 ETHIBOND sutures, by the modified Kessler technique and reinforced with either a 6-0 Prolene or 6-0 nylon continuous epitendinous sutures. Neurovascular structures are then repaired under an operating microscope, using either 9-0 or 10-0 nylon interrupted sutures in an epineural

(continued on next page)

**Table 2** (continued)

Reference	Patient number and age range	Definition	Aetiology and geographical region	Operative technique
(14)	21 pts  Mean follow-up 6.4 years.	Volar wrist laceration in which at least 10 structures, inclusive of tendons, at least one major nerve and usually one major vessel are divided.	Hitting a window while drunk (nine cases), hitting the window after losing their temper (five cases), knife cuts (four cases) and accidental glass cuts (three cases).  Turkey	fashion (Fig. 5). Wrist flexors are the final structures to be re-approximated and should be repaired with the wrist in significant flexion using 3-0 ETHIBOND sutures by the modified Kessler technique. The nerves were repaired by group fascicular repair under an operating microscope by the epineural suture technique with either 7-0 or 8-0 nylon sutures. The vessels were repaired using loupe magnification with 7-0 sutures. Ligation was performed in one case because of considerable contusion of two radial arteries and three ulnar arteries. The quality of the repair was assessed subjectively by the absence of tension on the suture line. Deep-to-superficial finger flexor tendons were repaired, and the wrist flexors were repaired using the modified Kessler technique with 4/0 braided polyester and reinforced with a 6-0 nylon continuous epitendinous suture.

(continued on next page)



**Table 2** (continued)

Reference	Patient number and age range	Definition	Aetiology and geographical region	Operative technique
(15)	Age range 16-42 124 pts. 115 men and 9 women.  Mean age 24.5, Age range 8-62 years.  30 pts followed up for 1-3 years. Right hand injured in 75% and left in 25%.	Sharp lacerations between the distal wrist crease and the flexor musculotendinous junction.  From structures in the wrist, at least 10 are injured completely, including a major nerve.	Glass laceration 81 (65.3%), knife wounds 21 (16.2%) and other 22 (17.7%).  15th Khordad Hospital, Tehran, Iran	After appropriate anaesthesia and use of tourniquet, the wounds were extended in longitudinal and transverse directions. The structures were explored. The disrupted tendons were repaired with 4/0 nylon sutures by the modified Kessler method. The disrupted nerves and arteries were repaired with 8/0 nylon sutures under loupe magnification. Ligation of 12 ulnar and 15 radial arteries was done due to severe injury in other centres.

**Table 3**  
Outcomes of the studies included in the analysis.

Reference	Outcome measure	Outcomes
	Range of motion, protective sensation, two-point discrimination and grip strength.	Range of motion of involved digits and wrist was excellent in all pts. Two-point discrimination was 5–8 mm in all median nerve injury pts. 1 of 4 ulnar injuries showed 5–10 mm response. Intrinsic muscle recovery was prolonged in ulnar injury.
(10)	Power MRC, range of movement Sensory – Pinprick, light touch, two-point discrimination and light touch.	Functional results were excellent in 46% of fingers, good in 22%, fair in 17% and poor in 15% in pts with fight-related injuries. The functional results were excellent in 55% of fingers, good in 17%, fair in 18% and poor in 10% of pts with accident-related injuries. The finger-to-palm distance was 2 cm in 5 pts, 1 cm in 16 pts and 0 in 12 pts. In 24 cases, full wrist flexion was achieved. In 4 pts, there was a loss of 15–20° of flexion. In 16 of the 22 cases with a repaired ulnar nerve, two-point discrimination and touching and pain sensation returned. Except for 3 pts who developed cold intolerance, the vascular condition was determined to be normal in all pts. Twenty of 35 repaired arteries reached the same function of the healthy hand, according to the Allen's test.
(11)	Intrinsic muscle recovery, sensation and range of motion.	Flexor tendon function (Kleinert)
		ROM was excellent in 12 pts and good in 7 pts Sensation – 7 pts for protective sensation and five pts 7–12 mm for S2PD
(12)	Sensory + motor outcomes.	Tendon outcomes were excellent in 58%; fair in 3% and poor in 39%. Sensory recovery was excellent in 11%; good in 33% and poor in 56%. Motor recovery was excellent in 11%; good in 22% and poor in 67%.
(13)	Questionnaire. Mean Functional Symptom Score Return to work time Mean Impact of Event score	Mean grip strength definition 1: 26/100; definition 2: 20.7/100. Mean pinch strength Definition 1: 36.9; definition 2: 30.5. Mean Functional Symptom Score – 15.1 after a mean follow-up of 10 years.
	Manual Muscle Strength Tests – MRC	93.5% took sick leave, with a mean of 34.7 weeks. 45.2% did not return to work within 1 year.
	Sensation – Bell-Krotoski <sup>1,2</sup> Grip and tip strength <sup>3,4</sup> (16)	1 month post-operatively, mean Impact of Event score – 26.2. 10 years after the trauma – 7.3
(1)	Tendon function, opposition, intrinsic function, deformity and sensation.	Sensory recovery definition 1: 3.8/10. Definition 2: 3.2/10. Range of motion of all involved digits was excellent in 34 pts, good in 3 pts and poor in one pt. Opposition was excellent in 31 pts, good in five pts and poor in two pts. Intrinsic muscle recovery was excellent in 29 pts, good in seven pts and fair to poor in two pts. Sensory recovery was excellent in 32 pts, good in five pts and fair in one pt.
(14)	Flexion/extension deficits, range of motion, Grip strength, sensation, Allen's test for vessels, DASH questionnaire and Ability to return to work.	Lister classification – excellent tendon results in 48% and poor in 12%. 18/21 cases <20% decrease in strength compared to contralateral arm. 1/21 >50% decrease in strength. Mean DASH score 12.57 points (range 2.4–34.8 points). 19/21 pts were able to return to former work. 2/21 pts had to change to relatively easier jobs.
(15)	ROM, Motor function – 85% of tendon function or distance from fingertip to distal palmar crease <1 cm.	30 pts were followed up.  Motion in wrist and fingers was excellent in 14 pts, good in 8 pts and fair in 5 pts, and fixed contracture was observed in 3 cases. Recovery in intrinsic muscle function was good in 9 pts. In 21 pts, recovery of intrinsic muscle function was fair to poor.

**Table 4**

Outcomes of the studies included in the analysis continued.

Reference	Rehabilitative methods	Complications
(14)	The whole hand including the digits was put into a bulky dressing, and a dorsal splint was applied to keep the wrist in 30° of flexion, the metacarpophalangeal (MCP) joints in 70° of flexion and the interphalangeal joints (IPJs) in the neutral position. Passive flexion active extension using rubber band traction was started at day 3. This position was kept for 4 weeks, and the splint was never removed during this period. At 4–6 weeks, the splint was changed with another one maintaining the wrist in neutral to 10° of flexion and the MCP joints in 40° of flexion, and the same programme of rubber band traction was continued with a wider range of movement.	No complications reported.
(10)	First 3 days, immobile. 3–28 days, passive flexion and active extension. At 28 days, active controlled flexion and passive controlled extension. At 6 weeks, passive extension for wrist and fingers with active movements on removing cast. At 8 weeks, strengthening exercises started.	3 pts developed cold intolerance.
(11)	Dorsal dynamic clamdigger splint wrist in 20–45° of flexion, MCP joints in 40–60° of flexion and IPJs allowed full extension. 0–4 weeks, active extension and passive finger flexion. 4–6 weeks, protective early motion, and flexion bands were removed. 6–8 weeks, splint removed. At 8 weeks, light resistance exercises. At 12 weeks, normal activity.	1 pt – neuroma of median nerve that had excision and sural nerve graft.  1 pt – neurolysis of the median nerve.
(12)	Not detailed.	No complications reported.
(13)	Not reported.	7 pts – anaesthetic hands.
(1)	After surgery, a dynamic dorsal splint is placed in pts with the wrist in 20–45° of flexion, the MCP joints in 40–60° of flexion, and the IPJs are allowed full extension at 0–4 weeks and active extension and passive finger flexion are performed. At 4–6 weeks, the splint is removed, and the pt begins protective early motion. At 6–8 weeks, tendon gliding exercises are initiated, and light activity of daily living exercises is encouraged. At 8 weeks, blocking and light resistance exercises begin; full resistance is prohibited. At 12 weeks, there is return to full activity.	4 pts – minor deformity (partial clawing). 1 pt – major deformity (total clawing).
(14)	Following surgery, the wrist was immobilised in 20–30° of flexion in a dynamic posterior plaster splint for 3 weeks. The wrist was then gradually neutralised with a thermoplastic splint over an average of 6 weeks. Post-operatively, in the first 4 weeks, active extension and passive finger flexion were carried out. At 4–6 weeks, the pt began protective early motion (progressive active flexion) while continuing the passive mobilisation regimen. The flexion bands were then removed; however, the splints were left. At week 8, blocking and light resistance exercises were begun, although full resistance was prohibited. At this time, a slight load was permitted, increasing to a full load within 10–12 weeks post-operatively.	1 pt – developed a median nerve neuroma.
(15)	After surgery, the hands and wrists had been splinted dorsally with 15° of wrist flexion, MCP joints with 20° of flexion and fingers in full extension. The splint was used for 45 days. The motion of fingers began on the second post-operative day with passive flexion and active extension.	Not reported.

### *Sensory function*

Two-point discrimination ranged from 100%<sup>17</sup> to 3%.<sup>11</sup> Sensory function assessed by the Bell-Krotoski method reported normal function in 0% of patients, with completely anaesthetic hands reported in 18.2% to 13.6% of patients depending on the definition of spaghetti wrist used.<sup>13</sup>

### *Patient-reported outcomes*

Three studies featured patient-reported outcomes.<sup>13,14,21</sup> One study found a mean functional symptom score of 15.1 after a mean follow-up of 10 years.<sup>13</sup> The patients took, on average, 34.7 weeks of sick leave, and 45.2% of patients did not return to work within 1 year. Furthermore, patients displayed a long-lasting, high-impact impairment with performance of daily living activities.<sup>13</sup>

Another study found a mean DASH function/symptom score of 12.57 points (range 2.4–34.8 points) (0 points representing the best possible result and 100 points representing the worst possible result).<sup>14</sup>

### *Return to work*

There is a large variation in the literature with regard to the time taken to return to work. One study found an 87.5% return to work rate.<sup>22</sup> Kabak et al. found 19 of 21 patients were able to return to former work. The remaining two patients were able to change work to physically more manageable jobs.<sup>14</sup> However, Taha and Taha reported a 0% return to work rate,<sup>21</sup> and findings from a larger study of 67 patients reported that 45.2% of patients did not return to work within 1 year.<sup>13</sup>

### *Psychological Impact*

Vaughn et al. conducted a retrospective cohort study on patient demographics and outcomes of spaghetti wrist injuries treated at San Francisco General Hospital.<sup>12</sup> Neither the operative technique nor the rehabilitative method was specifically described. This study found that 39% of patients with spaghetti wrist had a psychiatric diagnosis, most commonly depression.

### *Complications*

Neuroma was the most commonly cited complication;<sup>11,14</sup> Weinzwig also reported neurolysis of the median nerve.<sup>11</sup> Other complications were also described, such as major deformity of the hand due to clawing,<sup>1</sup> anaesthetic hands<sup>13</sup> and cold intolerance of the hand,<sup>10</sup> but these may be due to neurovascular injury resulting from the initial injury rather than complications during or after surgery.

## **Discussion**

Whilst there have been a number of studies that have examined the management and outcome of spaghetti wrist injuries,<sup>1,8,11,14</sup> only a small number of the studies included adequate sample sizes and assessed long-term outcomes.<sup>13</sup>

### *Operative Technique*

Six of the eight studies included reports on operative technique. Common features include systematic identification and tagging of damaged structures and the repair of damaged structures ranging from deep to superficial. The modified Kessler technique was used for the repair of tendons.<sup>1,10,11,14,15</sup>

No studies to date have been conducted comparing outcomes of different techniques used to repair spaghetti wrist injuries. This could be partly attributed to the lack of a unified definition or classification system of spaghetti wrist injuries.

Time to theatre is an important issue. In one study, 72% of patients underwent operation on the same day for the repair of damaged structures. Seventy-nine per cent of patients with arterial injury

**Table 5**  
Definitions of Spaghetti Wrist.

Definition	Reference
Three completely transected structures, tendon, nerve or vessel.	(15)
At least three completely transected structures, including at least a nerve and often a vessel.	(1, 10–12)
At least one nerve and five tendons damaged.	(17)
At least 10 structures are divided inclusive of tendons; at least one major nerve and usually one major vessel.	(14)
At least 10 divided structures.	(13)
Simultaneous laceration of both the median and ulnar nerves with flexor tendons at the wrist.	(13)

were operated on within 24 hours and the remaining within 48 hours.<sup>13</sup> Arterial injuries can be catastrophic; therefore, the patient should be taken to the theatre as an emergency. The criteria given in BOAST6 guidelines on vascular injuries comment as follows:

‘The limb must be revascularised as a surgical emergency. Beyond 3–4 hours, warm ischaemia results in irreversible tissue damage and an increasing risk of amputation. Risks of delayed revascularisation include myoglobinuria and may be associated with increased mortality’.<sup>23</sup>

Vascular injuries can be difficult to improve. However, with extensive hand injuries such as the spaghetti wrist, the chances of improvement are much greater. Therefore, all extensive injuries of the hand should be treated with extreme caution and a low threshold given to operate as a matter of emergency.

#### Definition

As shown in this study, several definitions for spaghetti wrist have been used in the literature. The term ‘spaghetti wrist’ was originally coined by Puckett and Meyer and denoted a forearm volar laceration in which three or more structures were severed.<sup>24</sup> Katz defined a spaghetti wrist as a laceration in which 10 or more structures were damaged.<sup>25</sup> Various other definitions have been used, thus leading to some ambiguity in the literature as to what constitutes a spaghetti wrist injury. Any attempt at comparison between results and standardisation of management is also, therefore, made more difficult. In this study, we have sought to bring together the various definitions that have been used (Table 5).

The lack of a unified definition is highlighted by Jacquet et al. who used two definitions in their study:<sup>16</sup>

1. Simultaneous laceration of both the median and ulnar nerves with flexor tendons at the wrist and/or
2. At least 10 divided structures including the median and/or ulnar nerves.

The implication is that the distinction between a volar forearm laceration and a spaghetti wrist injury lies in the level of severity. To avoid confusion and enable a meaningful comparison of outcomes of such injuries, a classification system based on severity is required. One such classification system has been proposed (Table 6).<sup>26</sup> Using this classification system will provide some consistency in reporting. Furthermore, additional research can be carried out to prognosticate injury types and better refine management on the basis of the severity of injury. Regardless of the definition used and severity of the injury, the overall systematic approach to the management of volar forearm lacerations remains essential.

#### Outcomes

Authors have mainly used objective outcomes to assess endpoints in these injuries with motor function, sensory function and range of motion being the most commonly used outcome measures. However, there is a considerable variation in the methods used to assess these endpoints. The MRC grading system,<sup>10,12,13</sup> manual muscle strength tests<sup>9,13</sup> and grip and tip strength<sup>13,14</sup> are examples

**Table 6**

Classification system for Spaghetti Wrist.

		Grade 1	Grade 2	Grade 3
Lacerated Structures	No. of Volar Structures	≤5	6-9	≥10
	Nerve*	Ulnar or Median	Ulnar and/or Median	Ulnar and/or Median
	Artery**	Ulnar or Radial	Ulnar and/or Radial	Ulnar and/or Radial
	Flexor tendons	≤3	4-7	≥8
	Extensor Tendons***	- or +	- or +	- or +
	Bones***	- or +	- or +	- or +
Type of Laceration	A1: Sharp	A1	A1	A1
	A2: Crush/avulsive	A2	A2	A2
	A3: Infected	A3	A3	A3
Type of Repair****	B1: Primary	B1	B1	B1
	B2: Delayed primary	B2	B2	B2
	B3: Secondary	B3	B3	B3

\*specify laceration of cutaneous nerves; \*\*specify laceration of major veins; \*\*\*specify number of tendons and bones; \*\*\*\*specify timing of repair of each structure. Table modified from (26).

of tests used to assess motor function post-operatively. The simplicity and widespread use of MRC power grading across specialties make this an attractive option for studies that compare outcomes post spaghetti wrist repair. In the studies to date, excellent motor outcomes have been achieved in 46%<sup>10</sup> to 58%<sup>12</sup> of patients.

Sensory function was most commonly tested using two-point discrimination tests.<sup>1,9–11,14,15</sup> One of the benefits of this method lies in the assignment of a numerical value to quantify sensation, which allows direct comparison among patients and across studies.

Complications were inconsistently reported. Complications reported ranged from neuromas to anaesthetic hands; however, the latter could be interpreted as a result of the original injury, rather than from surgery. Nerve injury was the most commonly reported complication. Division of the median or ulnar nerve can be a devastating injury, and it is important to follow a disciplined routine for surgical repair. Neuroma in continuity is a consequence when a repair is performed incorrectly or under tension.<sup>5</sup> Yuksel and colleagues described the secondary exploration of 28 patients with spaghetti wrist injuries. Their study included patients with anaesthetic or partially anaesthetic hands, who had been referred from another unit. The authors noted that 18 nerves had neuroma-in-continuity at repair sites, and in five patients, the median nerve was not repaired to its original proximal and distal stump. The unintended false connections between the structures in the wrist can have catastrophic consequences. Incorrect connections between the tendons in the wrist cause less significant problems, and therefore, knowledge of the cross-sectional anatomy of the wrist and forearm is essential.

Perhaps, the most important are the PROMs. However, only three of the studies analysed reported on PROMs. PROMs that have been used include mean functional symptom score,<sup>13</sup> DASH 2.0,<sup>13,14</sup> impact of event scale<sup>13</sup> and return to work time.<sup>13</sup> Using a standardised and widely accepted tool such as DASH 2.0 will enable meaningful comparisons to be made. In future studies, a greater focus must also be placed on PROMs alongside objective outcome measures, as patient satisfaction and hand functionality are the priorities for the surgeon rather than objective motor and sensory outcomes.

One cannot ignore the functional and psychological components of these injuries, which have been previously reported in hand trauma.<sup>27</sup> One month post-operatively, the mean score on the Impact of Event Scale was 26.2, which raises a clinical concern of post-traumatic stress disorder.<sup>13</sup> Sixty-four per cent of patients experienced moderate-to-severe psychological impact at this point.

At an average follow-up of 10 years after the trauma, this score was 7.3. This reduction is likely to be a combination of the surgical procedure and appropriate rehabilitation. An important consideration is also the pre-injury psychological state of these patients. This is important because a suicide attempt is a common cause of spaghetti wrist. One study found that 39% of the patients investigated had a psychiatric diagnosis before admission.<sup>12</sup> These patient factors are important in the long-term management of these patients. Other factors that have been identified as obstacles to the care of spaghetti wrist patients include socioeconomic limitations, poor patient compliance and irregular follow-up.<sup>12</sup>

### *Post-operative rehabilitation*

Post-operative rehabilitation methods used were largely similar between studies.

However, some contention exists in the literature. Mobilisation remains a topic of discussion, as conflicting guidance suggests that tendon injuries require early mobilisation, whereas nerve injuries benefit from a period of immobilisation.<sup>28</sup>

The initial passive flexion with active extension technique, which is a commonly used method, uses stabilisation. This is parallel to previously used techniques such as Kleinert's early mobilisation,<sup>29,30</sup> but active flexion and active extension techniques have also been used.<sup>31</sup> Scar massage and sensory re-education are also performed in cases of major nerve injury.

Other authors<sup>24</sup> have described protective mobilisation with rubber band traction, with decreasing amounts of fixed flexion over time.<sup>17</sup> However, this is not routinely performed due to the risk of flexion contractures. The time of splint removal is another contentious issue, with some studies using protective early motion at 4–6 weeks.<sup>31</sup>

The importance of accurate repair and robust rehabilitation plans are highlighted in the great cost of rehabilitation and length of time required to return to work after these injuries. Rosberg et al. analysed the costs of treatment in median and ulnar nerve injuries and found that costs were higher with concomitant tendon injuries.<sup>32</sup> These costs are also seen in terms of employment.

Research has found a mean length of sick leave of 34.7 weeks.<sup>13</sup> A supporting study identified that only 59% of patients returned to work after peripheral nerve injury, and this figure was considerably low in combined injuries to median and ulnar nerves.<sup>33</sup>

### *Limitations*

A limitation of this study is that risk of bias was not specifically assessed for in the data analysis. Meta-analysis was also not possible because of the heterogeneity of the data.

### **Summary**

The definitions of spaghetti wrist vary greatly in the literature, and the scientific and surgical community would benefit greatly from a single definition, or a classification system such as the system adapted in this article. Reporting also varies greatly in surgical technique, outcomes and post-operative rehabilitation.

The spaghetti wrist can have devastating impacts on the physical, functional, and psychological health of patients and brings a great cost to employers and health care systems. An increased focus on the standardisation of assessment, management and rehabilitation and on overcoming the obstacles to care will help to decrease this burden.

### **Conflict of interest**

None

### **Funding**

None

### **Acknowledgements**

Evidence search: Management of spaghetti wrist injuries. Tom Roper. (24 October 2016). BRIGHTON, UK: Brighton and Sussex Library and Knowledge Service.

## Appendices

### Appendix A. Search strategy and search terms

Relevant natural language and controlled vocabulary terms were selected and combined. Final result sets were de-duplicated and reviewed for relevance by the searcher, with irrelevant results being discarded. Additional search strings of (volar ADJ2 wrist) ADJ2 lacerat\* and (volar ADJ2 wrist) ADJ2 injur\* were tried, but no new material was found. The strategy used for the Cochrane databases was as follows: #1 spaghetti near/1 wrist:ti,ab,kw (word variations have been searched) #2 'full house' near/1 wrist #3 (volar or forearm or 'zone V') near/1 (laceration\$ or injur\*) #4 #1 or #2 or #3. In addition to conventional database searches, prospective citation searching with Google Scholar was conducted for the most relevant papers.

### Appendix B. Evidence search results and handling

MEDLINE retrieved 15 results; Embase: 12; Google Scholar: 2; NICE evidence search: 1; Cochrane Library: 0; CINAHL: 0; Other sources: 2. Following de-duplication, 18 results remained. The articles were then screened by title and abstract, and three articles were excluded as they were outside the study range (exclusion criteria 4). The full text of 15 articles was reviewed.

### Appendix C. PRISMA Checklist



#### PRISMA 2009 Checklist

Section/topic	#	Checklist item	Report on page
<b>TITLE</b>			
Title	1	Identify the report as a systematic review, meta-analysis, or both.	1
<b>ABSTRACT</b>			
Structured summary	2	Provide a structured summary including, as applicable: background; objectives; data sources; study eligibility criteria, participants, and interventions; study appraisal and synthesis methods; results; limitations; conclusions and implications of key findings; systematic review registration number.	2
<b>INTRODUCTION</b>			
Rationale	3	Describe the rationale for the review in the context of what is already known.	4
Objectives	4	Provide an explicit statement of questions being addressed with reference to participants, interventions, comparisons, outcomes, and study design (PICOS).	4
<b>METHODS</b>			
Protocol and registration	5	Indicate if a review protocol exists, if and where it can be accessed (e.g., Web address), and, if available, provide registration information including registration number.	4
Eligibility criteria	6	Specify study characteristics (e.g., PICOS, length of follow-up) and report characteristics (e.g., years considered, language, publication status) used as criteria for eligibility, giving rationale.	5
Information sources	7	Describe all information sources (e.g., databases with dates of coverage, contact with study authors to identify additional studies) in the search and date last searched.	4, 5
Search	8	Present full electronic search strategy for at least one database, including any limits used, such that it could be repeated.	26
Study selection	9	State the process for selecting studies (i.e., screening, eligibility, included in systematic review, and, if applicable, included in the meta-analysis).	26
Data collection process	10	Describe method of data extraction from reports (e.g., piloted forms, independently, in duplicate) and any processes for obtaining and confirming data from investigators.	4, 5
Data items	11	List and define all variables for which data were sought (e.g., PICOS, funding sources) and any assumptions and simplifications made.	4, 5
Risk of bias in individual studies	12	Describe methods used for assessing risk of bias of individual studies (including specification of whether this was done at the study or outcome level), and how this information is to be used in any data synthesis.	4, 23
Summary measures	13	State the principal summary measures (e.g., risk ratio, difference in means).	4
Synthesis of results	14	Describe the methods of handling data and combining results of studies, if done, including measures of consistency (e.g., I <sup>2</sup> ) for each meta-analysis.	5

## References

- Noaman HH. Management and functional outcomes of combined injuries of flexor tendons, nerves, and vessels at the wrist. *Microsurgery*. 2007;27(6):536–543.



2. Bauer S, Savundra J. Temporary arterial stenting in a full-house spaghetti wrist injury in a remote rural setting: benefit for hand perfusion or risk of increased morbidity. *BMJ Case Rep.* 2013;2013.
3. Xu G, Lai-jin L. Coverage of skin defects in spaghetti wrist trauma: application of the reverse posterior interosseous flap and its anatomy. *J Trauma.* 2007;63(2):402–404.
4. Matsunaga T, Saitoh S, Tanikawa H, Hayashi M, Ohira M, Kimura T. Deep cutting injury from the edges of a snowboard. *Br J Sports Med.* 2004;38(1):80–83.
5. Yuksel F, Peker F, Acikel C, Cellkoz B. Secondhand management of "spaghetti wrist": do not hesitate to explore. *Annals of plastic surgery.* 2002;49(5):500–504 discussion 4–5.
6. Yii NW, Urban M, Elliot D. A prospective study of flexor tendon repair in zone 5. *J Hand Surg Br.* 1998;23(5):642–648.
7. Yazdanshenas H, Naeeni AF, Ashouri A, Washington ER, Shamie AN, Azari K. Treatment and Postsurgery Functional Outcome of Spaghetti Wrist. *J Hand Microsurg.* 2016;8(3):127–133.
8. Bukhari AJ, Saleem M, Bhutta AR, Khan AZ, Abid KJ. Spaghetti wrist: management and outcome. *J Coll Physicians Surg Pak.* 2004;14(10):608–611.
9. El-lamie KK YT. Spaghetti Wrist: Good Prognosis with Adequate Surgical Technique and Early Physiotherapy. *Egypt, J Plast Reconstr Surg.* 2010;34(2):161–166.
10. Yildirim A, Nas K. Evaluation of postoperative early mobilization in patients with repaired flexor tendons of the wrist, the spaghetti wrist. *J Back Musculoskelet Rehabil.* 2010;23(4):193–200.
11. Weinzwieg N, Chin G, Mead M, Gonzalez M. "Spaghetti wrist": management and results. *Plast Reconstr Surg.* 1998;102(1):96–102.
12. Vaughn CJ, Raghavan SS, Hansen SL, Terry MJ. Obstacles to the Care of Patients With Multicomponent Volar Wrist Lacerations at a County Hospital. *Ann Plast Surg.* 2016;76 Suppl 3:S238–S240.
13. Jaquet JB, van der Jagt I, Kuypers PD, Schreuders TA, Kalmijn AR, Hovius SE. Spaghetti wrist trauma: functional recovery, return to work, and psychological effects. *Plast Reconstr Surg.* 2005;115(6):1609–1617.
14. Kabak S, Halici M, Baktir A, Turk CY, Avsarogullari L. Results of treatment of the extensive volar wrist lacerations: the spaghetti wrist. *Eur J Emerg Med.* 2002;9(1):71–76.
15. MPB H. Management and results of extensive volar wrist lacerations: "the spaghetti wrist" in 124 patients during a 5 year period in 15th Khordad hospital Tehran. *MJIRI.* 2006;20(1).
16. Mathiowetz V, Weber K, Volland G, Kashman N. Reliability and validity of grip and pinch strength evaluations. *J Hand Surg Am.* 1984;9(2):222–226.
17. El-Lamie K YT. Spaghetti wrist: good prognosis with adequate surgical technique and early physiotherapy. *Egypt, J Plast Reconstr Surg.* 2010;34:161–166.
18. Mafi P BH. Management and Results of Extensive Volar Wrist Lacerations: "The Spaghetti Wrist" in 124 Patients during a 5 year period in 15th Khordad Hospital Tehran. *Med J Islam Repub Iran.* 2006;20(1).
19. Bell-Krotoski J, Weinstein S, Weinstein C. Testing sensibility, including touch-pressure, two-point discrimination, point localization, and vibration. *J Hand Ther.* 1993;6(2):114–123.
20. Lister GD, Kleinert HE, Kutz JE, Atasoy E. Primary flexor tendon repair followed by immediate controlled mobilization. *J Hand Surg Am.* 1977;2(6):441–541.
21. Taha A, Taha J. Results of suture of the radial, median, and ulnar nerves after missile injury below the axilla. *J Trauma.* 1998;45(2):335–339.
22. Rogers GD, Henshall AL, Sach RP, Wallis KA. Simultaneous laceration of the median and ulnar nerves with flexor tendons at the wrist. *J Hand Surg Am.* 1990;15(6):990–995.
23. Boast 6: Management of Arterial Injuries associated with fractures and dislocations: *British orthopaedic association*; 2016 [Available from: <https://www.boa.ac.uk/wp-content/uploads/2014/12/BOAST-6.pdf>].
24. Puckett CL, Meyer VH. Results of treatment of extensive volar wrist lacerations: the spaghetti wrist. *Plastic and reconstructive surgery.* 1985;75(5):714–721.
25. RG K. Discussion. Results of treatment of extensive volar wrist lacerations: the spaghetti wrist. *Plast Reconstr Surg.* 1985;75(720):1.
26. AK-KVNT Ali. Epidemiology and Classification of Extensive Volar Wrist Lacerations: The "Spaghetti Wrist". *Internet j third world med.* 2003;1(2).
27. Haese JB. Psychological aspects of hand injuries. Their treatment and rehabilitation. *J Hand Surg Br.* 1985;10(3):283–287.
28. Lee WP, Constantinescu MA, Butler PE. Effect of early mobilization on healing of nerve repair: histologic observations in a canine model. *Plast Reconstr Surg.* 1999;104(6):1718–1725.
29. Kleinert HE, Meares A. In quest of the solution to severed flexor tendons. *Clin Orthop Relat Res.* 1974(104):23–29.
30. Stefanich RJ, Putnam MD, Peimer CA, Sherwin FS. Flexor tendon lacerations in zone V. *J Hand Surg Am.* 1992;17(2):284–291.
31. Elliot D, Moiemn NS, Flemming AF, Harris SB, Foster AJ. The rupture rate of acute flexor tendon repairs mobilized by the controlled active motion regimen. *J Hand Surg Br.* 1994;19(5):607–612.
32. Rosberg HE, Carlsson KS, Hojgard S, Lindgren B, Lundborg G, Dahlin LB. Injury to the human median and ulnar nerves in the forearm—analysis of costs for treatment and rehabilitation of 69 patients in southern Sweden. *J Hand Surg Br.* 2005;30(1):35–39.
33. Bruyns CN, Jaquet JB, Schreuders TA, Kalmijn S, Kuypers PD, Hovius SE. Predictors for return to work in patients with median and ulnar nerve injuries. *J Hand Surg Am.* 2003;28(1):28–34.