

# Radiographic Factors for Adjacent Vertebral Fractures and Cement Loosening Following Balloon Kyphoplasty in Patients with Osteoporotic Vertebral Fractures

Naosuke Kamei<sup>1)</sup>, Kiyotaka Yamada<sup>2)</sup>, Toshio Nakamae<sup>1)</sup>, Takeshi Hiramatsu<sup>2)</sup>, Takashi Hashimoto<sup>2)</sup>, Toshiaki Maruyama<sup>1)</sup>, Nobuo Adachi<sup>1)</sup> and Yoshinori Fujimoto<sup>2)</sup>

1) Department of Orthopaedic Surgery, Graduate School of Biomedical and Health Sciences, Hiroshima University, Hiroshima, Japan

2) Department of Orthopaedic Surgery, JA Hiroshima General Hospital, Hatsukaichi, Japan

## Abstract:

**Introduction:** Balloon kyphoplasty (BKP) is a minimally invasive surgical approach for the treatment of osteoporotic vertebral fractures (OVF). Some risks have been reported after treatment with BKP; therefore, it is necessary to determine when BKP does not work. Thus, in this study, we aim to clarify the radiographic predictors of secondary vertebral fractures and cement loosening after BKP for OVF.

**Methods:** This study enrolled patients with single-level OVF at the thoracolumbar junction (T11-L2) who underwent BKP for the first time between January 2011 and March 2014. The clinical outcomes were evaluated using the visual analog scale (VAS) and a modified Oswestry Disability Index (ODI) at 1 week and 1, 3, 6, and 12 months after surgery. Radiographic assessments were performed preoperatively and within 1 year after BKP using plain radiography and computed tomography.

**Results:** The 85 patients who met the inclusion criteria underwent BKP. The average age of participants (21 men, 64 women) was 77.8 years (range, 57-92 years). Postoperative VAS and ODI scores were all significantly better than preoperative scores. Polymethyl methacrylate (PMMA)-cement leakage was observed in 18 patients (21.2%) but was asymptomatic in all cases. Secondary vertebral fractures were detected in 20 patients (23.5%), including adjacent levels in 15 patients (17.6%) and non-adjacent levels in 5 patients (5.9%). Rostral bridging osteophyte formation was found to be significantly associated with the occurrence of adjacent vertebral fractures (odds ratio 12.746;  $p=0.010$ ). PMMA-cement loosening was observed in three patients (3.5%). A high prevalence (100%) of bridging osteophytes, vacuum clefts, and spinous process fractures was observed in patients with PMMA-cement loosening. PMMA-cement loosening was found in 3 out of 10 patients with all three of these factors.

**Conclusions:** Rostral bridging osteophyte formation was determined to be a risk factor for both adjacent vertebral fractures and PMMA-cement loosening.

Level of Evidence: 3

## Keywords:

osteoporosis, vertebral fracture, balloon kyphoplasty, X-ray, CT, prognosis

Spine Surg Relat Res 2022; 6(2): 159-166  
dx.doi.org/10.22603/ssrr.2021-0112

## Introduction

The number of patients with osteoporosis has seen a steady increase as society ages, and when a bone fracture occurs, it often interferes with daily life<sup>1)</sup>. Vertebral fractures are the most common fracture occurring among patients

with osteoporosis<sup>2,4)</sup>. Osteoporotic vertebral fractures (OVF) can cause vertebral body collapse and spinal deformity associated with increased morbidity and mortality<sup>5,6)</sup>. Most patients with OVF can be treated conservatively, with rest or thoracolumbar bracing. However, delayed bone union can cause persistent pain and significant spinal deformity, which

Corresponding author: Naosuke Kamei, nahkamei@hiroshima-u.ac.jp

Received: May 31, 2021, Accepted: August 3, 2021, Advance Publication: October 11, 2021

Copyright © 2022 The Japanese Society for Spine Surgery and Related Research

may require surgical treatment<sup>7-9</sup>). Since OVF occurs mainly in the elderly, less invasive methods should be chosen for initial treatment<sup>10</sup>.

Percutaneous vertebroplasty is a minimally invasive surgical approach for the treatment of OVF. In addition, balloon kyphoplasty (BKP) is not only less invasive, but it also aims to inflate the balloon within the fracture to restore vertebral body height<sup>11</sup>. BKP improves pain, activities of daily living, and quality of life in patients with OVF faster than conservative therapies<sup>12,13</sup>. Therefore, BKP is known to be a common surgical treatment for OVF. However, risks after treatment with BKP have been reported, such as cement leakage, secondary vertebral fracture, and instability of the vertebrae<sup>14-16</sup>.

To properly apply BKP as a treatment for OVF, we need to know in what cases BKP does not work. Thus, in this study, we primarily aim to identify the factors that cause secondary vertebral fractures and cement loosening after BKP. To clarify the appropriate indication of BKP for the treatment of OVF, we investigated the clinical outcomes of the first BKP performed on a thoracolumbar junction vertebral fracture, a common site of OVF, and the radiographic predictors of secondary vertebral fractures and cement loosening after BKP.

## Materials and Methods

Of the patients who underwent BKP in our hospital between January 2011 and March 2014, this study enrolled patients who had a single level of OVF at the thoracolumbar junction (T11-L2) with local tenderness and who received BKP for the first time. BKP was applied to patients with unstable OVF who did not improve with conservative treatment for more than 4 weeks and had back pain of 40 mm or more on the visual analog scale (VAS). All patients provided written informed consent to receive BKP. Radiographic features of the thoracic and lumbar spine including the fractured vertebrae were then preoperatively assessed using plain X-ray and computed tomography (CT). BKP was performed using Kyphon™ Balloon Kyphoplasty (Medtronic, Minneapolis, MN) as previously reported<sup>17</sup>. All patients completed a 1-year follow-up.

### Outcomes

The primary outcomes were back pain severity measured by the VAS and the American Academy of Orthopedic Surgeons MODEMS version of the Oswestry Disability Index (ODI; range, 0%-100%) before surgery and at 1 week and 1, 3, 6, and 12 months after surgery<sup>18,19</sup>.

### Radiographic assessments

Polymethyl methacrylate (PMMA)-cement leakage, secondary vertebral fracture in adjacent and non-adjacent levels, and loosening of PMMA cement were assessed using plain X-ray and CT within 1 year after the treatment. Secondary vertebral fracture was defined as a new postoperative verte-

bral body fracture with or without pain. Loosening of PMMA cement was identified as a low-density area around the PMMA cement on CT that was not observed immediately after BKP<sup>20</sup>. The clinical and radiographic characteristics of the patients immediately before surgery (age, sex, time since onset to surgery, bone density of the lumbar spine, number of pre-existing vertebral fractures, vertebral wedge angle, degree of change in vertebral wedge angle, bridging osteophyte formation from the adjacent superior vertebral body to the rostral side, vacuum cleft in vertebrae, posterior wall injury, spinous process fracture) were examined as candidate factors associated with secondary vertebral fractures and cement loosening after BKP. Age was then assessed at the time of surgery. Bone density was measured using dual-energy X-ray absorptiometry and represented as the young adult mean. The vertebral wedge angle was evaluated from a plain X-ray lateral view in the sitting position before surgery, immediately after surgery, and 1 year after surgery ( $\alpha$  in Fig. 1a). In addition, the degree of change in vertebral wedge angle was assessed as the difference in vertebral wedge angle in a plain X-ray lateral view between sitting and supine positions ( $\alpha$ - $\beta$  in Fig. 1a, b). Bridging osteophyte formation, vacuum cleft, posterior wall injury, and spinous process fracture were evaluated using CT. Spinal surgeons with experience of more than 19 years (KY and TN) performed the evaluations for each patient. The observers were blinded to the patients' data.

### Statistical analyses

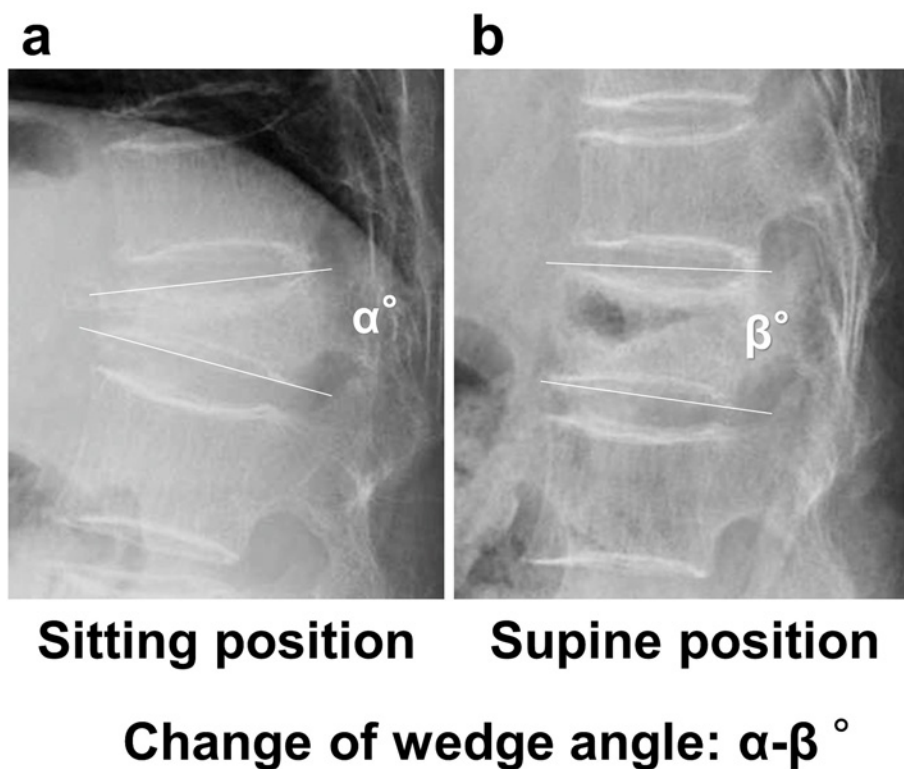
Results of the continuous values are expressed as mean± standard deviation. VAS scores, ODI scores, and vertebral wedge angles were statistically evaluated using one-way repeated measures analysis of variance (ANOVA) with Tukey's honestly significant difference test. Multivariate logistic regression analysis was used to search for significant associations for the adjacent vertebral fracture after BKP. Differences were considered significant if  $p < 0.05$ . JMP® 14 (SAS Institute Inc., Cary, NC) were used for the statistical analyses.

## Results

In this study, 85 of the 236 patients who underwent BKP were determined to have a single level of OVF at T11-L2 and received BKP for the first time. The average age of patients (21 males, 64 females) was 77.8 years (range, 57-92 years).

### Clinical outcomes

The mean VAS score (mm) was 74.3±19.6 before BKP. Postoperative mean VAS score was 20.5±19.6, 25.5±25.8, 29.1±22.6, 33.7±27.2, and 38.1±38.6 at 1 week and 1, 3, 6, and 12 months after surgery, respectively. All postoperative VAS scores were noted to be significantly lower than preoperative VAS score (Fig. 2a). The mean ODI score (%) was 61.2±17.7 before BKP. Postoperative mean ODI score was



**Figure 1.** Wedge angle measurement of fractured vertebral bodies in plain X-ray lateral view. Vertebral wedge angle in (a) sitting position ( $\alpha^\circ$ ) and (b) supine position ( $\beta^\circ$ ). The change of wedge angle was calculated as the difference between these angles.

32.6±18.2, 32.5±18.9, 35.8±17.1, 30.8±17.1, and 30.6±19.4 at 1 week and 1, 3, 6, and 12 months after surgery, respectively. All postoperative ODI scores were significantly better than preoperative ODI score (Fig. 2b).

#### *Vertebral wedge angles*

The mean of vertebral wedge angle ( $^\circ$ ) in the sitting position was 21.7±7.4 before BKP. Postoperative mean vertebral wedge angle in the sitting position was 13.4±6.6 immediately after surgery and 17.8±7.3 at 1 year after surgery. The mean vertebral wedge angle immediately after surgery was significantly smaller than that before BKP. In addition, the mean vertebral wedge angle at 1 year after surgery was significantly smaller than before BKP and significantly greater than immediately after surgery. The loss of correction in vertebral wedge angle ( $^\circ$ ) at 1 year postoperatively was 3.8±4.2.

#### *Leakage of PMMA cement*

PMMA-cement leakage was observed in 18 patients (21.2%) but was asymptomatic in all of these patients. PMMA leaked to the intervertebral disc (Fig. 3a) in 11 cases and to anterior (Fig. 3b) or lateral side of the vertebral body in 7 cases but not to the spinal canal.

#### *Risk factors for secondary vertebral fractures*

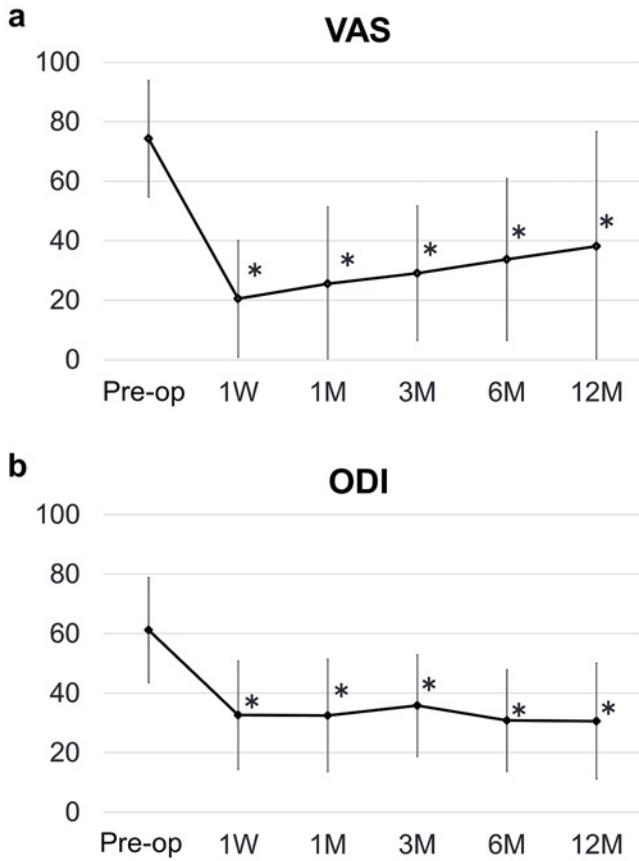
Secondary vertebral fractures were detected in 20 patients (23.5%), including adjacent levels in 15 patients (17.6%)

and non-adjacent levels in 5 patients (5.9%). Secondary spinal fractures at the adjacent level occurred at an average of 1.3±1.1 months (range, 1 week to 3 months) after BKP, whereas those at the non-adjacent level occurred at an average of 2.8±1.9 months (range, 1 week to 5 months) after the BKP. Of the 15 patients with adjacent level fractures, 11 patients occurred within 1 month after BKP and 3 of 5 patients with non-adjacent level fractures occurred more than 3 months after BKP (Fig. 4). Data for candidate factors associated with secondary vertebral fractures are shown in Table 1. Lower bone density was observed in patients with non-adjacent vertebral fracture. The number of pre-existing vertebral fractures was higher in patients with non-adjacent vertebral fracture. High prevalence of bridging osteophyte was observed in patients with adjacent and non-adjacent vertebral fracture. Statistical associations between candidate factors and occurrence of secondary vertebral fractures were assessed using a multivariate logistic regression analysis (Table 2). Prevalence of bridging osteophytes was significantly associated with the occurrence of adjacent vertebral fractures (odds ratio 12.746, 95% CI 1.844-88.100,  $p=0.010$ ) (Table 2 a). However, three candidate factors, including bone density, number of pre-existing vertebral fractures, and bridging osteophytes, were found to be not significantly associated with non-adjacent levels of fractures ( $p=0.097$ , 0.102, and 0.168, respectively).

**Risk factors for PMMA-cement loosening**

The PMMA-cement loosening was observed in three patients (3.5%) (Fig. 5d). Data for candidate factors associated with PMMA-cement loosening are shown in Table 3. High

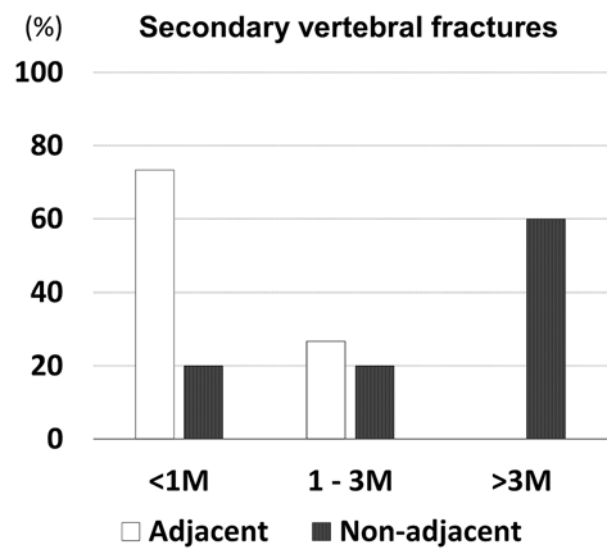
prevalence (100%) of bridging osteophyte, vacuum cleft, and spinous process fracture was observed in patients with PMMA-cement loosening (Table 3, Fig. 5a, b). Although the number of patients with PMMA-cement loosening was too small to assess the statistical significance, PMMA-cement loosening was detected in 3 out of 10 patients with all three of these factors.



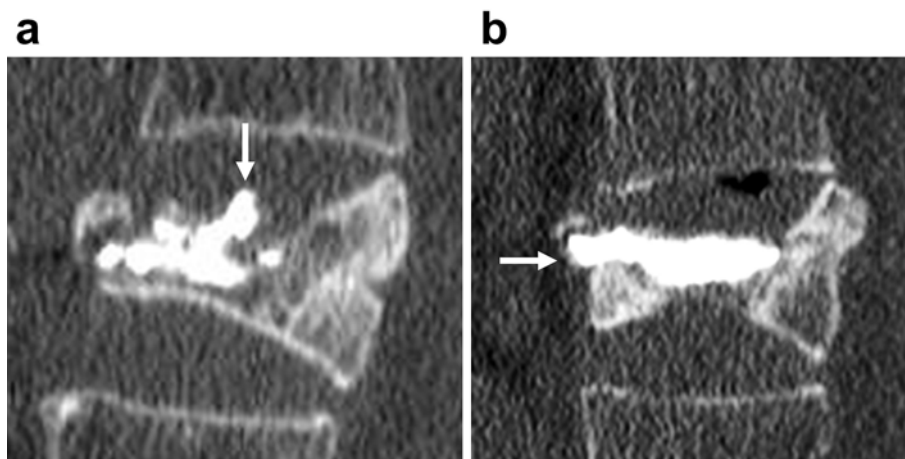
**Figure 2.** Graph of scores before, 1 week, and 1, 3, 6, and 12 months after surgery on (a) the Oswestry Disability Index and (b) the visual analog scale. All postoperative scores were significantly improved compared to preoperative scores. \* Significant difference,  $p < 0.05$  (one-way repeated measures ANOVA with Tukey's HSD test).

**Discussion**

This study demonstrated the radiographic characteristics associated with adjacent vertebral fractures and cement loosening after BKP. Multivariate logistic regression analysis revealed a significant association between bridging osteophyte



**Figure 4.** Graph of the period from surgery to the occurrence of secondary vertebral fractures. Each data point is expressed as a percentage. The majority (73.3%) of adjacent vertebral fractures occurred within 1 month after surgery, while the majority (60.0%) of non-adjacent vertebral fractures occurred more than 3 months after surgery.



**Figure 3.** Computed tomographic sagittal plane reconstruction images of PMMA-cement leakage (a) to the intervertebral disc and (b) to the anterior.

**Table 1.** Data for Candidate Factors Associated with Secondary Vertebral Fractures.

Variable	Total (n=85)	Adjacent level		Non-adjacent level	
		With (n=15)	Without (n=70)	With (n=5)	Without (n=80)
Age (year)	77.8±7.0	79.7±6.0	77.4±7.2	77.0±7.0	77.7±7.1
Gender (female)	64 (75.3%)	12 (80.0%)	52 (74.3%)	3 (60.0%)	61 (76.3%)
Time since onset (month)	4.3±4.6	4.0±4.4	4.3±4.7	2.3±0.7	4.3±4.7
Bone density (YAM%)	74.5±12.1	75.1±14.1	74.3±11.8	65.0±6.0	74.4±11.7
Number of pre-existing vertebral fractures	0.9±1.4	1.3±1.8	0.8±1.3	2.0±2.8	0.9±1.4
Vertebral wedge angle (degree)	21.7±7.4	23.2±8.7	21.4±7.1	22.0±4.9	21.7±7.4
Change of wedge angle (degree)	8.6±6.1	11.6±6.9	7.9±5.8	9.2±6.9	8.5±6.1
Bridging osteophyte	32 (37.6%)	11 (73.3%)	21 (30.0%)	3 (60.0%)	29 (36.3%)
Vacuum cleft	71 (83.5%)	13 (86.7%)	58 (82.9%)	4 (80.0%)	67 (83.8%)
Posterior wall injury	65 (76.5%)	13 (86.6%)	52 (74.3%)	2 (40.0%)	63 (78.8%)
Spinous process fracture	17 (20.0%)	3 (20.0%)	14 (20.0%)	1 (20.0%)	16 (20.0%)

**Table 2.** Multivariate Logistic Regression Analysis of Candidate Factors Associated with Secondary Vertebral Fractures.

a. Adjacent level (n=15)

Variable	Odds ratio	95% CI	P-value
Age	1.044	0.940–1.172	0.434
Gender (female)	1.755	0.245–12.583	0.576
Time since onset	1.003	0.792–1.205	0.980
Bone density	0.996	0.951–1.068	0.901
Number of pre-existing vertebral fractures	1.552	1.033–2.905	0.079
Vertebral wedge angle	1.03	0.938–1.246	0.651
Change of wedge angle	1.108	0.933–1.227	0.138
Bridging osteophyte	12.746	1.844–88.100	0.010*
Vacuum cleft	0.524	0.033–8.320	0.647
Posterior wall injury	1.931	0.144–25.821	0.619
Spinous process fracture	0.380	0.058–2.488	0.313

\*p<0.05

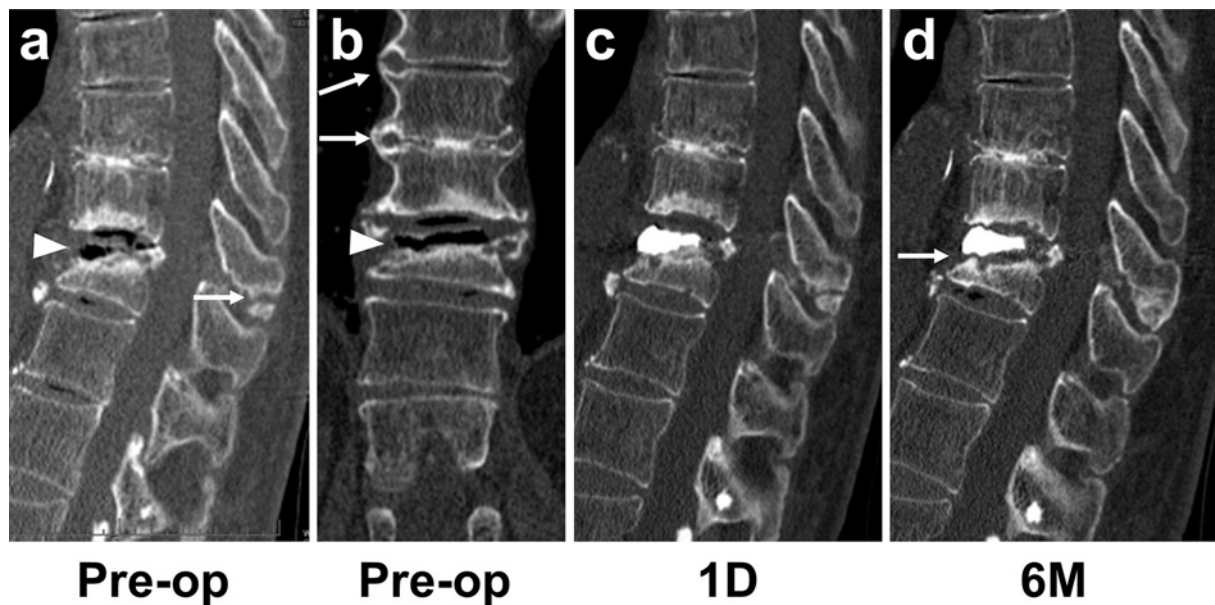b. Non-adjacent level (n=5)

Variable	Odds ratio	95% CI	P-value
Age	0.995	0.654–1.775	0.984
Gender (female)	0.001	0.000–1.830	0.071
Time since onset	0.335	0.011–2.985	0.420
Bone density	0.614	0.232–0.892	0.097
Number of pre-existing vertebral fractures	10.574	1.842–1100.917	0.102
Vertebral wedge angle	1.554	0.928–5.524	0.359
Change of wedge angle	1.003	0.659–1.499	0.989
Bridging osteophyte	904.795	0.057–2087394	0.168
Vacuum cleft	0.783	0.002–285.190	0.935
Posterior wall injury	0.024	0.000–384.034	0.450
Spinous process fracture	0.031	0.000–9623.563	0.589

formation from the adjacent vertebral body to the cranial side and adjacent vertebral fractures. No radiographic factors were determined to be significantly associated with non-adjacent vertebral fractures or PMMA-cement loosening due to the low incidence of these complications. However, patients with non-adjacent vertebral fractures had a high number of pre-existing vertebral fractures and low bone density.

In addition, all patients with PMMA-cement loosening had bridging osteophytes, vacuum clefts, and spinous process fractures. Furthermore, postoperative VAS and ODI scores were significantly better than those before surgery. In addition, these score improvements were comparable to those of previous reports<sup>21,22</sup>. The postoperative vertebral wedge angle has significantly improved from the preoperative angle, although the corrective effect decreased slightly at 1 year postoperatively.

The incidence of secondary vertebral fractures after BKP in this study was comparable to previous reports<sup>23-25</sup>. Several previous studies have already identified factors associated with adjacent vertebral fractures<sup>26-30</sup>. Thoracolumbar fracture levels have been reported as a risk factor for adjacent vertebral fractures after BKP<sup>28,29</sup>. Thus, the thoracolumbar level is known as a risk factor for adjacent vertebral body fractures and is also a common site for vertebral body fractures. Therefore, this present study was limited to patients with thoracolumbar junction vertebral body fractures. Factors such as age, sex, bone density, time to surgery, pre-existing vertebral fracture, vertebral wedge angle, and posterior wall injury were assessed as potential risk factors for adjacent vertebral body fractures in this study and were evaluated in previous reports. While sex, time to surgery, and vertebral wedge angle were reported in a previous study as factors associated with adjacent vertebral body fractures, these factors were not associated with adjacent vertebral fractures in other studies and in this present study<sup>26-30</sup>. Therefore, these three factors might not be significant factors associated with adjacent vertebral fractures. A previous study did not show a statistically significant association between pre-existing vertebral fractures and adjacent vertebral fractures, but patients with adjacent vertebral body fractures tended to have pre-existing vertebral fractures ( $p=0.053$ )<sup>28</sup>. Similar trends were observed in this study ( $p=0.079$ ). This study found no significant association between these factors and adjacent vertebral fractures, but focused on evaluating changes in vertebral wedge angle between sitting and supine positions, bridging osteophyte formation, vacuum cleft, and spinous process fracture as new factors. Rostral bridging osteophyte forma-



**Figure 5.** Representative reconstruction images of computed tomography of a patient with PMMA-cement loosening a, b) preoperatively, c) 1 day later, d) 6 months postoperatively. a) A triangle indicates a vacuum cleft; an arrow indicates a spinous process fracture. b) A triangle indicates a vacuum cleft; arrows indicate bridging osteophytes. d) An arrow indicates PMMA-cement loosening.

**Table 3.** Data for Candidate Factors Associated with Loosening of PMMA-Cement.

Variable	Total (n=85)	With loosening (n=3)	Without loosening (n=82)
Age (year)	77.8±7.0	81.7±2.9	77.7±7.1
Gender (female)	64 (75.3%)	3 (100%)	61 (74.4%)
Time since onset (month)	4.3±4.6	3.3±2.6	4.3±4.7
Bone density (YAM%)	74.5±12.1	76.3±24.6	74.4±11.7
Number of pre-existing vertebral fractures	0.9±1.4	0.7±1.2	0.9±1.4
Vertebral wedge angle	21.7±7.4	20.9±10.1	21.7±7.4
Change of wedge angle	8.6±6.1	11.7±5.6	8.5±6.1
Bridging osteophyte	32 (37.6%)	3 (100%)	29 (35.3%)
Vacuum cleft	71 (83.5%)	3 (100%)	68 (82.9%)
Posterior wall injury	65 (76.5%)	2 (66.7%)	63 (76.8%)
Spinous process fracture	17 (20.0%)	3 (100%)	14 (17.1%)

tion from the adjacent superior vertebral body was significantly associated with the occurrence of adjacent vertebral fractures (odds ratio 12.746;  $p=0.010$ ). Some patients with bridge osteophyte formation would be included in the category of disseminated idiopathic skeletal hyperostosis because of the continuity of bridge osteophyte formation across multiple vertebrae. However, adjacent intervertebral fractures also occurred in patients who had only single-intervertebral bridging osteophyte formation. In this study, non-adjacent level secondary vertebral fractures also occurred in five patients. Although the number of patients with non-adjacent fractures was too small to be assessed statistically, these patients tended to have low bone density and a high number of pre-existing vertebral fractures. These features are also considered risk factors for vertebral fractures, even in the natural course of osteoporosis<sup>31,32</sup>. In addition, 73.3% of adjacent level fractures occurred within 1 month

after BKP, whereas 60.0% of non-adjacent level fractures occurred more than 3 months after BKP in this study; therefore, non-adjacent vertebral fractures might not be specific to BKP.

Loosening of PMMA-cement was found in three patients after BKP in this study. A previous study reported risk factors for cement loosening after percutaneous vertebroplasty (PVP)<sup>20</sup>. They reported that 49 of 195 patients (25.1%) who underwent PVP for OVF exhibited cement loosening. However, the patients' condition differed between this previous study and ours. This previous study has enrolled patients who had been refractory to conservative treatment for more than 3 months. It also included patients with split-type vertebral fractures reported as a risk factor for cement loosening. A split vertebral fracture was also reported as a risk factor for revision surgery after BKP<sup>33</sup>. The present study did not include patients with split vertebral fractures. No statisti-

cally significant risk factors for cement loosening were found, as there were only three cases in this study. However, bridging osteophytes, vacuum clefts, and spinous process fractures were observed in all three of these patients. In particular, the prevalence of bridging osteophytes and spinous process fractures was markedly higher than in patients without loosening of the PMMA cement. In the present study, a bridging osteophyte was also identified as a risk factor for adjacent vertebral fracture; BKP indications should be carefully considered in the presence of rostral bridging osteophyte formation from the adjacent superior vertebral body. Spinous process fracture was also reported as a risk factor for cement loosening after PVP18. OVF with spinous process fractures may be classified as type B2 in the AOSpine thoracolumbar injury classification system<sup>34</sup>. Surgical intervention is strongly recommended for this type of fracture<sup>35</sup>. From the results of this study, it might be more appropriate to carefully select BKP interventions if both bridging osteophytes and spinous process fractures are present.

This study has some limitations. This study did not include cases with BKP within 4 weeks of the onset of fracture. A previous study has reported that patients who underwent BKP within 4 weeks after the onset of fracture had improved postoperative vertebral wedge angles and a lower incidence of adjacent vertebral fractures<sup>36</sup>. However, another previous study showed that patients who underwent BKP within 2 months of the onset of fractures had improved postoperative vertebral wedge angles, but it did not reduce the incidence of adjacent vertebral fractures<sup>37</sup>. Differences in these reports might be due to differences between 4 weeks and 2 months, but it could also be attributed to differences in patient selection. It is difficult to judge the effect of conservative therapy within 4 weeks of fracture onset. Therefore, in this study, BKP was performed only in patients who had severe pain for more than 4 weeks after fracture onset and was unlikely to be able to heal the fracture conservatively. Magnetic resonance imaging was not used for evaluation in this study, as it was not performed on all patients. This study did not consider the content of drug treatment at all because the content and duration of drug therapy varied from patient to patient. However, this study did not include patients using steroids or teriparatide, which had an impact on fracture healing. The number of patients with PMMA-cement loosening in this study was too low to assess statistical significance. Thus, larger sample size studies will be needed in the future to demonstrate the key factors associated with PMMA-cement loosening.

**Conflicts of Interest:** The authors declare that there are no relevant conflicts of interest.

**Sources of Funding:** No funds were received in support of this work.

**Author Contributions:** Naosuke Kamei wrote and prepared the manuscript, and all of the authors participated in

the study design. All authors have read, reviewed, and approved the article. The first two authors contributed equally to this work and should be considered as co-first authors.

**Ethical Approval:** The study protocol was approved by the institutional review board of Hiroshima University Hospital (Approval code: E-1352).

**Informed Consent:** Informed consent was given by all participants in this study.

## References

1. Nishizawa Y, Miura M, Ichimura S, et al. Executive summary of the Japan Osteoporosis Society Guide for the use of bone turnover markers in the diagnosis and treatment of osteoporosis (2018 Edition). *Clin Chim Acta*. 2019;498:101-7. doi:10.1016/j.cca.2019.08.012
2. Riggs BL, Melton LJ, 3rd. The worldwide problem of osteoporosis: insights afforded by epidemiology. *Bone*. 1995;17(5):505S-11 S. doi:10.1016/8756-3282(95)00258-4
3. Fujiwara S, Kasagi F, Masunari N, et al. Fracture prediction from bone mineral density in Japanese men and women. *J Bone Miner Res*. 2003;18(8):1547-53. doi:10.1359/jbmr.2003.18.8.1547
4. Ensrud KE, Schousboe JT. Clinical practice. Vertebral fractures. *N Engl J Med*. 2011;364(17):1634-42. doi:10.1056/NEJMcp1009697
5. Lau E, Ong K, Kurtz S, et al. Mortality following the diagnosis of a vertebral compression fracture in the Medicare population. *J Bone Joint Surg Am*. 2008;90(7):1479-86. doi:10.2106/JBJS.G.00675
6. Nakanishi K, Uchino K, Watanabe S, et al. Video-assisted thoracoscopic surgery for re-collapse of vertebrae after percutaneous vertebral augmentation (PVA). *Spine Surg Relat Res*. 2020;5(1):28-33. doi:10.22603/ssrr.2020-0009
7. Gehlbach SH, Burge RT, Puleo E, et al. Hospital care of osteoporosis-related vertebral fractures. *Osteoporos Int*. 2003;14(1):53-60. doi:10.1007/s00198-002-1313-z
8. Inose H, Kato T, Ichimura S, et al. Risk factors of nonunion after acute osteoporotic vertebral fractures: a prospective multicenter cohort study. *Spine (Phila Pa 1976)*. 2020;45(13):895-902. doi:10.1097/BRS.0000000000003413
9. Iwata A, Kanayama M, Oha F, et al. Is bone nonunion, vertebral deformity, or spinopelvic malalignment the best therapeutic target for amelioration of low back pain after osteoporotic vertebral fracture? *Spine (Phila Pa 1976)*. 2020;45(13):E760-7. doi:10.1097/BRS.0000000000003422
10. Hosogane N, Nojiri K, Suzuki S, et al. Reply to the editor: surgical treatment of osteoporotic vertebral fracture with neurological deficit- a nationwide multicenter study in Japan. *Spine Surg Relat Res*. 2020;4(3):292-3. doi:10.22603/ssrr.2020-0033
11. Hinde K, Maingard J, Hirsch JA, et al. Mortality outcomes of vertebral augmentation (vertebroplasty and/or balloon kyphoplasty) for osteoporotic vertebral compression fractures: a systematic review and meta-analysis. *Radiology*. 2020;295(1):96-103. doi:10.1148/radiol.2020191294
12. Wardlaw D, Cummings SR, Van Meirhaeghe J, et al. Efficacy and safety of balloon kyphoplasty compared with non-surgical care for vertebral compression fracture (FREE): a randomised controlled trial. *Lancet*. 2009;373(9668):1016-24. doi:10.1016/S0140-6736(09)60010-6
13. Boonen S, Van Meirhaeghe J, Bastian L, et al. Balloon kyphoplasty for the treatment of acute vertebral compression frac-

- tures: 2-year results from a randomized trial. *J Bone Miner Res.* 2011;26(7):1627-37. doi:10.1002/jbmr.364
14. Tarukado K, Tono O, Ikuta K, et al. Instability of the vertebrae remains following balloon kyphoplasty. *Global Spine J.* 2014;4(2): 89-92. doi:10.1055/s-0034-1370790
  15. Abdelgawaad AS, Ezzati A, Govindasamy R, et al. Kyphoplasty for osteoporotic vertebral fractures with posterior wall injury. *Spine J.* 2018;18(7):1143-8. doi:10.1016/j.spinee.2017.11.001
  16. Lee JK, Jeong HW, Joo IH, et al. Percutaneous balloon kyphoplasty for the treatment of very severe osteoporotic vertebral compression fractures: a case-control study. *Spine J.* 2018;18(6): 962-9. doi:10.1016/j.spinee.2017.10.006
  17. Garfin SR, Yuan HA, Reiley MA. New technologies in spine: kyphoplasty and vertebroplasty for the treatment of painful osteoporotic compression fractures. *Spine (Phila Pa 1976).* 2001;26(14): 1511-5. doi:10.1097/00007632-200107150-00002
  18. Fairbank JC, Couper J, Davies JB, et al. The Oswestry low back pain disability questionnaire. *Physiotherapy.* 1980;66(8):271-3.
  19. Fairbank JC, Pynsent PB. The Oswestry disability index. *Spine (Phila Pa 1976).* 2000;25(22):2940-52; discussion 2952. doi: 10.1097/00007632-200011150-00017
  20. Nakamae T, Yamada K, Tsuchida Y, et al. Risk factors for cement loosening after vertebroplasty for osteoporotic vertebral fracture with intravertebral cleft: a retrospective analysis. *Asian Spine J.* 2018;12(5):935-42. doi:10.31616/asj.2018.12.5.935
  21. Noriega D, Marcia S, Theumann N, et al. A prospective, international, randomized, noninferiority study comparing an implantable titanium vertebral augmentation device versus balloon kyphoplasty in the reduction of vertebral compression fractures (SAKOS study). *Spine J.* 2020;20(12):2039-40. doi:10.1016/j.spinee.2020.08.021.
  22. Cheng J, Muheremu A, Zeng X, et al. Percutaneous vertebroplasty vs balloon kyphoplasty in the treatment of newly onset osteoporotic vertebral compression fractures: A retrospective cohort study. *Medicine (Baltimore).* 2019;98(10):e14793. doi:10.1097/MD.00000000000014793
  23. Pflugmacher R, Schroeder RJ, Klostermann CK. Incidence of adjacent vertebral fractures in patients treated with balloon kyphoplasty: two years' prospective follow-up. *Acta Radiol.* 2006; 47(8):830-40. doi:10.1080/02841850600854928
  24. Eck JC, Nachtigall D, Humphreys SC, et al. Comparison of vertebroplasty and balloon kyphoplasty for treatment of vertebral compression fractures: a meta-analysis of the literature. *Spine J.* 2008; 8(3):488-97. doi:10.1016/j.spinee.2007.04.004
  25. Tutton SM, Pflugmacher R, Davidian M, et al. KAST study: the Kiva system as a vertebral augmentation treatment—a safety and effectiveness trial: a randomized, noninferiority trial comparing the Kiva system with balloon kyphoplasty in treatment of osteoporotic vertebral compression fractures. *Spine (Phila Pa 1976).* 2015;40(12):865-75. doi:10.1097/BRS.0000000000000906
  26. Spross C, Aghayev E, Kocher R, et al. Incidence and risk factors for early adjacent vertebral fractures after balloon kyphoplasty for osteoporotic fractures: analysis of the SWISSspine registry. *Eur Spine J.* 2014;23(6):1332-8. doi:10.1007/s00586-013-3052-6
  27. Civelek E, Cansever T, Yilmaz C, et al. The retrospective analysis of the effect of balloon kyphoplasty to the adjacent-segment fracture in 171 patients. *J Spinal Disord Tech.* 2014;27(2):98-104. doi: 10.1097/bsd.0b013e31824e9b98
  28. Takahashi S, Hoshino M, Yasuda H, et al. Development of a scoring system for predicting adjacent vertebral fracture after balloon kyphoplasty. *Spine J.* 2019;19(7):1194-201. doi:10.1016/j.spinee.2019.02.013
  29. Ko BS, Cho KJ, Park JW. Early adjacent vertebral fractures after balloon kyphoplasty for osteoporotic vertebral compression fractures. *Asian Spine J.* 2019;13(2):210-5. doi:10.31616/asj.2018.0224
  30. Momomura R, Shimamura Y, Kaneko K. Postoperative clinical outcomes of balloon kyphoplasty treatment: would adherence to indications and contraindications prevent complications? *Asian Spine J.* 2020;14(2):198-203. doi:10.31616/asj.2019.0010
  31. Marshall D, Johnell O, Wedel H. Meta-analysis of how well measures of bone mineral density predict occurrence of osteoporotic fractures. *BMJ.* 1996; 312(7041):1254-9. doi:10.1136/bmj.312.7041.1254
  32. Klotzbuecher CM, Ross PD, Landsman PB, et al. Patients with prior fractures have an increased risk of future fractures: a summary of the literature and statistical synthesis. *J Bone Miner Res.* 2000;15(4):721-39. doi:10.1359/jbmr.2000.15.4.721
  33. Takahashi S, Hoshino M, Yasuda H, et al. Characteristic radiological findings for revision surgery after balloon kyphoplasty. *Sci Rep.* 2019;9(1):18513. doi:10.1038/s41598-019-55054-5
  34. Vaccaro AR, Oner C, Kepler CK, et al. AOSpine thoracolumbar spine injury classification system: fracture description, neurological status, and key modifiers. *Spine (Phila Pa 1976).* 2013;38(23): 2028-37. doi:10.1097/BRS.0b013e3182a8a381
  35. Vaccaro AR, Schroeder GD, Kepler CK, et al. The surgical algorithm for the AOSpine thoracolumbar spine injury classification system. *Eur Spine J.* 2016;25(4):1087-94. doi:10.1007/s00586-015-3982-2
  36. Minamide A, Maeda T, Yamada H, et al. Early versus delayed kyphoplasty for thoracolumbar osteoporotic vertebral fractures: the effect of timing on clinical and radiographic outcomes and subsequent compression fractures. *Clin Neurol Neurosurg.* 2018;173: 176-81. doi:10.1016/j.clineuro.2018.07.019
  37. Takahashi S, Hoshino M, Terai H, et al. Differences in short-term clinical and radiological outcomes depending on timing of balloon kyphoplasty for painful osteoporotic vertebral fracture. *J Orthop Sci.* 2018;23(1):51-6. doi:10.1016/j.jos.2017.09.019

Spine Surgery and Related Research is an Open Access journal distributed under the Creative Commons Attribution-NonCommercial-NoDerivatives 4.0 International License. To view the details of this license, please visit (<https://creativecommons.org/licenses/by-nc-nd/4.0/>).