

Journal section: Oral Medicine and Pathology
 Publication Types: Review

doi:10.4317/jced.59554
<https://doi.org/10.4317/jced.59554>

Jaw bone metastasis from Lung cancer as sole primary source: A systematic review

Sonia Gupta ¹, Manveen-Kaur Jawanda ², Aruna Ganganna ³, Suman Basavaraju ⁴, Neha Kashav ⁵, Jayata Dhawan ⁶, Sumit-Kumar Yadav ⁷, Achla-Bharti Yadav ⁸

¹ MDS, Reader, Department of Oral Pathology and Microbiology & Forensic odontology, Rayat and Bahra Dental college and hospital, Mohali, Punjab, India

² MDS, Professor & Head, Department of Oral Pathology and Microbiology & Forensic odontology. Laxmi bai institute of dental sciences and hospital, Patiala, Punjab, India

³ MDS, Assistant Professor, Department of Periodontology, JSS Dental College and Hospital, Mysore, Karnataka, India

⁴ MDS, Reader, Department of Periodontology, JSS Dental College and Hospital, Mysore, Karnataka, India

⁵ MDS, Senior Lecturer, Department of Pediatric and Preventive Dentistry, Bhojia Dental College and Hospital, Baddi, HP, India

⁶ MDS, Senior Lecturer, Department of Pediatric and Preventive Dentistry, MM College of Dental Sciences and Research, Mullana, Haryana, India

⁷ MDS, Professor, Department of Orthodontics & Dentofacial Orthopedics, D J College of Dental Sciences & Research, Modinagar, UP, India.

⁸ MDS, Professor, Department of Oral Pathology & Microbiology, D J College of Dental Sciences and Research, Modinagar, UP, India

Correspondence:

#95/3, Adarsh Nagar, Dera Bassi
 Dist. Mohali, Punjab-140507, India
Sonia.4840@gmail.com

Received: 20/03/2022
 Accepted: 04/05/2022

Gupta S, Jawanda MK, Ganganna A, Basavaraju S, Kashav N, Dhawan J, Yadav SK, Yadav AB. Jaw bone metastasis from Lung cancer as sole primary source: A systematic review. J Clin Exp Dent. 2022;14(7):e573-93.

Article Number: 59554 <http://www.medicinaoral.com/odo/indice.htm>
 © Medicina Oral S. L. C.I.F. B 96689336 - eISSN: 1989-5488
 eMail: jced@jced.es
Indexed in:
 Pubmed
 Pubmed Central® (PMC)
 Scopus
 DOI® System

Abstract

Background: Lung cancer is one of the leading causes of death worldwide. Lung cancer metastasis to oral region is very rare. Very few research work has been conducted till date to analyse the jaw bone metastasis from Lung cancer as the primary source. The goal of this research was to examine published cases of jaw bone metastasis from lung cancer as the sole primary source from 1st December 1961 to 31st December 2021 and to learn about their characteristics.

Material and Methods: An electronic search of the published English literature was performed in PubMed/ Medline, Scopus, Google Scholar, and Research gate databases, using keywords like ‘Lung cancer’, OR/AND ‘Lung carcinoma’, OR/AND ‘Metastasis’, OR/AND ‘Primary’, OR/AND ‘Source’, OR/AND ‘Oral cavity’ OR/AND ‘Jaw’, OR/ AND ‘Mandible’, OR/AND ‘Maxilla’, OR/ AND ‘Temporomandibular joint’, OR/ AND ‘Condyle’, OR/ AND ‘Ramus’, OR/ AND ‘Maxillary sinus’, AND Initial’, OR/ AND ‘Treatment’, OR/AND ‘Prognosis’, OR/ AND ‘Follow-up’, OR/AND ‘Recurrence’, OR/ AND ‘Survival rate’. We also searched all related journals manually. Reference list of all articles was also checked. Data extracted were tabulated and summarized.

Results: In total, we found 60 relevant publications with 66 patients in our research. The prognosis was poor, with a survival time of 1 week to 1.5 years. The most prevalent diagnosed metastatic lung cancer to jaw bones was adenocarcinoma and mandible was the predominant site.

Conclusions: Jaw bone metastasis from lung cancer is rare and has a bad prognosis. Because of their resemblance to other jaw problems and late clinical signs, these lesions go unnoticed the majority of the time, making detection difficult. More cases need to be published in order to raise awareness of these lesions and gain a better understanding of their characteristics.

Key words: *Jaw bone, lung cancer, metastasis, primary, prognosis.*

Introduction

According to GLOBOCAN databases, Lung cancer (LC) has overtaken breast cancer as the 2nd most often diagnosed cancer worldwide, and it remains one of the major causes of mortality (1). In 2020, an estimated 2.2 million new cases of LC were diagnosed worldwide, contributing for around 11.4 % of the global cancer burden (1). LC is characterised by its stealthy nature, remaining asymptomatic until the disease has progressed to an advanced stage, which is associated with a risk of distant metastasis. And, most of the time, even once symptoms arise, patients disregard them, resulting in a delay in diagnosis and treatment (2). The liver, kidney, adrenals, brain, skeletal muscles, vertebrae, and other organs are all involved in distant distribution via LC (3). According to a retrospective analysis done by Tsuya *et al.* in 2007, bone metastasis from LC is a frequent event and the most common bone metastasized from LC is spine followed by the ribs, ilium, sacrum, femur, humerus, scapula and sternum (4). LC metastasis into the oral cavity is uncommon, and mostly affects oral soft tissues rather than jaw bones (JB). Few cases of jaw bone metastasis (JBM) from LC as the sole primary source have been reported in the literature. And the prognosis for such cases is poor, indicating the

critical importance of their early identification and management. Due to their strong resemblance to benign growth, late appearance, or lack of interpretation, diagnosis of JBM remains difficult for clinicians and pathologists (5). The goal of this research was to examine published cases of JBM from LC as the sole primary source from 1st December 1961 to 31st December 2021, , as well as to learn about their characteristics.

Material and Methods

The Preferred Reporting Items for Systematic Reviews and Meta-Analyses (PRISMA) standards were used to conduct this research. There was no need to seek any ethical approval because of the nature of the current review.

-Focused PECO question
 For search screening, we framed a focused PECO question; How many cases of JBM from LC as the sole primary source have been documented in the literature and what is the prognosis of these metastatic lesions?
 Population: Patients with JBM from LC
 Exposure: LC metastasis
 Comparison: Not applicable for this research
 Outcome: Prognosis of JBM from LC
 -Search strategy for identification of studies (Fig. 1)

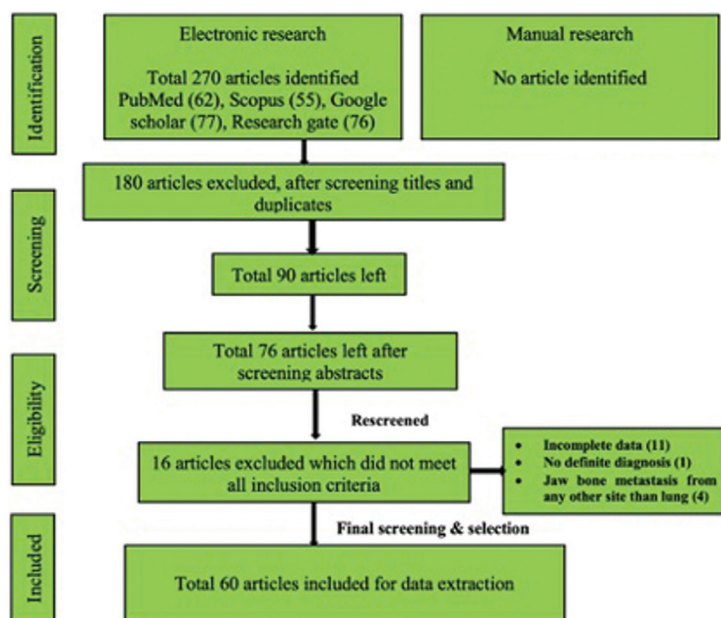


Fig. 1: PRISMA Flow chart showing search strategy and screening.

An electronic search of the published English literature was performed in PubMed/ Medline, Scopus, Google Scholar, and Research gate databases, using keywords like ‘Lung cancer’, OR/ AND ‘Lung carcinoma’, OR/ AND ‘Metastasis’, OR/AND ‘Primary’, OR/AND ‘Source’, OR/AND ‘Oral cavity’ OR/AND ‘Jaw’, OR/ AND ‘Mandible’, OR/AND ‘Maxilla’, OR/ AND ‘Temporomandibular joint’, OR/ AND ‘Condyle’, OR/ AND ‘Ramus’, OR/ AND ‘Maxillary sinus’, OR/ AND ‘Initial’, OR/ AND ‘Treatment’, OR/AND ‘Prognosis’, OR/ AND ‘Follow-up’, OR/AND ‘Recurrence’, OR/ AND ‘Survival rate’ We also searched all related journals manually. Reference list of all articles was also checked.

-Screening of studies

The current review involved three steps screening of the studies. In the first step, titles were reviewed by two authors (SG, MKJ) independently and duplicates were removed. Then two authors (AG, SB) reviewed the selected abstracts of all the reports independently. In the final stage, the text of selected studies was screened by remaining four authors separately (NK, JD, SKY, ABY). Full report was collected, discussed, and resolved among all authors for cases that appeared to fit the inclusion criteria or for which evidence was insufficient to make a clear determination.

-Inclusion criteria

- Confirmed cases of JBM from LC as the sole primary source. Papers included were from 1st December 1961 to 31st December 2021.
- Type of studies: Case reports, letter to editor, Retrospective analysis and correspondence.
- In retrospective analysis, only those cases were selected in which LC was the sole primary source of JBM.
- Cases were selected beyond the restriction of limitations on parameters such as age, gender, ethnicity or socioeconomic status, etc.
- Articles published only in English language were included.

-Exclusion criteria

- Cases with no definite diagnosis of JBM from LC as the sole primary source.
- Publications reporting the JBM from any other site than lung.
- Cases of oral soft tissue metastasis from LC as the primary source.
- Epidemiological studies, case control studies, cohort studies which lack individual patient data, were excluded.
- Review articles, editorials, conference abstracts, hypothesis papers, web news, media reports, animal studies.
- Duplicate, irrelevant and incomplete data were excluded.
- Articles published in languages other than English were excluded.

-Outcome measures

1. Primary outcome measures: To evaluate the number of cases of JBM from LC as the sole primary source re-

ported in the literature from 1st December 1961 to 31st December 2021, and to determine their prognosis.

2. Secondary outcome measures: To evaluate factors such as:

- World-wide distribution of cases of JBM from LC
- Patient’s demographic details
- Associated risk factors
- Predominant site of JBM from LC
- Clinical and radiographic features of these metastatic lesions
- Most prevalent type of metastatic LC
- Type of therapies used to treat such metastatic lesions
- Risk of bias assessment

Most of the studies included in this review were case reports. Risk of bias in the included studies were appraised following CARE checklist guidelines. In many of the studies, there was missing information regarding many parameters used for data extraction in our research. We tried reaching the authors of those cases to clarify this bias; however we were unable to recover the missing information.

-Data extraction & analysis

After study selection, screening and a thorough examination, the data were extracted. The information gathered was cross-checked and tabulated into three tables (Tables 1-3 cont.). In case of missing data, 6 weeks’ time was given to gather the information. If the information was still missing, we then indicated the missing data as “Not available (NA)” in the text and in the tables. Extracted data points in table 1 included demographic details such as; authors’ names, year of publication, country, age of patient, gender of patient, previous history of LC and associated risk factors. Table 2 included clinical details such as; jaw involved, right/left side, anterior/posterior side, chief complaint, clinical features, radiographic features, provisional diagnosis, final diagnosis, side of LC, JB as the initial site of metastasis and any other site of metastasis. Table 3 described therapeutic parameters such as; type of treatment given, prognosis, and cause of death.

Results (Table 4-4 cont.-1)

Results were expressed in descriptive statistics. Our electronic search yielded a total of 270 articles. No additional articles could be found with a manual search. After removing duplicates, screening titles and abstracts and the papers that did not fulfil the inclusion criteria, a total of 60 articles were left and included for data extraction (Fig. 1), (6-46). There were 52 Case reports, 4 Retrospective analysis, 3 letter to editor and 1 Correspondence. Some of the variable assessments in several papers, particularly in Retrospective analysis, were incomplete. There were 66 patients in total, with 37 males (56%) and 25 females (38%). The maximum number of cases were from India (n-15), followed by Turkey (n-

Table 1: Demographic data of patients with jaw bone metastasis from lung cancer as the sole primary source (1st December 1961 to 31st December 2021).

S.NO.	Authors/ Year	Country	Age of patient (years)	Gender	Previous history of lung cancer	Associated risk factors/ Medical history
1.	Moses <i>et al.</i> 1961	USA	NA	NA	Y	NA
2.	Ciola <i>et al.</i> 1977	Switzerland	NA	NA	N	NA
3.	Compere <i>et al.</i> 1981	France	NA	NA	N	N
4.	Peacock <i>et al.</i> 1982	UK	53	M	N	S
5.	Huang <i>et al.</i> 1986	Taiwan	49	F	N	N
6.	Ii <i>et al.</i> 1992	Japan	36	M	Y	S, A
7.	Marinella <i>et al.</i> 1997	USA	62	M	N	Renal transplant, scleroderma
8.	Hwang <i>et al.</i> 2004	Korea	58	M	N	N
9.	Kaufmann <i>et al.</i> 2005	Germany	48	M	Y	NA
10.	Bodner <i>et al.</i> 2006	Israel	67	F	Y	NA
11.	Bodner <i>et al.</i> 2006	Israel	71	M	Y	NA
12.	Sari <i>et al.</i> 2006	Turkey	65	M	N	S, D
13.	Yaser <i>et al.</i> 2006	Turkey	NA	NA	N	N
14.	Pereira-Filho <i>et al.</i> 2007	Brazil	64	F	N	NA
15.	Bircan <i>et al.</i> 2008	Turkey	53	M	NA	NA
16.	Jham <i>et al.</i> 2011	USA	66	F	NA	NA
17.	Jham <i>et al.</i> 2011	USA	54	F	NA	NA
18.	Jham <i>et al.</i> 2011	USA	73	F	NA	NA
19.	Tabib <i>et al.</i> 2011	Israel	49	M	N	TA, IHD
20.	Tatlidil <i>et al.</i> 2011	Turkey	50	F	N	NA
21.	Zhang <i>et al.</i> 2011	China	78	M	N	N
22.	Abi-Fadel <i>et al.</i> 2012	USA	71	M	Y	S, D, CAD, COPD, SS
23.	Scolozzi <i>et al.</i> 2012	Switzerland	72	F	N	N
24.	Giugliano <i>et al.</i> 2013	Italy	61	M	N	S
25.	Joel <i>et al.</i> 2013	India	60	F	N	S
26.	Misir <i>et al.</i> 2013	Turkey	55	M	N	NA
27.	Bouzoba <i>et al.</i> 2014	France	46	M	NA	S, T
28.	Dhupar <i>et al.</i> 2014	India	51	F	N	S
29.	Dirican <i>et al.</i> 2014	Turkey	75	F	N	RD
30.	Rajalakshmi <i>et al.</i> 2014	India	78	M	N	S, T, D
31.	Ates <i>et al.</i> 2015	Turkey	51	M	N	NA
32.	Kusunoki <i>et al.</i> 2015	Japan	77	M	Y	DM
33.	Mankapure <i>et al.</i> 2015	India	65	F	N	T, Betel nut
34.	Rajnikanth <i>et al.</i> 2015	India	60	M	N	HT
35.	Scheinder <i>et al.</i> 2015	USA	61	F	Y	S, HT, PVD, CAO, COPD.
36.	Butt <i>et al.</i> 2016	Africa	53	F	N	Goitre, Hysterectomy
37.	Cai <i>et al.</i> 2016	China	63	F	Y	S
38.	Cai <i>et al.</i> 2016	China	71	F	N	NA
39.	Gopal <i>et al.</i> 2016	India	63	F	N	N
40.	Nawale <i>et al.</i> 2016	India	71	M	NA	NA
41.	Nawale <i>et al.</i> 2016	India	59	F	NA	NA
42.	An <i>et al.</i> 2017	Korea	75	M	Y (SCC metastasis to lung)	NA

Table 1 cont.: Demographic data of patients with jaw bone metastasis from lung cancer as the sole primary source (1st December 1961 to 31st December 2021).

43.	Bisht <i>et al.</i> 2017	India	38	M	N	S
44.	Guarda-Nardini <i>et al.</i> 2017	Italy	59	F	N	S
45.	McKernon <i>et al.</i> 2017	UK	61	F	N	S
46.	Moraes <i>et al.</i> 2017	Brazil	66	M	Y	PC, Breast metastasis
47.	Pizzuto <i>et al.</i> 2017	Italy	65	M	N	S
48.	Pizzuto <i>et al.</i> 2017	Italy	65	F	N	S, BC
49.	Sharma <i>et al.</i> 2017	India	61	M	N	T
50.	Yanagisawa <i>et al.</i> 2017	Japan	84	M	N	S
51.	Hale <i>et al.</i> 2018	Chile	71	M	N	S, HT, BPH.
52.	Lin <i>et al.</i> 2018	Taiwan	65	F	N	N
53.	Mastuda <i>et al.</i> 2018	Japan	83	M	N	N
54.	Mondal <i>et al.</i> 2018	India	30	F	N	N
55.	Savithri <i>et al.</i> 2018	India	64	F	N	N
56.	Teyateeti <i>et al.</i> 2018	Thailand	72	M	N	S, BP, Psoriasis.
57.	Bonacina <i>et al.</i> 2019	Italy	77	M	N	S
58.	George <i>et al.</i> 2019	India	68	M	N	S, A
59.	Karpathiou <i>et al.</i> 2019	Greece	69	M	N	NA
60.	Picot <i>et al.</i> 2019	France	58	M	N	S
61.	Chebil <i>et al.</i> 2020	Tunesia	57	M	N	S, CAS, MI
62.	Gulmez <i>et al.</i> 2020	Turkey	75	M	N	S, HT, DM.
63.	Johnson <i>et al.</i> 2020	USA	66	M	N	S
64.	Tamgade <i>et al.</i> 2020	India	41	M	N	G
65.	Mateus <i>et al.</i> 2021	Portugal	64	F	N	Leukaemia
66.	Patait <i>et al.</i> 2021	India	59	M	N	S, T, Gutkha

A: Asbestos, BC: Breast cancer, BP: Bell's Palsy; BPH: Benign prostate hypertrophy; CAS: Carotid artery stenosis; CAO: Carotid artery occlusion; COPD: Chronic obstructive pulmonary disease, D: Drinking, DM: Diabetes mellitus; F: Female, HT: Hypertension, IHD: Ischaemic heart disease; M: Male, MI: Myocardial infarction, N: No, NA: Not available, PC: Prostate cancer, PVD: Peripheral vascular disease, RD: Renal disease, S: Smoking, SCC: Squamous cell carcinoma, SS: Septic shock, T: Tobacco, TA: Takayasu's Arteritis, UK: United Kingdom, USA: United states of America, Y: Yes.

8), USA (n-8), Italy (n-5), and Japan (n-4). The patients' average age was 62.9 years (range 30-84 years). Mean age was 65.5 years in males and 60.9 years in females, with a range of 38-84 years and 30-75 years for males and females, respectively. 12 of the 66 patients (18%) had a previous history of LC, while the other 47 (71.2%) had none. 26 patients had a habit of smoking (39.3%), 5 had tobacco chewing habit (7.5%), 2 had drinking (3%) and 1 (1.5%) was having betel nut chewing habit. Many other underlying comorbidities were also associated. JBM was observed maximum in mandible (n-45), followed by maxilla (n-13) and Temporomandibular joint (TMJ) (n-8). Left side of mandible predominated as compared to right side and the right side of the maxilla was more involved than the left side (5 and 3 cases respectively). One case occurred bilaterally. Metastasis was seen more in the posterior region of the maxilla as well mandible. In 3 cases, this site involvement was not clear.

Out of 13 maxillary cases, 4 occurred in the maxillary sinus (MS), with right sided predilection (n-3). Condylar region of TMJ was affected in 8 cases, with 4 cases on right side and 3 on left side. In 1 case, no site was given. Out of 66 cases, 57 patients (86.3%) reported with a chief complaint related to oro-dental health, while 9 (13.7%) had reported with other chief complaints. 11 patients (16.6%) had a previous history of extraction. Patients presented with variable radiographic and clinical features (Table 4-4 cont.-1). JB was the initial site of metastasis in 47 individuals. (71.2%), while in 15 patients (22.7%), it was detected after diagnosis of LC. JB was the only site of metastasis from LC in 32 cases (48.4%), whereas 25 cases (37.8%) exhibited other parts of the body also. 35 cases (53%) showed ipsilateral metastasis, while 12 had contralateral (18%), and 4 had bilateral (6%). The average time of development of JBM from diagnosis of LC was few days to 10 years. The most

Table 2: Clinical details of patients with jaw bone metastasis from lung cancer (1st December 1961 to 31st December 2021).

P.No	Jaw involved	R/L	A/P	Chief complaint at time of presentation	Clinical features	Radiographic features	PD	FD	SOLC	JAISOM	AOSOM
1.	Mand	NA	NA	Pain in lower jaw since few days	EO: NAD IO: Symptoms mimicking gumboil	Plain R/G: Ill-defined lytic area	NA	AD	NA	Y	N
2.	Max	L	A	Pain in upper facial region since 1 month	EO: Painful swelling IO: Painful swelling	Plain R/G: Ill-defined lytic area	NA	LCLC	L	NA	NA
3.	TMJ	NA	Co	Pain in TMJ region	EO: NAD IO: Pain, Clicking sounds, symptoms	NA	TMJ Dysfunction syndrome	AD	NA	Y	NA
4.	TMJ	R	Co	Facial swelling, pain, limited jaw movement	EO: Deviation of jaw towards right side IO: Poor oral hygiene	CT: Erosion of right condyle	Primary bronchus carcinoma with secondary condylar deposits	SCC	R	Y	N
5.	Mand	R	P	Painful swelling of right submandibular region, diplopia, headache.	EO: Painful swelling IO: firm swelling	Plain R/G: irregular RL with ill-defined borders	Maxillary sinus polyp	AD	L	Y	Y (V, Max, Sacrum)
6.	Max	R	Max sinus	Bloody sputum, epistaxis, headache	EO: NA IO: NA	CT: Dense soft tissue mass	NA	AD	R	N (1 month AD-OLC)	Y (Nasopharynx, other PNS)
7.	Mand	L	A	Numbness over the left lip, chin and submental area for several days	EO: NCS IO: NCS	OPG: lytic lesion CT: soft tissue mass	NA	AD	R	Y	N
8.	Mand	NA	A	Swelling in front lower jaw region.	EO: NA IO: Erythematous, tender, facial and gingival swelling.	Plain R/G: Poorly defined OL lesion, loss of LD, PF, CPD CT: CPD, inhomogeneous mass extending to soft tissues.	OM, MOT.	AD	NA	Y	N
9.	TMJ	L	Co	Pain in the left TMJ	EO: Pain and discomfort IO: NAD	CT: Solitary condylar mass	NA	AD	L	N (TNS)	N
10.	Mand	L	A	NA	EO: NA IO: Exophytic mass i.r.t.33.	NA	NA	NSCLC	NA	N (12 mo ADOLC)	Y (SNA)
11.	Mand	R	A	NA	EO: NA IO: Periapical swelling i.r.t.43	NA	PG	NSCLC	NA	N (12 mo ADOLC)	N

Table 2 cont.: Clinical details of patients with jaw bone metastasis from lung cancer (1st December 1961 to 31st December 2021).

12.	TMJ	R	Co	Pain and dislocation of the right TMJ	EO: Dislocation and sensitivity	CT, MRI:	NA	SCC	R	Y	N
13.	Mand	L	P	Pain	NA	NA	NA	AD	L	Y	N
14.	Mand	NA	NA	Pain in lower jaw	EO: NA IO: Painful swelling	NA	NA	AD	NA	Y	N
15.	Mand	R	P	Dyspnoea, cough, and weight loss	EO: NA IO: Swelling of R Mand Gingiva, mobile tooth (PM).	IOPA: RL involving radical apex of the PM	PG, Cystic lesion	SCLC	R	N (Following DOLC)	Y (V, Ri, Li)
16.	Mand	NA	NA	NA	NCS, swelling.	NA	NA	NEC	NA	NA	NA
17.	Mand	NA	NA	NA	NCS	NA	NA	NEC	NA	NA	NA
18.	Mand	NA	NA	NA	Loose teeth.	NA	NA	SCC	NA	NA	NA
19.	TMJ	L	Co	Pain and swelling in the left preauricular area for 1 month	EO: Pain and swelling, enlarged LN at clavicle. IO: Denture, no pain, normal occlusion.	OPG: Complete osteolysis of condyle CT: Mass replacing the condyle	TMJ disorder	SCLC	L	Y	Y(Li)
20.	Mand	R	P	Tooth pain and an abscess	EO: N IO: Abscess around 45, 46.	OPG: Bony defect on the mesial aspect of 46, bone resorption in the periapical regions of the 45, 46 extending to the buccal side.	OM, OI.	AD	R	Y	N
21.	Mand	L	NA	Numbness of the lower lip	EO: NA IO: NCS	OPG: PF in left mand.	NA	AD	L	Y	N
22.	Mand	R	NA	Cough and hoarseness for 1 month	EO: NCS IO: Paraesthesia	CT: OL	Osteoradionecrosis	SCLC	L	N (8 mo AD-OLC)	N

Table 2 cont.-1: Clinical details of patients with jaw bone metastasis from lung cancer (1st December 1961 to 31st December 2021).

	TMJ	L	Co	Pain in left TMJ, limited MO, and malocclusion of 3 months duration.	EO: left TMJ dysfunction, Pain, reduced MO. IO: Normal class I malocclusion.	OPG: Well circumscribed round to oval RL within the left condylar head CT, MRI: Large mass within the left condyle, bone erosion, infiltration into adjacent structures	TMJ Ant dislocation	LCLC	L	Y	Y (V)
23.											
24.	Mand	L	NA	Palpable mass on left side of lower jaw for 2 months	EO: Painful swelling. IO: NAD	CT: Bony lesion	OI	SCC	L	Y	N
25.	Mand	L	P	Worsening of breath, left chest pain	EO: NCS IO: NCS	BONE SCAN: Metastatic deposits	NA	AD	L	N (During diagnosis of LC)	Y (Sm)
26.	Mand	R	P	Pain and swelling at right lower jaw	EO: Swelling IO: Smooth surfaced non-tender lesion measuring about 2 × 2 cm at R Mand PM, M area, Paraesthesia.	OPG: ill-defined RL, OL of the right molar region under the inferior alveolar canal.	OI	AD	L	Y	N
27.	Mand	L	P	Pain in lower jaw for 2 months	EO: NA IO: NCS	OPG: RL lesion with blurred boundaries at the 44, 45 region. Dentascan: OL lesion with rupture of the lingual plate.	OI, MOT	AD	R	Y	Y (V, Fi)
28.	Mand	R	NA	Swelling and pain on right side of face.	EO: Facial asymmetry with a single diffuse firm, non-tender swelling over right preauricular area with shiny overlying skin. IO: Poor oral hygiene, carious teeth.	OPG: Ill-defined RL extending from sigmoid notch up to the lower border of mandible.	OM, SI, SGT, MOT	AD	R	Y	N
29.	Mand	R	NA	Pain and swelling in right lower jaw for several months.	EO: Swelling IO: Soft mass (5 cm × 7 cm).	NA	NA	AD	R	Y	Y (Li, Bone)

Table 2 cont.-2: Clinical details of patients with jaw bone metastasis from lung cancer (1st December 1961 to 31st December 2021).

	Mand	L	P	Swelling of left side of face, difficulty in MO for 4 months	EO: Diffuse, firm swelling over left body and angle of the Mand with normal overlying skin, palpable SM LN. IO: Decreased MO, restricted jaw movements, and grade 2 mobility in relation to 36, 37, and 38.	CT: OL lesion OPG, PA Skull: RL with irregular border at the left body and ramus of the mandible till condylar head. TMJ tomography: Osseous destruction	OS, MJT, OS, CS.	SCC	L	Y	N
30.											
31.	Max	R	MS	Pain and blurred vision in the left eye	NA	CT: Peripheral contrast enhancement in the vicinity of the anterior wall of right MS & posterior wall of the left bulbus oculi	NA	AD	R	Y	Y(Ocular)
32.	Max	R	NA	Pain in right alar region for 1 month	EO: Submucosal swelling with an intact and smooth surface in the right nasal vestibule close to the pyriform fossa edge of the right maxillary bone, wide destruction of Max bone. IO: NAD	CT: Round lesion in the right nasal vestibule close to the pyriform fossa edge of the right maxillary bone	NA	SCC	NA	N (3 mo AD-OLC)	Y (Nasal)
33.	Mand	L	P	Pain and swelling in lower left post region	EO: NAD IO: Firm, painful swelling	OPG: RL lesion around related teeth due to periodontal bone loss	NA	NA	L	Y	N
34.	Mand	R	P	Swelling in the right lower back teeth region of the jaw since 3 months	EO: Hard swelling on the right side of the mandible, and fixed to the underlying skin. Palpable right SM LN. IO: Firm, nontender swelling in the right mandibular premolar-molar region, Poor hygiene.	CT: Well-defined OL lesion involving the ramus and body of the right mandible, periosteal lesion with multiple irregular calcifications and extended into the lingual and mandibular soft tissues	OC, OT, IL	AD	R	Y	N

Table 2 cont.-3: Clinical details of patients with jaw bone metastasis from lung cancer (1st December 1961 to 31st December 2021).

	Mand	L	P	Left side jaw pain and swelling for 5 weeks	EO: Tender swelling, no lymphadenopathy. IO: Mobile tooth #18 associated with firm expansile mass palpated in buccal vestibule and FOM.	NA	NA	NEC	R	N (1.5 Yr ADOLC)	Y(Li)
35.	Mand	L	P	Left side jaw pain and swelling for 5 weeks	EO: Tender swelling, no lymphadenopathy. IO: Mobile tooth #18 associated with firm expansile mass palpated in buccal vestibule and FOM.	NA	NA	AD	L	Y	N
36.	Mand	L	P	Pain, swelling, limited MO and numbness over left intraoral region for 8 weeks	EO: Trismus, limited left condylar mobility, firm, tender swelling. IO: Paraesthesia	OPG, CT: OL lesion invading the adjacent tissues.	OS, MJT.	AD	L	Y	N
37.	Mand	NA	P	Pain	EO: Pain, swelling, numb chin IO: Paraesthesia	CT: OL lesion and periosteal reaction.	OS, MJT	AD	NA	N (TNS)	NA
38.	Mand	NA	P	Pain	EO: NA, IO: Exophytic growth	OPG: RL fibro osseous lesion	AM	AD	NA	Y	NA
39.	Max	L	P	Pain and swelling in left upper back tooth region for 2 months, HOE	EO: mild facial asymmetry in the left middle third of the face. IO: Diffuse, hard, tender swelling i.r.t 27, unhealed DS	IOPA- destruction of cortical bone and maxillary sinus floor	DS	AD	BL	Y	N
40.	Mand	NA	NA	NA	NA	NA	NA	AD	NA	Y	NA
41.	Mand	NA	NA	NA	NA	NA	NA	AD	NA	Y	NA
42.	Mand	R	Co	Pain in right TMJ, Limited MO	EO- Pain IO- MO reduced	OPG: Ill- defined bony destruction on the right condyle. CT: Ill-defined mass on right condylar head, bony destruction.	TMJ disorder	SCC	BL	Y	Y (Sm, Ri)
43.	Max	R	P	Swelling on right cheek for 4 months	EO: Diffuse swelling on right maxilla IO: Well-defined firm, solitary growth in the right maxillary gingiva buccal sulcus and alveolar region extending from mesial aspect of 14 to distal aspect of 17.	CT: Growth involving the upper gingiva buccal sulcus and the maxilla with bony destruction	NA	AD	BL	Y	Y (Li)

Table 2 cont.-4: Clinical details of patients with jaw bone metastasis from lung cancer (1st December 1961 to 31st December 2021).

	TMJ	R	Co	Pain and joint sounds in the right TMJ area	EO: Pain clicking sound. IO: Limited MO	CT- OL lesion, cortical plate destruction of the right condylar head.	TMJ disorder	AD	R	Y	N
44.				Pain and joint sounds in the right TMJ area	EO: Pain IO: Limited MO	CT- OL lesion, cortical plate destruction of the right condylar head.	TMJ disorder	AD	R	Y	N
45.	Mand	L	NA	Pain in left mandible for 5 months, HOE	EO: Pain IO: Pain	IOPA: poorly defined RL	NA	AD	R	Y	Y (Ad, SCLN)
46.	Mand	R	P	Pain in the right mandible over the past year, HOE	EO-NA IO- Bluish area located in the overlying mucosa of the edentulous alveolus of the R Mand (PMI).	OPG: Well defined, UL, oval RL with sclerotic borders.	RC	SCLC	NA	N (8 Y ADOLC)	N
47.	Max	R	NA	Dyspnoea along with chest pain	EO: Pain IO: Pain, ulcerative swelling	MRI- mass invading maxilla	NA	SCC	R	N (6 mo AD-OLC)	N
48.	Mand	R	NA	Dyspnoea along with chest pain	EO: NA IO: ulcerative growth, mobile teeth	CT: Huge mass involving with bone erosion, and also the soft tissue involvement.	NA	SCC	R	N (7 mo AD-OLC)	N
49.	Mand	R	P	Growth in the lower right posterior region of the jaw, since one month.	EO: NAD IO- Well-defined solitary, firm, non-tender, soft tissue growth with an erythematous ulcerated area extending from 43 to 47. No discharge.	OPG: Diffuse irregular RL with ragged borders in the right side body of the mandible in 46 region.	OS, MJT, OT	AD	R	Y	N
50.	Max	L	MS	Headaches, lethargy, fever, and facial swelling	EO: Facial swelling, oedematous nasal mucosa with necrotic debris	CT: extensive sinusitis involving the sphenoid, ethmoid, and MS, complete opacification of the nasal cavities and all PNS, Both sides.	NA	AD	L	N (8 mo AD-OLC)	Y (Nose, skull, Ri, sternum, V, Pe, Ti)
51.	TMJ	R	Co	Pain in right TMJ	EO: Firm, painful, poorly delimited, swelling with no skin involvement. IO: Partial edentulous, without alterations in oral soft tissues	OPG: Discrete OL in condyle CT: OL lesion involving condyle and TMJ	TMJ Disorder	AD	R	Y	N

Table 2 cont.-5: Clinical details of patients with jaw bone metastasis from lung cancer (1st December 1961 to 31st December 2021).

	Max	R	Max sinus	Discomfort at the right maxillary posterior region for 1 month. HOE	EO: Pain IO: Healing sockets	OPG: Cloudiness of the right maxillary sinus	NA	NSCLC	L	Y	N
52.	Mand	R	P	Pain, difficulty in opening mouth	EO: Painful swelling, Facial asymmetry, mandibular deviation toward the right side IO: NA	OPG: Bone destruction of the right mandibular ramus and the condylar process.	OS, MJT	AD	R	Y	Y (Spine, Brain, LN)
53.	Mand	L	P	Weight loss, pain in left TMJ, difficulty in MO, eye proptosis	NA	CT: Mass in left ramus	NA	SCC	L	Y	Y (Orbit, Sm)
54.	Mand	R	P	Pain in the chin region for the past 3months	EO: Facial asymmetry, paraesthesia of LL and chin IO: Diffuse swelling obliterating the labial vestibule from 41 to 44 region, healed sockets	OCCLUSAL: Expansion of buccal cortical plate with irregular bone loss	OM, OS, MJT.	AD	R	Y	Y (Li, Ki, V, Fe, Ri)
55.	Mand	L	A	Numbness of left lower lip for few months.	EO: Decreased sensation, decreased skin fold below left chin. IO: NCS	CT: Soft tissue mass with bony destruction	NA	AD	L	Y	Y (V, Ri, Pe, Brain)
56.	Max	L	P	Pain and bleeding from the upper jaw	IO: Ulcerated polypoid exophytic lesion	CT: CT: lesion with bone erosion	NA	AD	R	Y	Y (Ri, Scapula,)
57.	mand	R	NA	Swelling over the right side of the mandible of one month's duration, HOE	EO: Bony hard painful swelling, normal underlying skin with paraesthesia of lip IO: Edentulous, Tender alveolar mucosa	OPG: Large RL with irregular borders	OT, MJT	AD	R	Y	N
58.	Mand	L	NA	Shortness of breath for 10 days	EO: Facial swelling	CT: PF of the left mandible, soft tissue mass with swelling of the adjacent muscles	NA	MEC	L	Y	Y (V)
59.	Mand	L	A	Mandibular tumefaction occurring 1 month	IO: Ulcerated, painful, and nodular lesion	OPG- OL lesion with bone erosion	NA	AD	R	N (1yr ADOLC)	Y ((Ad, Scapula, Fe)

Table 2 cont.-6: Clinical details of patients with jaw bone metastasis from lung cancer (1st December 1961 to 31st December 2021).

61.	Mand	L	P	Diffuse left buccal swelling evolving for a week	EO: Painless tough mass on the left mandibular ramus, trismus, NCS. Normal overlying skin, BL SMG lymphadenopathy. IO: Poor oral hygiene	OPG: RL with enlargement of the mandibular foramen CT: OL lesion.	OS, Cellulitis	AD	R	Y	N
62.	Max	R	NA	Cough and shortness of breath for 2 months	EO: Swelling IO: NA	CT: Soft tissue mass	NA	SCC	L	Y	Y (Li, hand, pe)
63.	Mand	L	P	Left-sided mandibular pain, HOE	EO: NA IO: NCS	CT: Focal area of moth-eaten bony architecture	OM	ADD	L	Y	Y (Li, Ad, LS, V)
64.	Max	L, R	A	Mobile teeth, pain, swelling in upper jaw	IO: Inflamed gingiva in 11 and 12, BOP, mild non-tender swelling, cortical plate expansion.	IOPA, OPG: OL lesion	NA	AD	BL	Y	N
65.	Mand	L	P	Painful swelling in left back jaw.	EO: Pain IO: Pain, no lesion	CT: expansive and erosive lesion of the left ramus with central necrosis.	NA	AD	R	Y	N
66.	Max	R	P	Pain and swelling over right side of face since past 1 month, HOE	EO: Soft, tender, diffuse swelling. Palpable right submandibular lymph node fixed to underlying structures. IO: Bright red, soft, tender, indurated, oval proliferative, ulcerative growth	OPG: OL lesion, loss of LD CBCT: OL lesion, destruction of MS wall	NA	AD	R	Y	N

A: Anterior, Ad: Adrenals, AD: Adenocarcinoma, ADOLC: After diagnosis of lung cancer, ADOM: After diagnosis of metastasis, AM: Ameloblastoma, AOSOM: Any other site of metastasis, BL: Bilateral, CBCT: Cone beam computerized tomography, Co: Condyle, CPD: Cortical plate destruction, CS: Chondrosarcoma, CT: Computerized tomography, DS: Dry socket, EO: Extraoral, FD: Final diagnosis, Fe: Femur, Fi: Fibula, JAISOM: Jaw as initial site of metastasis, HOE: History of extraction, IL: Inflammatory lesion, IO: Intraoral, IOPA: Intraoral periapical, Ki: Kidney, L: Left, LCLC: Large cell lung cancer, LD: Lamina dura, Li: Liver, LN: Lymph node, LS: Lumbar spine, M: Molar, Mand: Mandible, Max: Maxilla, mo: months, MJT: Malignant jaw tumor, MEC: Mucoepidermoid carcinoma, MO: Mouth opening, MOT: Malignant odontogenic tumor, MRI: Magnetic resonance imaging, MS: Maxillary sinus, N: No, NA: Not available, NAD: No abnormality detected, NCS: Numb chin syndrome, NEC: Neuroendocrine carcinoma, NSCLC: Non-small cell lung carcinoma, OC: Odontogenic cyst, OL: Odontogenic infection, OL: Osteolytic, OM: Osteomyelitis, OPG: Orthopantomogram, OS: Osteosarcoma, OT: Odontogenic tumor, P: Posterior, PA: Periapical, PD: Provisional diagnosis, Pe: Pelvis, PF: Pathological fracture, PG: Pyogenic granuloma, PM: Pre-molar, PNS: Paranasal sinus, P. No: Patient number, R: Right, RC: Residual cyst, R/G: Radiograph, RL: Radiolucency, Ri: Ribs, SCC: Squamous cell carcinoma, SCLC: Small cell lung cancer, SCLN: Supraclavicular lymph nodes, SI: Space infection, SGT: Salivary gland tumor, SM: Submandibular, Sm: Skeletal muscles, SNA: Site not available, SOLC: Site of lung cancer, Ti: Tibia, TMJ: Temporomandibular joint, TNS: Time not stated, UL: Unilocular, V: Vertebrae: Y: yes.

Table 3: Data describing treatment and prognosis of patients with jaw bone metastasis from lung cancer (1st December 1961 to 31st December 2021).

Patient Number	Treatment given	Prognosis and follow up	Cause of death
1.	NA	NA	NA
2.	NA	NA	NA
3.	Surgery	NA	NA
4.	Radiotherapy	Death (12 weeks. ADOM)	Bronchopneumonia
5.	Chemotherapy, Radiotherapy	Favorable	-
6.	Radiotherapy	Death (5 mon ADOM)	Brain hemorrhage
7.	Radiotherapy	NA	NA
8.	NA	NA	NA
9.	Radiotherapy	Systemic metastasis	NA
10.	Supportive	Death (4 mon ADOM)	Multiple metastasis
11.	Chemotherapy	Death (1 mon ADOM)	Multiple metastasis
12.	Chemotherapy, Radiotherapy, Surgery	Death (Few mon ADOM)	Multiple metastasis
13.	NA	NA	NA
14.	Chemotherapy, Radiotherapy	Death (Appx 2 mon ADOM)	NA
15.	Chemotherapy	Death (9 mon ADOM)	Relapse of lung cancer
16.	Radiotherapy	NA	NA
17.	Radiotherapy	NA	NA
18.	Radiotherapy	NA	NA
19.	Chemotherapy	Death (Few weeks. ADOM)	Lung infection
20.	Surgery	Death (12 mon ADOM)	Multiple metastasis
21.	Declined by patient	-	-
22.	Amrubicin	Partial relief	-
23.	Radiotherapy	Death (6 mon ADOM)	NA
24.	Radiotherapy	Treatment going on	-
25.	Chemotherapy	Death (17 mon ADOM)	NA
26.	Chemotherapy	Recurrence, lost to follow up	-
27.	Surgery	NA	NA
28.	Chemotherapy	Lost to follow up	-
29.	Chemotherapy, Radiotherapy	Death (2 mon ADOM)	Chronic renal failure
30.	Referred to oncologist	Death (4 mon ADOM)	NA
31.	Chemotherapy	NA	NA
32.	Radiotherapy, Surgery	Death (Appx 10 mon ADOM)	Multiple metastasis
33.	Chemotherapy, Radiotherapy	NA	NA
34.	NA	NA	NA
35.	Radiotherapy	Death (2 mon ADOM)	Multiple metastasis
36.	Chemotherapy, Radiotherapy	NA	Disseminated condition
37.	Chemotherapy, Radiotherapy, Surgery	Death (12 mon ADOM)	NA
38.	Chemotherapy, Radiotherapy, Surgery	Death (8 mon ADOM)	NA
39.	Chemotherapy, Radiotherapy	Favourable (under follow up)	-
40.	Surgery	NA	NA

Table 3 cont.: Data describing treatment and prognosis of patients with jaw bone metastasis from lung cancer (1st December 1961 to 31st December 2021).

41.	Surgery	NA	NA
42.	Chemotherapy, Radiotherapy	Favourable	-
43.	Chemotherapy, Radiotherapy	Treatment going on	-
44.	Chemotherapy, Radiotherapy	Death (13 mon ADOM)	Disseminated condition
45.	Referred to oncologist	NA	NA
46.	Chemotherapy	Favourable	Disseminated condition
47.	Radiotherapy	Death (0.5 mon ADOM)	Pleural effusion, acute lung failure
48.	Surgery	(Death (1 week ADOM)	Pleural Effusion
49.	Radiotherapy	Lost to follow up	NA
50.	Chemotherapy	Death (Several Weeks. ADOM)	Intracranial haemorrhage
51.	Referred to oncologist	Death (2 mon ADOM)	Multiple organ failure
52.	Chemotherapy, Radiotherapy	Death ((2 mon ADOM)	Respiratory Failure
53.	Chemotherapy	Favourable	-
54.	Chemotherapy, Radiotherapy	Death (10 mon ADOM)	Multiple metastasis
55.	Radiotherapy	Death (7 mon ADOM)	Multiple metastasis
56.	Chemotherapy, Radiotherapy	Death (7 mon ADOM)	Deep vein thrombosis
57.	Radiotherapy	NA	-
58.	Chemotherapy, Radiotherapy	Treatment going on	
59.	NA	NA	-
60.	Surgery, Targetoid therapy	Death (2 mon ADOM).	Multiple metastasis
61.	Chemotherapy	Death (5 mon ADOM)	Disseminated condition
62.	Not given	Lost to follow up	Multiple metastasis
63.	Radiotherapy	Treatment going on	-
64.	NA	NA	NA
65.	Chemotherapy	Death (8 mon ADOM)	Disseminated condition
66.	NA	NA	NA

ADOM: After diagnosis of metastasis, mon: Months, NA: Not available

common type of LC diagnosed was Adenocarcinoma (n-40), followed by Squamous cell carcinoma (n-11). The most common treatment aids included radiotherapy (n-15), chemotherapy (n-12), and Surgery (n-6). In several cases, combined therapy was used. Even after treatment, 29 individuals (44%) died. The period between JBM diagnosis and death ranged from 1 week to 1.5 years. Results are summarized in Table 4-4 cont.-1.

Discussion

Metastasis to the oral cavity is a rare occurrence, with the real incidence unclear (1-2% of all oral cancers) (47). Because of their rarity, they are sometimes overlooked for a long time before being discovered and are diagnosed during investigations (48). According to epidemiological investigations, LC is the most common primary source of oral soft tissue metastasis, while Breast cancer

is the most common source of JBM.(5) However, a few cases of JBM from LC have been recorded in the literature. In this study, we found 66 documented cases of JBM from LC.

Studies reveal that JBM affects both genders equally. In certain studies, however, a male majority was found (49). In the current study also, there was a little male predominance, with M: F =1.4:1. JBM can strike at any age, with peak incidence in 4th-7th decades (50). The patients in this study ranged in age from 3rd-8th decade. According to researchers, smoking and tobacco consumption habits are strongly linked to the development of LC (51). Nicotine and its derivatives, which are found in tobacco and smoke, help to promote the expression of oncogenic proteins which leads to the spread of LC (52). And because these habits are more prevalent in males, they are more likely to develop LC. People with

Table 4: Summary of results documented from literature research describing the characteristics of jaw bone metastasis from lung cancer (1st December 1961 to 31st December 2021).

Feature	Number
Total number of papers published	60 (CR=52, RA=4, LTE=3,Co=1)
Total number of patients	66
World-wide distribution of cases	India =15 (22.7%) Turkey=8 (12.1%) United states of America =8 (12.1%) Italy=5 (7.5%) Japan =4 (6%) China=3 (4.5%) Israel =3 (4.5%) France =3 (4.5%) Korea =2 (3%) Brazil =2 (3%) Taiwan=2 (3%) Switzerland=2 (3%) United Kingdom =2 (3%) Germany=1 (1.5%) Portugal=1 (1.5%) South Africa=1 (1.5%) Chile=1 (1.5%) Greece=1 (1.5%) Thailand=1 (1.5%) Tunisia=1 (1.5%)
Gender	M=37 (56%) F=25 (38%) NA=4 (6%)
Average age of patients (Range)	62.9 Years. (30-84)
Average age of male patients (Range)	65.5 Years. (30-84)
Average age of female patients (Range)	60.9 Years. (30-75)
Previous history of Lung cancer	12 (18%)
No previous history Lung cancer	47 (71 %)
NA data of previous history of Lung cancer	7 (10.6%)
Associated risk factors	36 (54.5%) Smoking=26 (39.3%) Tobacco chewing=5 (7.5%) Cardiac=6 (9%) Drinking=2 (3%) Respiratory=2 (3%) Renal=2 (3%) Diabetes mallitus=1 (1.5%) Betel nut=1 (1.5%) Others =5 (7.5%)
No risk factors	12 (18%)
NA data of associated risk factors	18 (27.2%)
Chief complaint related to oral health	57 (86.3%)
Chief complaint not related to oral health	9 (13.7%)
History of extraction	11 (16.6%)
No. of cases involving Mandible	Total- 45 (68.1%) R/L: (R=16, L=19, NA=10) A/P : (A=7, P=22, NA=16)

Table 4 cont.: Summary of results documented from literature research describing the characteristics of jaw bone metastasis from lung cancer (1st December 1961 to 31st December 2021).

No. of cases involving Maxilla	Total=13 (19.7%) R/L: (R= 5, L=3, BL=1) A/P: (A=2, P=4, NA=3) Maxillary Sinus=4 (6%) (R=3, L=1)
No. of cases involving temporomandibular joint	Condyle=8 (12%) (R=4, L=3, NA=1)
Jaw as initial site of metastasis	Yes=47 (71.2%) No=15 (22.7%) NA=4 (6.1%)
Jaw as only site of metastasis	Yes=32 (48.4%) No=25 (37.8%) NA=9 (13.6%)
Average time of detection of metastasis from diagnosis of Lung cancer	Few days to 10 Years.
Clinical features	Swelling=30 (45.4%) Pain=14 (21.2%) NCS=14 (21.2%) Mobile teeth=6 (9%) Paraesthesia= 6 (9%) Trismus =6 (9%) Facial asymmetry=6 (9%) Poor oral hygiene=6 (9%) Exophytic =4 (6%) Clicking sounds= 3 (4.5%) Unhealed sockets=3 (4.5%) Ulcerated growth=3 (4.5%) Lymphadenopathy=3 (4.5%) Jaw deviation=2 (3%) Abscess=1(1.5%) Bluish area=1(1.5%) NA=6 (9%)
Radiographic features	Radiolucent / Osteolytic =30 (45.4%) Bone erosion/ destruction=15 (22.7%) Soft tissue mass=13 (10%) NA=12 (18%)
Side of lung metastasis	Ipsilateral=35 (53%) Contralateral=12 (18%) Bilateral=4 (6%) NA=15 (22.7%)
Type of lung cancer	Adenocarcinoma = 40 (60.6%) Squamous cell carcinoma = 11 (16.6%) Small cell lung cancer = 4 (6.1%) Neuroendocrine carcinoma = 3 (4.5%) Non-small cell lung cancer = 3 (4.5%) Large cell lung cancer=3 (4.5%) Mucoepidermoid carcinoma=1 (1.5%) NA=1 (1.5%)

Table 4 cont.-1: Summary of results documented from literature research describing the characteristics of jaw bone metastasis from lung cancer (1st December 1961 to 31st December 2021).

Treatment aids	Radiotherapy=15 (22.7%) Radiotherapy + Chemotherapy =14 (21%) Chemotherapy=12 (18%) Surgery=6 (9%) Chemotherapy+ Radiotherapy+ Surgery=3 (4.5%) Surgery +Targetoid =1 (1.5%) Drug therapy=1 (1.5%) Supportive=1 (1.5%) Not Given=1 (1.5%) Declined by patient=1 (1.5%) NA=7 (10.6%)
Death	29 (44%)
Average time of death from diagnosis of jaw bone metastasis	1 Week- 1.5 Years
Most common cause of death	Multiple metastasis=10 (34.4%) Disseminated condition =5 (17.2%) Pleural effusion=2 (6.8%) Acute lung failure=2 (6.8%) Lung infection=1 (3.4%) Deep vein thrombosis=1 (3.4%) Multiple organ failure=1 (3.4%) Bleeding =1(3.4%) Brain haemorrhage=1 (3.4%) NA=6 (20.6%)
Partial relief of symptoms	1 (1.5%)
Favourable prognosis	5 (7.5%)
Treatment going on	4 (6.1%)
Lost to follow up	3 (4.5%)

A: Anterior, BL: Bilateral; CR: Case report, Co: Correspondence, F: Female, L: Left, LTE: Letter to editor, M: Male, NA: Not available, P: Posterior, R: Right, RA: Retrospective analysis

underlying comorbidities and lung disorders such as lung disorders, such as ‘chronic obstructive pulmonary disease’ are more likely to acquire LC and have a worse prognosis as a result of distant metastasis induced by a weakened immune system (50). 3% individuals in this study had respiratory comorbidities. Other most prevalent comorbidities were cardiac, renal, and endocrinal (Table 4-4 cont.-1).

LC has increased in emerging countries such as India, China, Brazil, and others in recent years due to increasing smoking, drinking, and tobacco chewing habits. While in the developed and industrialized countries, the incidence rate has fallen down due to recession of these habits (52). However, the specific regional distribution of JBM from LC has not been reported in the literature. In our study, India had the highest number of cases of JBM from LC followed by Turkey and USA. Various other regions were also involved (Table 4-4 cont.-1). Looking at this data, wide region involvement of JBM from LC can be appreciated.

Pathogenic mechanisms of JBM aren’t completely understood. Metastasis is a multistage process that in-

volves tumour cells being detached from their originating site and being transported to a secondary site via lymphatic or hematogenous channels (53). One of the proposed pathways is the “Batson’s plexus,” a valveless prevertebral venous plexus network that involves retrograde tumour cell movement from the lungs to the face (54). Another method of metastasis in LC involves direct suction, access to the pulmonary vein, and drainage to the left side of the heart (55). Because the JB does not have lymphatic capillaries, hematogenous metastasis is the most prevalent route here. Rich capillary network act as the milieu for the localization of tumour cells. Metastatic foci are more common in red bone marrow than fatty marrow, which allows for greater trapping of metastatic cells due to slow regulation of blood flow control. Red bone marrow also contains growth factors that may help some metastatic tumours cells to colonise faster. JBM is more common in the mandible (posterior area notably the body (premolar-molar region), angle, and ascending ramus) than in the maxilla, owing to the existence of abundant red marrow in the mandible, whereas the maxilla contains mostly fatty marrow (49). Similar

results were documented in the current research, with mandibular predominance of JBM and the posterior side was more affected in both jaws.

LC spread to the paranasal sinuses (PNS) is rare (56). Joel *et al.* discovered that the MS were the most common site of metastasis among the PNS (57). The route of metastasis at this region is also suggested to be through hematogenous spread and Batson's plexus system (58). TMJ is a rare location of metastasis that usually arises in the late stages of a cancer that is connected with skeletal metastasis. According to Irani *et al.*, TMJ and condylar involvement were the least common among the JBM (49). Only 8 cases of metastatic LC affecting the TMJ and condyle were found in the current research. The exact cause of the uncommon occurrence of metastasis in the condylar region is unknown, however is thought to be owing to poor red marrow and a deficit blood flow from the maxillary and temporal arteries. Furthermore, the presence of a bone plate in the condylar region may limit tumour cell proliferation, resulting in decreased tumour cell entrapment (39).

JBM is more difficult to diagnose than soft tissue lesions for the following reasons.

1. They seem similar to squamous cell carcinoma, the most frequent malignant tumour of the jaws.
2. The lesions are placed in the centre of the bone.
3. Unless the disease is advanced, the patient has little subjective symptoms.
4. Lesion radiographs are frequently non-specific.

However, it is possible that the seeming rarity is due in part to a failure to recognise metastatic tumours in the jaws. Furthermore, because the jaws are not frequently inspected at autopsy, some abnormalities may be missed. As a result, the true incidence of metastatic tumours in the jaws may be higher.

Patients with JBM present with asymptomatic lesions to a wide variety of symptoms. The most common symptoms are numb chin syndrome (NCS) or mental nerve neuropathy. Pain, swelling, and tooth loosening are other typical symptoms. Current review revealed that patients presented with variable symptoms (Table 4-4 cont.-1). The post-extraction site is regarded as one of the particular JBM sites. Kaugers *et al.*, observed a substantial link between trauma and oral metastasis. It backed up the seeding hypothesis, which states that cells from the lungs collect in traumatic sites via sputum, and that these traumatised areas operate as a breeding ground for cancer cells, leading to distant metastases. In our research, we could find only 11 individuals with history of teeth extraction.

JBM is difficult to diagnose since the lesions mimic various inflammatory disorders of the jaw, periapical lesions, odontogenic lesions, malignant jaw tumours. TMJ metastasis can be misinterpreted as TMJ problems. Many cases in the current study were given a prelimi-

nary diagnosis of odontogenic tumours, osteomyelitis, malignant tumours of the jaw, salivary gland tumours, and so on. Clinicians must be aware of problems that could result in a misdiagnosis. History of LC could help in the detection of secondary metastatic cancer. JBM via LC is a late indication. 18% of the patients in this research were aware of previous LC, whereas 71% had no such history.

JB metastatic tumours are of high clinical importance because, they may be the only symptom of an undiagnosed underlying malignancy or the first sign of the metastasis. In our study, appx 71% patients had evidence of metastasis as the initial symptom of the disease.

Radiographic characteristics of JBM are not pathognomonic. The type of contact between tumour cells and the bone microenvironment can lead to osteolytic or osteoblastic lesions. Most malignancies are characterised by osteolysis. Osteoblastic lesions are uncommon like caused by prostate cancer (58). Certain tumours can cause reactive new bone development, resulting in a mixed radiopaque and radiolucent lesion. To identify the amount of soft tissue involvement and other sites of distant metastasis in the body, computerized tomography (CT) and magnetic resonance imaging (MRI) are required. 45.4% lesions in the current study manifested as osteolytic, with ill-defined radiolucency.

Histopathological examination is required to provide a conclusive diagnosis of the type of JBM. However, it might be difficult to make an exact diagnosis because these lesions have a varied histological appearance rather than a distinct picture. When the major focus of the primary metastatic site is known, diagnosing the secondary metastasis can be simple. Other tools, such as special staining, immunohistochemistry, and electron microscopy, may be necessary in some circumstances to determine the initial tumor's nature.

Many new entities of LC have recently been introduced to the World Health Organization (WHO) classification system 2015 (59). Adenocarcinoma has been discovered to be the most prevalent type of LC that metastasizes to the JB. And same was the finding in this study as well. Mucoepidermoid carcinoma is a salivary gland cancer that seldom spreads to the lungs. Only 1 such case has been documented in the current research (60).

Although LC entails multiorgan distant metastases, JB might occasionally be the only site of metastasis. Out of 66 instances in this study, 32 had JB as the only location of LC metastasis, whereas 25 had metastasis to other parts of the body as well such as brain, kidney, adrenal, liver, vertebrae, spine, pelvis, skin, ocular, and skeletal muscles. JBM treatment and prognosis are determined by the site of genesis and the extent of the disease. Treatment options include biopsy, local excision, chemotherapy, radiotherapy brachytherapy, and/or combination therapy. Commonly used therapeutic aids in this study were radiotherapy,

chemotherapy, surgery and combined therapy. Unfortunately, JBM by LC has a bad prognosis with a maximum survival rate of 5 years. Even after treatment, 44% people died, according to the current study. 5 patients had a good prognosis with no signs of recurrence.

Limitations of the current study

One of the limitations of current research was small sample size. Most of studies included were case reports and case series. Population based analysis was not included. We excluded epidemiological, case control studies because we also aimed to evaluate individual features of these metastatic lesions. And in those studies, individual data of patients was not available.

Conclusions

During the last 60 years (December 1961-December 2021), we found only 66 published cases of LC metastasis to JB, according to our research. These findings suggest that LC metastasis to JB is a rare occurrence. The prognosis was poor with a survival rate of 1 week to 1.5 years. Metastasis of LC predominantly involved mandible than maxilla. The most prevalent type of LC diagnosed was Adenocarcinoma. Because of their resemblance to other jaw problems and late clinical signs, these lesions go unnoticed the majority of the time. Diagnosis of JBM is a challenging task for the clinicians, and pathologists. A thorough examination of the metastatic lesions is required, including a review of the patient's medical history, clinical presentation, and early diagnosis in order to identify the primary site of metastasis and choose the best course of treatment. More cases need to be published in order to raise awareness of these lesions and gain a better understanding of their characteristics.

References

1. World Health Organization, International Agency for Research on Cancer. Globocan 2020: Lung Cancer. International Agency for Research on Cancer. Available at <http://gco.iarc.fr/today/data/factsheets/cancers/15-Lung-fact-sheet.pdf>. Accessed: March 2, 2021.
2. Burring SS, Peake MD. Symptoms and the early diagnosis of lung cancer. *Thorax*. 2005;60:268-9.
3. Popper HH. Progression and metastasis of lung cancer. *Cancer Metastasis Rev*. 2016;35:75-91.
4. Tsuya A, Kurata T, Tamura K, Fukuoka M. Skeletal metastases in non-small cell lung cancer: a retrospective study. *Lung Cancer*. 2007;57:229-32.
5. Irani S. Metastasis to the Jawbones: A review of 453 cases. *J Int Soc Prev Community Dent*. 2017;7:71-81.
6. Moss RL. Metastasis of bronchogenic carcinoma to the mandible. Report of a case. *Oral Surg Oral Med Oral Pathol*. 1961;14:1501-9.
7. Ciola B, Yesner R. Radiographic manifestations of a lung carcinoma with metastases to the anterior maxilla. *Oral Surg Oral Med Oral Pathol*. 1977;44:811-6.
8. Compère JF, Deboise A, Bertrand JC, Peron JM, Auriol M, Guilbert F, et al. Mandibular condyle metastasis : report of three cases. *Rev Stomatol Chir Maxillofac*. 1981;82:357-60.
9. Peacock TR, Fleet JD. condylar metastasis from a bronchogenic carcinoma. *Br J Oral Surg*. 1982;20:39-44.
10. Huang YL, Lin LM, Yan YH, Chao TC, Shen YS, Lin CC, et al.

- Bronchogenic carcinoma metastatic to the mandible--report of a case. *Gaoxiong Yi Xue Ke Xue Za Zhi*. 1986;2:478-85.
11. Ii T, Doutsu Y, Ashitani J, Taniguchi H, Shima T, Sakamoto A, et al. A case of pulmonary adenocarcinoma in a young man with multiple metastasis to the nasopharynx and paranasal sinuses. *Nihon Kyobu Shikkan Gakkai Zasshi*. 1992;30:1884-8.
12. Marinella MA. Metastatic large cell lung cancer presenting with numb chin syndrome. *Respir Med*. 1997;91:235-6.
13. Kaufmann MG, Perren A, Grätz KW, Eyrieh GK. Condylar metastasis. Review of the literature and report of a case. *Mund Kiefer Gesichtschir*. 2005;9:336-40.
14. Bodner L, Sion-Vardy N, Geffen DB, Nash M. Metastatic tumors to the jaws: a report of eight new cases. *Med Oral Patol Oral Cir Bucal*. 2006;11:E132-5.
15. Yasar F, Oz G, Dolanmaz D, Akgünlü F. Mandibular metastasis in a patient with pulmonary adenocarcinoma. *Dentomaxillofac Radiol*. 2006;35:383-5.
16. Pereira-Filho VA, Chaves MD, Haddad J, Gabrielli MF, Gabrielli MA, Hochulli-Vieira E, et al. Mandible metastasis as the first sign from primary adenocarcinoma of the lung. *Gen Dent*. 2007;55:224-7.
17. Jham BC, Salama AR, McClure SA, Ord RA. Metastatic tumors to the oral cavity: a clinical study of 18 cases. *Head Neck Pathol*. 2011;5:355-8.
18. Tabib R, Elias S, Tal Y, Ben-Yehuda A, Abu-Tair J. Temporomandibular joint-related symptoms as initial presentation of lung carcinoma in a patient with Takayasu's arteritis. *J Oral Maxillofac Surg*. 2011;69:226-9.
19. Tatlidil R, Gözübüyük MM. Mucinous adenocarcinoma of lung presenting as oral metastases: a case report and literature review. *J Endod*. 2011;37:110-3.
20. Zhang FG, Hua CG, Shen ML, Tang XF. Primary tumor prevalence has an impact on the constituent ratio of metastases to the jaw but not on metastatic sites. *Int J Oral Sci*. 2011;3:141-52.
21. Abi-Fadel F, Smith PR, Ayaz A, Sundaram K. Paranasal sinus involvement in metastatic carcinoma. *J Neurol Surg Rep*. 2012;73:57-9.
22. Scolozzi P, Becker M, Lombardi T. Mandibular condylar metastasis mimicking acute internal derangement of the temporomandibular joint. *J Can Dent Assoc*. 2012;78:c77.
23. Giugliano FM, Alberti D, Guida G, Palma GD, Iadanza L, Mormile M, et al. Non small-cell lung cancer with metastasis to thigh muscle and mandible: two case reports. *J Med Case Rep*. 2013;7:98.
24. Joel A, Carey RA, Rajadoss JV, Chacko RT. Numb chin syndrome as a manifestation of non-small cell lung cancer. *South Asian J Cancer*. 2013;2:219.
25. Misir AF, Mercan U, Günhan O. Metastasis of lung adenocarcinoma to the mandible: Report of a case. *J Oral Maxillofac Pathol*. 2013;17:253-6.
26. Bouzoubaa S, Khazana M, Slimani F, Chekkoury EI, Benyahya I. Lung cancer reveal by mandibular metastasis: a case at the Centre of Consultation and Dental Treatment Dental of Casablanca (CCDTC). *Odontostomatol Trop*. 2014;37:40-6.
27. Dhupar V, Akkara F, Kamat RD, Shetye O. Mandibular metastasis from a pulmonary squamous cell carcinoma. *Ann Maxillofac Surg*. 2014;4:103-6.
28. Dirican N, Gunes S, Karakaya Y, Kaya V, Cerci S, Dirican A. Mandible bone metastases secondary to pulmonary adenocarcinoma. *Med Arch*. 2014;68:356-8.
29. Raja Lakshmi C, Sudhakara Rao M, Bhavana SM, Sathish S. Primary squamous cell carcinoma of lung leading to metastatic jaw tumor. *Case Rep Pulmonol*. 2014;2014:392616.
30. Ates I, Yazici O, Ates H, Ozdemir N, Zengin N. Unusual metastases of lung cancer: bulbus oculi and maxillary sinus. *Exp Oncol*. 2015;37:231-2.
31. Kusunoki T, Homma H, Kidokoro Y, Yanai A, Ikeda K, Wada R. A Case of Maxillary Bone Metastasis from Lung Cancer. *Clin Pract*. 2015;28:5:819.
32. Rajinikanth M, Prakash AR, Swathi TR, Reddy S. Metastasis of lung adenocarcinoma to the jaw bone. *J Oral Maxillofac Pathol*. 2015;19:385-8.

33. Schneider KM, Martinez AY, Guglielmi M. Large cell neuroendocrine carcinoma: topic review and a unique case of metastasis to the mandible. *J Maxillofac Oral Surg.* 2015;14:120-6.
34. Cai Z, Zhu C, Wang L, Zhu L, Zhang Z, Zhu H, et al. A retrospective study of six patients with mandibular metastatic carcinoma. *Oncol Lett.* 2016;11:3650-3654.
35. Nawale KK, Vyas M, Kane S, Patil A. Metastatic tumors in the jaw bones: A retrospective clinicopathological study of 12 cases at Tertiary Cancer Center. *J Oral Maxillofac Pathol.* 2016;20:252-5.
36. Guarda-Nardini L, Stellini E, Di Fiore A, Manfredini D. A Rare Case of Misdiagnosed Silent Lung Cancer with Solitary Metastasis to the Temporomandibular Joint Condyle. *J Oral Facial Pain Headache* 2017;31:180-185.
37. Pezzuto A, Morrone M, Mici E. Unusual jaw metastasis from squamous cell lung cancer in heavy smoker: Two case reports and review of the literature. *Medicine (Baltimore).* 2017;96:e6987.
38. Yanagisawa S, Miyauchi E, Ichinose M. Numb Chin Syndrome: An Ominous Sign of Lung Cancer. *J Thorac Oncol.* 2017;12:e114-e116.
39. Lin HY, Chiang CP, Wang YP, Yu-Fong Chang J. Metastatic lung carcinoma in the right maxilla. *J Formos Med Assoc.* 2018 ;117:1130-1132.
40. Matsuda S, Yoshimura H, Yoshida H, Umeda Y, Imamura Y, Sano K. Mandibular metastasis as the first clinical indication of occult lung adenocarcinoma with multiple metastases: A case report. *Medicine (Baltimore).* 2018;97:e0296.
41. Mondal D, Jana M, Julka PK, Roy S. Synchronous orbital and mandibular metastases from squamous cell carcinoma of lung as initial disease presentation in a young female: First report of a rare occurrence. *J Cancer Res Ther.* 2018;14:1425-1427.
42. Savithri V, Suresh R, Janardhanan M, Aravind T. Metastatic adenocarcinoma of mandible: in search of the primary. *BMJ Case Rep.* 2018;11:e227862.
43. George R, Neralla M, Rajan J, Haque AE, Kumar SP. Metastatic Tumour to the Mandible - A Diagnostic and Management Dilemma. *Cureus.* 2019;11:e5093.
44. Sioka C, Karpathiou G, Papoudou-Bai A, Zikou A, Tsina E, Bellou V, et al. A unique case of mandibular metastasis from primary lung mucoepidermoid carcinoma. *Oral Oncol.* 2019;98:168-170.
45. Johnson C, Read-Fuller A. Mandibular metastasis from lung adenocarcinoma as the first sign of occult malignancy. *Proc (Bayl Univ Med Cent).* 2020;33:261-262.
46. Tamgadge S, Pereira T, Kale S, Shetty S, Tamgadge A. Lung metastasis, an incidental finding in maxilla - A case report. *Indian J Pathol Microbiol.* 2020;63:273-275.
47. Beena V, Panda S, Heera R, Rajeev R. Multiple metastatic tumors in the oral cavity. *J Oral Maxillofac Pathol.* 2011;15:214-8.
48. Hirshberg A, Shnaiderman-Shapiro A, Kaplan I, Berger R. Metastatic tumours to the oral cavity - pathogenesis and analysis of 673 cases. *Oral Oncol.* 2008;44:743-52.
49. Irani S. Metastasis to the Jawbones: A review of 453 cases. *J Int Soc Prev Community Dent.* 2017;7:71-81.
50. Barta JA, Powell CA, Wisnivesky JP. Global Epidemiology of Lung Cancer. *Ann Glob Health.* 2019;85:8.
51. Ito H, Onizawa K, Satoh H. Non-small-cell lung cancer metastasis to the oral cavity: A case report. *Mol Clin Oncol.* 2017;6:422-424.
52. Schaal C, Chellappan SP. Nicotine-mediated cell proliferation and tumor progression in smoking-related cancers. *Mol Cancer Res.* 2014;12:14-23.
53. Kumar G, Manjunatha B. Metastatic tumors to the jaws and oral cavity. *J Oral Maxillofac Pathol.* 2013;17:71-5.
54. Curien R, Moizan H, Gerard E. Gingival metastasis of a bronchogenic adenocarcinoma: report of a case. *Oral Surg Oral Med Oral Pathol Oral Radiol Endod.* 2007;104:e25-28.
55. Sánchez-Jiménez J, Acebal-Blanco F, Arévalo-Arévalo RE, Molina-Martínez M. Metastatic tumours in upper maxillary bone of esophageal adenocarcinoma. A case report. *Med Oral Patol Oral Cir Bucal.* 2005;10:252-7.
56. Bernstein JM, Montgomery WW, Balogh K Jr. Metastatic tumors to the maxilla, nose, and paranasal sinuses. *Laryngoscope.* 1966;76:621-50.
57. Nahum AM, Bailey BJ. Malignant tumors metastatic to the paranasal sinuses: case report and review of the literature. *Laryngoscope.* 1963;73:942-53.
58. Logothetis CJ, Lin SH. Osteoblasts in prostate cancer metastasis to bone. *Nat Rev Cancer.* 2005;5:21-8.
59. Travis WD, Brambilla E, Nicholson AG, Yatabe Y, Austin JHM, Beasley MB, et al. WHO Panel. The 2015 World Health Organization Classification of Lung Tumors: Impact of Genetic, Clinical and Radiologic Advances Since the 2004 Classification. *J Thorac Oncol.* 2015;10:1243-1260.
60. Ciebien M, Belting CM. Mucoepidermoid tumor metastatic to the mandible: case report. *Mil Med.* 1975;140:32-5.

Abbreviations

CT: Computerized tomography, JB: Jaw bone, JBM: Jaw bone metastasis, LC: Lung cancer, MRI: Magnetic resonance imaging, MS: Maxillary sinus, NCS: Numb chin syndrome, PNS: Paranasal sinus, PRISMA: Preferred Reporting Items for Systematic Reviews and Meta-Analyses, TMJ: Temporomandibular joint, WHO: World health organization.

Ethical approval

Not required.

Funding resources

Nil.

Author's contributions

SG: Conceptualization, Data curation, Investigation, Methodology, Project administration, Resources, Validation, Writing-original draft, Writing-review & editing
 MKJ: Project administration, Supervision, Visualization
 AG: Investigation, Methodology, Project administration
 SB: Investigation, Methodology, Project administration
 NK: Methodology, Resources, Validation
 JD: Methodology, Resources, Validation
 SKY: Formal analysis, Final review
 ABY: Formal analysis, Final review

Conflict of interest

Nil.