

Successfully Nonsurgical Epidermoid Cyst Management with Recombinant Hydrolytic Enzymes: A Case Report

Desiree Giselle Castelanich^{1,2}, Luis Alberto Parra Hernández², Maricarmen Chacín³

¹Sociedad Argentina de Dermatología, Buenos Aires, Argentina; ²Sociedad Internacional de Rejuvenecimiento Facial No Quirúrgico (SIRF), Barranquilla, Colombia; ³Universidad Simón Bolívar. Facultad de Ciencias de la Salud, Centro de Investigaciones de Ciencias de la Vida (CICV), Barranquilla, Colombia

Correspondence: Maricarmen Chacín, Email Maricarmen.chacing@unisimon.edu.co

Introduction: Epidermoid cysts (E.C.s), also known as sebaceous cysts, are benign asymptomatic subepidermal nodules filled with keratin material. These cysts originate from the follicular infundibulum, which when obstructed by keratin, results in cyst formation. Conventionally, E.C.s have been managed surgically with a high success rate and minimal complications. In this report, we present the successful resolution of an E.C. using a minimally invasive technique involving the intralesional injection of recombinant hydrolytic enzymes like hyaluronidase, collagenase, and lipase.

Case Presentation: A 44-year-old woman with no significant medical history presented to the clinic with a mass on her right cheek that had been evolving for over 10 years. Skin and soft tissue ultrasound confirmed the presence of an E.C. of 9.3×6.6 × 9.3 mm. Owing to the size and location of the cyst, a decision was made to infiltrate the lesion with recombinant enzymes. Remarkably, significant clinical improvement was observed on Day 21, and complete dissolution of the E.C. occurred 40 days after the initial intervention. Importantly, no recurrences were observed during the 4-year follow-up period.

Conclusion: Intralesional administration of hydrolytic enzymes represents an innovative technique in the management of E.C.s. However, further controlled studies are required to determine the efficacy and safety of this procedure.

Keywords: epidermoid cyst, hyaluronidase, lipase, collagenase, sebaceous cyst

Introduction

Epidermoid cysts (E.C.s), also known as sebaceous cysts, are benign, asymptomatic, dome-shaped, encapsulated subepidermal nodules filled with keratin material.¹ E.C.s originate from the follicular infundibulum, where plugging of the follicular orifice results in the formation of a cyst communicating with the skin surface via a keratin-blocked orifice.^{1–3} Although commonly referred to as sebaceous cysts, this term is inappropriate because the lesion develops within the infundibulum and does not involve the sebaceous gland. Other common synonyms include infundibular, epidermal, and epidermal inclusion cysts.⁴ While these cysts are generally benign lesions, on rare occasions, malignant tumors may arise within this type of lesion.^{5–7}

Most cases of E.C.s are sporadic and not associated with specific genetic syndromes. However, E.C.s can occur in Gardner syndrome⁸ (familial adenomatous polyposis) and Gorlin syndrome⁸ (basal cell nevus syndrome). Therefore, the occurrence of E.C.s before puberty in unusual locations and numbers should raise suspicion of one of these syndromes. In Favre–Racouchot syndrome (nodular elastosis with cysts and comedones) in elderly patients, E.C. may result from chronic sun damage. Furthermore, the appearance of E.C.s has been associated with the administration of B-Raf (serine/threonine-protein kinase B-Raf) inhibitors, such as vemurafenib, dabrafenib, and encorafenib, and they typically appear on the face.⁹ Additionally, E.C.s have been reported in patients treated with imiquimod and cyclosporine.^{9,10}

While complete surgical excision of the cyst with its wall or capsule intact is classically accepted as the most effective treatment for E.C., some authors advocate the minimal excision technique as equally effective, less invasive, and esthetically more appropriate.¹¹ However, medical literature on minimally invasive techniques is scarce. This case report describes the successful treatment of an E.C. in the right cheek using a minimally invasive technique involving intralesional injection of recombinant hydrolytic enzymes like hyaluronidase, collagenase, and lipase.¹²

Hyaluronidase stands at the forefront of enzymatic treatments in dermatology, distinguished by catalysing hyaluronic hydrolysis (H.A). The mechanism of action of this enzyme involves H.A., hydrolysis at 1,4-glucosaminidic bonds between glucosamine and glucuronic acid, alongside other mucopolysaccharides within the extracellular matrix. Additionally, hyaluronidase significantly enhances tissue permeability through high molecular weight H.A. fragmentation, which, in turn, boosts other local drug efficacy like anaesthetics, mesotherapy, and dermal filler injection, among others. Additionally, it offers a corrective mechanism for addressing undesirable outcomes or facial asymmetries via HA-based dermal filler degradation.^{12,13}

Delving into matrix metalloproteinases (M.M.P.s), collagenases play a crucial role, extending beyond their primary function of collagen degradation. These enzymes are effector molecules that promote dermal cell migration and reepithelialisation while protecting against apoptosis and inflammation. The human body hosts diverse collagenases, yet recombinant bacterial-origin collagenases exhibit pronounced efficacy in collagen hydrolysis. Notably, collagenase has demonstrated its ability to activate keratinocyte cellular responses *in vitro*, encouraging granulation tissue development, inflammation reduction, reepithelialisation, and hastening wound closure. These advantages highlight collagenase potential in skin rejuvenation, scar management, and preparatory procedures for surgery.^{12,14,15}

A complementary enzyme, lipase, is known mostly for triacylglycerides hydrolysis and is used for targeting localised fat reduction, cellulite management, and enhancing both the face and body contours. This enzyme's application underscores the multifaceted approach of enzymatic therapies in improving aesthetic outcomes, offering innovative solutions for complex dermatological challenges.^{16,17}

Case Presentation

A 44-year-old woman with a non-tender nodule in the right cheek for over ten years. The patient had a history of moderate acne vulgaris during adolescence. There were no other significant clinical findings prior to developing the lesion. Physical examination revealed a single nodular lesion on the right cheek, which protruded slightly beyond the skin surface (Figure 1). Upon palpation, a soft-textured lesion was detected, more palpable than visible, measuring approximately 1 cm in diameter. The lesion was well-defined, oval-shaped, nonpainful, mobile, and clinically compatible with an E.C. To characterise the lesion further, an ultrasound evaluation was performed, which revealed an ovoid, hypochoic, cystic structure with regular borders measuring approximately 9.3×6.6 × 9.3 mm in the subcutaneous cellular tissue plane (Figure 2).

Given its location on the face and its small size, after the patient's informed consent was obtained, intralesional enzymatic therapy was started using the recombinant enzymes Slim Lipase PB500 (Pbserum[®], Madrid, Spain), Smooth Collagenase GH PB220 (Pbserum[®], Madrid, Spain), and Drain Hyaluronidase PB3000 (Pbserum[®], Madrid, Spain) according to the protocol described below:

Preparation of the Enzymatic Solution

1. The enzymes were present in a vial in the form of lyophilised powder.
2. One millilitre of 0.9% physiological solution was poured into a 3 mL injector in which each of the enzyme vials (Slim Lipase PB500, Smooth Collagenase GH PB220 and Drain Hyaluronidase PB3000) was to be reconstituted.
3. A total of 3 mL of the enzyme solution was prepared, ie, 1 mL for each vial.

Intralesional Treatment Protocol

4. Asepsis and antisepsis of the area were achieved.
5. The enzymatic treatment was applied with a 3 mL syringe and a 30G ½ needle. In this method, 1.5 mL of the mixture was applied in the centre of the cystic lesion and 1.5 mL in the perilesional region radially.
6. Finally, routine postprocedural recommendations, precautions, and follow-up plans were explained to the patient.

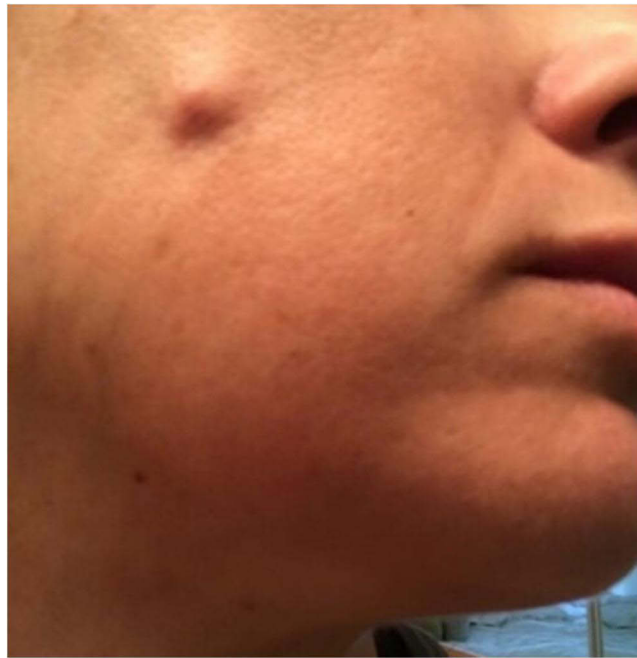


Figure 1 Mass on right cheek.

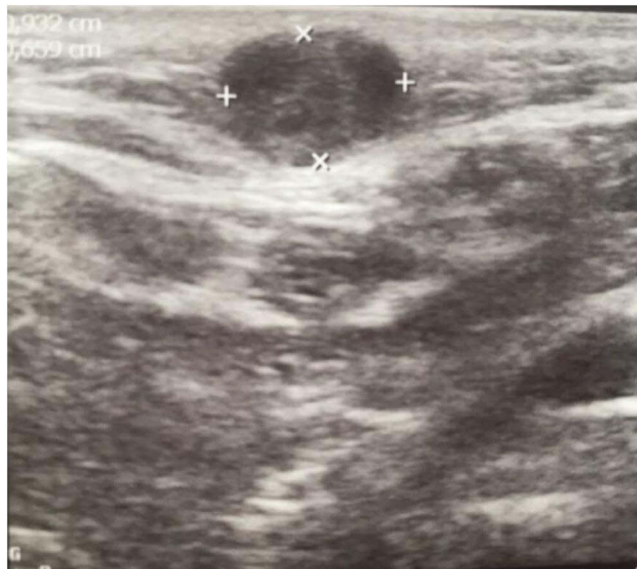

Figure 2 Ovoid, hypoechoic cystic lesion with regular borders, measuring approximately 9.3×6.6 × 9.3 mm in the subcutaneous cellular tissue plane.

Patient Monitoring and Control

Day 7 after enzymatic treatment: Erythema, oedema, and inflammatory reaction were observed in the infiltrated area (Figure 3a). Ultrasound follow-up showed a hypoechoic lesion in the subcutaneous cellular tissue with slightly irregular borders measuring 6×7 × 3 mm (Figure 3b). A wait-and-watch approach was adopted, and a reapplication was performed subsequent to the control ultrasound on Day 21 after the initial application.

Day 21 after enzymatic treatment: A new enzyme application was performed using the same dilution and volume as before (Figure 3c).

Day 41 after enzymatic treatment: A reduction of the nodular volume was observed, leaving an erythematous macule in its place (Figure 3d). Control ultrasound revealed the absence of tumours (study without clinical alterations) (Figure 3e).

Long-term evolution: Four years after enzymatic application, there is no evidence of C.E. recurrence (Figure 3f).

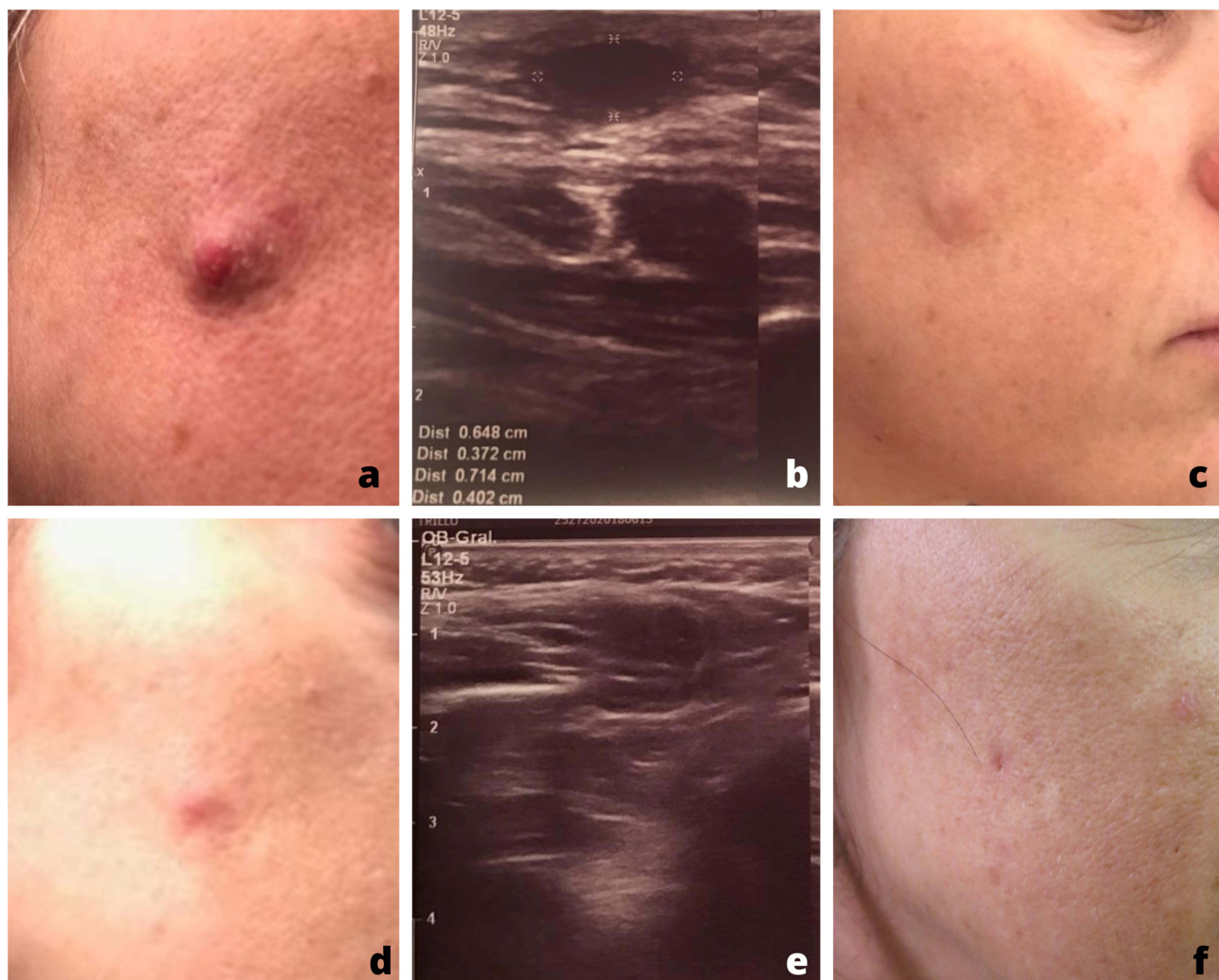


Figure 3 (a) After the first session, erythema, oedema, and inflammatory reactions are observed in the infiltrated area. (b) Hypoechoic lesion in the subcutaneous cellular tissue with slightly irregular borders of $6 \times 7 \times 3$ mm. (c) New application of the enzymes with the same dilution and volume as previously mentioned. (d) Reduction of the nodular volume, leaving in its place an erythematous macule. (e) Control ultrasound shows the absence of tumours. (f) Affected area 4 years after the application.

Ethics Statement

All procedures undergone in this patient were conducted described in this report were carried out in strict compliance with the ethical guidelines of both institutional and national research committees. In addition, our methods conform to the ethical standards set forth in the 1964 Declaration of Helsinki and its subsequent amendments, ensuring high ethical and scientific integrity. The study was also reviewed and approved by the Research Ethics Committee Of The Caribbean Foundation For Biomedical Research with approval number CEI-BIOS-001-170524-301. The patient involved in this clinical case gave written informed consent, accepting the use of his clinical information and images for research and publication purposes.

Discussion and Literature Review

Epidermoid and dermoid cysts are rare benign lesions in the head and neck region, comprising nearly 7% of lesions in these areas. E.C.s, formerly known as sebaceous cysts, are the most common benign cutaneous lesions, accounting for approximately 85–90% of all excised cysts.^{4,18} E.C.s can manifest as solitary or multiple lesions,^{6,19} predominantly affecting men in their third and fourth decades of life.¹ However, the presentation age range varies widely from birth to the eighth decade of life. While the face, neck, periauricular area, and upper trunk are the commonly affected regions, E.

C.s can occur on any part of the body, including the gluteal region, nipples, buttocks, palms of the hands, and plantar aspect of the feet.^{20,21} When found on the distal part of the fingers, they may cause changes in the nail plate.²²

Neonatal E.C.s are common, occurring in approximately half of all newborns. They typically manifest as small epidermal cysts called milia, which are transient and may be idiopathic (primary milia) or occur in traumatised areas, such as burns or certain dermatoses (secondary milia). Additionally, milia can develop at sites of bullous scarring in certain genodermatoses, such as epidermolysis bullosa, bullous pemphigoid, porphyria cutanea tarda, and sunburn. Milia may also arise after cosmetic procedures, such as dermabrasion, or after cryotherapy for skin tumours.¹⁸ Approximately 1% of E.C.s have been observed to undergo malignant transformation into squamous cell carcinoma or basal cell carcinoma.^{7,23,24}

Physical examination typically reveals a non-fluctuant and compressible mass ranging in size from several millimetres to several centimetres.⁴ These cysts often feature a dark central opening referred to as a punctum. While E.C.s are usually asymptomatic, they may become inflamed owing to cyst lining rupture. Discharge of a foul-smelling, yellowish, cheese-like material from the lump may be described. Signs such as erythema, enlargement, tenderness to palpation, pain, and fluctuation may appear suddenly because of inflammation. Inflamed cysts can be mistaken for a boil or carbuncle.²⁰ Spontaneous or surgical drainage can aid in the healing process.^{11,25} Scrotal E.C.s may calcify, leading to calcinosis cutis and requiring monitoring.^{23,24}

Histologically, an E.C. is lined by an epithelial cell wall. This epithelium is a stratified squamous epithelium similar to the epidermis and includes a granular and lamellar keratin layer in the lumen. In contrast, “true” dermoid cysts involve cutaneous appendages, such as hair follicles, sebaceous glands, and sweat glands, and teratoid cysts occur when there are tissues of the three germ layers, such as cartilage bone, muscle, and respiratory or gastrointestinal epithelium.²⁴ If the cyst becomes infected, chronic inflammatory cellular infiltration may occur outside the cyst wall and cyst structure remodelling. The rupture of the cyst lining with the release of keratin scales into the surrounding soft tissue can cause acute granulomatous foreign body reaction.^{1,4} Clinically, this may initially manifest as local tenderness. Chronic inflammatory cell accumulation outside the cyst wall may also result from a previous infection.¹¹ E.C.s may exhibit unusual histologic features in Gardner’s syndrome, such as hybrid cysts. Small, uncomplicated cysts usually do not require treatment and simple, complete surgical excision of the cyst with its wall intact can be performed.¹¹ In these cases, an initial incision and drainage may be indicated, with the possibility of future recurrence. Local anaesthetic with epinephrine is recommended to minimise bleeding; the anaesthetic should be injected around the cyst, avoiding direct injection into it to prevent leakage.^{4,11} A small-diameter elliptical incision with the inclusion of the central nucleus or punctum is made. For optimal cosmetic results, the incision should be restricted to the minimal tension lines of the skin. Multilayered subcuticular incision and epidermal closure can yield favourable outcomes.²⁵

A complete excision should be postponed if there is an active infection, as the dissection planes will be difficult. Surgery during active inflammation increases the risk of infection, wound dehiscence, and cyst recurrence. The lesion should be removed after resolving the infection. An alternative surgical approach with punch biopsy and expulsion of the intact cyst through the small defect or standard excision can also be performed.²⁴ In the case of surrounding inflammation, intralesional triamcinolone can be administered to help decrease inflammation and delay surgical removal. Ensuring the complete removal of the cyst wall is essential to prevent recurrence, as cysts are more challenging to remove once they have ruptured.³

While small cysts can be treated with CO₂ or erbium-YAG (yttrium–aluminium–garnet) lasers, large cysts require a surgical approach. To avoid sagging of the skin after removal of large cysts, a small sheet of the epidermis is removed above the cyst, allowing an individualised adaptation of the surgical margins. Histopathological confirmation of all surgically removed E.C.s is necessary to ensure complete excision and avoid misdiagnosis. Although not observed in this case, possible malignant transformation is another important argument for periodic histopathological analysis.^{22,25} Complete excision involves sterile preparation, bandaging, local anaesthesia, excision using a combination of sharp and blunt dissection, and wound closure. The key is to excise the cyst intact, with minimal or no loss of sebum. An alternative method involves a smaller incision in the sac, manual sebum removal, and empty cyst removal with forceps and scissors. Although this results in a smaller scar, it may lead to a higher rate of internal inflammation and suppuration.¹⁹

The microincision technique involves treating the empty sac with the chemical phenol. The choice of skin incision depends on the cyst characteristics, with linear incisions over the centre recommended for non-inflamed or scar-free cysts and small elliptical incisions for cysts with a punctum or scar. Recurrent inflammation or scar tissue formation may require more radical excision.¹ For small, benign, subcutaneous lesions, office-based excision is possible. Depending on the location, management can be proposed, as in the presented case, where the fear of a hypertrophic scar on the face delayed the patient's consultation. However, when the diagnosis is uncertain, patients with very small lesions are usually referred to a hospital for excision, although using diagnostic aids such as ultrasound can improve management and decision-making in these cases.

The application of hydrolytic agents in the treatment of certain diseases needs more groundwork. Nevertheless, we can mention some kinds of drugs that have recently attracted so many researchers because of their own benefits for the world of medicine. An example of this is provided by Lindgren et al who demonstrate how intralesional hyaluronidase is used to treat the patient who is suffering from two conditions at the same time: the cosmetically ugly outcomes include periorbital myxedema and dermopathy which are referred to as Graves' Eye Disease (GED). Hyaluronidase, which is obtainable from bacterial recombinant origins is now FDA cleared to be used in the various treatment of ophthalmologic disease complications due to hyaluronan volume reduction, and in replenishing the impact of injection H.A fillers. Thanks to its effectiveness in the heaviest and largest pouches which are situated right below the knee, the grafting process has not been challenged much. The treatment procedure was done in three steps: the first step was the injection of 10 units of hyaluronidase per cubic centimeter into the area; the second step was to determinate the amount of HA filler needed using the distortion of the skin as a guideline. In this way an easy-going operation of hyaluronidase as an enzyme has become obvious, and up to 25 patients with no severe side-effects- swelling, redness and mild itching- do not experience any at all. The side effects of which are mild to moderate are more prevalent, namely haematoma/bruising.²⁶

In a separate recent investigation by Paris et al, the treatment of Fournier's gangrene was addressed using recombinant enzymes initiated three weeks into the condition to facilitate the healing of wounds. Regular irrigation of the granulation tissue every three weeks was employed to guarantee optimal tissue penetration. Remarkably, epithelialisation of the affected areas was visible after just one week, with most wounds healing satisfactorily and without infection signs within a month. Using a mixture enriched with high levels of collagenase, lipase, and lyase exhibited promise in markedly improving and accelerating the healing process in Fournier's gangrene patients. Additional research is needed to develop concrete treatment protocols.²⁷

Nevertheless, areas like the face may cause patient anxiety owing to the fear of pathological scarring and visual sequelae; hence, achieving total elimination without sequelae is crucial. The case presented herein demonstrated the successful and recurrence-free removal of an E.C. present on the face for several years.¹¹

Conclusions

The face is a prominent area that often raises concerns among patients regarding the potential sequelae of surgical treatment for benign lesions, such as hypertrophic scarring and hyperpigmentation. This novel and straightforward technique offers a conservative approach, eliminating the risk of scarring sequelae. Moreover, it avoids adopting an expectant behavior, preventing the cyst from growing further and potentially affecting the patient's long-term self-esteem.

The challenge of selecting treatments for dermatological conditions like sebaceous cysts on the face underscores an important juncture in aesthetic medicine and dermatology. Proposing a departure from traditional surgical interventions, this discussion emphasises the potential of enzyme therapy—utilising hyaluronidase, collagenase, and lipase—as a less invasive solution. These enzymes target the breakdown of key components within the cysts, such as the lipid-rich sebum and collagenous capsule, offering a strategy to diminish scarring and reduce recovery time, which is particularly crucial for facial treatments where aesthetic considerations are paramount.

The evidence supporting enzyme therapy's effectiveness in aesthetic contexts is burgeoning, yet its specificity for decomposing the sebaceous material and collagen in facial cysts warrants additional exploration. Despite this, the promising aspect of such therapies, especially as effective, minimally invasive alternatives, deserves emphasis. This

innovative approach not only meets the aesthetic expectations of patients but also heralds a shift towards treatment modalities that preserve skin integrity, representing a significant evolution from the conventional surgical paradigm.

Ethical Aspects

All procedures undergone in this patient were conducted described in this report were carried out in strict compliance with the ethical guidelines of both institutional and national research committees. In addition, our methods conform to the ethical standards set forth in the 1964 Declaration of Helsinki and its subsequent amendments, ensuring high ethical and scientific integrity. The study was also reviewed and approved by the Research Ethics Committee Of The Caribbean Foundation For Biomedical Research with approval number CEI-BIOS-001-170524-301. The patient involved in this clinical case gave written informed consent, accepting the use of his clinical information and images for research and publication purposes.

Author Contributions

All authors made a significant contribution to the work reported, whether that is in the conception, study design, execution, acquisition of data, analysis and interpretation, or in all these areas; took part in drafting, revising or critically reviewing the article; gave final approval of the version to be published; have agreed on the journal to which the article has been submitted; and agree to be accountable for all aspects of the work.

Funding

Internal funds for the strengthening of research from Universidad Simón Bolívar, Vicerrectoría de Investigación, Extensión e Innovación, Barranquilla, Colombia.

Disclosure

The authors declare that there are no conflicts of interest.

References

1. Zito PM, Scharf R. Epidermoid Cyst. StatPearls [Internet]; 2023. Available from: <https://www.ncbi.nlm.nih.gov/books/NBK499974/>. Accessed July 31, 2024.
2. Handa U, Kumar S, Mohan H. Aspiration cytology of epidermoid cyst of terminal phalanx. *Diagn Cytopathol*. 2002;26(4):266–267. doi:10.1002/dc.10075
3. Weir CB, St.Hilaire NJ. Epidermal Inclusion Cyst. StatPearls [Internet]; 2023. Available from: <https://www.ncbi.nlm.nih.gov/books/NBK532310/>. Accessed July 31, 2024.
4. Hoang VT, Trinh CT, Nguyen CH, Chansomphou V, Chansomphou V, Tran TTT. Overview of epidermoid cyst. *Eur J Radiol Open*. 2019;6:291. doi:10.1016/j.ejro.2019.08.003
5. Ruiz-Genao D, Ballesteros M, Fraga J, García-Díez A, Fernández-Herrera J. Micosis fungoide folicular, comedoniana y quística. *Actas Dermosifiliogr*. 2005;96(2):102–105. doi:10.1016/S0001-7310(05)73046-5
6. Narváez-Ruiz R, Mellado-Torres JM, Ángeles-Velázquez A, Chávez-Priego T, Nextle A. Quiste epidermoide. Reporte de tres casos y revisión de la literatura. *Rev Mex Cirugía Bucal y Maxilofac*. 2022;17(3):147–155.
7. Antón-Badiola I, San Miguel-Fraile P, Peteiro-Cancelo A, Ortiz-Rey JA. Carcinoma epidermoide desarrollado sobre quiste de inclusión epidérmica cutáneo. Presentación de un nuevo caso y revisión de la literatura. *Actas Dermosifiliogr*. 2010;101(4):349–353. doi:10.1016/j.ad.2010.01.001
8. Sachlos E, Auguste D [Dermatology by Bologna]. Biomaterials [Internet]; 2018. Available from: <https://r1.vlreader.com/EpubReader?ean=1780702063428#>. Accessed July 31, 2024.
9. Boussemart L, Routier E, Mateus C, et al. Prospective study of cutaneous side-effects associated with the BRAF inhibitor vemurafenib: a study of 42 patients. *Ann Oncol off J Eur Soc Med Oncol*. 2013;24(6):1691–1697. doi:10.1093/annonc/mdt015
10. Faltaous AA, Leigh EC, Ray P, Wolbert TT. A Rare Transformation of Epidermoid Cyst into Squamous Cell Carcinoma: a Case Report with Literature Review. *Am J Case Rep*. 2019;20:1141. doi:10.12659/AJCR.912828
11. ZUBER TJ. Minimal Excision Technique for Epidermoid (Sebaceous) Cysts. *Am Fam Physician*. 2002;65(7):1409–1412.
12. De Castro García MP, Muñoz Montaña JR. Evaluación de ácido hialurónico y coctel enzimático en cicatrices. Estudio multicéntrico. *Dermatología C*. 2020;18(2):84–92.
13. Bailey SH, Fagien S, Rohrich RJ. Changing role of hyaluronidase in plastic surgery. *Plast Reconstr Surg*. 2014;133(2):127e–132e. doi:10.1097/PRS.0b013e3182a4c282
14. Xue M, Le NTV, Jackson CJ. Targeting matrix metalloproteases to improve cutaneous wound healing. *Expert Opin Ther Targets*. 2006;10(1):143–155. doi:10.1517/14728222.10.1.143
15. Gutiérrez-Fernández A, Inada M, Balbín M, et al. Increased inflammation delays wound healing in mice deficient in collagenase-2 (MMP-8). *FASEB J*. 2007;21(10):2580–2591. doi:10.1096/fj.06-7860com

16. Martins AM, Pham QP, Malafaya PB, et al. The role of lipase and α -amylase in the degradation of starch/poly(Caprolactone) fiber meshes and the osteogenic differentiation of cultured marrow stromal cells. *Tissue Eng A*. 2009;15(2):295–305. doi:10.1089/ten.tea.2008.0025
17. Banerjee A, Chatterjee K, Madras G. Lipase mediated enzymatic degradation of polydioxanone in solution. *Polym Degrad Stab*. 2014;110:284–289. doi:10.1016/j.polymdegradstab.2014.09.015
18. Gotmare SS, Gupta AA, Rathod P, Nainani P. Epidermoid cyst: a case report and review of literature. *Pan Afr Med J*. 2016;23:3–6. doi:10.11604/pamj.2016.23.226.9225
19. Nigam J, Bharti J, Nair V, et al. Epidermal Cysts: a Clinicopathological Analysis with Emphasis on Unusual Findings. *Int J Trichol*. 2017;9(3):108. doi:10.4103/ijt.ijt_16_17
20. Gulati A, Batra H Epidermoid Cysts of Face: clinicopathological Presentation and a report of four cases [Internet]; 2023. Available from: https://www.academia.edu/26617780/Epidermoid_Cysts_of_Face_Clinicopathological_Presentation_and_a_report_of_four_cases. Accessed July 31, 2024.
21. Janarthanam J, Mahadevan S. Epidermoid cyst of submandibular region. *J Oral Maxillofac Pathol*. 2012;16(3):435–437. doi:10.4103/0973-029X.102511
22. Jeon S, Lee SY, Kim J, et al. Clinicopathologic features of epidermoid cysts in the upper and lower extremities, including a case of malignant transformation in the palmoplantar region. *Arch Hand Microsurg*. 2022;27(4):285–291. doi:10.12790/ahm.22.0049
23. Muddegowda PH, Lingegowda JB, Ramachandrarao RK, Konapur PG. Calcinosis Cutis: report of 4 Cases. *J Lab Physicians*. 2011;3(02):125–126. doi:10.4103/0974-2727.86849
24. Apollos JR, Ekatah GE, Ng GS, McFadyen AK, Whitelaw SC. Routine histological examination of epidermoid cysts; to send or not to send? *Ann Med Surg*. 2017;13:24–28. doi:10.1016/j.amsu.2016.12.047
25. Sempowski IP. Sebaceous cysts: ten tips for easier excision. *Can Fam Physician*. 2006;52(3):315.
26. Lindgren AL, Sidhu S, Welsh KM. Periorbital myxedema treated with intralesional hyaluronidase. *Am J Ophthalmol Case Rep*. 2020;19 (August 2019):100751. doi:10.1016/j.ajoc.2020.100751
27. Paris E, López Berroa J. Fournier's gangrene wounds successfully healed with High pbserum enzymes: a case report. *AboutOpen*. 2024;11 (1):18–20. doi:10.33393/ao.2024.2736

Clinical, Cosmetic and Investigational Dermatology

Dovepress

Publish your work in this journal

Clinical, Cosmetic and Investigational Dermatology is an international, peer-reviewed, open access, online journal that focuses on the latest clinical and experimental research in all aspects of skin disease and cosmetic interventions. This journal is indexed on CAS. The manuscript management system is completely online and includes a very quick and fair peer-review system, which is all easy to use. Visit <http://www.dovepress.com/testimonials.php> to read real quotes from published authors.

Submit your manuscript here: <https://www.dovepress.com/clinical-cosmetic-and-investigational-dermatology-journal>