

RESEARCH ARTICLE

Open Access



The largest secure corridor of the infra-acetabular screw—a 3-D axial perspective analysis

Bei Zhao^{1,2}, Wei Zhang¹, Hao Li¹, Liren Han¹, Shizhang Han¹, Xiaofei Yang¹, Jun Yan^{1*} and Weidong Mu^{2*}

Abstract

Background: The infra-acetabular screw which is placed from the pubis to the ischium can be used as a special positional screw of the posterior column of the acetabulum. This study was performed to simulate the surgical procedure and obtain the ideal insertion point, diameter, length and angle of the screw through the method of axial perspective in Chinese patients.

Methods: We randomly collected the pelvic computed tomography (CT) scans of 200 adults. DICOM-formatted CT-scan images were imported into Mimics software to establish the 3D digital model of the right semi-pelvic was established. A virtual cylinder representing the screw was placed from the pubis to the ischium to fix the posterior column. The largest secure diameter and length of the virtual screw were measured and the position of the insertion point and the directions of the screw were also researched.

Results: The screw insertion safe zone exhibits an irregular shape of “tear drop” in the reconstructed pelvic model. The mean maximum diameter of screws was 5.01 ± 1.28 mm, and the mean maximum length of screws was 93.99 ± 8.92 mm. The screw insertion corridor with the least diameter 3.5 mm was found in 94 of 100 males (94%) and 86 of 100 females (86%). We found gender-dependent differences for the mean maximum diameter and the maximum length of the screw. There was statistically significant difference between genders in the position of insertion point.

Conclusions: In this study, we suggest an individual preoperative 3D reconstruction simulation to develop better screw placement plans, which provides a valuable guideline for seeking the largest secure corridor of infra-acetabular screw. Further biomechanical studies are needed to verify the function of the screw.

Keywords: Acetabular fracture, Axial perspective, Positional screw, Digital measurement

* Correspondence: awpkaka@126.com; Dr_muweidong@163.com

Bei Zhao and Wei Zhang contributed equally to this work and should be considered co-first authors.

Jun Yan and Weidong Mu contributed equally to this work.

¹Department of Orthopaedics, Liaocheng People's Hospital, Liaocheng, Shandong, China

²Department of Traumatic Orthopaedics, Shandong Provincial Hospital Affiliated to Shandong First Medical University, Jinan, Shandong, China



© The Author(s). 2021 **Open Access** This article is licensed under a Creative Commons Attribution 4.0 International License, which permits use, sharing, adaptation, distribution and reproduction in any medium or format, as long as you give appropriate credit to the original author(s) and the source, provide a link to the Creative Commons licence, and indicate if changes were made. The images or other third party material in this article are included in the article's Creative Commons licence, unless indicated otherwise in a credit line to the material. If material is not included in the article's Creative Commons licence and your intended use is not permitted by statutory regulation or exceeds the permitted use, you will need to obtain permission directly from the copyright holder. To view a copy of this licence, visit <http://creativecommons.org/licenses/by/4.0/>. The Creative Commons Public Domain Dedication waiver (<http://creativecommons.org/publicdomain/zero/1.0/>) applies to the data made available in this article, unless otherwise stated in a credit line to the data.

Background

The treatment of complex acetabular fractures involving quadrilateral displacement has been widely studied in recent years [1–6]. The goal of acetabular surgery is perfect reduction and rigid fixation, allowing early joint movement and avoiding postoperative complications [1, 5, 7].

Early, Letournel and Judet suggested the ideal screw path is parallel of the quadrilateral wall, in which the screw could fix the quadrilateral fracture and prevent the medial subluxation [8]. The placement of this additional screw can also increase the fixation strength of plate for acetabular fractures [4, 5]. On this basis, Culemann et al described the infra-acetabular screw [1]. They showed the operative technique and indication of the screw. However, the placement of the infra-acetabular screw is technically demanding due to the unique and complex anatomy of the osseous area. The knowledge of the correct insertion point and screw direction is essential to avoid penetrating into joint and injury to neurovascular structures [9].

At present, there are multiple studies on the application of CT data utilizing various software for the fixation of periacetabular screws [7, 9–13]. Previous studies have showed that the method of axial perspective can help to find a larger anterior and posterior column screw path [10, 11]. The purpose of the study is to specify the ideal insertion point, the largest secure diameter and length, and the accurate angle of the infra-acetabular screw through the method of axial perspective.

Materials and methods

We retrospectively collected the pelvic CT scans of 200 adults who had undergone continuous slice CT scanning at the imaging research center of our hospital during August 2016 and June 2019. Patients were excluded if they had pelvic or acetabular fractures, tumors, severe

deformities, or severe hip inflammation. This study was approved by the Institutional Review Board of Liaocheng people's hospital. Due to the retrospective nature of the study, informed consent was waived. The mean age of the patients on whom the models were based was 46.31 ± 14.19 years (range 18–86 years).

DICOM-formatted CT-scan images of each patient were imported into Mimics software (20.0; Materialise, Leuven, Belgium). We removed the soft tissue, femoral head and sacroiliac joint by the function of image segmentation, region growth and multiple slice editing of Mimics software, respectively. A total of 200 right virtual semi-pelvic models were created.

We reduced the transparency of the semi-pelvic models and turned it to the axial perspective view, which was parallel to the posterior of obturator foramen from top to bottom (Fig 1A). Observations and measurements were conducted in different positions of the model through the perspective view to find the largest translucent area. Then, a translucent area like a tear drop was seen clearly (Fig 1B). The area represented the infra-acetabular screw path and the outline represented the medial cortical bone. A virtual cylinder representing the screw was placed into the translucent area. The risk of border penetration was assessed as the diameter of the cylinder increasing progressively and the maximum diameter was defined (Fig 1C). We observed and adjusted the length of the screw to make sure that the screw did not penetrate the cortical bone (Fig 2A–D). The diameter and length of the virtual screw were measured. In order to confirm the position of screw, the distances from the insertion point to the eminencia iliopectinea, the pubic tubercle and the pelvic border (arcuate line/pecten pubis) were measured, respectively. They were recorded as Distance L1, L2 and L3 (Fig 3). The lateral inclination angle between the screw and the medial surface of quadrilateral

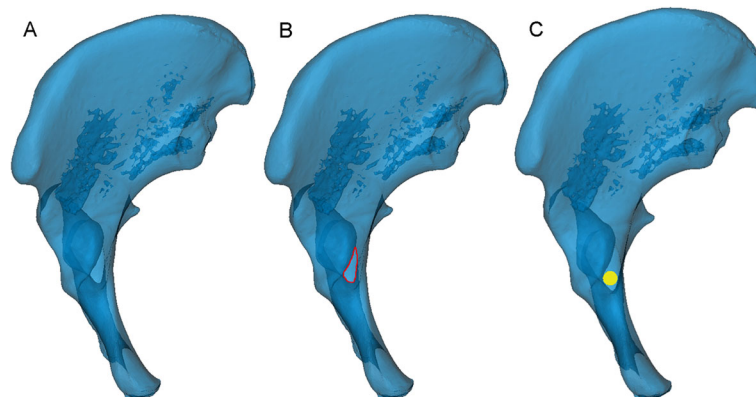


Fig. 1 Find the largest screw path. **A** The 3D model was turned to the axial perspective to find the largest translucent area. **B** The outline of this translucent area (marked in red) represented the overlaying cortical bone, like a drop of water. **C** A virtual screw was placed in the centre of the tear-drop area. Then, the diameter was increased progressively until it reached the borderline of the area (the yellow circle of the cylinder represents the largest screw)

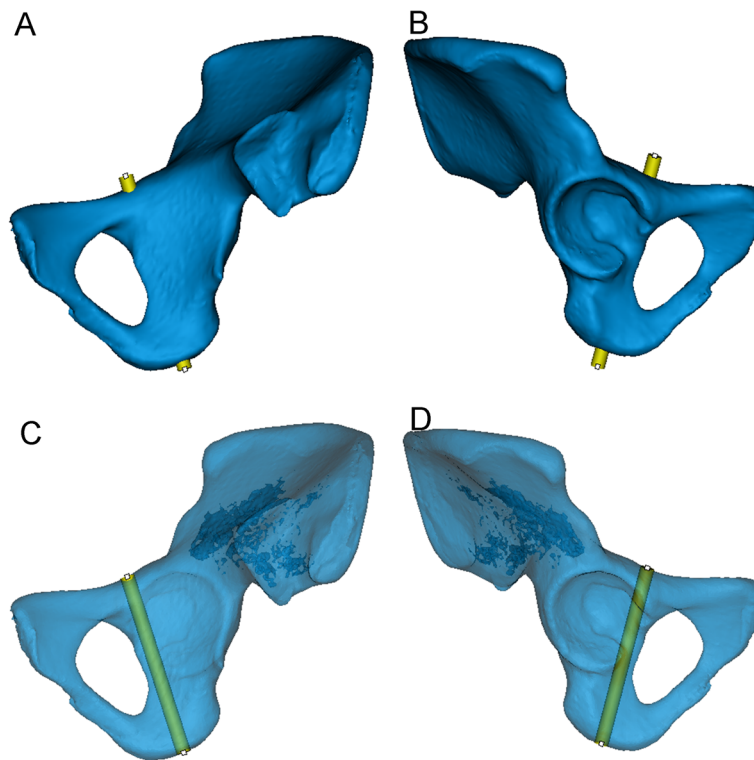


Fig. 2 The position of the virtual screw was verified in the 3D model. **A, B** Observed from the interior and exterior of the opaque 3D model, respectively. The screw has the largest diameter without penetrating the cortical bone. **C, D** Adjusted to the optimal length of the screw from the translucent 3D model

plate was measured and recorded as angle α (Fig 4A). In addition, we defined a reference plane perpendicular to the medial surface of quadrilateral plate. The posterior inclination angle between the screw and the reference plane was also measured and recorded as angle β (Fig 4B).

The collected data were analyzed by SPSS 19.0 statistical software. The experimental data are represented as the mean \pm SD. T tests were used to compare the data. Statistical significance was accepted at $p < 0.05$.

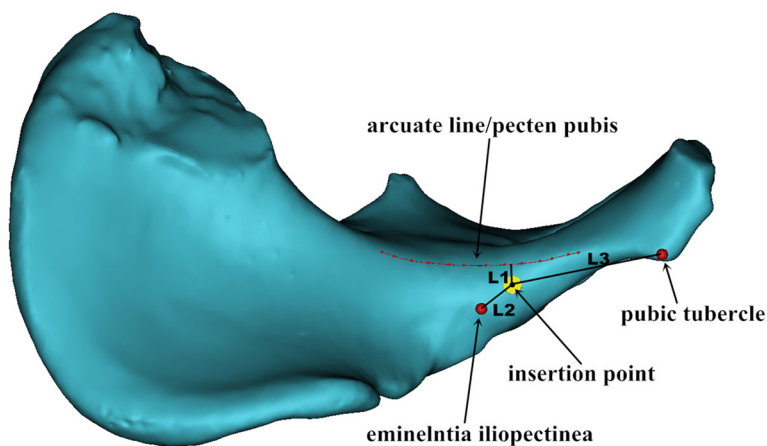


Fig. 3 The measurement of Distance L1, L2 and L3. The red curve represented the arcuate line/pecten pubis. The vertical distance from the insertion point to the red curve was recorded as L1. The distances from the insertion point to eminencia iliopectinea and pubic tubercle were recorded as L2 and L3, respectively

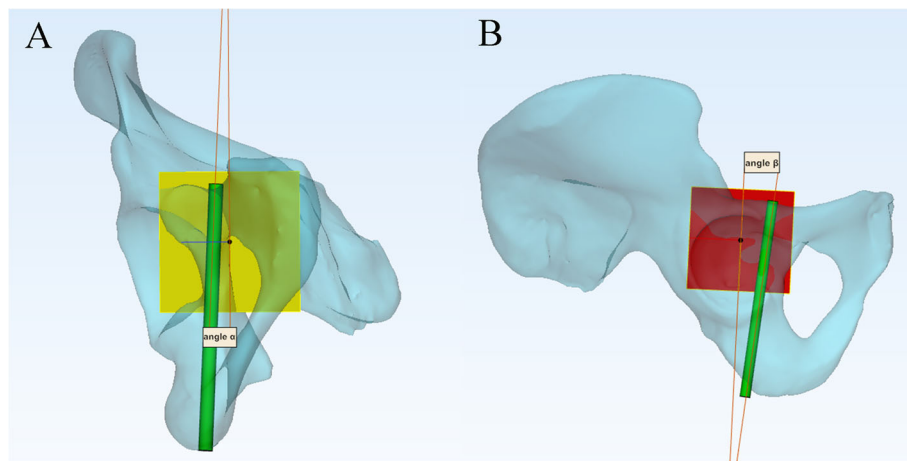


Fig. 4 The measurement of Angle α and β . The red plane represented the medial surface of quadrilateral plate. The yellow plane was perpendicular to the red plane. **A** View from the yellow plane, α was the lateral inclination angle between the screw and the red plane. **B** View from the red plane, β was the posterior inclination angle between the screw and the yellow plane

Results

The study subjects included 100 males and 100 females aged between 18 and 86 years old, with a mean age of 46.31 ± 14.19 years. As shown in Fig 1B, the screw insertion safe zone exhibited an irregular “tear drop” from the reconstructed pelvic model.

As shown in Tables 1 and 2, the mean maximum diameter of screws was 5.01 ± 1.28 mm and the mean maximum length of screws was 93.99 ± 8.92 mm. The mean distance L1 was 5.99 ± 3.14 mm, L2 was 14.45 ± 3.18 mm, and L3 was 45.81 ± 6.40 mm, respectively. For the data captured above, the intersex difference was significant ($P < 0.05$).

The mean angle α and β of different genders were also recorded in Table 3. The former was $-0.09^\circ \pm 4.39^\circ$ and the latter was $-1.90^\circ \pm 8.88^\circ$. However, the results were not statistically significant between males and females ($P > 0.05$).

The screw insertion corridor with a diameter of at least 3.5 mm was found in 94 of 100 males (94%) and 86 of 100 females (86%). However, the corridor with a diameter of at least 4.5 mm was found in 77 of 100 males (77%) and 53 of 100 females (53%) from the Fig 5.

Discussion

In recent years, the trend in treatment of acetabular fractures is achievement of less invasive single ilioinguinal approach, especially in elderly patients [14–18]. Due to the complex characteristic of pelvic anatomy, the safe region of screw placement is far away from the acetabulum, which will reduce the peri-acetabular stability [7]. The common fixation methods for acetabular fractures are positional screw fixation and plate osteosynthesis [10]. Past researches of positional screw fixation have achieved good outcomes [19, 20]. The infra-acetabular screw can be applied via a single ilioinguinal approach to treat acetabular fractures involving a fracture line descending along the acetabular fossa and reaching the obturator foramen [1]. So far, there is no literature that identifies this screw as a positioning screw for the posterior column, and few digital anatomical studies are conducted on its properties.

Mimics software has been widely used in 3D reconstruction for the development of digital orthopedics technology. In our study, we applied the 3D method of axial perspective that described in previous studies were

Table 1 Comparison between different genders: Diameters of screws, Lengths of screws

| Group | Diameter ^b (mm) | Length ^b (mm) |
|----------------------|----------------------------|--------------------------|
| All (n = 200) | 5.01 ± 1.28 | 93.99 ± 8.92 |
| Male (n = 100) | 5.54 ± 1.38 | 100.23 ± 6.37 |
| Female (n = 100) | 4.49 ± 0.90 | 87.74 ± 6.36 |
| t value ^a | 6.391 | 13.860 |
| P value ^a | 0.00 | 0.00 |

^at and P are the results of gender comparisons
^bFor the Diameter and Length, intersex difference was significant ($P < 0.05$)

Table 2 Comparison between different genders: L1, L2 and L3

| Group | L1 ^b (mm) | L2 ^b (mm) | L3 ^b (mm) |
|----------------------|----------------------|----------------------|----------------------|
| All (n = 200) | 5.99 ± 3.14 | 14.45 ± 3.18 | 45.81 ± 6.40 |
| Male (n = 100) | 7.16 ± 2.81 | 13.90 ± 2.58 | 47.14 ± 6.20 |
| Female (n = 100) | 4.82 ± 3.02 | 15.00 ± 3.61 | 44.48 ± 6.35 |
| t value ^a | 5.683 | -2.486 | 2.999 |
| P value ^a | 0.00 | 0.014 | 0.003 |

^at and P are the results of gender comparisons
^bFor the distance of L1, L2 and L3, intersex difference was significant ($P < 0.05$)

Table 3 Comparison between different genders: Angle α and β

| Group | α (°) | β (°) |
|----------------------|--------------|--------------|
| All (n = 200) | -0.09 ± 4.39 | -1.90 ± 8.88 |
| Male (n = 100) | 0.28 ± 4.78 | -1.99 ± 9.35 |
| Female (n = 100) | -0.46 ± 3.96 | -1.81 ± 8.43 |
| t value ^a | 1.204 | -0.147 |
| P value ^a | 0.230 | 0.883 |

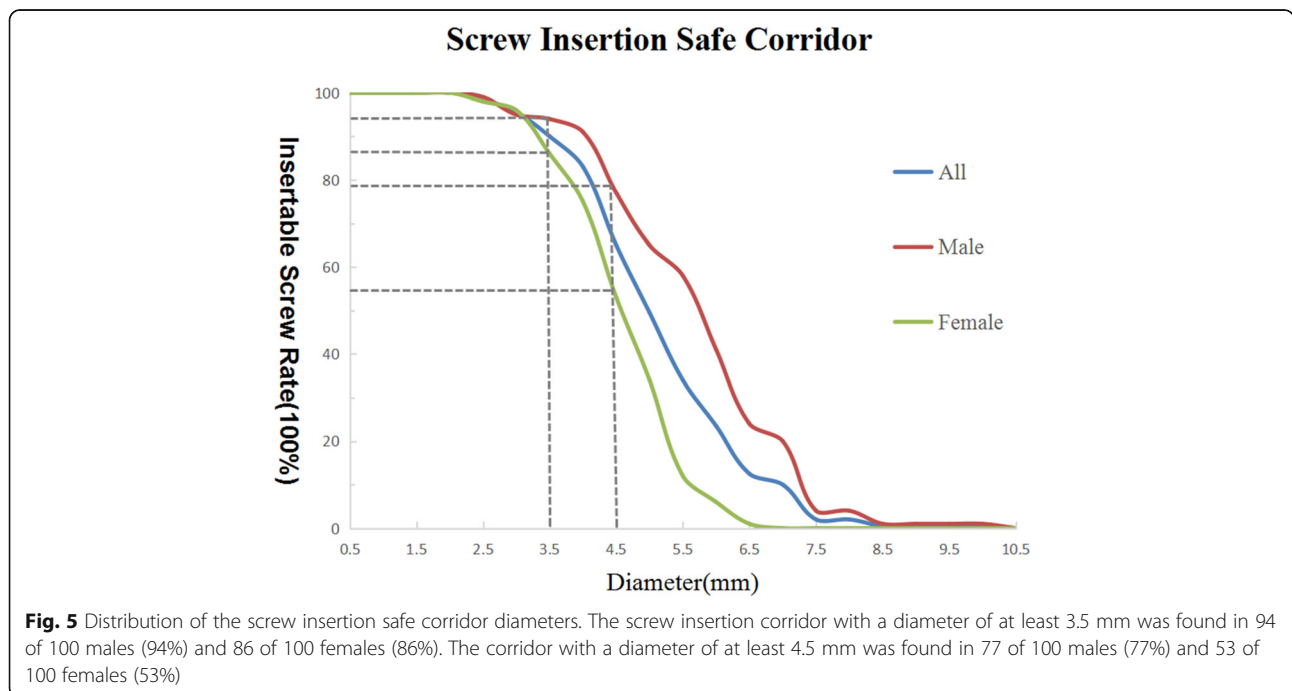
^at and P are the results of gender comparisons. For the Angle α , a negative value indicates a medial inclination. For the Angle β , a negative value indicates an anterior inclination

applied to simulate the surgical procedure [10, 11, 21]. We found the largest secure screw path along the longitudinal axis of the anterior part of posterior column after reducing the transparency of the 3D model. Compared with previous studies of computer-assisted determination or virtual three-dimensional model [12, 22], the method of axial perspective showed another osseous channel for positional screw of posterior column. We increased the diameter of virtual cylinder progressively and monitored the virtual screw in the views of coronal plane, sagittal plane and horizontal plane, without violating the cortices and articular surface. Compared with previous human cadaveric studies [23, 24], our method greatly saved manpower, material and financial resources, and can be repeated and verified through highly reliable test results.

In our research, the diameter and length of the infra-acetabular screw were significantly larger in males compared with females. In addition, the vertical distance from the insertion point to the arcuate line or pecten

pubis and the distances from the insertion point to eminentia iliopectinea and pubic tubercle were all measured in this study, which exhibited significant difference between genders. This was due to the obvious anatomic differences in pelvic bones between female and male. This study showed that the mean angle α and β between male and female had no statistical inference. From the Table 3, both angles were close to 0 degrees. This means that the screw is almost parallel to the medial surface of quadrilateral plate and perpendicular to the arcuate line.

Gras et al found that 93% pelvis contained an infra-acetabular corridor with a diameter of at least 5 mm [13]. They also provided reference values for placement of a 3.5-mm cortical screw in the corridor. However, in our study, we found that the containable diameter of the screw was smaller in Chinese patients, especially in female. According to the data in our study, the maximum diameter to avoid cortical breaches is 5.54 ± 1.38 mm in male and 4.49 ± 0.90 mm in female. The screw insertion corridor with a diameter of at least 3.5 mm was found in 94 of 100 males (94%) and 86 of 100 females (86%). Only 77 males (77%) and 53 females (53%) possessed a corridor with diameter of at least 4.5 mm as shown in Fig 5. If a positional screw is to be used, a 3.5-mm cortical screw is the first choice and a 4.5 mm-hollow screw may be considered in males. Nevertheless, due to individual and sex differences, the use of preoperative measurements and calculations by digital tools is recommended. Technically, to avoid joint violation, it is crucial to save the subcondral bone while trying to place a juxta articular screw, which requires the use of screws with a



smaller diameter than calculated by the preoperative CT scan. The screw diameter also depends on some other variables like the quality of the reduction and the direction of the screw, so surgeons should prepare different size of screws before the surgery.

On the basis of mastering the diameter and length of screw, the insertion point and direction are important factors affecting the safe placement of infra-acetabular screw. Unlike the common posterior column screw, the infra-acetabular screw needs to be placed through the middle window of ilioinguinal approach. Culemann et al reported that the entry point for the infra-acetabular screw was 1 cm caudal of the eminencia ilipectinea and in the middle of the pubic ramus [1]. Baumann et al found that the ideal entry point for the infra-acetabular screw was 10.2 mm caudal and 10.4 mm medial of the eminencia ilipectinea [7]. Gras et al found that the optimized entry points of infra-acetabular screws were located in the medio-caudal region of the eminencia ilipectinea [13]. Different from previous studies, we found that the optimized insertion point was 13.90 ± 2.58 mm away from the eminencia ilipectinea in males and 15.00 ± 3.61 mm in females. This is due to the different pelvic shapes between female and male. The anatomic landmark of eminencia ilipectinea and pubic tubercle can be used as effective references intraoperatively as they are large bony bumps that can be well palpable and identified. The parameters of the infra-acetabular screw may provide the surgeon appropriate information of safe positional screw placement for the treatment of acetabular fracture with separation of both columns. The large standard deviation of our results indicates great differences among individuals. As a result, preoperative planning should be implemented detailedly for each patient. 3D reconstruction and simulated screw placement technique with digital software before operation are valuable.

There are still some limitations to this study. We only analyzed the data based on genders, not different age groups. In addition, we did not collect data according to age, height, weight or body bone density. These factors may also affect the implantation of screws. We only studied the pelvises of Chinese people, who have different skeletal shapes with American and European populations. Thus, more biomechanical studies and related clinical research should be performed to compare the effect of the infra-acetabular screw with other acetabular screws.

Conclusion

We indicate a valuable guideline for seeking the largest secure corridor of infra-acetabular screw, which is used as a special posterior column positional screw. The ideal screw position and the size of the screws can be

determined in 3D-models by digital software. Further biomechanical studies are needed to verify the strength and effect of the screw.

Abbreviations

3-D: Three-dimensional; CT: Computed tomography; DICOM: Digital Imaging and Communication in Medicine; Mimics: Materialise's Interactive Medical Image Control System; SPSS: Statistical Package for the Social Sciences; SD: Standard deviation

Acknowledgements

Not applicable.

Authors' contributions

BZ, WZ performed the study, analyzed the data, and drafted the manuscript. HL, LRH and SZH contributed to discussion of data, writing, and editing of the article. XFY, JY and WDM contributed to conception and study design, and editing of the article. All authors read and approved the final manuscript. All authors have read the journal policies and have no issues relating to journal policies. All authors have seen the manuscript and approved to submit to your journal. The work described has not been submitted elsewhere for publication, in whole or in part.

Funding

No funding.

Availability of data and materials

The datasets generated and analyzed during the current study are available from the corresponding author on reasonable request.

Declarations

Ethics approval and consent to participate

This study has obtained ethics approval and consent of the ethics committee in Liaocheng People's hospital (NO. 2019037). Due to the retrospective nature of the study, informed consent was waived.

Consent for publication

Not applicable.

Competing interests

The authors declare that they have no conflict of interest.

Received: 23 November 2020 Accepted: 6 June 2021

Published online: 16 June 2021

References

- Culemann U, Marintschev I, Gras F, Pohlemann T. Infra-acetabular corridor—technical tip for an additional screw placement to increase the fixation strength of acetabular fractures. *J Trauma Acute Care Surg*. 2011; 70(1):244–6.
- Collinge CA, Lebus GF. Techniques for reduction of the quadrilateral surface and dome impaction when using the anterior intrapelvic (modified stoppa) approach. *J Orthop Trauma*. 2015;29:S20–4.
- Gras F, Marintschev I, Grossterlinden L, Rossmann M, Graul I, Hofmann GO. The anterior intra-pelvic approach for acetabular fractures utilizing approach specific instruments and an anatomical-preshaped, three dimensional suprapectineal plate. *J Orthop Trauma*. 2017;31(7):e210–6.
- Gras F, Marintschev I, Schwarz CE, Hofmann GO, Pohlemann T, Culemann U. Screw- versus plate-fixation strength of acetabular anterior column fractures: A biomechanical study. *J Trauma Acute Care Surg*. 2012;72(6):1664–70.
- Marintschev I, Gras F, Schwarz CE, Pohlemann T, Hofmann GO, Culemann U. Biomechanical comparison of different acetabular plate systems and constructs—the role of an infra-acetabular screw placement and use of locking plates. *Injury Int J Care Injured*. 2012;43(4):470–4.
- White G, Kanakaris NK, Faour O, Valverde JA, Martin MA, Giannoudis PV. Quadrilateral plate fractures of the acetabulum: an update. *Injury*. 2013;44(2): 159–67.
- Baumann F, Schmitz P, Mahr D, Kerschbaum M, Gänsslen A, Nerlich M. A guideline for placement of an infra-acetabular screw based on anatomic landmarks via an intra-pelvic approach. *J Orthop Surg Res*. 2018;13(1):77.

8. Letournel E, Judet R. Fractures of the acetabulum. New York: Springer; 1993.
9. Schwabe P, Altintas B, Schaser KD, Druschel C, Kleber C, Haas NP, et al. Three-dimensional. Fluoroscopy-navigated percutaneous screw fixation of acetabular fractures. *J Orthop Trauma*. 2014;28(12):700–6.
10. Feng X, Zhang S, Luo Q, Fang J, Lin C, Leung F, et al. Definition of a safe zone for antegrade lag screw fixation of fracture of posterior column of the acetabulum by 3D technology. *Injury*. 2016;47(3):702–6.
11. Feng X, Fang J, Lin C, Zhang S, Lei W, Li Y, et al. Axial perspective to find the largest intraosseous space available for percutaneous screw fixation of fractures of the acetabular anterior column. *Int J Comput Assist Radiol Surg*. 2015;10(8):1347–53.
12. Puchwein P, Enninghorst N, Sisak K, Ortner T, Schildhauer TA, Balogh ZJ, et al. Percutaneous fixation of acetabular fractures: computer-assisted determination of safe zones, angles and lengths for screw insertion. *Arch Orthop Trauma Surg*. 2012;132(6):805–11.
13. Gras F, Gottschling H, Schröder M, Marintschev I, Reimers N, Burgkart R. Sex-specific differences of the infraacetabular corridor: a biomorphometric CT-based analysis on a database of 523 pelvis. *Clin Orthop Relat Res*. 2015; 473(1):361–9.
14. Ochs BG, Marintschev I, Hoyer H, Culemann U, Pohlemann T, Stuby FM. Changes in the treatment of acetabular fractures over 15 years: analysis of 1266 cases treated by the German Pelvic Multicentre Study Group (DAO/ DGU). *Injury Int J Care Injured*. 2012;41(8):839–51.
15. Guerado E, Cano JR, Cruz E. Fractures of the acetabulum in elderly patients: an update. *Injury*. 2012;43(Suppl 2):S33–41.
16. Zhuang Y, Zhang K, Wang H, Wei X, Liu P, Wang PF, et al. A short buttress plate fixation of posterior column through single ilioinguinal approach for complex acetabular fractures. *Int Orthop*. 2017;41(1):165–71.
17. Kaifang C, Yanhui J, Zhenfei H, Ramphul N, Fan Y, Tingfang S, et al. A single modified ilioinguinal approach for the treatment of acetabular fractures involving both columns. *J Orthop Trauma*. 2018;32(11):1.
18. Fensky F, Lehmann W, Ruecker A, Rueger JM. Ilioinguinal approach: indication and technique. *J Orthop Trauma*. 2018;32(Suppl 1):S12–3.
19. Stöckle U, Hoffmann R, Nittinger M, Südkamp NP, Haas NP. Screw fixation of acetabular fractures. *Int Orthop*. 2000;24(3):143–7.
20. Chang JK, Gill SS, Zura RD, Krause WR, Wang GJ. Comparative strength of three methods of fixation of transverse acetabular fractures. *Clin Orthop Relat Res*. 2001;392(392):433–41.
21. Jung GH, Lee Y, Kim JW, Kim JW. Computational analysis of the safe zone for the antegrade lag screw in posterior column fixation with the anterior approach in acetabular fracture: a cadaveric study. *Injury*. 2017;48(3):608–14.
22. Attias N. The use of a virtual three-dimensional model to evaluate the intraosseous space available for percutaneous screw fixation of acetabular fractures. *J Bone Joint Surg Br*. 2005;87-B(11):1520–3.
23. Dienstknecht T, Müller M, Sellei R, Nerlich M, Pfeifer C, Krutsch W, et al. Percutaneous screw placement in acetabular posterior column surgery: gender differences in implant positioning. *Injury*. 2014;45(4):715–20.
24. Dienstknecht T, Müller M, Sellei R. Screw placement in percutaneous acetabular surgery: gender differences of anatomical landmarks in a cadaveric study. *Int Orthop*. 2013;37(4):673–9.

Publisher's Note

Springer Nature remains neutral with regard to jurisdictional claims in published maps and institutional affiliations.

Ready to submit your research? Choose BMC and benefit from:

- fast, convenient online submission
- thorough peer review by experienced researchers in your field
- rapid publication on acceptance
- support for research data, including large and complex data types
- gold Open Access which fosters wider collaboration and increased citations
- maximum visibility for your research: over 100M website views per year

At BMC, research is always in progress.

Learn more biomedcentral.com/submissions

