

# Direct Puncture Cholangiography for Clarifying Difficult Anatomy

M Ezzedien Rabie, MSc, FRCSI, FRCSEd

## ABSTRACT

Laparoscopic cholecystectomy is a very frequently performed procedure. Its most dreadful complication is bile duct injury. Difficulty in appreciating the biliary anatomy plays an important role in its causation. Here we describe our technique in clarifying the difficult anatomy by directly injecting the radiologic contrast in the ambiguous area, and thus avoiding a potential injury.

**Key Words:** Bile duct, Cholangiography, Anatomy.

## INTRODUCTION

Shortly after its inception, laparoscopic cholecystectomy (LC) became the gold standard for cholecystectomy. Its perceived advantages over the open procedure convinced the surgical fraternity to embrace it without prior validation through randomized trials. An upsurge of LC followed, with 1.6 million procedures performed in the United States between 1992 and 1996 alone.<sup>1</sup> This upsurge was accompanied by an associated increase in the rate of bile duct injuries, certainly due to unfamiliarity with the laparoscopic techniques. In this technical report, we present an unconventional way of performing peroperative cholangiography, which was utilized in 2 cases and helped to prevent biliary injury in one of them.

## CASE REPORTS

### First Case

A 31-y-old female, with no chronic medical illness, presented with vomiting and upper abdominal pain radiating to the back for 2 days duration. The patient sought medical advice in another hospital where ultrasound examination showed cholelithiasis with dilated biliary radicles.

On examination, her vital signs were normal as well as her chest and heart, but there was minimal tenderness in the epigastrium and right upper quadrant of the abdomen.

Laboratory investigations showed a normal blood count and deranged liver enzymes. Her alkaline phosphatase was 236U/L (reference range, 36 to 126), alanine aminotransferase 513U/L, (reference range, 30 to 56) aspartate aminotransferase 722U/L (reference range, 10 to 42), gamma glutamyl transferase 205U/L (reference range, 5 to 64), total bilirubin 35  $\mu\text{mol/mL}$ , (reference range, 3 to 17) direct bilirubin 13  $\mu\text{mol/mL}$  (reference range, 0 to 8), and amylase was 27U/L (reference range, 27 to 130).

The patient was admitted as a case of obstructive jaundice and was allowed a fat-free diet.

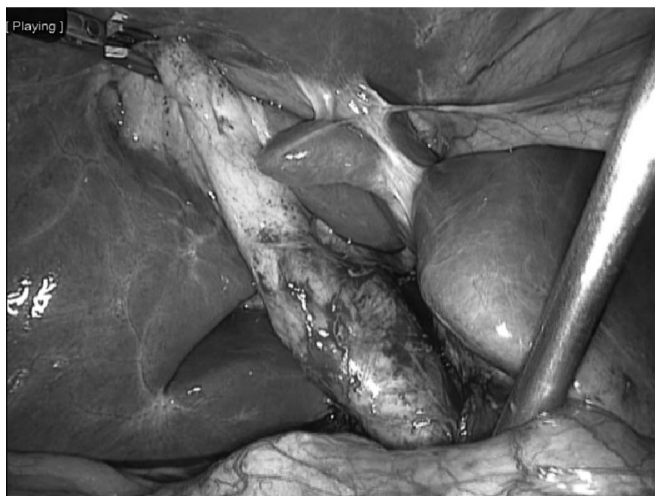
An ultrasound scan confirmed the presence of gallstones in a thick-walled gallbladder with pericholecystic fluid

Department of Surgery, Armed Forces Hospital, Southern Region, Saudi Arabia

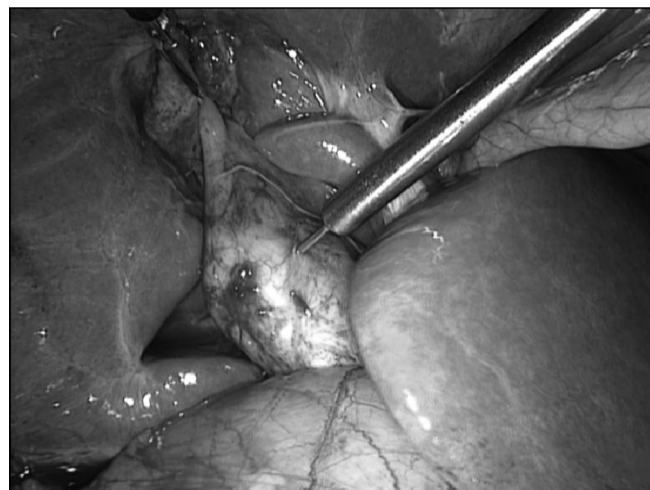Address correspondence to: M Ezzedien Rabie, Department of Surgery, Armed Forces Hospital, Southern Region, PO Box 101-Khamis Mushait-Saudi Arabia. Telephone: 00966 50775 3692, E-mail: ezzedien@hotmail.com

DOI: 10.4293/108680813X13693422521124

© 2013 by JSLs, *Journal of the Society of Laparoendoscopic Surgeons*. Published by the Society of Laparoendoscopic Surgeons, Inc.



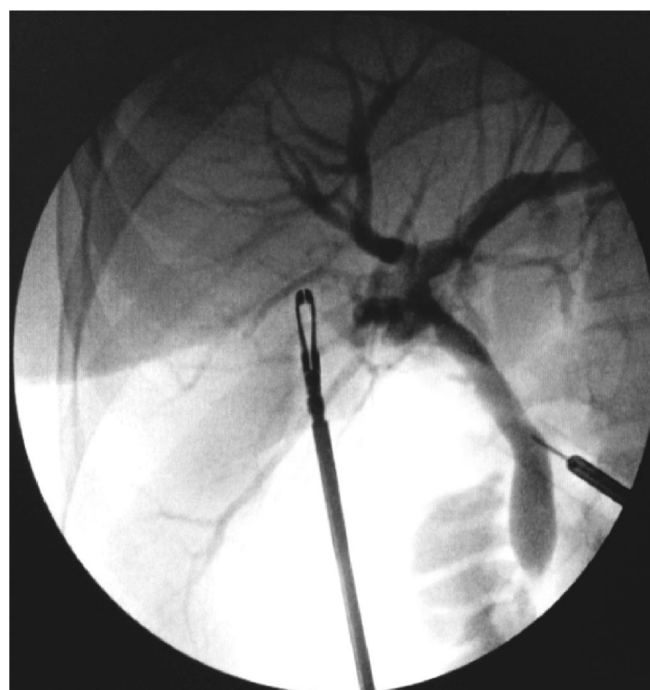
**Figure 1.** Extension of the lower part of the “gallbladder” behind the duodenum.



**Figure 2.** Injection of the contrast into what appeared to be the lower part of the gallbladder.

collection. The common bile duct (CBD) measured 7 mm, and there was a stone in its lower end with dilatation of the intrahepatic biliary radicles. Endoscopic retrograde cholangiopancreatography (ERCP) was attempted, but the presence of a scarred papilla prevented CBD cannulation. In the meantime, the patient desaturated and the procedure was terminated. Reattempted ERCP with the patient under general anaesthesia succeeded to clear the CBD from different-sized stones, and the free drainage of bile was established.

Three days later, a laparoscopic cholecystectomy was performed. The procedure was initiated by creating the pneumoperitoneum, utilizing a Veress needle through an umbilical incision, and the laparoscope was inserted. This was followed by inserting 3 more ports according to the standard procedure. The gallbladder was then grasped at the fundus, and retracted in a cephalad and lateral direction. The lower part of the gallbladder appeared to extend downwards behind the duodenum (**Figure 1**), raising the possibility of it being the CBD. Intraoperative cholangiography was performed using the direct puncture technique, with the laparoscopic aspiration cannula inserted into the target region (**Figure 2**). At this point, it was immediately evident that this was in fact the CBD (**Figure 3**). Due to the uncertainty of the limits between the gallbladder and the CBD, conversion to open cholecystectomy was performed. Postoperatively, the patient tolerated the procedure well and was discharged for outpatient follow-up, where she appeared 2 weeks later in good health.



**Figure 3.** What appeared to be the gallbladder proved to be the common bile duct after contrast injection.

### Second Case

A 56-y-old male with no past medical history, presented with upper abdominal pain of 4 days duration. The pain radiated to the back and was associated with discoloration of the eyes. On examination, his vital signs were normal as were his chest and heart, but there was mild tenderness in the right hypochondrium.

His blood results, coagulation profile, renal values and electrolytes were all normal. His liver enzymes showed alkaline phosphatase of 167U/L (reference range, 36 to 126), gamma glutamyl transferase 184U/L (reference range, 5 to 64) alanine aminotransferase 419U/L (reference range, 30 to 56) aspartate aminotransferase 310U/L (reference range, 10 to 42), total bilirubin 111  $\mu\text{mol/L}$  (reference range, 3 to 17), direct bilirubin 74  $\mu\text{mol/L}$  (reference range, 0 to 8).

An ultrasound scan showed mild fatty changes of the liver and gallstones in a thick-walled gallbladder, with no intra- or extrahepatic biliary dilatation. Magnetic resonance cholangiopancreatography (MRCP) showed a small filling defect in the lower end of the common bile duct that was cleared by endoscopic retrograde cholangiopancreatography (ERCP) and a small stone retrieved.

Laparoscopic cholecystectomy was performed 2 days later after the serum amylase level came down to normal after an initial post-ERCP rise to 403U/L (reference range, 27 to 130).

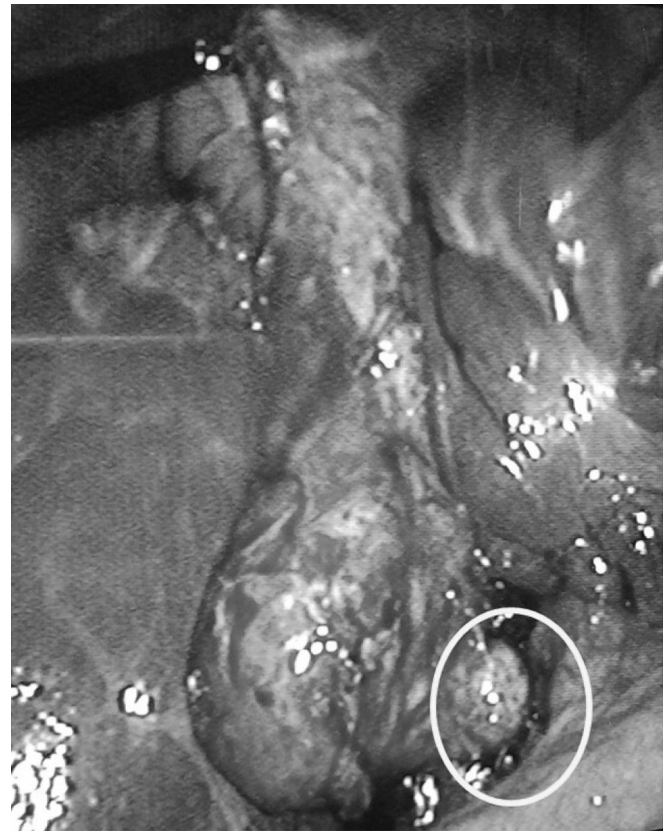The procedure started as previously described, and the fundus was retracted upward in a cephalad direction. The lower half of the gallbladder was covered by omentum and adherent duodenum. Tedious blunt dissection teased these tissues down, exposing the covered part of the gallbladder, which took an unusual L-shaped configuration, ending in a tapered portion (**Figure 4**).

Because there was some anatomic uncertainty, a peroperative cholangiography was performed by injecting the contrast directly into the tapered portion, which then proved to be the cystic duct (**Figure 5**). It was divided between clips, and the gallbladder was removed after the cystic artery was controlled. A drain was inserted into the subhepatic region and the operation was concluded.

Postoperatively, the patient tolerated the procedure well; the drain was removed 2 days later and he was discharged. Unfortunately, he returned 3 weeks later with a subhepatic collection, which was successfully drained percutaneously, with no ill effects.

## DISCUSSION

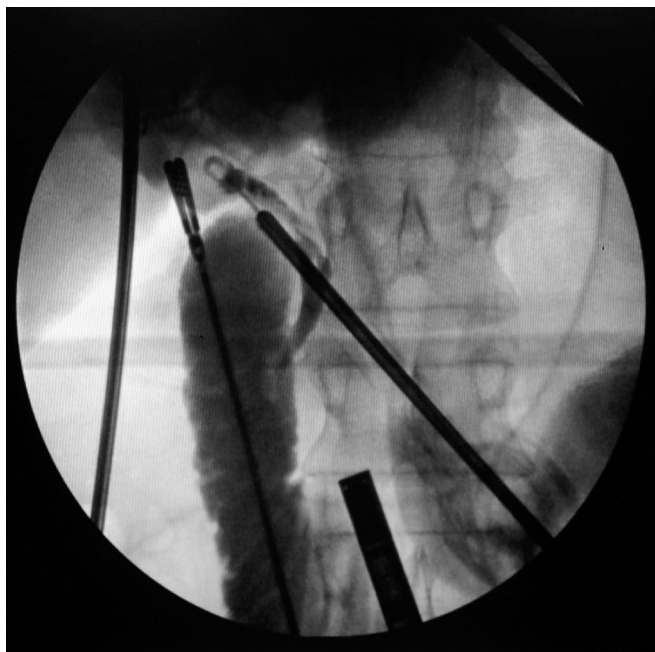Although the initial high incidence of biliary injury rate associated with laparoscopic cholecystectomy has decreased, it remains higher than that of the open procedure. A rate of 0.5% has been attributed to laparoscopic cholecystectomy, compared to 0.2% of its open counterpart.<sup>2</sup> Moreover, the severity of laparoscopic injuries is usually greater than that of the open technique.<sup>3</sup> The most



**Figure 4.** The gallbladder with L shaped configuration tapering down (white circle).

common cause of iatrogenic bile duct injury is failure to identify the anatomy, with the surgeon's misperception playing a prominent role.<sup>4</sup> Acute cholecystitis, the inexperience of the surgeon, and anatomic uncertainty are definite risk factors for CBD injury.<sup>2,5</sup> On occasions, the CBD has been mistaken for the cyst duct and consequently severed.<sup>6</sup>

There are many variations of the biliary anatomy, the appreciation of which may be made more difficult by the inherent limitations of laparoscopic surgery, with lack of depth perception and the absence of direct tactile sensation. In this regard, intraoperative cholangiography and ultrasonography offer a great help in verifying any anatomic ambiguity. Intraoperative cholangiography may be performed by injecting the contrast directly into the gallbladder (cholecystocholangiography) or, more commonly, the cystic duct, the latter being the standard technique. Cystic duct catheterization is usually performed by clipping the duct at its junction with the gallbladder, then nicking it below the clip to thread the cholangiocatheter.<sup>7</sup> Its major disadvantage is that if the supposed cystic duct



**Figure 5.** The injected contrast visualized the mucosal valves of the cyst duct.

was in reality the common bile duct, biliary damage would occur, resulting in a Stewart and Way type 1 injury,<sup>4</sup> which requires a delicate repair.

Laparoscopic ultrasound (LUS) is another imaging modality used to detect CBD stones and to verify biliary anatomy,<sup>8</sup> but training and familiarity with the techniques are prerequisites for its adoption. Additionally, it may not provide accurate anatomic details, and the findings might need confirmation with intraoperative cholangiography, resulting in an unnecessary waste of time.

Currently, the debate over the routine versus selective use of intraoperative cholangiography is still running.<sup>9,10</sup> In one study, its routine use decreased the incidence and severity of CBD injury and increased its intraoperative recognition rate. However, it did not completely prevent it.<sup>11</sup>

Certain operative strategies have been recommended to avoid biliary injury. The creation of the critical view of safety, introduced by Strasberg in 1995,<sup>12</sup> is one such strategy.<sup>13,14</sup> Although this is true in the many cases, in others, performing the necessary dissection may be hampered by the presence of dense adhesions in the region, as observed in the second case presented here.

In our practice, we perform preoperative cholangiography on a selective basis, according to the standard technique during which the cystic duct is catheterized, if this duct can be easily dissected and isolated. In the presence of dense adhesions in the area or uncertainty of the anatomy, we directly puncture the target spot for the injection of the contrast. As was observed in the cases reported here, the uncertainty immediately unfolds, with the needle serving as a landmark to where we exactly are. In this way, CBD injury is avoided, as no harm results from the needle puncture.

## CONCLUSION

Direct puncture cholangiography is a simple technique, which can be applied during difficult laparoscopic cholecystectomy procedures. In the presence of anatomic uncertainty, the injection of the contrast directly into the target location may clarify the anatomy and thus help to avoid a potential CBD injury. It should be considered as an addition to the surgeon's armamentarium during laparoscopic cholecystectomy.

## References:

1. Flum DR, Cheadle A, Prael C, Dellinger EP, Chan L. Bile duct injury during cholecystectomy and survival in Medicare beneficiaries. *2003*;290(16):2168–73.
2. Hunter JG, Thompson SK. Laparoscopic cholecystectomy, intraoperative cholangiography, and common bile duct exploration. *Mastery of Surgery*. 5th ed. JE Fischer, Editors. Philadelphia: Lippincott Williams & Wilkins 2007;1116–1128.
3. Slater K, Strong RW, Wall DR, Lynch SV. Iatrogenic bile duct injury: the scourge of laparoscopic cholecystectomy. *Aust NZ J Surg*. 2002;72(2):83–88.
4. Way LW, Stewart L, Gantert W, et al. Causes and prevention of laparoscopic bile duct injuries: analysis of 252 cases from a human factors and cognitive psychology perspective. *Ann Surg*. 2003;237(4):460–469.
5. Georgiades CP, Mavromatis TN, Kourlaba GC, et al. Is inflammation a significant predictor of bile duct injury during laparoscopic cholecystectomy? *Surg Endosc*. 2008;22(9):1959–1964. Epub 2008 Apr 29.
6. Zha Y, Chen XR, Luo D, Jin Y. The prevention of major bile duct injuries in laparoscopic cholecystectomy: the experience with 13,000 patients in a single center. *Surg Laparosc Endosc Percutan Tech*. 2010;20(6):378–383.
7. Fried GM, Ferri LE, Hsu KE. Laparoscopic cholecystectomy. In: Soper NJ, Swanstrom LL, Eubanks WS, Leonard ME, eds. *Mastery of Endoscopic and Laparoscopic Surgery: Indications and*

*Techniques*, 3rd Edition. Philadelphia: Lippincott Williams & Wilkins 2009;300–308.

8. Hublet A, Dili A, Lemaire J, Mansvelt B, Molle G, Bertrand C. Laparoscopic ultrasonography as a good alternative to intraoperative cholangiography (IOC) during laparoscopic cholecystectomy: results of prospective study. *Acta Chir Belg*. 2009;109(3):312–316.

9. Sharma AK, Cherry R, Fielding JW. A randomised trial of selective or routine on-table cholangiography. *Ann R Coll Surg Engl*. 1993;75(4):245–248.

10. Jiang H, Wu H, Pankaj P, Qiu J, Zeng Y. Is laparoscopic intraoperative cholangiogram the method of choice? A review of the literature. *Hepatogastroenterology*. 2011;58(110–111). doi: 10.5754/hge11119. Epub 2011 Jul 15.

11. Debru E, Dawson A, Leibman S, et al. Does routine intraoperative cholangiography prevent bile duct transection? *Surg Endosc*. 2005;19(4):589–593. Epub 2005 Mar 11.

12. Strasberg SM, Hertl M, Soper NJ. An analysis of the problem of biliary injury during laparoscopic cholecystectomy. *J Am Coll Surg* 1995;180:105.

13. Yamashita Y, Kimura T, Matsumoto S. A safe laparoscopic cholecystectomy depends upon the establishment of a critical view of safety. *Surg Today*. 2010;40(6):507–513. Epub 2010 May

14. Avgerinos C, Kelgiorgi D, Touloumis Z, Baltatzi L, Dervenis C. One thousand laparoscopic cholecystectomies in a single surgical unit using the “critical view of safety” technique. *J Gastrointest Surg*. 2009;13(3):498–503. Epub 2008 Nov 14.