

Available online at www.sciencedirect.com

ScienceDirect

journal homepage: www.elsevier.com/locate/radcr

Case Report

Imaging appearance of cystic and solid mesothelioma of the tunica vaginalis [☆]

Tanner D. Hannappel, BS, M4^a, Matthew J. DeVries, MD^{b,c}, Neil J. Hansen, MD^{b,c,*}

^a University of Nebraska College of Medicine, Omaha, NE, USA

^b University of Nebraska Medical Center, Omaha, NE, USA

^c Department of Radiology, 981045 Nebraska Medical Center, Omaha, NE 68198-1045, USA

ARTICLE INFO

Article history:

Received 30 January 2020

Revised 6 April 2020

Accepted 7 April 2020

Keywords:

Tunica vaginalis

Mesothelioma

Ultrasound

CT

ABSTRACT

We present the case of a 32-year-old male who presented with a growing scrotal mass initially diagnosed as benign adenomatoid tumor on ultrasound 6 years prior. Repeat ultrasound showed an abnormal extra-testicular mass with nodular and cystic components and internal vascularity. A computed tomography scan of the abdomen and pelvis confirmed a right extra-testicular scrotal mass with cystic and solid enhancing components. The patient underwent radical orchiectomy and postoperative pathology diagnosed mesothelioma of the tunica vaginalis of the testis. Mesothelioma of the tunica vaginalis of the testis is an exceptionally rare disease. We discuss the risk factors, imaging features, and treatment strategies of the disease.

© 2020 The Authors. Published by Elsevier Inc. on behalf of University of Washington.

This is an open access article under the CC BY-NC-ND license.

(<http://creativecommons.org/licenses/by-nc-nd/4.0/>)

Case report

A 32-year-old male with intellectual disability was found to have fullness of his right scrotum during physical examination of a routine healthcare maintenance appointment. An extra-testicular mass had been found at a prior appointment 6 years earlier and ultrasound at that time found both testicles were normal in size and echotexture, with normal Doppler blood flow. A small, solid, hypoechoic extra-testicular mass was found located just superior to the right testicle that measured 0.9 × 0.4 centimeters (cm). The mass was interpreted as a benign adenomatoid tumor (Fig. 1). On repeat ultrasound 6 years later, a moderate-sized hydrocele within the right

scrotal sac was seen along with an abnormal area measuring 6.0 × 3.2 × 4.4 cm superior and lateral to the right testicle. This abnormal area consisted of cystic and solid nodular areas with the solid components showing internal vascularity / Doppler flow (Fig. 2). These findings were suspicious for neoplasm, so further evaluation with computed tomography (CT) imaging of the abdomen and pelvis was obtained (Fig. 3). Given the presence of an enlarging cystic and solid extra testicular right scrotal mass, the patient was referred to Urology.

Subsequently, the patient underwent radical orchiectomy of his right testicle and the specimens were sent for pathology. Pathology confirmed mesothelioma of the tunica vaginalis with negative margins for tumor. The patient was determined not to be a candidate for chemotherapy, and

[☆] Competing Interests: None of the authors or their immediate family members have relevant conflicts of interest, financial or otherwise.

* Corresponding author.

E-mail address: njhansen@unmc.edu (N.J. Hansen).

<https://doi.org/10.1016/j.radcr.2020.04.004>

1930-0433/© 2020 The Authors. Published by Elsevier Inc. on behalf of University of Washington. This is an open access article under the CC BY-NC-ND license. (<http://creativecommons.org/licenses/by-nc-nd/4.0/>)

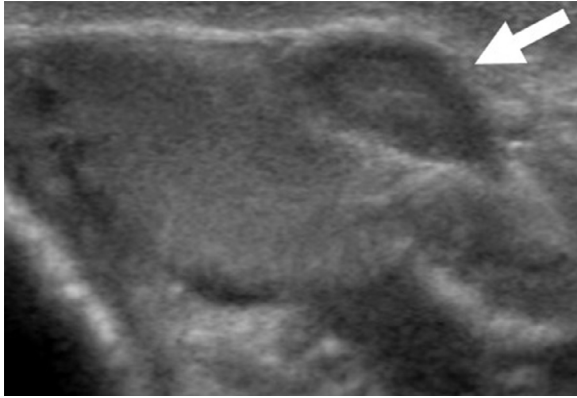


Fig. 1 – Axial grayscale ultrasound image of the right testicle. Well defined hypoechoic extra-testicular mass adjacent to the right testicle (arrow), seen 6 years previous.

given the negative tumor margins and unestablished role of adjunctive therapies, it was decided a careful surveillance approach was to be the course of action.

Discussion

Mesothelioma of the tunica vaginalis of the testis is a particularly rare malignancy with less than 250 documented cases since 1957 [1,2]. Malignant mesotheliomas, although uncommon in their own right, most often arise from the mesothelial cells of the pleura or peritoneum, but can also form in the pericardium and tunica vaginalis of the testis. Mesothelioma can develop from the tunica vaginalis due to its embryologic development, originating from the peritoneum as the testes descend out of the abdomen [3,4]. Malignant mesothelioma of the tunica vaginalis accounts for less than 1% of all malignant mesotheliomas [1,5].

The most widely established risk factor for malignant mesotheliomas is asbestos exposure, however, as is seen with pleural and peritoneal mesotheliomas, this risk factor has only been identified in about 35% of cases of mesothelioma of the tunica vaginalis [6,7]. Other reported risk factors include chronic hydrocele, trauma, radiation, and recurrent epididymitis [2,8]. The patient presented here did not have any known risk factors for mesothelioma. In general, mechanisms that cause chronic irritation and inflammation of the tunica vaginalis are thought to be an underlying cause of the mesothelioma, although due to the distinct rarity of the disease, there is limited epidemiologic data available to study [5].

The most common initial presentation of mesothelioma of the tunica vaginalis is painless scrotal enlargement [6]. In one study of 74 published case reports of mesothelioma of the tunica vaginalis, the preoperative diagnosis in over half of the cases was a hydrocele with another third of the cases diagnosed as a testicular tumor [7]. In many cases, patients undergo surgery for these indications with the definitive diagnosis only being made postoperatively at pathologic examination secondary to its nonspecific imaging findings and scarcity [1,9]. A variety of imaging appearances of mesothelioma of the tunica vaginalis have been described, in spite of their rarity. Common features on ultrasonography include the presence of a simple or complex hydrocele with nodular or plaque-like masses of either solid or mixed internal structures arising from the wall [10]. These lesions are often hypervascular on Doppler. The tunica vaginalis can also be thickened or hyperemic [4,8].

Radical orchiectomy is the primary treatment option for mesothelioma of the tunica vaginalis, especially in patients with localized disease [11]. Mesothelioma of the tunica vaginalis recurs at a rate of around 11% with radical orchiectomy, compared to 35% for patients who underwent conservative surgical management with local resection of hydrocele wall only [7]. The role for adjunctive therapies is not well established, as varying treatment strategies involving chemotherapy and radiotherapy have shown little benefit [7]. Prognosis of

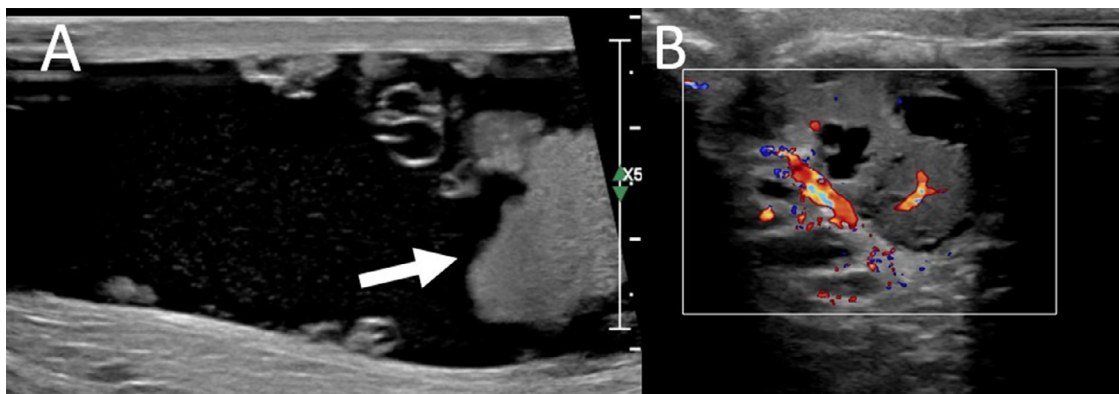


Fig. 2 – (A) Axial grayscale ultrasound image of the scrotum adjacent to the testicle. A large right hydrocele is present with a diffuse cystic and solid extra testicular mass (arrow). (B) Color Doppler image at the level of the mass shows internal vascular flow.

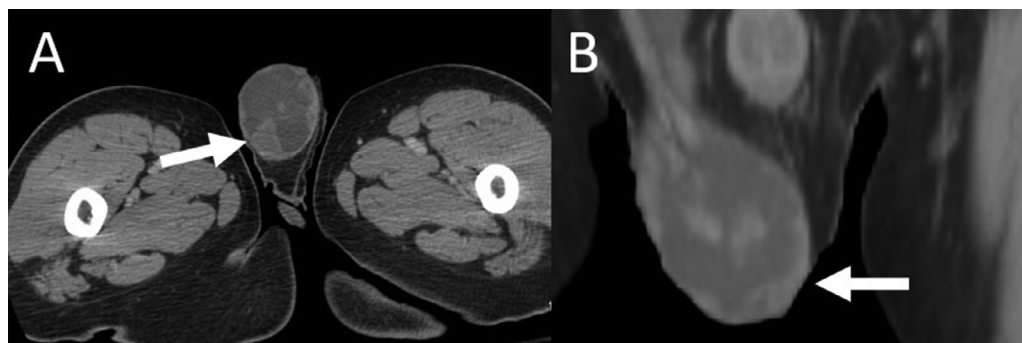


Fig. 3 – (A) Axial contrast enhanced computed tomography image at the level of the scrotum. The large right hydrocele is again seen, with solid (arrow) and cystic extra-testicular nodules. (B) Coronal contrast enhanced CT image shows the enhancing nodules (arrow) within the right hydrocele extending superiorly to the level of the inguinal canal.

the disease is difficult to predict, with varying results in individual case reports. One study reported a median survival time of 23 months and an overall recurrence rate of around 50% [7]. The most important prognostic factor in mesothelioma of the tunica vaginalis is age, as younger patients tend to do better than older patients [3].

REFERENCES

- [1] Nazemi A, Nassiri N, Pearce S, Daneshmand S. Testicular Mesothelioma: an analysis of epidemiology, patient outcomes, and prognostic factors. *Urology* 2019;126:140–4.
- [2] Baqui AA, Boire NA, Baqui TT, Etwaru DJ. Malignant Mesothelioma of the Tunica Vaginalis Testis-A Malignancy Associated With Asbestos Exposure and Trauma: A Case Report and Literature Review. *J Investig Med High Impact Case Rep* 2019;7:2324709619827335.
- [3] Hassan R, Alexander R. Nonpleural mesotheliomas: mesothelioma of the peritoneum, tunica vaginalis, and pericardium. *Hematol Oncol Clin North Am* 2005;19(6):1067–87 vi.
- [4] Garriga V, Serrano A, Marin A, Medrano S, Roson N, Pruna X. US of the tunica vaginalis testis: anatomic relationships and pathologic conditions. *Radiographics* 2009;29(7):2017–32.
- [5] Mezei G, Chang ET, Mowat FS, Moolgavkar SH. Epidemiology of mesothelioma of the pericardium and tunica vaginalis testis. *Ann Epidemiol* 2017;27(5):348–59 e311.
- [6] Punatar CB, Jadhav KK, Kumar V, Sagade SN. Malignant mesothelioma of tunica vaginalis without any risk factors: An uncommon case. *J Cancer Res Ther* 2019;15(Supplement):S167–9.
- [7] Plas E, Riedl CR, Pflüger H. Malignant mesothelioma of the tunica vaginalis testis: review of the literature and assessment of prognostic parameters. *Cancer* 1998;83(12):2437–46.
- [8] Chekol SS, Sun CC. Malignant mesothelioma of the tunica vaginalis testis: diagnostic studies and differential diagnosis. *Arch Pathol Lab Med* 2012;136(1):113–17.
- [9] Mrinakova B, Kajo K, Ondrusova M, Simo J, Ondrus D. Malignant Mesothelioma of the Tunica Vaginalis Testis. A Clinicopathologic Analysis of Two Cases with a Review of the Literature. *Klin Onkol* 2016;29(5):369–74.
- [10] Bertolotto M, Boulay-Coletta I, Butini R. Imaging of mesothelioma of tunica vaginalis testis. *Eur Radiol* 2016;26(3):631–8.
- [11] Brun C, Giusiano S, Thiam K, Guinde J, Froudarakis M, Astoul P. The necessity of a more aggressive initial surgical treatment in patients with mesothelioma of the testicular tunica vaginalis. *Ann Med Surg (Lond)* 2019;47:57–60.