

A rare case of an acute type B aortic dissection contained infrarenal rupture of the false lumen after prior endovascular abdominal aneurysm repair

Elena Streck, MD, Yaser Souri, MD, and Alexander Hyhlik-Dürr, MD, Augsburg, Germany

ABSTRACT

New-onset acute type B aortic dissection after prior endovascular aneurysm repair is extremely rare. Extension of an aortic dissection can cause destabilization of the previously implanted stent graft, thrombosis of the stent graft, and rupture of the aneurysmal sac, with high mortality without therapy. This report describes the case of a 66-year-old patient complaining of sudden abdominal pain radiating to both flanks. Computed tomography angiography of the aorta revealed acute type B aortic dissection with infrarenal rupture of the false lumen after endovascular abdominal aneurysm repair 5 years prior. The patient underwent infrarenal open surgical conversion with suprarenal aortic clamping and implantation of a bifurcated Dacron graft. Postoperatively, no serious complications resulted from the treatment, except for fascial dehiscence. In such cases, the patients can be treated in an emergency situation with open repair, despite the high risk of complications and mortality. (J Vasc Surg Cases Innov Tech 2024;10:101366.)

Keywords: Acute type B dissection; Aortic abdominal rupture; ATBD; Endovascular repair; Open repair

Acute type B aortic dissection (ATBD) accounts for 25% to 40% of all aortic dissections.¹ Rupture of ATBD is uncommon, occurring in <5% of all acute type B dissections.² Acute aortic dissection combined with infrarenal aortic rupture after endovascular aneurysm repair (EVAR) is an extremely rare complication. A few case reports have reported that treatment of patients with ruptured aortic Stanford type B dissection after EVAR is often lethal.³ In one of two cases, the patient died after open aortic repair at postoperative day 4 of multisystem organ failure. In the second case, the patient died without therapy after experiencing cardiac arrest. Regarding endovascular repairs for these cases, we found no information in the literature.

This report describes the case of a patient who first received EVAR for treatment of an abdominal aortic aneurysm (AAA) and 5 years later developed complicated ATBD with infrarenal aortic rupture. In this case, according to the Society for Vascular Surgery reporting standards for type B aortic dissection from 2020, the primary entry tear of the hyperacute aortic dissection (<24 hours) was in zone 3 and extended to zone 9 (type B_{3,9}). Open surgery of the patient was the last option for treatment in this case. The patient provided

written informed consent for the report of his case details and imaging studies.

CASE REPORT

A 66-year-old-man presented with normal blood pressure (120/70 mm Hg) after rupture of the infrarenal aorta and complained of sudden abdominal pain radiating to both flanks at our emergency department. The patient had a history of smoking and arterial hypertension. He had been taking candesartan 16 mg as an antihypertensive drug and acetylsalicylic acid 100 mg daily. The physical examination findings of the patient were not spectacular, with the exception of abdominal pain radiating to both flanks. Blood analysis revealed a high serum creatinine level (3.63 mg/dL). The patient mentioned a treatment history of EVAR (AFX stent graft; Endologix) for an asymptomatic AAA (5.1 cm diameter) 5 years prior. A computed tomography (CT) angiography (CTA) scan of the aorta showed an ATBD with the main entry distal to the left subclavian artery, combined with infrarenal rupture of the false lumen, which were not present on the last follow-up contrast-enhanced CT scan of the abdomen and pelvis 3 years prior. Spontaneous aneurysmal sac shrinkage after EVAR was not observed at the last follow-up examination. The false lumen extended distally to the infrarenal aorta (segment 4) beyond the stent graft with retroperitoneal hematoma suggestive for rupture (Fig 1). The CTA scan showed the false lumen, with a major supply to the right kidney and superior mesenteric artery. The celiac trunk had a dual supply from both lumens. The CTA scan showed that the left kidney was already nonfunctional after the ATBD. Additionally, the CTA scan showed an aneurysmal lesion of the right common iliac artery of 3.75 cm and a left internal iliac artery aneurysm of 3.1 cm.

The patient declined surgery due to the potential complications, such as dialysis and intestinal ischemia. However, after 12 hours, the patient decided to undergo the surgery after speaking with his family. After receiving informed consent, the

From the Department of Vascular Surgery, Medical Faculty, Augsburg University Hospital.

Correspondence: Elena Streck, MD, Department of Vascular Surgery, Medical Faculty, Augsburg University Hospital, Stenglinstraße 2, Augsburg 86156, Germany (e-mail: elena.streck@gmail.com).

The editors and reviewers of this article have no relevant financial relationships to disclose per the Journal policy that requires reviewers to decline review of any manuscript for which they may have a conflict of interest.

2468-4287

© 2023 The Author(s). Published by Elsevier Inc. on behalf of Society for Vascular Surgery. This is an open access article under the CC BY-NC-ND license (<http://creativecommons.org/licenses/by-nc-nd/4.0/>).

<https://doi.org/10.1016/j.jvscit.2023.101366>

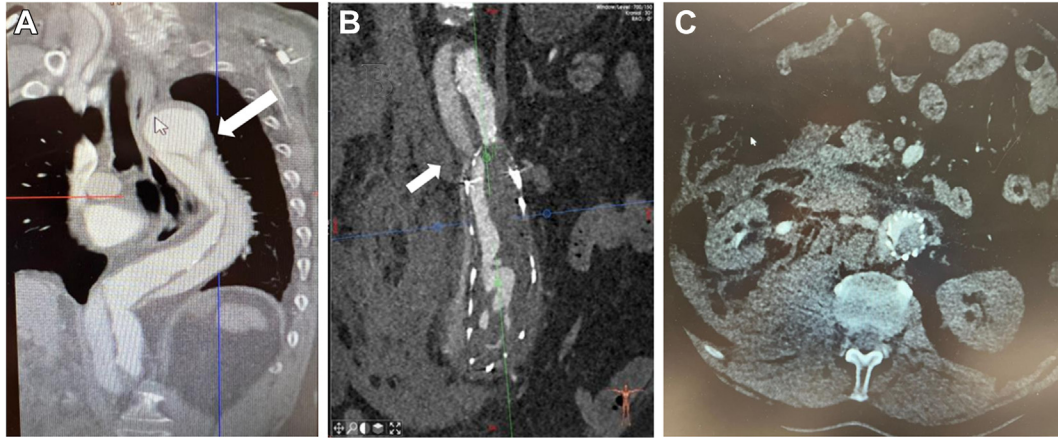


Fig 1. Preoperative computed tomography (CT) images of the aorta demonstrating acute type B aortic dissection (ATBD) at the level of the descending aorta (**A**), hematoma after infrarenal rupture of the false lumen of the ATBD after endovascular aneurysm repair (EVAR) with AFX stent graft placement (**B**), and no perfusion of the left renal artery after ATBD (**C**). Arrow indicates the entry tear (**A**) and reentry tear (**B**) on the CT scan.

patient underwent infrarenal open surgical conversion, with suprarenal aortic clamping of 30 minutes and implantation of a bifurcated Dacron graft (Hemagard; Getinge). Identification of the true lumen of the dissection was not an issue because the aortic neck with the stent graft inside was easy to identify. A proximal aortic anastomosis, including the whole aortic wall, was performed infrarenally with an end-to-end configuration after removal of the stent graft. Distal anastomoses were performed on the left external iliac artery and right common iliac artery with end-to-end configurations. The nonfunctional left renal artery after ATBD and left internal iliac artery with the aneurysm were ligated. The duration of surgery was 210 minutes, and the estimated blood loss was 200 mL.

The postoperative course was significant for a transient elevation of creatinine and oliguria that improved gradually. Ultrasound was performed, which showed normal perfusion of the right kidney. The relevant postoperative complication was a fascial dehiscence after 2 weeks, which was closed with Vicryl mesh (Johnson & Johnson) and treated with vacuum therapy for another 2 weeks. Subsequently, the wound dehiscence was treated conservatively.

The postoperative CT scan at 3 weeks postoperatively showed an unaltered type B dissection of the thoracic aorta and successful surgical treatment of the ATBD with infrarenal false lumen rupture after EVAR, and reperfusion of the right kidney artery (Fig 2).

DISCUSSION

Antegrade type B aortic dissection after EVAR of an AAA is an extremely rare and potentially lethal condition. Only a few cases have described aortic dissection after AAA repair.³⁻⁷ In 2018, Nomura et al³ summarized case reports of similar antegrade complicated type B aortic dissections. They found that the timing of the aortic dissection after abdominal aorta repair varied from 11 weeks to 10 years. Different complications after ATBD,

in combination with EVAR, were described, such as endograft thrombosis in 8 of 10 cases, endograft collapse in 8 of 10 cases, and rupture in 2 of 10 cases, with often disastrous outcomes. Treatment after aortic rupture is described as difficult or not possible because of the risk of multiorgan failure postoperatively. In the present case, life-threatening ATBD in normotensive patient occurred 5 years after uneventful treatment of an infrarenal aneurysm using EVAR. Normal blood pressure during aortic dissection is unusual. Our patient's blood pressure was measured after rupture of the infrarenal aorta; however, it is most likely that the ATBD was caused by high blood pressure. In the literature, all the patients with the same condition were normotensive.^{8,9}

The recommended surveillance for an endovascular graft is usually 3 and 6 months after repair and then annually.¹⁰ In the present case, the patient was lost to follow-up for the 3 years before he presented with ATBD and infrarenal rupture of the false lumen. Spontaneous type B aortic dissection is the most probable cause, given the 5-year period between the development of ATBD and AAA repair. Device-related and procedure-related dissection of the aorta after stent graft implantation will usually occur within a shorter time after surgery. The postprocedure contrast-enhanced CT scan of the whole aorta of our patient on the third postoperative day showed no evidence of aortic dissection.

Presumably, the stress to the calcified, aortic wall from his high blood pressure weakened the aorta wall, which caused an ATBD with the main entry distal to the left subclavian artery. Apparently, the increased pressure in diastole in the false lumen was sufficient to dissect the aortic wall beyond the proximal origin of the prior stent graft. The radial force exerted by the endograft over the length of the proximal neck was obviously exceeded by the dissection lumen. The false lumen of the dissection

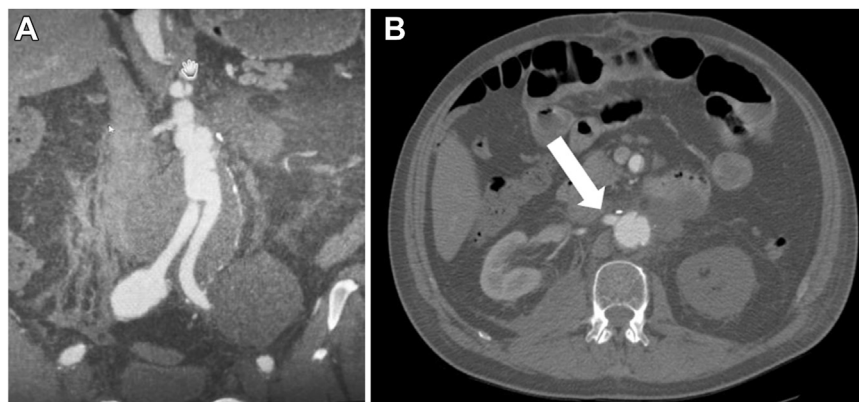


Fig 2. Postoperative computed tomography (CT) image of aorta after removal of the AFX stent graft and implantation of a bifurcated Dacron graft (A), with reperfusion of the right kidney artery (B).

terminated in the excluded aneurysm sac, resulting in a lack of outflow and caused rupture of the infrarenal aorta.

We believe that the design of the aortic endograft does not affect the risk of rupture during ATBD. Aortic dissection is an arterial wall disease in which the inner layer of the aortic wall tears and separates from the middle layer of the aortic wall. The dissection is not between the aortic wall and endograft. If the endograft would increase the rupture risk during dissection, it would lead to local rupture or penetration of the stent graft into the aortic neck. However, this was not found in our patient.

Endovascular treatment of complicated type B dissections using thoracic endovascular aortic repair for entry occlusion is common. Standard thoracic endovascular aortic repair to treat ATBD with infrarenal aortic rupture of the false lumen after EVAR would be ineffective because of the multiple reentries required and, therefore, was not a treatment option. Only open abdominal repair, despite the high risk of complications and operative mortality, is possible.

In the present case, after suprarenal clamping of the aorta within 30 minutes, no celiac artery, superior mesenteric artery, or lower leg malperfusion was observed. Postoperatively, the patient had a few days of acute kidney insufficiency while in the intensive care unit, which improved gradually despite single kidney perfusion. The postoperative CT scan showed an unaltered type B dissection of the thoracic aorta, which could now be classified as uncomplicated, and no conspicuous findings after surgery.

CONCLUSIONS

We describe a very rare case of ATBD, combined with infrarenal false lumen rupture, after EVAR. Open surgery of complicated infrarenal aorta rupture and a nonfunctional left kidney after acute type B dissection is the treatment of choice for hemodynamically stable patients despite the high risk of complications, especially dialysis.

Treatment of postoperative uncomplicated type B dissection of the thoracic aorta is conservative, with follow-up CTA examinations of the chest at 6 months and then annually. Nevertheless, the patient's condition, morbidity, and age of the patient play a role in the surgical outcome and, therefore, should be analyzed individually.

DISCLOSURES

None.

REFERENCES

1. Hughes CC. Management of acute type B aortic dissection: ADSORB trial. *J Thorac Cardiovasc Surg*. 2015;49:158–162.
2. Estrera AL, Miller III CC, Safi HJ, et al. Outcomes of medical management of acute type B aortic dissection. *Circulation*. 2006;114:1384–1389.
3. Nomura Y, Nagao K, Hasegawa S, et al. Fatal Complications of New-Onset Complicated Type B aortic dissection after endovascular abdominal aortic aneurysm repair: report of 2 cases and literature review. *Vasc Endovasc Surg*. 2018;53:255–258.
4. Iyer V, Rigby M, Vrabec G. Type B aortic dissection after endovascular abdominal aortic aneurysm repair causing endograft collapse and severe malperfusion. *J Vasc Surg*. 2009;50:413–416.
5. van Keulen JW, Toorop RJ, de Borst CJ, et al. Abdominal stent-graft collapse due to progression of a Stanford type B dissection. *J Endovascular Ther*. 2009;16:752–754.
6. Vainas T, Tielliu IFJ, de Vries BMW, van der Laan VM, Zeebregts CJ, van den Dungen JJAM. Acute type B dissection complicated by infrarenal aortic stent-graft collapse with spontaneous re-expansion. *J Endovascular Ther*. 2014;21:353–355.
7. Yoshiga R, Morisaki K, Matsubara Y, et al. Emergency thoracic aortic stent grafting for acute complicated type B aortic dissection after a previous abdominal endovascular aneurysm repair. *Surg Case Rep*. 2015;1:99.
8. Haulon S, Greenberg RK, Khwaja J, et al. Aortic dissection in the setting of an infrarenal endoprosthesis: a fatal combination. *J Vasc Surg*. 2003;38:1121–1124.
9. Daniel G, Ben Ahmed S, Warein E, Gallon A, Rosset E. Type B aortic dissection with abdominal aortic aneurysm rupture one year after endovascular repair of abdominal aortic aneurysm. *Ann Vasc Surg*. 2016;33:e7–e10.
10. Daye D, Walker TG. Complications of endovascular aneurysm repair of the thoracic and abdominal aorta: evaluation and management. *Cardiovasc Diagn Ther*. 2018;8:138–156.

Submitted Jul 2, 2023; accepted Oct 23, 2023.