



Case report

Abdominal cocoon syndrome as rare cause of intestinal obstruction: A case report



Mir Ali Mousavi, Ali Shaghghi, Mohammad Sabouri, Roya Yousefian *

Department of General Surgery, School of Medicine, Ayatollah Mousavi Hospital, Zanjan University of Medical Sciences, Iran

ARTICLE INFO

Keywords:

Case report
Abdominal cocoon syndrome
Obstruction
Surgery

ABSTRACT

Introduction: Abdominal cocoon syndrome (ACS) is a rare complication that is hardly diagnosed before surgery. Abnormal membrane in partial or total intestine can make obstruction with generalized abdomen pain.

Case presentation: We present a case of 43-year-old man, who presented to our hospital with generalized abdominal pain, preferably hypogastric. He has recurrent nausea and vomiting with no appetite. Dilated loops were explored between pancreases and stomach that are continued to the ileum. Complete removal of the membrane performed by laparotomy.

Discussion: Idiopathic sclerosing encapsulating peritonitis (SEP), known as cocoon syndrome, is a rare complication with unknown cause and pathology. Obstruction is the chief complaint. Abdominal discomfort, tenderness, nausea, and intestinal distention are also presented. Previous peritoneal dialysis, intra-abdominal inflammation, previous abdominal surgery or trauma, and beta-blocker intake predispose patients to the SEP. The present case has chronic SEP type 2, as the membrane existed in the entire small intestine.

Conclusion: Our case highlights the importance of considering ACS as a differential diagnosis for left upper quadrant abdominal pain in patients with obstructive symptoms, especially by surgeons, because it is difficult to diagnosis before surgery.

1. Introduction

Several different patients are presented with abdominal cocoon syndrome, as a primary sclerosing encapsulating peritonitis (SEP) that causes bowel obstruction [1,2]. The exact pathophysiology of the disease remains unknown, although many hypotheses have been raised [2,3]. This complication is diagnosed by computed tomography (CT) with intravenous (IV) contrast [4]. However, the most cases are diagnosed during surgery [2,3].

2. Case presentation

Written informed consent was obtained from the patient for publication of this case report and accompanying images. A copy of the written consent is available for review by the Editor-in-Chief of this journal on request.

A 43-year-old man, who lived in Zanjan city as a mountainous and cold city, with a severe abdominal pain, nausea and vomiting was referred to the surgery service. He underwent emergency surgery for

acute appendicitis ten yrs. ago and appendectomy was performed through lower midline incision. He experienced recurrent abdominal pain, treated conservatively. At the admission day, all conservative treatments failed. He had no familial history for any diseases. He had no drug history exception of sedatives for conservative treatment. No smoking or alcohol consumption was reported. Results of biochemical assessment showed hypocalcemia (decrease in serum ionized calcium) and hyperbilirubinemia (total and direct). All other biochemical parameters were in normal ranges.

The diagnostic workup during this admission was a CT scan with oral and IV contrast. Dilated loops were explored between pancreases and stomach that are continued to the ileum. In the up-right abdominal X-ray air-fluid levels were observed. The CT scan revealed a distended intestine, especially near to the ligament of Treitz. The surgeon noticed an abnormal membrane covering part of the ileus, and a sample of the tissue was sent for histo-pathological examination. The findings were non-specific, indicating a membrane formed from the connective tissue. The CT scan revealed a distended duodenum to the distal ileum and secum, especially near to the ligament of Treitz (Figs. 1, 2). The colon

* Corresponding author.

E-mail address: miralimsvi@gmail.com (R. Yousefian).<https://doi.org/10.1016/j.ijscr.2022.107547>

Received 7 July 2022; Received in revised form 21 August 2022; Accepted 21 August 2022

Available online 24 August 2022

2210-2612/© 2022 The Authors. Published by Elsevier Ltd on behalf of IJS Publishing Group Ltd. This is an open access article under the CC BY-NC-ND license (<http://creativecommons.org/licenses/by-nc-nd/4.0/>).

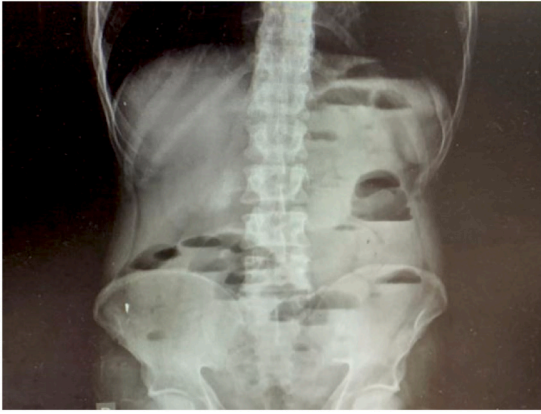

Fig. 1. Up-right abdominal X-ray revealing air-fluid level.

was empty.

The patient had no appetite to food and was malnourished. General surgeons made a decision of laparotomy, because no amelioration was occurred with any conservative treatment.

He underwent laparotomy through a midline incision by two assistant professors in general surgery aiding two residents. In the abdominal cavity, a dense membrane was found encapsulating the small intestine without involving the large intestine. The large intestine was empty (Fig. 3). The extended adhesiolysis was performed after the whole membrane excision, and the small bowel loops were released (Fig. 3). The entire small intestine was not desiroused. Pathological assessment confirmed the connective tissue with inflammatory cells. The patient was admitted to intensive care unit (ICU) for three days and intubated for two days.

In total, operation was tolerable by patient. He received total parenteral nutrition (TPN), five days after operation. On 6th post-operative day (POD), complete liquid diet was started and followed by oral intake according to the patient's tolerance and food intake was completed on 10th POD. He had a normal defecation on discharge day with no clinical symptoms, pain or any complication. Patient was discharged on POD 12 in good general condition, as well as normal clinical and radiological results. The work has been reported in line with the SCARE 2020 criteria [5].

3. Discussion

Herein, a man with silk cocoon syndrome was diagnosed according to the CT presentation. Severe nausea and vomiting forced the patient to hospital admission without response to the conservative treatments. Peritoneal encapsulation was described in 1968 due to the presence of additional peritoneal membrane, as a congenital disorder [1,2,4]. The membrane covers the entire of small intestine, and patient is asymptomatic. The composition and structure are similar to the peritoneum [1]. The Encapsulating peritoneal sclerosis (also known as SEP) is an acquired complication [4]. The main difference with peritoneal encapsulation is observed in histopathological results. In the first case, the

membrane is composed of connective tissue with inflammatory cells [1,4]. Idiopathic SEP, known as cocoon syndrome, was introduced in 1978 [4,6,7]. The cause of disease remains unknown. The pathology of disorder is unknown and it is more common in girls live in tropical countries [1,4,6–8].

There is three subcategory of ACS with acute, subacute or chronic presentations, including only part of the small intestine is encased, the membrane covers the entire small intestine, other organs, such as part of the colon, ovaries, liver, stomach, or the appendix are also included in the encapsulated viscera [1,2,4]. Intestinal obstruction is the main manifestation of this disorder. Other symptoms include abdominal discomfort, tenderness, nausea and intestinal distention. Previous peritoneal dialysis, intra-abdominal inflammation, previous abdominal surgery or trauma and beta-blocker intake predispose patients to the SEP [2,3,7,8]. The present case had the chronic SEP type 2, as the membrane existed in the entire small intestine that admitted due to the severe nausea and vomiting resulted from obstruction. In the chronic models, patient suffers from weight loss and malnutrition that is observed in our case. Air-fluid levels in the abdominal X-ray is an indicator of obstruction, however this route of diagnosis is not specific. CT is more accurate than X-ray [8]. Conservative treatments, including nil per mouse (NPO), nasogastric tube (NGT) or parenteral nutrition in mild cases and surgery in acute patients are suggested [4,8,9]. Our patient had NGT for the conservative treatment. However, the conservative methods did not respond to this patient due to the complete intestinal obstruction, and surgery was considered as the only choice of treatment [8]. The entire membrane encapsulating the small intestine was removed. Abdominal cocoon syndrome, as the main cause of intestinal obstruction, was treated by surgery. CT scan seems to be the better diagnostic method, although in the most cases diagnosis is confirmed in the operating room. The present man is the first Iranian reported case of chronic SEP type 2 that experienced appendectomy ten years ago. Home remedies and euphoria for constipation exacerbate his conditions. CT scan seems to be considered as the diagnostic method in patients' complaining constipation-resistant to treatment. Moreover, previous surgical history increases the risk of ACS in future.

Provenance and peer review

Not commissioned, externally peer-reviewed.

Funding

No funding.

Ethical approval

Ethic Committee of Zanjan University of Medical Sciences.

Consent

Received.

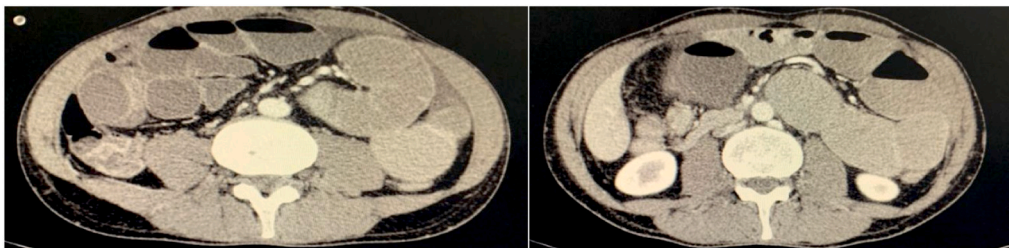


Fig. 2. CT scan revealing distended small bowel loops.

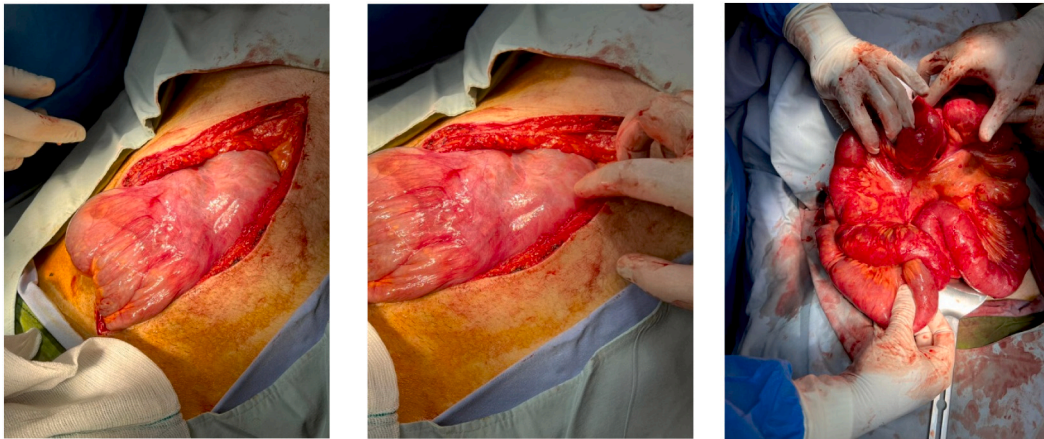


Fig. 3. Intraoperative findings. A thick membrane covering the small intestine is identified by entering to the abdomen. The abdominal cavity was filled by purulent fluid. A loop completely covered with the membrane. The membrane is completely removed.

Author contribution

Mir Ali Mousavi; Conception, Aid in surgery room, Write the first draft of manuscript.

Ali Shaghghi; Surgeon in surgery room.

Mohammad Saboori; Aid in surgery room.

Roya Yousefian; Surgeon in surgery room; revised the final version.

All authors read and edited the final version.

Registration of research studies

Not applicable.

Guarantor

Dr. Roya Yousefian.

Declaration of competing interest

None.

References

- [1] H. Allam, O. Al Yahri, S. Mathew, et al., The enigma of primary and secondary encapsulating peritoneal sclerosis, *BMC Surg.* 16 (2016) 81.
- [2] J. Xia, W. Xie, L. Chen, D. Liu, Abdominal cocoon with early postoperative small bowel obstruction: a case report and review of literature in China, *Medicine* 97 (2018), e11102.
- [3] J.H. Frost, E.E. Price, Abdominal cocoon: idiopathic sclerosing encapsulating peritonitis, *BMJ Case Rep.* 2015 (2015).
- [4] S. Akbulut, Accurate definition and management of idiopathic sclerosing encapsulating peritonitis, *World J. Gastroenterol.* 21 (2015) 675–687.
- [5] R.A. Agha, T. Franchi, C. Sohrabi, G. Mathew, for the SCARE Group, The SCARE 2020 guideline: updating consensus Surgical CAse REport (SCARE) guidelines, *International Journal of Surgery.* 84 (2020) 226–230.
- [6] A. Solmaz, M. Tokoçin, S. Arıcı, et al., Abdominal cocoon syndrome is a rare cause of mechanical intestinal obstructions: a report of two cases, *Am. J. Case Rep.* 16 (2015) 77–80.
- [7] M. Gadhire, M.B. Singh, M.A. Joshi, Abdominal cocoon syndrome, *J. Evol. Med. Dent. Sci.* 25 (2013) 1857–1859.
- [8] A. Solak, İ. Solak, Abdominal cocoon syndrome: preoperative diagnostic criteria, good clinical outcome with medical treatment and review of the literature, *Turk. J. Gastroenterol.* 23 (2012) 776–779.
- [9] B. Singh, S. Gupta, Abdominal cocoon: a case series, *Int. J. Surg.* 11 (2013) 325–328.