

A Simple Technical Modification for the Creation of an External Monitoring Skin Paddle for Tubed ALT Flap Reconstruction after Circumferential Hypopharyngeal Resection

Shao-Yun Hsu, MD*; Omar Hausien, MBBChir, MRCS†; Ting-Yi Liao, MD*; Hsu-Tang Cheng, MD*

Total laryngopharyngectomy remains the mainstay of treatment for advanced or residual postradiotherapy hypopharyngeal cancer. The tubed anterolateral thigh (ALT) flap is a popular reconstructive option for this complex defect.¹ Postoperative monitoring of this buried flap, however, is clinically challenging.

Various flap externalization methods have been reported, including the use of chimeric design of the ALT flap based on a second perforator,² the use of deepithelialized portion of the flap,³ the use of the distal stump of the ALT flap pedicle,⁴ and the use of a small segment of vastus lateralis muscle.⁵ However, the chimeric design may not always be possible because of the variation of the perforator numbers and locations of ALT flap, the deepithelialized ALT flap may be hard to be folded and externalized because of its bulkiness that may increase the chance of fistula,¹ the exposed distal pedicle stump may not be reliable for monitoring the venous condition, and the small muscle segment from the vastus lateralis muscle may dry out when it is exposed externally.

Here, we present a simple technical modification to the tubed ALT flap that permanently externalizes a distal skin paddle of the buried tube flap, allowing for direct flap monitoring. The skin paddle for tubularization was extended distally into a fusiform shape with the distal part prepared for externalization (see figure, **Supplemental Digital Content 1**, which displays that the skin paddle for tubularization was extended distally into a fusiform shape with the distal part prepared for externalization, <http://links.lww.com/PRSGO/A454>). The distal skin paddle was cut through the dermis with the subcutaneous tissue and fascia attached to the main flap. It remained well perfused while waiting for the tumor ablation surgery (Fig. 1). The flap pedicle was divided, and the main flap was tubularized to serve as neohypopharynx (see figure, **Supplemental Digital Content 2**, which

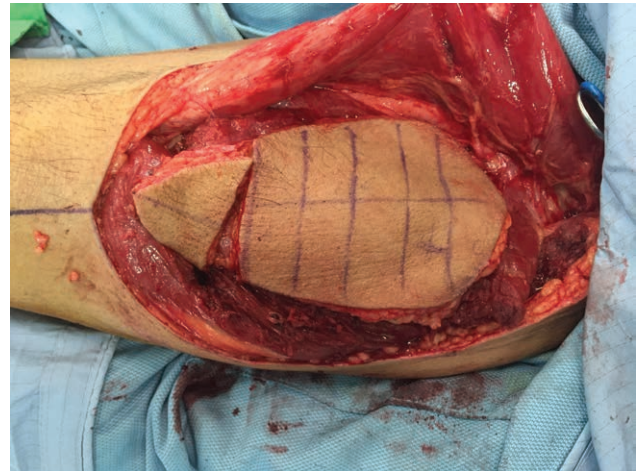


Fig. 1. The skin paddle of the ALT flap for tubularization was extended distally into a fusiform shape with the distal part prepared for externalization. The distal skin paddle was cut through the dermis with the subcutaneous tissue and fascia attached to the main flap. The distal skin paddle remained well perfused while waiting for the tumor ablation surgery.

displays that the flap pedicle was divided and the main flap was tubularized to serve as neohypopharynx, <http://links.lww.com/PRSGO/A454>).

We describe an illustrative case of the creation of a neohypopharynx by using ALT flap after radical neck dissection and total pharyngolaryngectomy (see figure, **Supplemental Digital Content 3**, which displays the hypopharyngeal defect after radical neck dissection and total pharyngolaryngectomy, <http://links.lww.com/PRSGO/A454>). For monitoring purpose, the distal skin paddle was folded, externalized, and stayed above the tracheal stoma (see figure, **Supplemental Digital Content 4**, which shows that for monitoring purpose, the distal skin paddle was folded, externalized, and stayed above the tracheal stoma, <http://links.lww.com/PRSGO/A454>). The distal skin paddle regained its normal perfusion after microvascular anastomosis (see figure, **Supplemental Digital Content 5**, which demonstrates that distal cutaneous stump of the tubed ALT flap functioned well as a reliable monitoring skin paddle, <http://links.lww.com/PRSGO/A454>). Healing of the externalized distal skin paddle to native neck skin was good despite previous irradiation (Fig. 2). Recovery was uneventful, and the patient could tolerate most regu-

From the *Division of Plastic and Reconstructive Surgery, Department of Surgery, China Medical University Hospital, School of Medicine, China Medical University, Taichung, Taiwan; and †Department of Surgery, Addenbrooke's Hospital, Cambridge, United Kingdom. Drs. Hsu and Hausien contributed equally to this work.

Copyright © 2017 The Authors. Published by Wolters Kluwer Health, Inc. on behalf of The American Society of Plastic Surgeons. This is an open-access article distributed under the terms of the Creative Commons Attribution-Non Commercial-No Derivatives License 4.0 (CCBY-NC-ND), where it is permissible to download and share the work provided it is properly cited. The work cannot be changed in any way or used commercially without permission from the journal. *Plast Reconstr Surg Glob Open* 2017;5:e1344; doi:10.1097/GOX.0000000000001344; Published online 25 May 2017.

Supplemental digital content is available for this article. Clickable URL citations appear in the text.

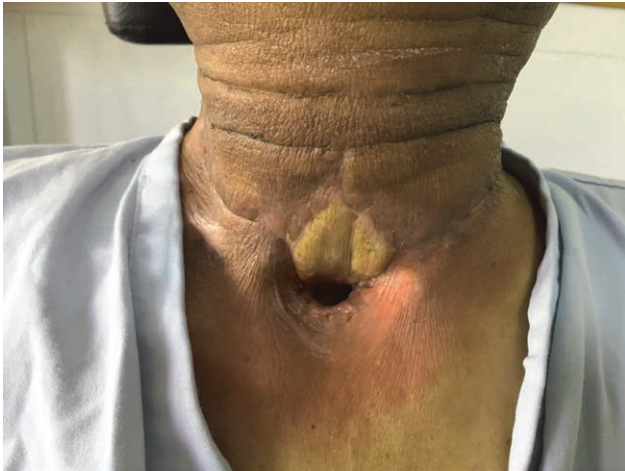

Fig. 2. Three weeks after the reconstruction, the healing of this distal paddle to the native neck skin was good despite previous neck irradiation.

lar food. Esophagography demonstrated a patent neohypopharynx with no evidence of stricture or fistula (see figure, Supplemental Digital Content 6, <http://links.lww.com/PRSGO/A454>).

Suprastomal externalization of a distal skin paddle of the tubed ALT flap is a technically simple and reliable method for the monitoring of this buried free flap.

Hsu-Tang Cheng, MD

Division of Plastic and Reconstructive Surgery
China Medical University Hospital
China Medical University School of Medicine
2, Yu-Der Road
Taichung City, 40449
Taiwan
E-mail: hsutangcheng@gmail.com

DISCLOSURE

The authors have no financial interest to declare in relation to the content of this article. The Article Processing Charge was paid for by the authors.

REFERENCES

1. Yu P, Robb GL. Pharyngoesophageal reconstruction with the anterolateral thigh flap: a clinical and functional outcomes study. *Plast Reconstr Surg.* 2005;116:1845–1855.
2. Tan NC, Yeh MC, Shih HS, et al. Single free anterolateral thigh flap for simultaneous reconstruction of composite hypopharyngeal and external neck skin defect after head and neck cancer ablation. *Microsurgery.* 2011;31:524–528.
3. Revenaugh PC, Waters HH, Scharpf J, et al. Suprastomal cutaneous monitoring paddle for free flap reconstruction of laryngopharyngectomy defects. *JAMA Facial Plast Surg.* 2013;15:287–291.
4. Spyropoulou GA, Lin PY, Chien CY, et al. Reconstruction of the hypopharynx with the anterolateral thigh flap: defect classification, method, tips, and outcomes. *Plast Reconstr Surg.* 2011;127:161–172.
5. Huang TC, Hsu YC, Chen HC, et al. Functional outcome analysis after anterolateral thigh flap reconstruction of pharyngoesophageal defect. *Ann Plast Surg.* 2015;75:174–179.