

A Pediatric Case of Antibiotic-Associated Hemorrhagic Colitis Caused by *Klebsiella Oxytoca*

Abstract

In recent decade the prevalence of antibiotic associated diarrhea was increased because of more antibiotic usage. *Colstridium difficile* is a microorganism which can cause mild to severe colitis. But the only cause of colitis related to Antibiotics is not *colstridium difficile*. In this case report we explain a child whit antibiotic associated colitis due to *klebsiella oxytoca*.

Keywords: *Antibiotic associated diarrhea, child, colitis, klebsiella oxytoca*

Introduction

Antibiotic-associated diarrhea (AAD) and hemorrhagic colitis are prevalent diseases among pediatric patients because of using penicillin for treatment of their illnesses.^[1]

Clostridium difficile was known as the microorganism causing this disease, but in recent years, studies show a kind of Gram-negative bacilli as the normal flora of intestine by the name of *klebsiella oxytoca* which can cause an AAD.

Here we discuss about a pediatric patient with AAD caused by *klebsiella oxytoca*.

Case Report

A 5.5-year-old boy had admitted in Nigria due to bloody diarrhea and fever.

Watery diarrhea and fever had begun 14 days before, and he admitted to Nisa Hospital in Nigeria for more evaluation. Intravenous (IV) ceftriaxone and then ciprofloxacin were administered for him by diagnosis of typhoid fever. After 48 hours, bloody diarrhea appeared and colonoscopy was done for him, which showed membranous colitis; so antibiotic was discontinued and then metronidazole was administrated. Because the symptoms continued, he was discharged with his parental consent and was admitted to Mofid Children's Hospital for further work-up.

The only positive sign in physical examination was tenderness around umbilical area.

This is an open access journal, and articles are distributed under the terms of the Creative Commons Attribution-NonCommercial-ShareAlike 4.0 License, which allows others to remix, tweak, and build upon the work non-commercially, as long as appropriate credit is given and the new creations are licensed under the identical terms.

For reprints contact: reprints@medknow.com

Data in laboratory studies were normal except stool exam which contained many white blood cells (WBC) and red blood cells (RBC). Radiologic study showed thickening of small bowel especially in right colon. In the past medical evaluation, he had episodes of pharyngitis and lymphadenopathy every 3–4 weeks, and penicillin and amoxicillin were administered for him every time.

In the first 2 days of admission, IV metronidazole was continued because of membranous colitis in his previous data and fever. After 48 hours, *clostridium difficile* toxins A and B were negative for 2 times in stool examination. Stool culture only showed pure *klebsiella* [Figure 1]. In further investigation, indole was positive [Figure 2], and *klebsiella oxytoca* colitis was the diagnosis. Metronidazole was discontinued, and only supportive care was done for him. In the 5th day of admission, the bloody diarrhea and fever disappeared, and he was finally discharged on the 7th day.

Discussion

In this case report, we discuss a pediatric patient with *klebsiella oxytoca* after periodic use of penicillin and amoxycillin.

First pediatric case of *klebsiella oxytoca* colitis was described in 2010.^[1] In the following years, some cases of pediatric *klebsiella oxytoca* colitis were reported.^[2–4] According to these data, females and males were equally infected, and the time onset of getting antibiotics at the first sign of disease is about 3–12 days.^[2,3,5] Penicillin inhibits growth of most bacteria in gut,

How to cite this article: Karimi A, Fayazi A, Ghorobi J, Pourmoghaddas Z. A pediatric case of antibiotic-associated hemorrhagic colitis caused by *klebsiella oxytoca*. *Int J Prev Med* 2019;10:113.

Abdollah Karimi¹,
Arefeh Fayazi¹,
Javad Ghorobi²,
Zahra
Pourmoghaddas^{1,3}

¹Research Institute for Children Health, Pediatric Infections Research Center, Mofid Children Hospital, Shahid Beheshti University of Medicine Sciences, Tehran, Iran, ²Department of Surgery, Shahid Beheshti University of Medicine Sciences, Tehran, Iran, ³Child Growth and Development Research Center, Research Institute for Primordial Prevention of Non-Communicable Disease, Isfahan University of Medical Sciences, Isfahan, Iran

Address for correspondence:

Dr. Zahra Pourmoghaddas,
Research Institute for Children Health, Pediatric Infections Research Center, Mofid Children Hospital, Shahid Beheshti University of Medicine Sciences, Tehran, Iran.
E-mail: zahrapormoghadas@yahoo.com

Access this article online

Website:
www.ijpvmjournal.net/www.ijpvm.ir

DOI:
10.4103/ijpvm.IJPVM_330_18

Quick Response Code:






Figure 1: Mucoïd colonies of bacteria

and due to B-lactamase activity of this Gram-negative bacteria, *klebsiella oxytoca* grows after using this kind of antibiotic.^[6]

Involving right colon in pediatric patients with this kind of colitis is more prominent and it is in contrast with colitis due to *clostridium difficile*.^[7] In our patient, right colon was more involved. Case report of *klebsiella oxytoca* colitis was described after the use of non-steroidal anti-inflammatory drugs (NSAIDs).^[1] A series of adult patients with *klebsiella oxytoca* colitis were reported after using NSAIDs.^[1,8]

Most reports suggest discounting of antibiotics for the improvement of colitis.^[9,10] Improvement of signs and symptoms begins after 3–7 days after withdrawal of drugs.^[2,9] In this case, improvement of symptoms and signs was seen 2 days after discounting the drug, and complete improvement happened in 5 days.

Conclusions

Klebsiella oxytoca colitis must be considered in differential diagnosis of hemorrhagic colitis after using antibiotics in pediatric patients with negative *clostridium difficile* toxins in stool.

Declaration of patient consent

The authors certify that they have obtained all appropriate patient consent forms. In the form the patient(s) has/have given his/her/their consent for his/her/their images and other clinical information to be reported in the journal. The patients understand that their names and initials will not be published and due efforts will be made to conceal their identity, but anonymity cannot be guaranteed.

Financial support and sponsorship

Nil.

Conflicts of interest

There are no conflicts of interest.

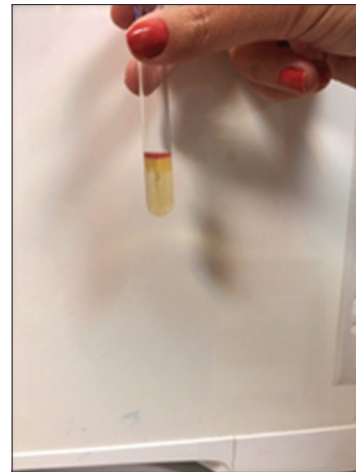

Figure 2: Indol positive gram negative bacilli

Received: 10 Aug 18 Accepted: 20 Jan 19

Published: 12 Jun 19

References

- Hoffmann KM, Deutschmann A, Weitzer C, Joainig M, Zechner E, Högenauer C, *et al.* Antibiotic-associated hemorrhagic colitis caused by cytotoxin-producing *Klebsiella oxytoca*. *Pediatrics* 2010;125:e960-3.
- Högenauer C, Langner C, Beubler E, Lippe IT, Schicho R, Gorkiewicz G, *et al.* *Klebsiella oxytoca* as a causative organism of antibiotic-associated hemorrhagic colitis. *N Engl J Med* 2006;355:2418-26.
- Shinjo M, Iwata S, Takahashi T. *Klebsiella oxytoca* positive, penicillin-associated hemorrhagic enterocolitis in children. *Pediatr Int* 2010;52:132-3.
- Yilmaz M, Bilir YA, Aygun G, Erzin Y, Ozturk R, Celik AF. Prospective observational study on antibiotic-associated bloody diarrhea: Report of 21 cases with a long-term follow-up from Turkey. *Eur J Gastroenterol Hepatol* 2012;24:688-94.
- Yamada M, Yamazawa K, Sekiguchi S, Shinjo M, Tomita K, Takenouchi T, *et al.* A pediatric case of antibiotic-associated hemorrhagic colitis caused by *klebsiella oxytoca*. *Glob Pediatr Health* 2014;1:2333794X14550525..
- Decré D, Burghoffer B, Gautier V, Petit JC, Arlet G. Outbreak of multi-resistant *Klebsiella oxytoca* involving strains with extended-spectrum beta-lactamases and strains with extended-spectrum activity of the chromosomal beta-lactamase. *J Antimicrob Chemother* 2004;54:881-8.
- Johal SS, Hammond J, Solomon K, James PD, Mahida YR. *Clostridium difficile* associated diarrhoea in hospitalised patients: onset in the community and hospital and role of flexible sigmoidoscopy. *Gut* 2004;53:673-7
- Zollner-Schwetz I, Högenauer C, Joainig M, Weberhofer P, Gorkiewicz G, Valentin T, *et al.* Role of *Klebsiella oxytoca* in antibiotic-associated diarrhea. *Clin Infect Dis* 2008;47:e74-8
- Högenauer C, Hinterleitner T. *Klebsiella oxytoca* as a cause of antibiotic-associated colitis. In: Scheld WM, Hammer SM, Hughes JM, editors. *Emerging Infections*. Washington, DC: ASM Press; 2008. p. 293-311.
- Philbrick AM, Ernst ME. Amoxicillin-associated hemorrhagic colitis in the presence of *Klebsiella oxytoca*. *Pharmacotherapy* 2007;27:1603-7.