

Scintigraphic Evaluation of Esophageal Motility and Gastroesophageal Reflux in Patients Presenting with Upper Respiratory Tract Symptoms

Abstract

Purpose of Study: The purpose is to evaluate the findings and utility of esophageal transit scintigraphy (ETS) and gastroesophageal reflux scintigraphy (GES) in patients presenting with upper respiratory tract (URT) symptoms suspected to be due to gastroesophageal reflux (GER) disease. **Materials and Methods:** Thirty patients aged between 19 and 60 years underwent nasopharyngolaryngoscopy (NPL), ETS, and GES. Correlation between GER, esophageal motility, and NPL was evaluated. Inclusion criteria include patients with recurrent URT symptoms such as chronic dry cough/hoarseness of voice and itching/foreign body sensation in throat. Those with typical gastrointestinal (GI) symptoms of GER, URT symptoms relieved by antibiotics, surgical intervention in abdomen, cardiac/hepatobiliary diseases, etc. were excluded from the study. **Results:** Significant correlation was found between GER and NPL in 28/30 patients. More the grade of reflux, more severe was the NPL findings. Two patients with Grade II reflux had normal NPL suggesting structural inflammatory changes due to acidic pH of refluxate which have not yet manifested or symptoms could be due to nonacid refluxate. Incidence of esophageal motility disorder was statistically significant in patients with GER disease (GERD). Patients who had symptoms, but no demonstrable GER showed delayed ET in supine position suggesting the presence of esophageal motility disorder even before GERD. **Conclusion:** GES demonstrated GER in patients presenting with URT symptoms without typical GI symptoms. ETS showed coexistence of esophageal motility disorder in most patients presenting with URT symptoms even without an associated reflux disease. We hypothesize that primary abnormal esophageal motility leads to delayed esophageal clearance and consequently to URT symptoms. Addition of ETS to GES is easily feasible with no significant additional cost, time, or radiation burden.

Keywords: Esophageal motility disorder, esophageal transit scintigraphy, gastroesophageal reflux disease, gastroesophageal reflux scintigraphy

Introduction

Gastroesophageal reflux disease (GERD) is very common among the population in present day's stressful life due to various reasons. Chest burn or burning chest, the most common symptom of gastroesophageal reflux, is the major reason for consumption of antacids in our society. GERD can be overlooked for several reasons: first, the most common symptoms, chest burn and regurgitation, occur in only half of these patients; second, because of the natural history of the disease and the frequency of its spontaneous remission, many patients do not seek medical advice; and third, there is no diagnostic standard for GERD.

Symptoms of GERD are divided into two categories: esophageal, which includes typical esophageal reflux complaints (chestburn, regurgitation of

food, and dysphagia) and noncardiac chest pain, and extraesophageal, which includes pulmonary (asthma and recurrent aspiration pneumonia), otolaryngologic (morning hoarseness, halitosis, excessive phlegm, frequent throat clearing, dry mouth, coated tongue, sensation of a lump/foreign body in the throat, throat tickle, chronic sore throat, nocturnal cough, chronic or recurrent cough, and difficulty in breathing (especially at night), closing off of the airway ("laryngospasm"), and dyspeptic symptoms (upper abdominal pain, nausea, vomiting, and bloating).

The typical esophageal symptoms occur only in 50%–65% with this disorder.^[1] Respiratory/extraesophageal manifestations are less recognized but appear to occur frequently as a complication of reflux. Posterior laryngitis appears particularly

Jaykanth
Amalachandran,
Shelley Simon,
Indirani Elangoven,
Avani Jain,
Thangalakshmi
Sivathapandi

Department of Nuclear Medicine
and PET-CT, Apollo Hospitals,
Chennai, Tamil Nadu, India

Address for correspondence:
Dr. Jaykanth Amalachandran,
Department of Nuclear Medicine
and PET-CT,
Apollo Hospitals, No. 21,
Greens Lane, Off Greens Road,
Chennai - 600 006, Tamil Nadu,
India.
E-mail: jaykanthamal@gmail.
com

Access this article online

Website: www.ijnm.in

DOI: 10.4103/ijnm.IJNM_97_17

Quick Response Code:



How to cite this article: Amalachandran J, Simon S, Elangoven I, Jain A, Sivathapandi T. Scintigraphic evaluation of esophageal motility and gastroesophageal reflux in patients presenting with upper respiratory tract symptoms. Indian J Nucl Med 2018;33:25-31.

This is an open access article distributed under the terms of the Creative Commons Attribution-NonCommercial-ShareAlike 3.0 License, which allows others to remix, tweak, and build upon the work non-commercially, as long as the author is credited and the new creations are licensed under the identical terms.

For reprints contact: reprints@medknow.com

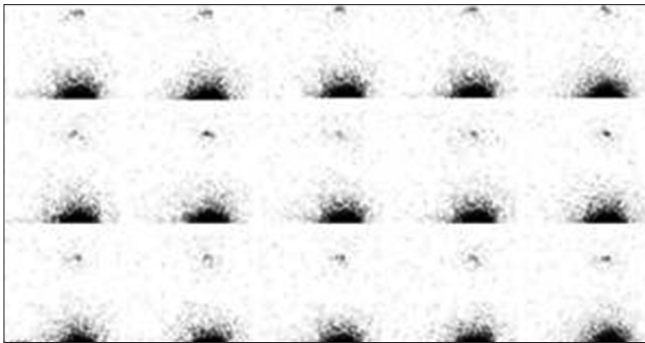


Figure 1: No reflux – Normal scan




Figure 3: Grade II GER – Visualization of tracer in middle 1/3rd of esophagus




Figure 5: Normal esophageal transit in erect position

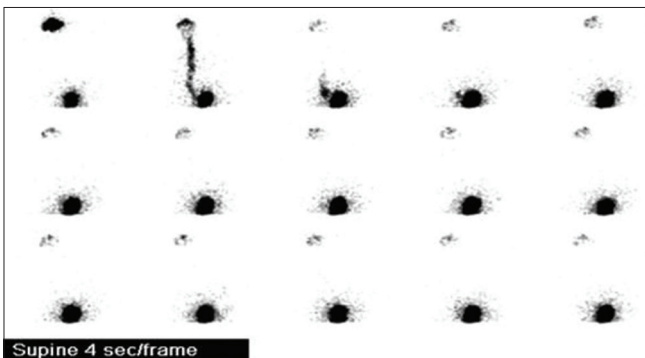


Figure 7: Normal esophageal transit in supine position

relevant, occurring in 50%–60% of patients with GER^[1] who present clinically with otolaryngeal symptoms.

The evaluation of these patients should include confirmed evidence of pathologically significant GER, excluding motility disorders involving esophagus and stomach, ruling out structural lesions of esophagus and stomach particularly




Figure 2: Grade I GER – Visualization of tracer in distal 1/3rd of esophagus




Figure 4: Grade III GER – Visualization of tracer in proximal 1/3rd of esophagus




Figure 6: Delayed esophageal transit in erect position

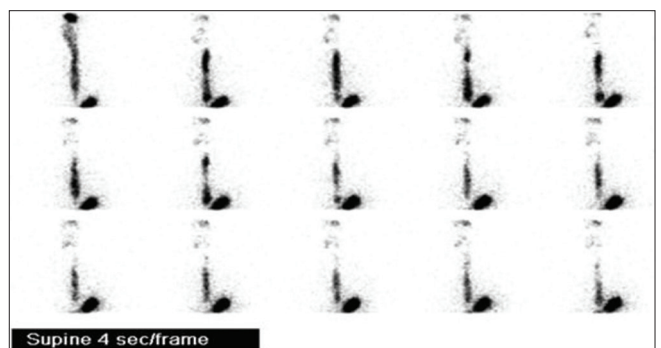


Figure 8: Delayed esophageal transit in supine position

involving lower esophageal sphincter/gastroesophageal junction, and finally, grading the severity of reflux.

A number of methods have been used to assess esophageal transit (ET) and GER. Scintigraphy is a noninvasive

Table 1: Scintigraphic grading of gastroesophageal reflux in controls with corresponding nasopharyngolaryngoscopy findings

Grade of GER	Number of controls (total - 10)	NPL findings
No reflux	8	Not significant
Grade I	2	Not significant
Grade II	Nil	Not significant
Grade III	Nil	Not significant

GER: Gastroesophageal reflux, NPL: Nasopharyngolaryngoscopy

Table 2: Incidence of delayed esophageal transit in various grades of gastroesophageal reflux in controls

GER study results (total - 10 controls)	Delayed ET in supine position	Delayed ET in erect and supine position
No reflux (8)	1	Nil
Grade I reflux (2)	Nil	Nil
Grade II reflux (nil)	Nil	Nil
Grade III reflux (nil)	Nil	Nil

ET: Esophageal transit, GER: Gastroesophageal reflux

method in which the test meals and acquisition procedures have been standardized, and the results are largely operator independent. The principal disadvantages of scintigraphy are the need for exposure to ionizing radiation and the costs associated with the procedure. However, the radiation burden to the patient in this scintigraphic procedure is much less when compared to the fluoroscopic barium swallow.

In this context of evaluation of patients presenting with otolaryngeal symptoms, certain questions remained unanswered. Does ET scintigraphy (ETS) play a role in addition to gastroesophageal scintigraphy in influencing the treatment of these patients? Does a positive scintigraphic finding in a symptomatic patient with normal nasopharyngolaryngoscopy (NPL) have any significance? Is there a correlation between GER, NPL, and esophageal motility?

Hence, this study was performed to provide answers to the aforementioned questions with the primary aim to assess the utility of gastroesophageal scintigraphy (GES) in adult patients presenting with otolaryngeal symptoms suspected to be due to acidic and nonacidic GER disease. Secondary aim was to assess ET in patients with recurrent otolaryngeal symptoms and to assess the importance of correlation between GER, NPL, and esophageal motility.

Materials and Methods

This prospective study was performed in the Nuclear Medicine Department, Apollo Hospitals at Chennai, during a period of 1 year from May 2015 to May 2016. A total of 30 patients (18 males, 12 females; age range - 19–60 years; mean age + standard deviation [SD] - 37.9 + 10.2 years) who had undergone flexible fiber-optic transnasal NPL were included in the study. All these patients underwent

GES which included the ET study in erect and supine position as well.

Ten healthy volunteers served as a control group (6 males, 4 females; age range - 19–74 years; mean age + SD - 34.7 + 8.0 years). None had a history of gastroesophageal disease, central nervous system disease, peripheral neuropathy, diabetes mellitus, or other systemic diseases commonly associated with gastroesophageal dysfunction. In addition, none had a recent history of drug treatment potentially affecting gastroesophageal function. Informed consent was obtained from all study participants, and the study was approved by ethical committee of the Apollo Hospitals. The images were interpreted by two experienced nuclear medicine physicians.

Inclusion criteria

Patients with recurrent otolaryngeal symptoms such as chronic dry cough, hoarseness of voice, itching/foreign body sensation in throat, difficulty in swallowing, and halitosis were included in the study.

Exclusion criteria

1. History of treatment for GER disease
2. Typical gastrointestinal (GI) symptoms of GER such as heartburn/retrosternal burning sensation, belching, and reflux of food particles into the mouth
3. History of treatment for upper respiratory tract symptoms relieved by antibiotics
4. History of coronary artery disease/ischemic heart disease
5. Diabetics
6. Smoking/alcoholism
7. History of any surgical intervention in the abdomen
8. History of cardiac/hepatobiliary diseases were excluded from the study.

Scintigraphy

ET and GER studies were done in the same sitting.

Esophageal transit study (erect and supine)

ETS was performed after a fast of at least 4 h before the study. About 0.3 mCi (11.1 MBq) of technetium-99m sulfur colloid with 15 ml of orange juice was given orally in erect and supine position. A large-field-of-view gamma-camera (Siemens e.CAM) fitted with a low-energy, general-purpose collimator was used. Dynamic images were acquired in anterior position in 64 × 64 matrix at the rate of 1 frame/s for 1 min.

Gastroesophageal reflux study (prone)

GES was performed by giving about 0.7 mCi (25.9 MBq) technetium-99m sulphur colloid with 470 ml of orange juice orally. Dynamic images were acquired with patient in prone position and detector posteriorly in 64 × 64 matrix at the rate of 1 frame/10 s for 10 min. The data were summed up to identify delays in transit through segments of the esophagus or brief episodes of reflux.

Interpretation

Esophageal transit study

Delayed transit if <90% of bolus is cleared in 7 s in erect position [Figure 5 and 6] and in 10 s in supine position [Figure 7 and 8].^[2] ET is determined based on the amount of residual activity in the esophagus using the formula $C(t) = E_{max} - E(t)/E_{max}$, where $C(t)$ represents the percentage of esophageal emptying at time t , E_{max} , the maximal count rate in the esophagus, and $E(t)$, the esophageal count rate at time t .

Gastroesophageal reflux

Presence of spikes of tracer activity (>4% of gastric activity^[3]) in the esophagus in any of the frames is considered as a gastroesophageal reflux. Absence of any spike of tracer activity in all the frames is considered as a normal scan with no reflux [Figure 1]. Reflux was quantified using regions of interest over the esophagus and stomach using the formula $R = E(t) - E(b) \times 100/Go$, where R is the percentage of reflux material into the esophagus; $E(t)$, the esophageal counts at time t ; $E(b)$, the paraesophageal background counts; and Go , the gastric counts at the beginning of the study.

Visual grading of gastroesophageal reflux based on extent of reflux

- Grade I: Tracer in distal 1/3rd of esophagus [Figure 2]^[4]
- Grade II: Tracer in middle 1/3rd of esophagus [Figure 3]
- Grade III: Tracer in proximal 1/3rd of esophagus [Figure 4].

Flexible fiber-optic transnasal nasopharyngolaryngoscopy report

The following regions were visualized for any evidence of abnormal structural changes of inflammation such as congestion/erythema, edema, and nodules by the ENT specialists.

- Nose and postnasal space
- Eustachian tube
- Posterior pharyngeal wall
- Base of tongue
- Vallecula
- Epiglottis
- Aryepiglottic folds
- Arytenoids
- Ventricular bands
- Vocal cords
- Pyramidal fossa
- Postcricoid area
- Subglottic space
- Trachea.

Nasopharyngolaryngoscopy grading

The findings mentioned in NPL were graded as significant and not significant as follows.

Significant

Presence of cobblestone appearance in posterior pharyngeal wall, posterior laryngitis (mucosal thickening in posterior one-third of true vocal cords), red and edematous posterior glottis, vocal cord nodules/edema, interarytenoid erythema/edema, congested arytenoids/aryepiglottic folds, keratotic patches in vocal cords, etc. were considered as significant findings in NPL.

Not significant

Presence of deviated nasal septum, B/L prominent uncinata, hypertrophic inferior turbinate, etc. were considered as non significant findings in NPL.

Statistical analysis

Continuous data were presented by mean with standard deviation and it was analyzed by Mann–Whitney U-test. Categorical data were presented by frequency with percentages and it was analyzed by Chi-square and Fisher's exact test. All the analysis was done using SPSS 14.0 version ("UNICOM Global", Mission Hills, California, USA). $P < 0.05$ was considered as significant.

Discussion

Chronic cough is a common and distressing symptom.^[5] The association between cough and GER is now well recognized.^[6-8] Indeed, GER is one of the most frequent causes of chronic cough, accounting for 10%–40% of cases. The pathophysiologic mechanisms underlying GER-related cough are not fully understood but may include microaspiration of esophageal contents into the larynx and tracheobronchial tree or a vagally mediated esophageal-tracheobronchial reflex.^[9,10] A self-perpetuating cough-reflux cycle has been proposed in which esophageal acid stimulates cough, and cough, in turn, amplifies reflux by increasing transdiaphragmatic pressure.^[10,11] The primary event in GER is the movement of gastric contents into the esophagus. There are several possible mechanisms whereby impaired ET could contribute to GER-related cough. A delay in ET could increase the rate of transient lower esophageal sphincter relaxations.^[12] Second, impaired esophageal clearance may lead to slow clearance of esophageal acid, which has been implicated in the pathogenesis of some cases of chronic cough.^[9,13]

In our study, we found significant correlation between the GER and the findings documented by NPL in 28 out of 30 patients ($P < 0.001$). The more the grade of reflux, the more severe was the NPL findings documented in terms of posterior laryngitis, congested arytenoids, cobblestone appearance in posterior pharyngeal wall, etc. These findings underscore the fact that direct contact with gastric contents as the major cause of reflux-associated posterior laryngitis. Two patients in whom scintigraphy demonstrated Grade II reflux had a normal NPL suggesting that structural inflammatory changes due to acidic pH of refluxate have

not yet manifested or the symptoms could be due to nonacid refluxate [Tables 3, 5, and 10].

Substantiating our findings, Songür *et al.*^[14] and Bestetti *et al.*^[15] have observed similar findings in their respective studies that showed that severe grade of esophagitis and the posterior laryngitis were more common, and frequency of reflux episodes, their duration, and percentage volume of gastric contents were significantly higher in the patients with proximal reflux (reflux reaching the upper third of esophagus, i.e., Grade III) than in patients with distal reflux (reflux into the lower third of esophagus, i.e., Grade I) [Tables 1, 2, 6 and 7].

In our study, when we evaluated the incidence of esophageal motility disorder in the patients and assessed the relationship between GER and esophageal transit, 67% (2/3) of patients with no scintigraphic evidence of GER showed delayed ET in supine position. Nearly 80% (4/5) of patients who had Grade I GER showed delayed ET in supine position. From those patients who had Grade II GER, 60% (3/5) had delayed ET in supine position while 20% (1/5) showed delay in the erect position as well. Finally, of those patients categorized as having Grade III GER, 64% (11/17) showed delayed transit while erect and 100% (17/17) displayed delayed ET in supine position. The incidence of esophageal motility disorder was statistically significant in our cases compared with controls ($P < 0.019$ for erect position, $P < 0.001$ for supine position) [Tables 8 and 9]. Hence, GERD patients not only have a higher incidence of esophageal motility disorder than the normal population, but patients with esophageal motility disorder also had significantly more GER and delayed clearance, particularly those presenting with extraesophageal symptoms (cough, asthma, and laryngitis). Similar results were postulated by Fouad *et al.*^[16] and Ho *et al.*^[17] in respective studies that esophageal motility disorder is seen in 50% of patients with extraesophageal symptoms compared to only 19% of patients with heartburn.

From our study, in patients who had symptoms but showed no demonstrable GER, more than half showed delayed ET in supine position. This finding indicates that esophageal dysmotility may manifest earlier than GERD becomes demonstrable. Hence, abnormal esophageal motility can be the primary disorder leading to delayed esophageal acid clearance, in turn, causing increased exposure of the esophageal, pharyngeal, and laryngeal mucosa to the acidic and other irritant contents of the gastric refluxate causing otolaryngeal symptoms, substantiated by the concept put forth by Songür *et al.*^[14] and Bestetti *et al.*^[15] Overall, our study shows strong evidence for the causal relationship of ineffective esophageal motility and otolaryngeal symptoms [Tables 4 and 5].

Whether esophageal motility disorder is a primary motility disorder causing GER disease and otolaryngeal symptoms

Table 3: Scintigraphic grading of gastroesophageal reflux in cases with corresponding nasopharyngolaryngoscopy findings

Grade of GER	Number of cases (total - 30 patients) (%)	NPL findings
No reflux	3 (10)	Not significant
Grade I	5 (16.6)	Not significant
Grade II	5 (16.6)	Not significant (2) Significant (3)
Grade III	17 (56.6)	Significant

GER: Gastroesophageal reflux, NPL: Nasopharyngolaryngoscopy

Table 4: Incidence of delayed esophageal transit in various grades of gastroesophageal reflux in cases

GER study results (total - 30 patients)	Delayed ET in supine position (%)	Delayed ET in erect and supine position (%)
No reflux (3)	2 (67)	Nil
Grade I reflux (5)	4 (80)	Nil
Grade II reflux (5)	3 (60)	1 (20)
Grade III reflux (17)	17 (100)	11 (64)

ET: Esophageal transit, GER: Gastroesophageal reflux

Table 5: Incidence of abnormal esophageal transit in symptomatic patients with corresponding nasopharyngolaryngoscopy report

GER study results (total - 30 patients)	Abnormal ET	NPL findings
No reflux (3)	2	Not significant
Grade I reflux (5)	4	Not significant
Grade II reflux (5)	4	Not significant (2) Significant (3)
Grade III reflux (17)	17	Significant

ET: Esophageal transit, GER: Gastroesophageal reflux, NPL: Nasopharyngolaryngoscopy

Table 6: Percentage of refluxate in patients with various grades of gastroesophageal reflux

Grade of GER	Percentage of refluxate into esophagus (approximate range)
Grade I	4.0%-5.2%
Grade II	4.9%-7.2%
Grade III	6.3%-8.1%

GER: Gastroesophageal reflux

Table 7: Incidence of gastroesophageal reflux in cases and control

Scintigraphic grade of GER	n		P
	Cases	Control	
I	5	2	<0.001
II	5	0	
III	17	0	
No reflux	3	8	
Total	30	10	

GER: Gastroesophageal reflux

or is merely an effect related to acid-induced injury to the esophagus is still controversial. Some studies suggest that gross pathologic injury to the esophagus is an important part of the pathophysiology of motility change, and improvement in esophageal clearance can be achieved by the healing of esophagitis.^[18,19] However, other studies show no differences of ET time and motor response to reflux between patients with esophagitis and controls.^[20,21]

In our study, when we assessed the correlation between GER, NPL findings, and esophageal motility, we found an interesting observation supporting the concept put forward by Eriksen *et al.*^[20] and Timmer *et al.*^[21] Out of three symptomatic patients with no demonstrable GER but with abnormal esophageal transit, there were no abnormal findings in nasopharyngolaryngoscopic examination. The nasopharyngolaryngoscopic findings were significant as the grade of GER becomes higher similar to those observed by Songür *et al.*^[14] and Bestetti *et al.*^[15] Our study showed that there was no correlation found between the nasopharyngolaryngoscopic findings and esophageal transit. Similarly, Ho *et al.*^[17] found no correlation between esophagitis on endoscopy and esophageal motility. Lemme *et al.*^[22] in their study concluded that there were no differences between the severity of ineffective esophageal motility in erosive and in nonerosive GERD patients. However, there was a linear statistically significant

association between the grade of GER and the NPL findings [Table 10] ($P < 0.001$).

Similar findings were observed in the study by Ho *et al.*^[17] in which they found that 56.7% of patients without endoscopic esophagitis had IEM. They showed that GERD patients with IEM did not have more endoscopic esophagitis than patients with normal manometry. No correlation was found between the endoscopic esophagitis and esophageal motility like our study. The only contrary was that our study had NPL as documentation for mucosal injury instead of upper GI endoscopy in the other studies. These results would indicate that IEM is an integral part of GER disease and is more of a cause than an effect^[20,23] and may not always be associated with mucosal injury.

Conclusion

Gastroesophageal scintigraphy was able to demonstrate significant GER in patients presenting with otolaryngeal symptoms without the typical GI symptoms. ETS could effectively document the presence of esophageal motility disorder in a simple, noninvasive manner entailing a low radiation burden and closely reflecting the normal physiology. ETS objectively showed the coexistence of esophageal motility disorder in most of the patients presenting with otolaryngeal symptoms even without an associated reflux disease. We suggest esophageal transit/gastroesophageal scintigraphy should be included in the routine workup of all the patients with recurrent otolaryngeal symptoms and may be useful for monitoring response to therapy. Our study suggests possibility of ineffective esophageal motility being the primary disorder leading to otolaryngeal symptoms in most of the patients along with associated reflux disease. This needs to be evaluated in larger patient cohort.

Financial support and sponsorship

Nil.

Conflicts of interest

There are no conflicts of interest.

References

1. Koufman JA. The otolaryngologic manifestations of gastroesophageal reflux disease (GERD): A clinical investigation of 225 patients using ambulatory 24-hour pH monitoring and an experimental investigation of the role of acid and pepsin in the development of laryngeal injury. *Laryngoscope* 1991;101:1-78.
2. Ferguson MK, Ryan JW, Little AG, Skinner DB. Esophageal emptying and acid neutralization in patients with symptoms of esophageal reflux. *Ann Surg* 1985;201:728-35.
3. Sandler MP, Coleman RE, Patton JA, Wackers FJ, Gottschalk A. Esophageal transit, gastroesophageal reflux and gastric emptying. *Diagnostic Nuclear Medicine*. 3rd ed. Ch. 24. Lippincott Williams and Wilkins 2003; p. 491-2.
4. Tuncel M, Kirathi PO, Aksoy T, Bozkurt MF. Gastroesophageal reflux scintigraphy: Interpretation methods and inter-reader agreement. *World J Pediatr* 2011;7:245-9.

Table 8: Comparison of esophageal transit in erect position - cases and control

ET in erect	n		P
	Cases	Control	
Delayed	12	0	<0.019
Normal	18	10	
Total	30	10	

ET: Esophageal transit

Table 9: Comparison of esophageal transit in supine position - cases and control

ET in supine	n		P
	Cases	Control	
Delayed	27	1	<0.001
Normal	3	9	
Total	30	10	

ET: Esophageal transit

Table 10: Scintigraphic grade of gastroesophageal reflux and nasopharyngolaryngoscopy cross-tabulation

Scintigraphic grade of GER	NPL findings		Total	P
	Not significant	Significant		
I	5	0	5	<0.001
II	2	3	5	
III	0	17	17	
No reflux	3	0	3	
Total	10	20	30	

NPL: Nasopharyngolaryngoscopy, GER: Gastroesophageal reflux

5. French CL, Irwin RS, Curley FJ, Krikorian CJ. Impact of chronic cough on quality of life. *Arch Intern Med* 1998;158:1657-61.
6. Irwin RS, Boulet LP, Cloutier MM, Fuller R, Gold PM, Hoffstein V, *et al.* Managing cough as a defense mechanism and as a symptom. A consensus panel report of the American College of Chest Physicians. *Chest* 1998;114:133S-81S.
7. Irwin RS, Curley FJ, French CL. Chronic cough. The spectrum and frequency of causes, key components of the diagnostic evaluation, and outcome of specific therapy. *Am Rev Respir Dis* 1990;141:640-7.
8. McGarvey LP, Heaney LG, Lawson JT, Johnston BT, Scally CM, Ennis M, *et al.* Evaluation and outcome of patients with chronic non-productive cough using a comprehensive diagnostic protocol. *Thorax* 1998;53:738-43.
9. Irwin RS, French CL, Curley FJ, Zawacki JK, Bennett FM. Chronic cough due to gastroesophageal reflux. Clinical, diagnostic, and pathogenetic aspects. *Chest* 1993;104:1511-7.
10. Ing AJ, Ngu MC, Breslin AB. Pathogenesis of chronic persistent cough associated with gastroesophageal reflux. *Am J Respir Crit Care Med* 1994;149:160-7.
11. Ing AJ, Ngu MC, Breslin AB. Chronic persistent cough and gastro-oesophageal reflux. *Thorax* 1991;46:479-83.
12. Holloway RH, Hongo M, Berger K, McCallum RW. Gastric distention: A mechanism for postprandial gastroesophageal reflux. *Gastroenterology* 1985;89:779-84.
13. Ing AJ, Ngu MC, Breslin AB. Chronic persistent cough and clearance of esophageal acid. *Chest* 1992;102:1668-71.
14. Songür N, Songür Y, Cerci SS, Oztürk O, Sahin U, Senol A, *et al.* Gastroesophageal scintigraphy in the evaluation of adult patients with chronic cough due to gastroesophageal reflux disease. *Nucl Med Commun* 2008;29:1066-72.
15. Bestetti A, Carola F, Carnevali-Ricci P, Sambataro G, Tarolo GL. ^{99m}Tc-sulfur colloid gastroesophageal scintigraphy with late lung imaging to evaluate patients with posterior laryngitis. *J Nucl Med* 2000;41:1597-602.
16. Fouad YM, Katz PO, Hatlebakk JG, Castell DO. Ineffective esophageal motility: The most common motility abnormality in patients with GERD-associated respiratory symptoms. *Am J Gastroenterol* 1999;94:1464-7.
17. Ho SC, Chang CS, Wu CY, Chen GH. Ineffective esophageal motility is a primary motility disorder in gastroesophageal reflux disease. *Dig Dis Sci* 2002;47:652-6.
18. Kahrilas PJ, Dodds WJ, Hogan WJ, Kern M, Arndorfer RC, Reece A, *et al.* Esophageal peristaltic dysfunction in peptic esophagitis. *Gastroenterology* 1986;91:897-904.
19. Williams D, Thompson DG, Heggie L, O'Hanrahan T, Bancewicz J. Esophageal clearance function following treatment of esophagitis. *Gastroenterology* 1994;106:108-16.
20. Eriksen CA, Sadek SA, Cranford C, Sutton D, Kennedy N, Cuschieri A, *et al.* Reflux oesophagitis and oesophageal transit: Evidence for a primary oesophageal motor disorder. *Gut* 1988;29:448-52.
21. Timmer R, Breumelhof R, Nadorp JH, Smout AJ. Oesophageal motor response to reflux is not impaired in reflux esophagitis. *Gut* 1993;34:317-20.
22. Lemme EM, Abrahão-Junior LJ, Manhães Y, Shechter R, Carvalho BB, Alvariz A, *et al.* Ineffective esophageal motility in gastroesophageal erosive reflux disease and in nonerosive reflux disease: Are they different? *J Clin Gastroenterol* 2005;39:224-7.
23. Ho KY, Kang JY. Reflux esophagitis patients in Singapore have motor and acid exposure abnormalities similar to patients in the western hemisphere. *Am J Gastroenterol* 1999;94:1186-91.