



Contents lists available at ScienceDirect

## International Journal of Surgery Case Reports

journal homepage: [www.casereports.com](http://www.casereports.com)

# Successful management of gunshot wound to the chest resulting in multiple intra-abdominal and thoracic injuries in a pediatric trauma patient: A case report and literature review

Adel Elkbuli<sup>a,\*</sup>, Evander Meneses<sup>a</sup>, Kyle Kinslow<sup>a</sup>, Mark McKenney<sup>a,b</sup>, Dessy Boneva<sup>a,b</sup>

<sup>a</sup> Department of Surgery, Division of Trauma and Surgical Critical Care, Kendall Regional Medical Center, Miami, FL, USA

<sup>b</sup> Department of Surgery, University of South Florida, Tampa, FL, USA

## ARTICLE INFO

### Article history:

Received 29 September 2020

Received in revised form 2 October 2020

Accepted 2 October 2020

Available online 5 October 2020

### Keywords:

Case report

Gunshot wound

Penetrating injury

Renal hematoma

Splenic injury

Splenectomy

## ABSTRACT

**INTRODUCTION:** Trauma remains the leading cause of mortality in the pediatric population. Penetrating thoracic injuries can result in devastating trauma to multiple organ systems. When these injuries occur, prompt diagnosis and swift treatment of internal organ injury are of utmost importance.

**CASE PRESENTATION:** A 13-year-old male presented to our Trauma Center after sustaining a gunshot wound (GSW) to the left chest. Despite his hemodynamic stability on presentation, CT scan revealed multiple injuries including splenic and renal lacerations. Exploratory laparotomy resulted in splenectomy, but no intervention was performed for the renal laceration. Instead, clinical monitoring alone was sought. Patient was discharged on hospital day 13 in stable condition.

**DISCUSSION:** Pediatric penetrating injuries secondary to GSWs can impact multiple organ systems. Despite hemodynamic stability on presentation, adequate staging of internal damage with CT allowed a targeted approach. In our case, non-operative management of the renal injury was implemented after hemorrhage control of his additional injuries. Failure to have done so would have inevitably complicated his overall management and made kidney salvage not feasible.

**CONCLUSION:** Prompt diagnosis and treatment are required in order to prevent significant morbidity and mortality in the pediatric patient from GSW-mediated penetrating thoracic injuries. Despite hemodynamic stability on presentation, patients should be emergently assessed for severe injury, with immediate surgical management as needed. Failure to do so could lead to rapid clinical deterioration, and inability to enact other conservative measures that lead to positive outcomes.

© 2020 The Author(s). Published by Elsevier Ltd on behalf of IJS Publishing Group Ltd. This is an open access article under the CC BY-NC-ND license (<http://creativecommons.org/licenses/by-nc-nd/4.0/>).

## 1. Introduction

Traumatic injuries remain the leading cause of morbidity and mortality in the pediatric population with blunt trauma mechanisms (motor vehicle collision, pedestrian accident, falls) being more common than penetrating injuries [1]. Gunshot wounds (GSWs) are the most common cause of penetrating trauma in children and adolescents with victims tending to be from lower socioeconomic areas [1,2]. As hemorrhage secondary to traumatic injury is the most common cause for mortality, studies have shown the importance for pediatric trauma patients to receive rapid diagnosis and treatment from specialized trauma centers [1,3]. Adequate assessment is imperative, especially when combined with concomitant thoracic injury. Isolated blunt thoracic trauma

in the pediatric population has an overall mortality of 5% but penetrating thoracic trauma has a mortality rate of over 14% [4,5].

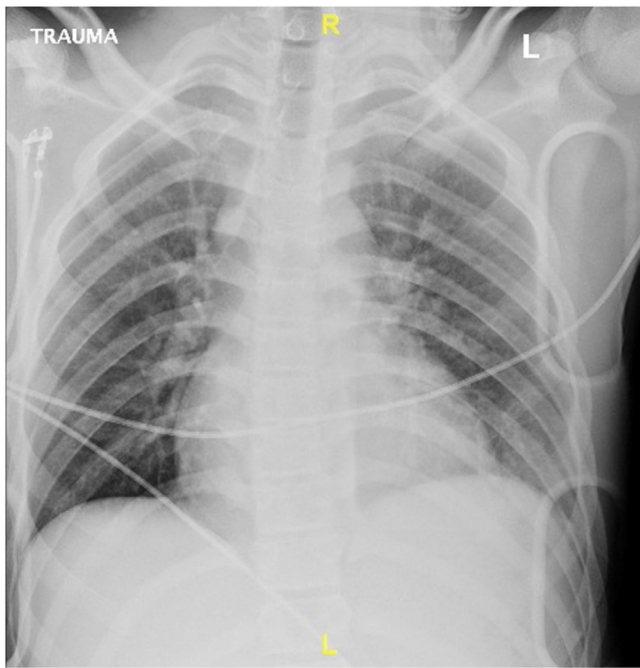
We present the case of 13-year-old male who suffered a GSW to his left chest, and due to the trajectory of the bullet, suffered severe polytrauma involving multiple body cavities. Despite his severe injuries, he was successfully managed with both operative and non-operative measures. This case was reported in line with SCARE criteria [6].

## 2. Case presentation

A 13-year-old male presented to our Level 1 Trauma Center via Emergency Medical Services (EMS) as a trauma alert after sustaining a GSW to the left chest treated with needle decompression in the field. On initial examination, his airway was intact and his vital signs were only significant for mild tachycardia of 105. His lung examination revealed symmetrical chest movement and only minor decreased breaths sounds on the injured side. His oxygen saturation was 100% on 3 L nasal cannula without any evidence of respiratory distress. He was awake and alert, with a Glasgow Coma

\* Corresponding author at: 11750 Bird Road, Miami, FL, 33175, USA.

E-mail addresses: [Adel.Elkbuli@hcahealthcare.com](mailto:Adel.Elkbuli@hcahealthcare.com), [a.elkbuli@med.miami.edu](mailto:a.elkbuli@med.miami.edu) (A. Elkbuli).

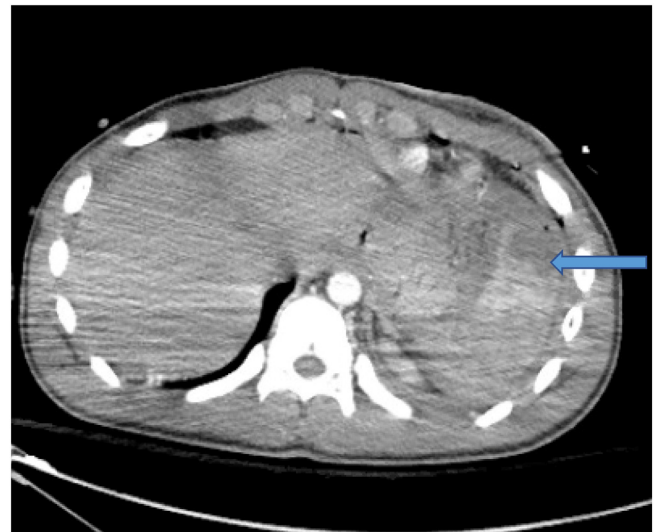


**Fig. 1.** Chest radiograph taken in the trauma bay without evidence of pneumothorax, hemothorax, or retained bullet fragment.

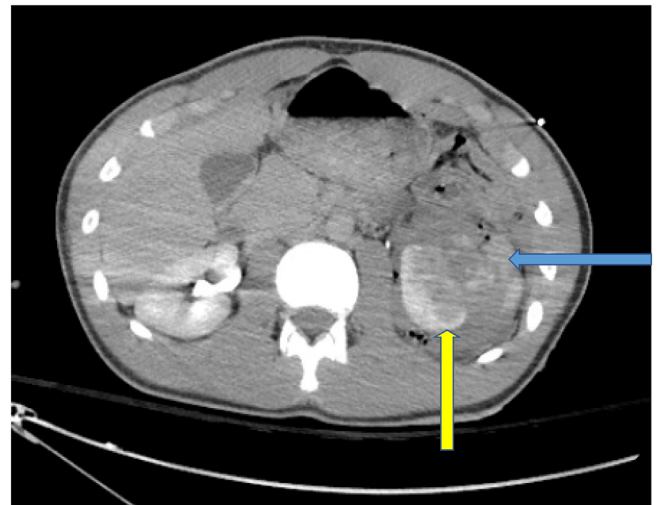
Scale 15. A bullet entry wound to the left chest was noted with exit from the left lower back.

Chest x-ray was negative for pneumothorax, most likely due to the needle decompression performed in the field, and negative for retained bullet fragments (Fig. 1). Initial laboratory results showed an elevated lactic acid of 6.2 (normal 0.4–2.0). His ABG pH was 7.33 (normal 7.35–7.45). Since he had no signs of respiratory distress from a possible pneumothorax, there was no need for immediate chest tube placement on the side of needle decompression. Because of the GSW trajectory, it was considered that the patient had likely suffered multi-organ, multiple cavity injury. He was taken for computed tomography (CT) scan to quickly evaluate the extent of his injuries. A quick transfer time of 16 min from arrival in trauma bay to CT scanner allowed for better visualization and evaluation of the extent of injuries the patient suffered from the gunshot wound and significantly aided in addressing those injuries intraoperatively. CT of the chest, abdomen and pelvis with IV contrast were performed which revealed a left sixth rib fracture, a left pulmonary contusion, a left hemothorax, a grade 4 splenic injury with contrast extravasation (Figs. 2 & 4), left kidney injury with contrast extravasation and a perinephric hematoma measuring 13 cm × 8 cm × 6 cm (Figs. 3 & 4), and foci of pneumoperitoneum in the left side of the abdomen. The patient was then promptly taken to the operating room for exploratory surgery.

Foley placement in the operating theater revealed frank hematuria. Subsequent exploratory laparotomy revealed a severe splenic laceration, a large retro-peritoneal/peri-nephric hematoma, and a colon injury with more than 50% circumference damage at the splenic flexure with stool contamination. There was a large mesenteric hematoma at the descending colon which was to be re-assessed during the follow up surgery. In addition, there was a left diaphragm laceration injury, and a left hemothorax. The patient underwent evacuation of the intra-abdominal hematoma and splenectomy to control the hemorrhage. Mobilization of the colonic splenic flexure with segmental colonic resection at the distal transverse colon was also performed for which he was left in temporary discontinuity. A left chest tube was placed due to the hemothorax and the previous needle decompression of the



**Fig. 2.** CT scan abdomen/pelvis with IV contrast - axial view demonstrates grade IV splenic injury with splenic hematoma and contrast extravasation indicating active bleeding due to splenic rupture (blue arrow).

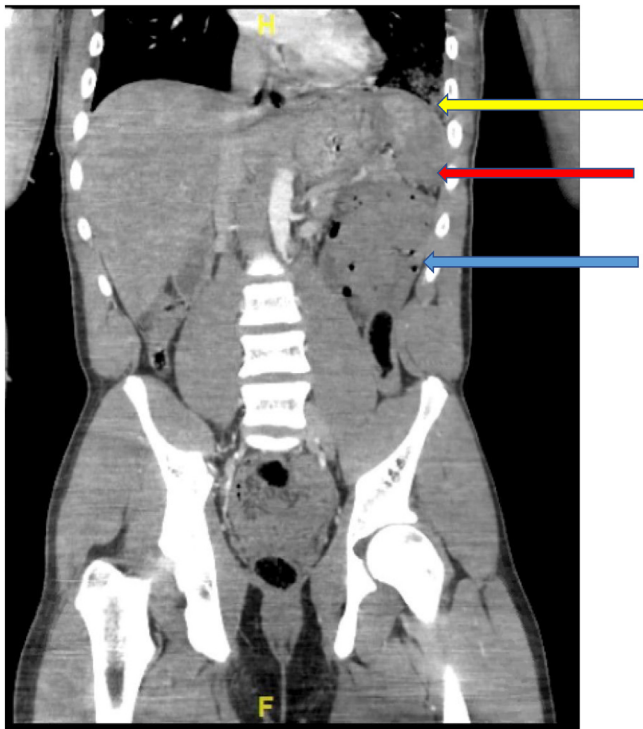


**Fig. 3.** CT scan abdomen/pelvis with IV contrast - axial view demonstrates a 13 cm × 8 cm × 6 cm left perinephric hematoma (blue arrow) and a high grade left kidney injury (yellow arrow).

left chest. Inspection of the heart revealed a contusion but no pericardial hematoma or fluid. The diaphragm was then repaired. The retroperitoneal injury was seen as a stable, non-expanding hematoma, and so the decision for observational management of this injury was carried out. Following this, an abdominal vacuum wound dressing was placed, and the patient was admitted to the Pediatric Intensive Care Unit (PICU). Intraoperatively, patient received a total of 1 L of crystalloid and no blood.

Postoperatively, resuscitation continued in the PICU where he received 2 units of packed red blood cells (PRBCs). His post-op, post-transfusion Hgb was 9. A post-operative EKG was normal but an echocardiogram revealed an ejection fraction of 43% without tamponade or valvular abnormality. The low ejection fraction was attributed to cardiac contusion. Further workup for his injuries included angiography to confirm cessation of bleeding from the left kidney injury, retroperitoneum and splenic hilum. His lactic acid resolved. Serial hemoglobin checks were stable.

On post-operative day 1, re-exploratory laparotomy with abdominal washout, end-to-end colo-colonic anastomosis (dis-



**Fig. 4.** CT scan abdomen/pelvis with IV contrast - coronal view demonstrates a large left sided perinephric hematoma (blue arrow). Part of the spleen is also seen highlighted with IV contrast (yellow arrow) and splenic hematoma (red arrow) due to splenic rupture.

tal transverse to proximal descending) was accomplished. The retroperitoneal hematoma was stable. He had closure of abdominal fascia with the skin left open with a wound vacuum. The decision for placing a wound vacuum instead of closing skin edges was due to the contamination from the initial colon injury and to lower the risk of wound infection. On hospital day 3, the wound vacuum over the laparotomy incision was removed and delayed primary closure of the skin, using steri-strips was performed.

On post-operative day 6, he developed a mild acute kidney injury with a creatinine of 1.20 (normal 0.12–1.06). Since he had a significant kidney injury, urine leak was suspected but this was ruled out with CT urogram. Following this, his creatinine normalized. Once the hemothorax had resolved and drainage output was minimal, his chest tube was removed on post-operative day 9. The cardiac contusion was managed expectantly and his cardiac output with non-invasive monitoring normalized after a brief management with inotropic pressors. Prior to discharge, he was tolerating a regular diet, voiding without difficulty, and ambulating independently. He received post-splenectomy vaccines for the encapsulated organisms (*S. pneumoniae*, *N. meningitidis*, and *H. influenzae* type b) prior to discharge on hospital day 13.

### 3. Discussion

We present the case of a pediatric GSW to the left chest that was managed successfully despite devastating injuries to multiple organ systems. It was not only our patient's polytrauma, but the specific injuries sustained (i.e. hemothorax, diaphragm, splenic, colon and kidney laceration, cardiac contusion) that portended a potentially poor prognosis. While hemodynamically stable on initial presentation, his overall condition was critical. Rapid operative management and intensive stabilization was key in preventing an otherwise certain, rapid decline in clinical status.

Polytrauma has been defined as two or more severe injuries [7]. Historically, polytrauma has been classified by the Injury Severity Score (ISS) with a score of  $\geq 15$  being correlated with a greater than 10% mortality risk [8,9]. The Pediatric Trauma Score (PTS) has similar prediction value for children in which a lower score confers increased risk of mortality [10]. Our patient's ISS score of 41 and PTS score of 8 speak to the severity of his traumatic insult. Additionally, previously described prognostic factors of penetrating thoracic trauma in the pediatric population include a combination of ISS and acidosis. An ISS  $> 25$  and significant acidosis ( $\text{pH} < 7.3$ ) have been associated with higher mortality rate and increased need for surgical intervention in prior studies [11]. While our patient's initial ABG pH was borderline (7.33), this in conjunction with his ISS support his higher risk of mortality and need for urgent surgical intervention from a clinical and laboratory standpoint. For this reason, and because he was hemodynamically stable at the time, we quickly brought him to CT from the trauma bay to gain a better understanding of his sustained injuries followed by immediate transfer to the operating room.

While our patient's clinical picture alone was indicative of the need for surgical management, his diagnostic findings (perinephric hematoma, splenic laceration, colon injury, etc.) further supported our final operative decision-making. His arrival in critical condition, but maintenance of vital signs, could lead one to falsely believe an underlying stable injury pattern and no need for emergent diagnostic assessment, or urgent surgical management. At patient intake in the trauma bay, preliminary decisions have vast implications down the road if not made quickly and accurately. What begins as a seemingly stable patient can rapidly turn into a patient requiring emergency resuscitation measures. In our patient's case, his multi-trauma portended a significant risk for such clinical deterioration. Subsequent development of hemorrhagic shock could have led to a necessity for large blood product transfusion and intravenous fluid volumes. With such management, "The triad of death" (hypothermia, coagulopathy, and metabolic acidosis) in exsanguinating patients could develop and potentially complicate his outcome. For example, development of coagulopathy would have likely led to lack of hemostatic control of the renal injury and altered his overall management (i.e. immediate nephrectomy rather than observation). Additional morbidity caused by entry into such an unstable cycle of resuscitation is even more far-reaching. The potential complications (ARDS, DIC, etc.) associated with extended intubation and massive transfusions would have likely altered our patient's outcome entirely. His hemodynamic stability on presentation was not the factor portending his overall successful outcome, but rather, the urgent surgical management enacted to maintain this relative stability throughout his hospital course.

While the spleen is the most commonly injured organ that children sustain in blunt abdominal trauma, penetrating splenic injury is much less common [12]. Historically, blunt splenic injuries had been treated with splenectomy, but careful observation and monitoring now allow predominantly non-operative management of these injuries, as long as the patient remains hemodynamically stable [13]. If observation fails, embolization is a potential stabilizing treatment that prevents the patient from undergoing a major abdominal surgery, which has its additional increased morbidity risk [14]. However, embolization failure ultimately necessitates splenectomy. Regarding penetrating splenic injury, immediate splenectomy is the current standard of care. However, recent evidence has offered support for non-operative management in select populations. A systematic review conducted by Sakamoto et al. showed that splenic injury was one of multiple penetrating solid organ injuries successfully managed with non-operative management [15]. They found a non-operative management failure rate of 28.5% with GSW, high-grade solid organ injury, and associ-



ated hollow viscus injury being significant contributing factors. Our patient's high-grade splenic injury, associated bowel injury, hematoma formation, and mechanism of injury ultimately warranted operative removal. Without rapid splenectomy, our patient would have been at significant risk for development of hemorrhagic shock and the associated sequelae described above.

Our patient's colonic injury warranted emergent surgical intervention with the choice of anastomosis staging being multifactorial. During his initial surgery, colonic discontinuity was performed without ostomy redirection as anastomosis was planned for the following day pending patient clinical stability. Previous literature has shown that in children with penetrating colorectal injury, colostomy resulted in longer hospital length of stay and higher complication rates with immediate primary anastomosis of colonic injuries proving safer, if feasible [16]. On index operation, we could have created a colostomy to divert the fecal stream due to the severe colonic injury. However, we instead decided to leave the patient in discontinuity for reassessment during his second surgery. Prior to re-exploratory laparotomy, he was hemodynamically stable without vasopressor support and adequately resuscitated. On second look, both colonic ends appeared viable and colo-colonic anastomosis was performed. He had no subsequent anastomotic leak or colon-related complications. Since the patient was managed quickly from his initial arrival to the hospital, we were able to control his colonic injury in this manner. Requirement of massive fluid resuscitation due to entry into an unstable state would have certainly altered the feasibility of performing an early anastomosis, with colostomy instead being sought. This again supports the urgency needed to prevent critically injured patients from becoming unstable regardless of initial presentation as to reduce potential adverse outcomes.

The management of the left kidney injury and perinephric hematoma posed the greatest challenge. However, complex decision making allowed us to preserve the kidney despite the major injury. On initial operation, accessing the retroperitoneum would have likely eliminated any tamponade effect, resulting in further bleeding, immediate onset of hemodynamic instability, and potential hemorrhagic shock. If the patient had gone into prolonged hemorrhagic shock by not undergoing urgent surgical management, he may have become more coagulopathic, resulting in continued bleed and expansion of the renal hematoma requiring nephrectomy. Despite the large hematoma creating mass effect on the intraperitoneal space, the surrounding intact structures, the non-expanding hematoma, and the patient's vital signs being maintained secondary to his prompt splenectomy allowed for a more conservative approach to avoid nephrectomy.

Previous literature has shown that pediatric renal trauma requires early detection, with staging required to determine operative or non-operative management [17]. Additionally, multiple studies have investigated the efficacy of renal preservation in the context of penetrating renal injury [17,18]. A retrospective review of 374 pediatric renal injuries by Buckley et al. showed that 41% of grade 4 renal injuries in hemodynamically stable children were successfully managed non-operatively based on CT staging alone (overall renal salvage rate >99%) [17]. Okur et al. also concluded that successful non-operative renal conservation is achievable in hemodynamically stable children with high-grade renal injury [18]. On the other hand, Davis et al. report that compared to children with renal injury secondary to blunt trauma, those with penetrating injury were significantly more likely to undergo nephrectomy. Among other factors, penetrating trauma was a major predictor of nephrectomy requirement [19]. Ultimately, our decision to observe the kidney injury was in the setting of hemodynamic stability. However, such stability would not have been obtained with general "watchful waiting". The prompt damage control of the splenic laceration with splenectomy, the hematoma evacuation, etc directly

led to the overall hemodynamic sustainment suitable for kidney salvage.

While cardiac injury in pediatric trauma is an uncommon entity, it can be life threatening when sustained. The incidence in our patient most likely occurred secondary to passage of the bullet near the mediastinum. In our case, the contusion manifested as a low ejection fraction on echocardiography after his initial operation, despite a normal cardiac output. Cardiac contusions have been shown to be associated with excessive in-hospital mortality, with a previous study showing as high as 35–40% [20,21]. Contusions can manifest as ST segment elevation, elevated cardiac biomarkers, and an abnormal echocardiogram. Treatment varies depending on the severity, with patients sometimes requiring consideration for urgent coronary revascularization [22]. In this case, our patient's cardiac contusion was successfully managed without need for such invasive measures.

#### 4. Conclusion

Pediatric penetrating injuries secondary to gunshot trauma can impact multiple organ systems and be immediately life threatening. Despite hemodynamic stability on presentation, adequate staging of internal damage with computerized tomography and subsequent urgent surgical intervention should be sought as needed, especially with abdominal/thoracic bullet entry. While splenic and/or renal injury secondary to penetrating trauma is rare in pediatric populations, standard management involves splenectomy/nephrectomy with growing evidence also supporting non-operative management in select populations. In our case, the non-operative management of a renal injury with hematoma was only possible due to the rapid intervention to control hemorrhage from his additional injuries. Failure to have done so would have inevitably complicated his management overall and made kidney salvage not feasible.

#### Declaration of Competing Interest

None.

#### Funding

None.

#### Ethical approval

This report was conducted in compliance with ethical standards. Informed written consent has been obtained and all identifying information is omitted.

#### Consent

Written informed consent was obtained from the patient for publication of this case report and accompanying images. A copy of the written consent is available for review by the Editor-in-Chief of this journal on request.

#### Author contribution

AE, EM, KK, DB, MM Conception of study, acquisition of data, analysis and interpretation of data, drafting the article, and revision of article. DB, MM – Management of case.

AE, EM, KK, DB, MM – Approval of the final version for submission.

DB – Operative Surgeon.

**Registration of research studies**

This is not first in man case report.

**Guarantor**

Dessy Boneva.  
Mark McKenney.

**Provenance and peer review**

Not commissioned, externally peer-reviewed.

**References**

- [1] A. Mikrogianakis, Penetrating abdominal trauma in children, *Clin. Pediatr. Emerg. Med.* 11 (3) (2010) 217–224.
- [2] M.L. Nance, R.F. Sing, P.M. Reilly, J.M. Templeton Jr., C.W. Schwab, Thoracic gunshot wounds in children under 17 years of age, *J. Pediatr. Surg.* 31 (7) (1996) 931–935.
- [3] J.B. Avraham, M. Bhandari, S.G. Frangos, D.A. Levine, M.G. Tunik, C.J. DiMaggio, Epidemiology of paediatric trauma presenting to US emergency departments: 2006–2012, *Inj. Prev.* 25 (2) (2019) 136–143.
- [4] M.H. Peclat, K.D. Newman, M.R. Eichelberger, C.S. Gotschall, V.F. Garcia, L.M. Bowman, Thoracic trauma in children: an indicator of increased mortality, *J. Pediatr. Surg.* 25 (9) (1990) 961–966.
- [5] A. Cooper, B. Barlow, C. DiScala, D. String, Mortality and truncal injury: the pediatric perspective, *J. Pediatr. Surg.* 29 (1) (1994) 33–38.
- [6] R.A. Agha, M.R. Borrelli, R. Farwana, K. Koshy, A.J. Fowler, D.P. Orgill, et al., The SCARE 2018 statement: updating consensus Surgical Case Report (SCARE) guidelines, *Int. J. Surg.* 60 (2018) 132–136.
- [7] J. Kroupa, Definition of “polytrauma” and “polytraumatism”, *Acta Chir. Orthop. Traumatol. Cech.* 57 (4) (1990) 347–360.
- [8] B.A. Cotton, M.L. Nance, Penetrating trauma in children. In *Seminars in Pediatric Surgery*, vol. 13, WB Saunders, 2004, May, pp. 87–97, No. 2.
- [9] A.J. Mazurek, Epidemiology of paediatric injury, *Emerg. Med. J.* 11 (1) (1994) 9–16.
- [10] M. Lecuyer, Calculated decisions: pediatric trauma score (PTS), *Pediatr. Emerg. Med. Pract.* 16 (5) (2019) CD3–4.
- [11] M. Reinhorn, H.L. Kaufman, E.F. Hirsch, F.H. Millham, Penetrating thoracic trauma in a pediatric population, *Ann. Thorac. Surg.* 61 (5) (1996) 1501–1505.
- [12] M.A. Morse, V.F. Garcia, Selective nonoperative management of pediatric blunt splenic trauma: risk for missed associated injuries, *J. Pediatr. Surg.* 29 (1) (1994) 23–27.
- [13] T. Lynch, J. Kilgar, A. Al Shibli, Pediatric abdominal trauma, *Curr. Pediatr. Rev.* 14 (1) (2018) 59–63, <http://dx.doi.org/10.2174/1573396313666170815100547>.
- [14] J.L. Gross, N.L. Woll, C.A. Hanson, C. Pohl, R.J. Scorpio, A.P. Kennedy Jr., C.P. Coppola, Embolization for pediatric blunt splenic injury is an alternative to splenectomy when observation fails, *J. Trauma Acute Care Surg.* 75 (3) (2013) 421–425.
- [15] R. Sakamoto, K. Matsushima, A. de Roulet, K. Beetham, A. Strumwasser, D. Clark, K. Inaba, D. Demetriades, Nonoperative management of penetrating abdominal solid organ injuries in children, *J. Surg. Res.* 228 (2018) 188–193, <http://dx.doi.org/10.1016/j.jss.2018.03.034>.
- [16] E.R. Haut, M.L. Nance, M.S. Keller, J.I. Groner, H.R. Ford, A. Kuhn, P.W. Stafford, Management of penetrating colon and rectal injuries in the pediatric patient, *Dis. Colon Rectum* 47 (9) (2004) 1526–1532.
- [17] J.C. Buckley, J.W. McANINCH, Pediatric renal injuries: management guidelines from a 25-year experience, *J. Urol.* 172 (2) (2004) 687–690.
- [18] M.H. Okur, S. Arslan, B. Aydogdu, M.S. Arslan, C. Goya, H. Zeytun, E. Basuguy, I. Uygun, M.K. Çigdem, A. Önen, S. Otcu, Management of high-grade renal injury in children, *Eur. J. Trauma Emerg. Surg.* 43 (1) (2017) 99–104, <http://dx.doi.org/10.1007/s00068-016-0636-y>.
- [19] K.A. Davis, R.L. Reed 2nd, J. Santaniello, A. Abodeely, T.J. Esposito, S.J. Poulakidas, F.A. Luchette, Predictors of the need for nephrectomy after renal trauma, *J. Trauma* 60 (1) (2006) 164–170, <http://dx.doi.org/10.1097/01.ta.0000199924.39736.36>.
- [20] Y.E. Kaptein, P. Talving, A. Konstantinidis, L. Lam, K. Inaba, D. Plurad, D. Demetriades, Epidemiology of pediatric cardiac injuries: a National Trauma Data Bank analysis, *J. Pediatr. Surg.* 46 (8) (2011) 1564–1571.
- [21] K.S. Mylonas, D.I. Tsilimigras, P. Texakalidis, P. Hemmati, D. Schizas, K.P. Economopoulos, Pediatric cardiac trauma in the United States: a systematic review, *World J. Pediatr. Congenit. Heart Surg.* 9 (2) (2018) 214–223.
- [22] M.A. Huis, C.A. Craft, R.E. Hood, Blunt cardiac trauma review, *Cardiol. Clin.* 36 (1) (2018) 183–191.

**Open Access**

This article is published Open Access at [sciencedirect.com](https://www.sciencedirect.com). It is distributed under the [IJSCR Supplemental terms and conditions](#), which permits unrestricted non commercial use, distribution, and reproduction in any medium, provided the original authors and source are credited.