

Clinical Report

Rituximab-associated interstitial lung disease in fibrillary glomerulonephritis

Valeria Sainz-Prestel^{1,2}, Jesus Hernandez-Perez^{1,2}, Jorge Rojas-Rivera^{1,2}, José María Milicua-Muñoz^{3,4}, Jesus Egido¹ and Alberto Ortiz^{1,2}

¹Nephrology, IIS-Fundación Jimenez Diaz/UAM/IRSIN, Madrid, Spain, ²REDINREN, ³Pathology, IIS-Fundación Jimenez Diaz/UAM/IRSIN, Madrid, Spain and ⁴ICU, IIS-Fundación Jimenez Diaz/UAM, Madrid, Spain

Correspondence and offprint requests to: Alberto Ortiz; E-mail: aortiz@fjd.es

Abstract

Rituximab (RTX) is a chimeric monoclonal antibody against CD20+ B cells increasingly used to treat kidney disorders. RTX-induced pulmonary disease has been reported in patients treated for haematological disorders, and a few cases have been observed in patients with underlying rheumatological conditions. We report a case of non-infectious interstitial pneumonitis associated with RTX use in a 49-year-old patient with primary (fibrillary) glomerulonephritis. As typically observed, discontinuation of the drug and prompt initiation of glucocorticoids led to resolution of pulmonary manifestations. However, fatalities have been reported and nephrologists treating glomerulonephritis patients with RTX should be aware of the existence of this potentially lethal complication.

Keywords: adverse effects; biological; glomerulonephritis; lung

Background

Rituximab (RTX) is a chimeric monoclonal antibody against CD20 which was initially developed as a treatment for B-cell lymphoma. B-cell depletion therapy with RTX has also been reported in several systemic autoimmune diseases such as rheumatoid arthritis (RA) or systemic lupus erythematosus (SLE) [1]. The full spectrum of RTX toxicity in patients not receiving chemotherapy for lymphoma is still incompletely understood. RTX-induced pulmonary disease has been reported in haematological disorders [2]. A few cases were observed in patients with underlying rheumatological conditions [2–6]. One case was reported in a patient with steroid-resistant nephrotic syndrome [7].

We report a case of RTX-associated interstitial lung disease in a patient with fibrillary glomerulonephritis.

Case report

A 49-year-old man presented with nephrotic syndrome and increased serum creatinine. Past history included hypertension, hypercholesterolaemia, porphyria cutanea tarda and chronic liver disease secondary to hepatitis C virus (HCV) genotype 4. Eight years earlier HCV had been treated with peg-interferon- α plus ribavirin for 13 weeks, but therapy was discontinued due to poor response and poor tolerance. The patient refused further treatment for HCV infection.

A kidney biopsy revealed fibrillary glomerulopathy. He was initially treated with furosemide, thiazide, angiotensin-converting enzyme inhibitor, angiotensin receptor blocker, spironolactone, doxazosin and a calcium channel

antagonist. The blood pressure was controlled and proteinuria decreased from 11–15 g/day to 7–9 g/day (11.000–15.000 mg/24 h to 7.000–9.000 mg/24 h). However, serum creatinine rose from 132.6 to 247.5 $\mu\text{mol/L}$ (1.5 to 2.8 mg/dL). Due to progressive impairment of renal function and persistent nephrotic proteinuria, immunosuppressive treatment was started with prednisone (1 mg/kg/day for 1 month and taper) and two 1000 mg doses of RTX separated 15 days.

Five weeks after the last RTX dose, progressive shortness of breath and dry cough developed without fever or other symptoms. He was admitted to the intensive care unit (ICU) because of low oxygen saturation (68%). Computed tomography revealed bilateral interstitial pulmonary infiltrates without pleural effusion. Bronchoscopy and bronchoalveolar lavage showed no bleeding and microbiological studies were negative.

The patient was treated with intravenous antibiotics and high-dose corticosteroids. He was discharged from the ICU after 10 days with the diagnosis of respiratory failure probably due to interstitial pneumonitis secondary to RTX. The serum creatinine level increased to 530.4 $\mu\text{mol/L}$ (6 mg/dL) and renal replacement therapy with haemodialysis was initiated (Figure 1).

Discussion

Non-infectious pulmonary disease is considered a complication of RTX use for malignancy. A recent systematic literature review identified 121 cases of RTX-associated lung injury reported in 65 studies [2]. Most patients had an

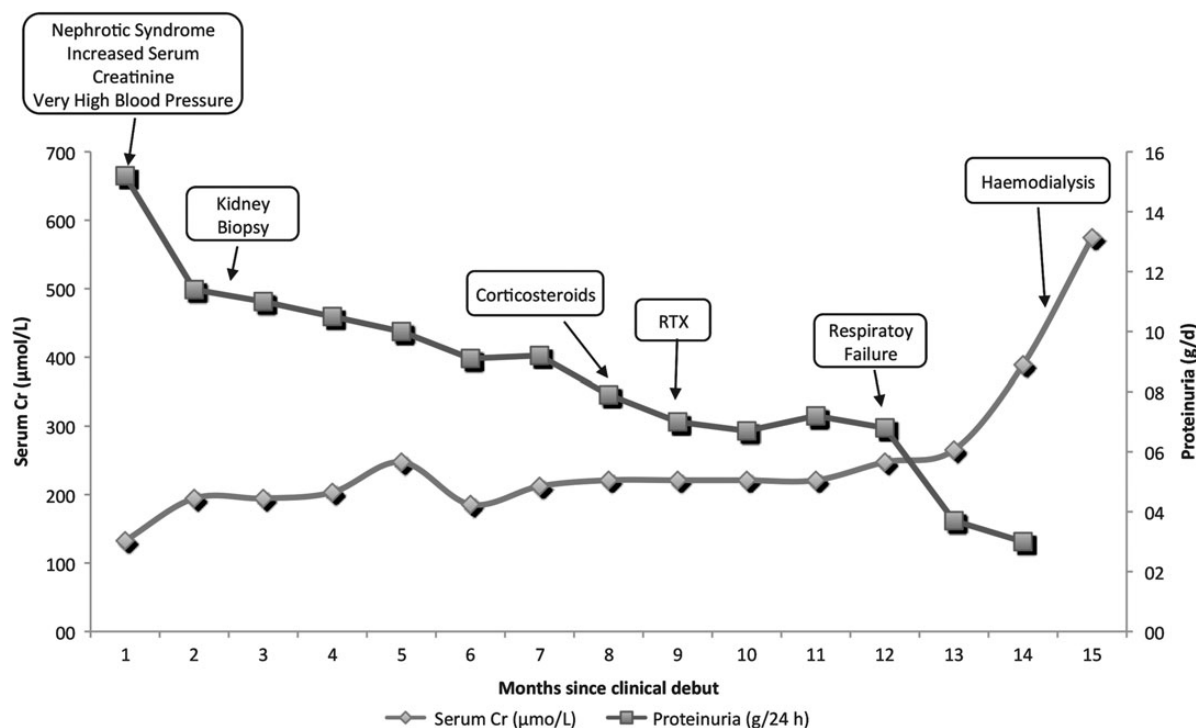


Fig. 1. Renal course of patient with fibrillary glomerulonephritis treated with corticosteroids and RTX.

underlying haematological disease. However, five cases were observed in patients with an underlying rheumatological condition but no haematological disease [2–5]. An additional case of pneumonitis secondary to RTX was reported in an RA patient [6]. Despite the widespread use of RTX in the treatment of membranous nephropathy, fibrillary glomerulonephritis and other forms of renal injury [8, 9], no cases of non-infectious pulmonary disease had been reported in patients treated for primary glomerulonephritis, according to the literature review in April 2013 (Table 1). The only reported patient with kidney disease had lupus nephritis and developed interstitial pneumonitis while on RTX [3]. In addition, a paediatric case of fatal pulmonary disease was observed in a girl 3 days after RTX administration for steroid-resistant nephrotic syndrome. In that case, a syncytial respiratory virus was found in a broncho-alveolar lavage, although the author felt that the infection did not play a determinant role [7].

There are no agreed upon criteria for the diagnosis of RTX-associated lung disease. However, the hypoxaemia, radiological and broncho-alveolar lavage findings, time course and response to steroids in the absence of an identifiable infectious agent in this patient are consistent with the diagnostic criteria generally used in the literature.

The pathogenesis of RTX-induced interstitial lung disease is unknown. It has been proposed to be secondary to cytotoxic T lymphocyte activation, cytokine release and complement activation, but specifically, the role of B-cell depletion in this complication is unknown. In particular, *tumour necrosis factor- α* (TNF- α) has been postulated as a mediator in the pathogenesis of interstitial lung disease because of its proinflammatory effects [10, 11]. However, there is no direct functional proof, such as response to anti-TNF- α therapy, to implicate this particular cytokine or any other in the pathogenesis of human RTX-associated lung disease. In fact, failure of anti-TNF-therapy for RTX-induced pulmonary disease has been reported [12].

Furthermore, most cases in non-cancer patients have been reported to occur 20–28 weeks after the first dose, a time course that is not consistent with acute effects of the drug. However, cases have been reported as early as 4 days after RTX [13], raising questions on whether the disease had the same pathogenesis in all cases reported. The present case was observed 7 weeks after the first RTX dose, which is earlier than in most reported cases (Table 1). However, this time course is consistent with that observed in the only patient who had kidney injury, the lupus nephritis patient [3]. The half-life of RTX is 18 days (range 5–78 days) [14]. The long lag periods observed are not consistent with a direct toxic effect of RTX, since concentrations of the drug at the time of the adverse effect should be much lower than earlier in the course of the follow-up. In contrast, the time course of the adverse effect is consistent with a progressive decrease in immunoglobulin concentrations, which in the case of nephritis patients may be accelerated by loss of immunoglobulins in urine. Thus, we propose that the pathogenesis may be related to loss of immunoglobulins and suggest a role for uncharacterized pathogens.

Patients with RTX-associated lung disease have been empirically treated with antibiotics and steroids, as was the present patient. Early suspicion and therapy are important since the mortality rate in reported cases in non-haematological disorders was 25% (Table 1).

Lung involvement consisting of pulmonary haemorrhage and fibrillary deposits in pulmonary alveolar-capillary interstitium has been reported in fibrillary glomerulonephritis [15], in our case the broncho-alveolar lavage discarded the presence of pulmonary haemorrhage.

In summary, we describe the first case of non-infectious interstitial pneumonitis associated with RTX use in a patient with primary glomerulonephritis. Nephrologists treating glomerulonephritis patients with RTX should be aware of the existence of this potentially lethal complication.

Table 1. Summary of reported cases of pulmonary toxicity associated with RTX as a treatment for non-haematological diseases

Study	Disease	Gender	Age	Dosing regimen	Accumulative dose	Concurrent treatment	Radiological findings	Lag time (from initial dose)	Lung Outcome
RCT [4]	RA	No data	No data	2x 500 mg	1000 mg	MTX	ILD	No data	Recovery
RCT [3]	SLE nephritis	Female	26	2x 1000 mg/15 days	2000 mg	None	Interstitial pneumonitis	7 weeks	Death
Case report [13]	SLE	Female	24	1x 1000 mg	1000 mg	Steroids pre-treatment	Interstitial pneumonitis	4 days	Full recovery
Case report [16]	RA	Female	64	2x 1000 mg/15 days	2000 mg	MTX and steroids	BOOP	23 weeks	Full recovery
RCT [5]	SLE	No data	No data	No data	2000 mg	Steroids	Pneumonia	28 weeks	Full recovery
Case report [6]	RA	Male	62	No data	No data	No data	Interstitial pneumonitis	28 weeks	Full recovery
Case report ^a [7]	NS	Female	9	375 mg/m ² body surface	375 mg/m ² body surface	None	ILD	3 days	Death
Present case	Fibrillary GN	Male	49	2x 1000 mg/15 days	2000 mg	Steroids	Interstitial pneumonitis	7 weeks	Full recovery

RCT, randomized controlled trial; RA, rheumatoid arthritis; SLE, systemic lupus erythematosus; MTX, methotrexate; ILD, Interstitial lung disease; BOOP, bronchiolitis obliterans organizing pneumonia; NS, nephrotic syndrome; GN, glomerulonephritis.

^aThis was the only case with an infectious agent identified: syncytial respiratory virus.

Acknowledgements. FIS PS09/00447, FEDER funds ISCIII-RETIC REDinREN/RD06/0016/, RD12/0021/, Comunidad de Madrid S2010/BMD-2378. Programa Intensificación Actividad Investigadora (ISCIII/Agencia Laín-Entralgo/CM) to AO. Special gratitude to Carlos Alcocer, Pablo Cannata and Eva Gomez-Peñalver.

Conflict of interest statement.

None declared.

References

- Rastetter W, Molina A, White CA. Rituximab: expanding role in the therapy for lymphomas and autoimmune diseases. *Annu Rev Med* 2004; 55:477–503
- Hadjinicolaou AV, Nisar MK, Bhagat S, Parfrey H, Chilvers ER, Ostör AJ. Non-infectious pulmonary complications of newer biological agents for rheumatic diseases—a systematic literature review. *Rheumatology (Oxford)* 2011; 50: 2297–2305
- Rovin BH, Furie R, Latinis K et al. and LUNAR Investigator Group. Efficacy and safety of rituximab in patients with active proliferative lupus nephritis: the lupus nephritis assessment with rituximab study. *Arthritis Rheum* 2012; 64: 1215–1226
- Emery P, Fleischmann R, Filipowicz-Sosnowska A et al. The efficacy and safety of rituximab in patients with active rheumatoid arthritis despite methotrexate treatment: results of a phase IIB randomized, double-blind, placebo-controlled, dose-ranging trial. *Arthritis Rheum* 2006; 54: 1390–1400
- Tanaka Y, Yamamoto K, Takeuchi T et al. A multicenter phase I/II trial of rituximab for refractory systemic lupus erythematosus. *Mod Rheumatol* 2007; 17: 191–197
- O'Connor MB, Bin Abdullah MF, O'Donovan N, Phelan MJ. Rituximab-induced pulmonary disease. *Rheumatol Int* 2012; 32: 2955–2956
- Chaumais MC, Garnier A, Chalard F et al. Fatal pulmonary fibrosis after rituximab administration. *Pediatr Nephrol* 2009; 24: 1753–1755
- Collins M, Navaneethan SD, Chung M et al. Rituximab treatment of fibrillary glomerulonephritis. *Am J Kidney Dis* 2008; 52: 9958–9962
- Ruggenti P, Cravedi P, Chianca A et al. Rituximab in idiopathic membranous nephropathy. *J Am Soc Nephrol* 2012; 23: 1416–1425
- Alho HS, Maasitta PK, Harjula AL, Hämmäinen P, Salminen J, Salminen US. Tumor necrosis factor- α in porcine bronchial model of obliterative bronchiolitis. *Transplantation* 2003; 76: 516–523
- Wagner SA, Mehta AC, Laber DA. Rituximab-induced interstitial lung disease. *Am J Hematol* 2007; 82: 916–919
- Wu Y, Jia Y, Xu J, Shuai X, Wu Y. Fatal interstitial lung disease induced by rituximab-containing chemotherapy, treatment with TNF- α antagonist and cytokine profiling: a case-report and review of the literature. *J Clin Pharm Ther.* 2013. [Epub ahead of print]
- Kishi J, Nanki T, Watanabe K, Takamura A, Miyasaka N. A case of rituximab-induced interstitial pneumonitis observed in systemic lupus erythematosus. *Rheumatology* 2009; 48: 447–448
- Breedveld F, Agarwall S, Yin M, Ren S, Li NF, Shaw TM, Davies BE. Rituximab pharmacokinetics in patients with rheumatoid arthritis: B-cell levels do not correlate with clinical response. *J Clin Pharmacol* 2007; 47: 1119–1128
- Calls Ginesta J, Torras A, Ricart MJ et al. Fibrillary glomerulonephritis and pulmonary hemorrhage in a patient with renal transplantation. *Clin Nephrol* 1995; 43: 180–183
- Soubrier M, Jeannin G, Kemeny JL et al. Organizing pneumonia after rituximab therapy: two cases. *Joint Bone Spine* 2008; 75: 362–365

Received for publication: 22.5.13; Accepted in revised form: 24.6.13