

Short communication

Open Access

## t(8;14;18): A 3-way chromosome translocation in two patients with Burkitt's lymphoma/leukemia

Delong Liu\*<sup>1</sup>, Josif Shimonov<sup>2</sup>, Suneeta Primanneni<sup>1</sup>, Yongrong Lai<sup>1,3</sup>, Tauseef Ahmed<sup>1</sup> and Karen Seiter<sup>1</sup>

Address: <sup>1</sup>Division of Oncology/Hematology, New York Medical College and Westchester Medical Center, Valhalla, NY 10595, USA, <sup>2</sup>Department of Medicine, Richmond University Medical Center, Staten Island, NY 10310, USA and <sup>3</sup>Department of Hematology, First Affiliated University Hospital, Guangxi Medical University, Nanning, Guangxi Province, China

Email: Delong Liu\* - delong\_liu@nyc.edu; Josif Shimonov - ishimunov@msn.com; Suneeta Primanneni - suneeta\_pinna@yahoo.com; Yongrong Lai - yongronglai@hotmail.com; Tauseef Ahmed - hdtrans@gmail.com; Karen Seiter - karen\_seiter@nyc.edu

\* Corresponding author

Published: 4 June 2007

Received: 28 February 2007

Molecular Cancer 2007, 6:35 doi:10.1186/1476-4598-6-35

Accepted: 4 June 2007

This article is available from: <http://www.molecular-cancer.com/content/6/1/35>

© 2007 Liu et al; licensee BioMed Central Ltd.

This is an Open Access article distributed under the terms of the Creative Commons Attribution License (<http://creativecommons.org/licenses/by/2.0>), which permits unrestricted use, distribution, and reproduction in any medium, provided the original work is properly cited.

### Abstract

Burkitt's lymphoma (BL) is a heterogeneous group of highly aggressive mature B-cell malignancies. It is characterized by a high rate of turnover of malignant cells and deregulation of the c-myc gene. It is typically associated with a t(8;14) translocation. Dual translocation of t(8;14) (c-myc) and t(14;18) (bcl-2) was reported to be associated with extremely poor prognosis. This study reports a novel t(8;14;18) triple translocation in two patients with Burkitt's lymphoma.

### Background

Burkitt's lymphoma/leukemia (BL) is a heterogeneous group of highly aggressive mature B-cell malignancies. It is characterized by a high rate of turnover of malignant cells and deregulation of the c-myc gene. The BL tumor cells usually express the B-cell-specific surface markers CD19, CD20, together with surface immunoglobulin (Ig), as well as CD10. The histologic hallmark of BL is the presence of apoptotic cells within scattered macrophages, a feature responsible for the "starry sky" microscopic appearance. A characteristic chromosome translocation associated with this disease typically takes place between chromosome 8q24 (c-myc) and one of the Ig gene-containing chromosomes, 14q32 (Ig H gene), 2p12 (Ig kappa) or 22q11 (Ig lambda). The frequency of such translocation is estimated to be approximately 80% t(8;14), 15% t(2;8), and 5% t(8;22), respectively [1]. We report in this study two cases of BL with a novel three-way chromosome translocation, t(8;14;18).

### Results and discussion

#### Case 1

A 61 year-old Arabic female presented with abdominal pain, weakness and fever in April, 1997. Physical examination was significant for splenomegaly. Her laboratory revealed WBC  $2.7 \times 10^9/L$ , Hgb 107 g/L, platelets  $178 \times 10^9/L$ , and LDH 1250 u/L. CT scan confirmed splenomegaly. Bone marrow was hypercellular with 30% lymphoid blasts. Flowcytometric analysis revealed a B cell population expressing CD19, CD20, CD22, HLA-DR and kappa, but negative for CD5, CD10, CD23, and CD34, and tdt. The chromosome analysis of the bone marrow revealed 47, XX, +7, t(8;14;18) (q24;q32;q22) (Fig. 1). This was consistent with BL by WHO criteria. She was given chemotherapy with cyclophosphamide, doxorubicin, vincristine, and prednisone following the L-20 regimen [2,3]. The patient was in complete remission (CR) and received maintenance chemotherapy. In November, 2002 she felt abdominal pain without any other complaint. Physical

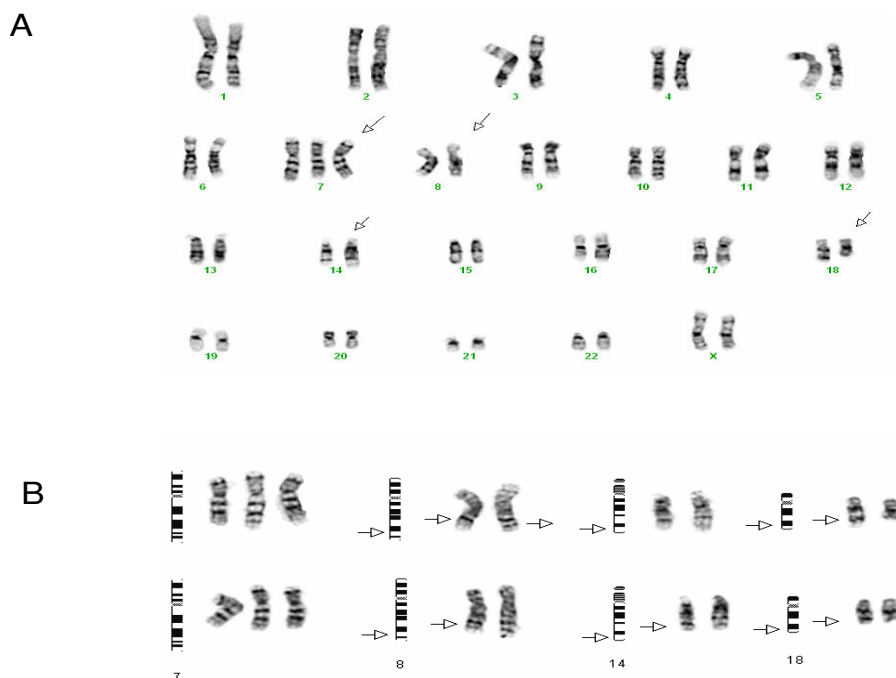
examination was unremarkable. WBC  $4.7 \times 10^9/L$ , Hgb 115 g/L, and platelets  $215 \times 10^9/L$ . CT scan revealed marked intra-abdominal lymphadenopathy. Bone marrow smear and flowcytometric analysis did not show overt involvement by BL, though focal involvement of the bone marrow was demonstrated on immunohistochemical study. The cytogenetic analysis from the bone marrow sample revealed only 46 XX. She was given the intensive chemotherapy with rituxamab plus hyper-CVAD [4]. She also received radiation therapy to the residual mass. She subsequently completed two years of maintenance therapy in August 2005 and has remained in CR at the time of this report.

### Case 2

A 56 year- old Hispanic male went to ER with worsening left sided facial pain with erythema and edema. Physical examination was significant for lymphadenopathy in the neck and inguinal areas as well as splenomegaly. He also had decreased air entry in both lungs and bilateral ankle edema. His CBC revealed WBC  $28.4 \times 10^9/L$ , Hgb 109 g/L, and platelets  $330 \times 10^9/L$ . The chemistry panel was significant for BUN 58 mg/dL, Creatinine 4.7 mg/dL, LDH > 2500 u/L, Uric acid 27.8 mg/dL. CT scan revealed bilateral pleural effusions, splenomegaly, massive matted retro-

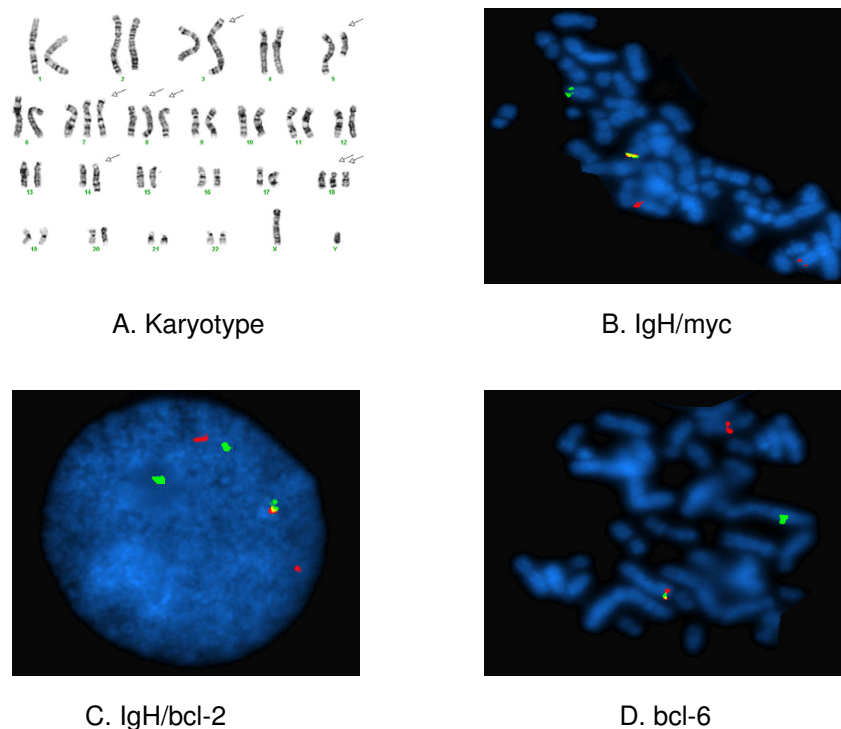
peritoneal lymphadenopathy and bilateral inguinal lymphadenopathy. MRI of the brain showed a 5 cm left pterygoid muscle mass extending into the cavernous sinus and lateral aspect of the orbit. Bone marrow was hypercellular and partially replaced by intermediate to large-sized neoplastic lymphoid cells with cytoplasmic vacuoles. Flowcytometric analysis revealed a B cell population expressing CD19, CD20, CD22, CD10(dim), surface IgG, HLA-DR and CD43, but negative for CD5, CD34, and tdT. The chromosome analysis of the bone marrow revealed 44-49, XY, t(3;5) (q27;q15), t(8;14;18) (q24;q32;q21), +der(8) t(8;14;18), +der(18) t(8;14;18) (Fig. 2). FISH study was positive for gene rearrangement of bcl-6, and fusions of myc, IgH, and bcl-2 (Fig. 2). This was consistent with BL. He received hemodialysis for his acute renal failure. He was given the intensive chemotherapy with rituximab plus hyper- CVAD. His lymphadenopathy resolved on examination. His renal function returned to normal quickly, and his blood counts returned to normal range upon discharge from the hospital.

This study identified two cases of BL with this novel t(8;14;18) triple translocation from one institution over 10 years. The first patient relapsed five and a half years after initial diagnosis, but her disease remained to be



### Figure 1

Cytogenetic abnormalities in case 1. (A). Karyotype 47, XX, +7, t(8;14;18) (q24;q32;q22). Arrows indicate abnormal chromosomes. (B). Diagrammatic representation of +7 and 3-way chromosome translocations. Arrows indicated abnormal chromosome regions involved in the 3-way translocation.



**Figure 2**

Cytogenetic abnormalities in case 2. (A). Karyotype 44–49, XY, t(3;5) (q27;q15), t(8;14;18) (q24;q32;q21), +der(8) t(8;14;18), +der(18) t(8;14;18). Arrows indicate abnormal chromosomes. (B) IgH/myc gene fusion. (C). IgH/bcl-2 gene fusion. (D). bcl-6 gene rearrangement.

chemo-sensitive. Gene locus translocations of myc, IgH, and bcl-2 were confirmed by FISH analysis in the second case. After extensive literature search and review, we believe this is the first report of t(8;14;18) triple translocation associated with clinical cases (Table 1). A review of a large cytogenetic database from 1350 leukemia and lymphoma karyotypes disclosed eight cases with karyotypes

of t(8;14) and t(14;18) involving 3-way recombinations of MYC-IGH-BCL2 [5]. Interestingly, 3-way recombinations of MYC-IGH-BCL2 were demonstrated by multicolor FISH and locus-specific FISH analysis [5]. It is therefore possible that the 3-way recombinations of MYC-IGH-BCL2 may take place more often than it is reported, since the multicolor FISH and locus-specific FISH are not

**Table 1: 3-way translocations associated with Burkitt's lymphoma/leukemia**

| Author           | Karyotype   | *Genes | Source    | Reference |
|------------------|-------------|--------|-----------|-----------|
| Ooteghem, 1994   | t(8;14;18)  | bcl-2  | cell line | 6         |
| Dyer, 1996       | t(8;14;18)  | NR     | cell line | 7         |
| Zimonjic, 2001   | t(8;14;18)  | NR     | cell line | 8         |
|                  | t(7;8;14)   | NR     | cell line | 8         |
| Zani, 1996       | t(8;14;12)  | bcl-7a | cell line | 13        |
| Macpherson, 1999 | t(1;8;22)   | NR     | patient   | 9         |
|                  | t(1;14;18)  | NR     | patient   | 9         |
|                  | t(12;14;18) | NR     | patient   | 9         |
| Liu, 2007        | t(8;14;18)  | NR     | patient   | TR        |
|                  | t(8;14;18)  | bcl-2  | patient   | TR        |

\*genes: gene mutation in addition to c-myc. NR: not reported. TR: this report

routinely done. It appears nonetheless that this 3-way chromosome translocation is an extremely rare genetic event occurring in clinical cases. There have been three separate reports of t(8;14;18) 3-way translocation that were found in BL cell lines [6-8]. Dual translocations of t(8;14) and t(14;18) involving c-myc and bcl-2 have been reported in Burkitt-like lymphoma patients [9-12]. 13 such patients with the dual translocation were found to have rapid clinical course and extremely poor prognosis [9]. None of the 13 patients survived past 7 months. Three cases of non-Burkitt lymphoma in the same report had triple translocations of t(1;8;22), t(1;14;18), and t(12;14;18), respectively [9]. t(7;8;14) was found in BL cell line, CA46 [8]. In another cell line of BL, a novel gene, bcl7a, from the triple translocation t(8;14;12) was identified [13]. c-myc translocation can also be seen in diffuse large B-cell lymphoma (DLBCL). DLBCL with c-myc translocation can be difficult to reliably differentiate from BL by currently available diagnostic tools [14]. Through gene expression profiling, eight cases of pathologically-diagnosed DLBCL and one case of high-grade lymphoma were reclassified as BL. These nine cases all expressed c-myc, bcl-2, and had high Ki-67 scores [14]. It is crucial to distinguish between DLBCL and BL, since the overall survival of those BL patients who were treated with intensive regimens were superior to those who received CHOP-like regimens [14]. Regardless of pathological diagnosis of BL or Burkitt-like lymphoma, it seems that poor-prognostic patients with dual and triple translocations involving c-myc and bcl-2 should receive intensive chemotherapy [2,3]. It is unclear whether hematopoietic stem cell transplantation plays any role in the therapy of BL with complex chromosome translocations [15-18].

### Abbreviations

BL: Burkitt's lymphoma/leukemia; FISH: fluorescent in situ hybridization; CHOP: cyclophosphamide, adriamycin, vincristine, prednisone.

### Competing interests

The author(s) declare that they have no competing interests.

### Authors' contributions

DL, KS conceived the study. DL, JS and SP collected data. DL, JS, SP, YL, TA and KS coordinated the design. DL drafted the final manuscript.

### Acknowledgements

This work was partially supported by New York Medical College Blood Disease Fund. Yongrong Lai received a scholarship from the Guangxi Scholarship Fund, Guangxi Province, China. We wish to thank Chitra Kumar, Thomas Matthews, William Kirkland and Wojciech Gorczyca for assistance in preparation of the figures.

### References

1. Hecht JL, Aster JC: **Molecular Biology of Burkitt's Lymphoma.** *J Clin Oncol* 2000, **18**:3707-3721.
2. Weiss M, Maslak P, Feldman E, Berman E, Bertino J, Gee T, Megherian L, Seiter K, Scheinberg D, Golde D: **Cytarabine with high-dose mitoxantrone induces rapid complete remissions in adult acute lymphoblastic leukemia without the use of vincristine or prednisone.** *J Clin Oncol* 1996, **14**:2480-2485.
3. Blum KA, Lozanski G, Byrd JC: **Adult Burkitt leukemia and lymphoma.** *Blood* 2004, **104**:3009-3020.
4. Thomas DA, Cortes J, O'Brien S, Pierce S, Faderl S, Albitar M, et al.: **Hyper-CVAD Program in Burkitt's-Type Adult Acute Lymphoblastic Leukemia.** *J Clin Oncol* 1999, **17**:2461-2470.
5. Knezevich S, Ludkovski O, Salski C, Lestou V, Chhanabhai M, Lam W, Klasa R, Connors JM, Dyer MJS, Gascoyne RD, Horsman DE: **Concurrent translocation of BCL2 and MYC with a single immunoglobulin locus in high-grade B-cell lymphomas.** *Leukemia* 2005, **19**:659-663.
6. Van Ooteghem RB, Smit EM, Beishuizen A, Lambrechts AC, Blij-Philippens M, Smilde TJ, Hagemeijer J: **A new B-cell line showing a complex translocation (8;14;18) and BCL2 rearrangement.** *Cancer Genet Cytogenet* 1994, **74**:87-94.
7. Dyer MJ, Lillington DM, Bastard C, Tilly H, Lens D, Heward JM, Stranks G, Morilla R, Monard S, Guglielmi P, Kluin-Nelemans JC, Hagemeijer A, Young BD, Catovsky D: **Concurrent activation of MYC and BCL2 in B cell non-Hodgkin lymphoma cell lines by translocation of both oncogenes to the same immunoglobulin heavy chain locus.** *Leukemia* 1996, **10**:1198-1208.
8. Zimonjic DB, Keck-Waggoner C, Popescu NC: **Novel genomic imbalances and chromosome translocations involving c-myc gene in Burkitt's lymphoma.** *Leukemia* 2001, **15**:1582-1588.
9. Macpherson N, Lesack D, Klasa R, Horsman D, Connors JM, Barnett M, Gascoyne RD: **Small Noncleaved, Non-Burkitt's (Burkitt-Like) Lymphoma: Cytogenetics Predict Outcome and Reflect Clinical Presentation.** *J Clin Oncol* 1999, **17**:1558-1567.
10. Thangavelu M, Olopade O, Beckman E, Vardiman JW, Larson RA, McKeithan TW, Le Beau MM, Rowley JD: **Clinical, Morphologic, cytogenetic characteristics of patients with lymphoid malignancies characterized by both t(14;18)(q32;q21) and t(8;14)(q24;q32) or t(8;22)(q24;q11).** *Genes Chromosomes Cancer* 1990, **2**:147-158.
11. Karan A, Gascoyne RD, Coupland RW, Shepherd JD, Phillips GL, Horsman DE: **Combination of t(14;18) and Burkitt's type translocation in B-cell malignancies.** *Leuk Lymphoma* 1991, **10**:433-44.
12. Brito-Babapule V, Crawford A, Khokhar T, Laffan M, Matutes E, Fairhead S, Catovsky D: **Translocations t(14;18) and t(8;14) with rearranged bcl-2 and c-myc in a case presenting as B-ALL (L3).** *Leukemia* 1991, **5**:83-87.
13. Zani VJ, Asou N, Jadayel D, Heward JM, Shipley J, Nacheva E, Takasaki K, Catovsky D, Dyer MJS: **Molecular cloning of complex chromosomal translocation t(8;14;12)(q24.1;q32.3;q24.1) in a Burkitt lymphoma cell line defines a new gene (BCL7A) with homology to caldesmon.** *Blood* 1996, **87**:3124-3134.
14. Dave SS, Fu K, Wright GW, Lam LT, Kluin P, Boerma E-J, Greiner TC, Weisenburger DD, Rosenwald A, Ott G, Muller-Hermelink H, Gascoyne RD, Delabie J, Rimsza LM, Braziel RM, Grogan TM, Caspo E, Jaffe ES, Dave BJ, Sanger W, Bast M, Vose JM, Armitage JO, Connors JM, Smeland EB, Kvaloy S, Holte H, Fisher RI, Miller TP, Montserrat E, Wilson WH, Bahl M, Zhao H, Yang L, Powell J, Simon R, Chan WC, Staudt LM: **Molecular diagnosis of Burkitt's lymphoma.** *N Engl J Med* 2006, **354**:2431-2442.
15. Sweetenham JW, Pearce R, Taghipour G, Blaise D, Gisselbrecht C, Goldstone AH: **Adult Burkitt's and Burkitt-like non-Hodgkin's lymphoma - outcome for patients treated with high-dose therapy and autologous stem-cell transplantation in first remission or at relapse: results from the European Group for Blood and Marrow Transplantation.** *JCO* 1996, **14**:2465-2472.
16. Ungkanont A, Mongkongsritrakoon W, Jootar S, Srichaikul T: **Allogeneic stem cell transplantation in a patient with refractory Burkitt's lymphoma using non-myceloablative conditioning regimen.** *Bone Marrow Transplant* 2000, **26**:1351-1354.
17. Grigg A, Seymour J: **Graft versus Burkitt's lymphoma effect after allogeneic marrow transplantation.** *Leuk Lymphoma* 2002, **43**:889-892.

18. Liu D, Seiter K, Chiao JW, Shi Q, Qureshi A, Jeong W, Nelson J, Ahmed T: **Mitoxantrone, AraC, and Pentostatin (MAP regimen): phase I study of a novel non-myeloablative conditioning regimen for hematological malignancies.** *Int J Cancer Research* 2006, **2**:131-142.

Publish with **BioMed Central** and every scientist can read your work free of charge

*"BioMed Central will be the most significant development for disseminating the results of biomedical research in our lifetime."*

Sir Paul Nurse, Cancer Research UK

Your research papers will be:

- available free of charge to the entire biomedical community
- peer reviewed and published immediately upon acceptance
- cited in PubMed and archived on PubMed Central
- yours — you keep the copyright

Submit your manuscript here:  
[http://www.biomedcentral.com/info/publishing\\_adv.asp](http://www.biomedcentral.com/info/publishing_adv.asp)

