



The Quad Link Technique for an All-Soft-Tissue Quadriceps Graft in Minimally Invasive, All-Inside Anterior Cruciate Ligament Reconstruction

Gregory R. Sprowls, M.D., and Brett N. Robin, M.D.

Abstract: The quadriceps tendon autograft has become an attractive option for anterior cruciate ligament reconstruction (ACLR) because of its robust size and versatility as a graft. Emerging literature has shown impressive biomechanical viability and promising clinical outcomes. The substantial size of a quadriceps graft and the shorter graft requirement of the all-inside approach obviate the need to harvest a bone plug for supplemental graft length and allow the use of an all-soft-tissue graft. The recent development of sophisticated harvest tools has mitigated prior issues reported with quadriceps tendon harvest. Quadriceps graft harvest is now less technically challenging, more reproducible, and can be done through a minimally invasive incision. However, an optimal technique for attachment of the adjustable loop suspensory fixation devices to an all-soft-tissue quadriceps tendon graft has yet to be established. We describe our method for quadriceps tendon harvest and present the Quad Link technique for attachment of adjustable loop suspensory fixation devices to a quadriceps graft for ACLR.

Modern techniques for anterior cruciate ligament reconstruction (ACLR) are continually evolving and currently there are multiple options for graft source and preparation technique. Many factors must be considered when choosing a graft source. These include patient-specific concerns including age, sex, activity level, and expectations regarding scar cosmesis, as well as graft-specific considerations like availability, surgeon preference, level of technical difficulty associated with particular grafts, and graft-associated complications.^{1,2}

The quadriceps tendon autograft is a unique option for ACLR because of its robust size and versatility as a

graft. Staubli et al. reported a mean cross-sectional area of 64.6 mm, compared to 36.8 mm for the patellar tendon.³ Lippe et al. reported a mean maximum length of 88.3 ± 8.4 mm.⁴ An abundant cross-sectional area makes doubling or quadrupling the graft unnecessary, and the quadriceps tendon's average length consistently surpasses the 70 mm that is required for the all-inside technique for ACLR.⁴⁻⁶ With reliable graft size and the use of an all-inside technique, there is no need to violate the patella for added graft length, as is done with bone-tendon graft constructs. This decreases harvest morbidity and risk of patella fracture.

Suspensory fixation of an all-soft-tissue quadriceps graft in the knee is best achieved using the Graft Link all-inside technique, initially described for a hamstring autograft.^{7,8} However, a preferred method for graft preparation and adjustable loop suspensory device fixation to a quadriceps tendon graft in minimally invasive, all-inside ACLR has yet to be identified. Crall and Gilmer have previously described their method for all-soft-tissue quadriceps graft preparation, but this involves splitting the tendon between the rectus femoris and vastus intermedius layers.⁸

We describe our method for quadriceps tendon harvest and present the Quad Link technique for adjustable loop suspensory device fixation to a quadriceps graft in ACLR, without splitting the tendon.

From the Department of Orthopaedic Surgery, Baylor Scott and White Health, Temple, Texas; and College of Medicine, Texas A&M Health Science Center, Temple, Texas, U.S.A.

The authors report that they have no conflicts of interest in the authorship and publication of this article. Full ICMJE author disclosure forms are available for this article online, as [supplementary material](#).

Received February 21, 2018; accepted April 12, 2018.

Address correspondence to Gregory R. Sprowls, M.D., Baylor Scott & White Health, Department of Orthopedics, 2401 South 31st Street, Temple, TX 76508, U.S.A. E-mail: gregory.sprowls@bswhealth.org

© 2018 by the Arthroscopy Association of North America. Published by Elsevier. This is an open access article under the CC BY-NC-ND license (<http://creativecommons.org/licenses/by-nc-nd/4.0/>).

2212-6287/18245

<https://doi.org/10.1016/j.eats.2018.04.004>

Surgical Technique

Preoperative

Quadriceps tendon length and thickness are routinely measured preoperatively from the sagittal magnetic resonance imaging image. A tourniquet is applied to the thigh. The knee is left in flexion and a lateral post is used.

Graft Harvest

The proximal pole of the patella and approximate distal extent of the vastus medialis oblique are outlined on the skin (Video 1). A longitudinal line is made from the edge of the proximal pole of the patella, at its midpoint, and extended proximally 2 to 3 cm. Diagnostic arthroscopy is performed prior to graft harvest using standard anteromedial and anterolateral portals to confirm the ACL disruption and to address associated pathology. An incision is then made using the aforementioned longitudinal line. Excess subcutaneous fat directly over the quadriceps tendon is excised. Subcutaneous tissue and the paratenon are cleared away from the underlying quadriceps using a ray-tec sponge (Johnson & Johnson, New Brunswick, NJ) and Metzzenbaum scissors. The distal quadriceps tendon and vastus medialis oblique muscle are identified. Manipulation of the retractors at the proximal aspect of the incision allows for adequate visualization of the proximal quadriceps tendon.

A quad tendon graft harvester (Arthrex, Naples, FL) is then used in a manner consistent with its technique guide (Fig 1A).⁹ Centering the graft harvester just lateral to the midpoint of the patella ensures that the 9- to 10-mm-wide graft is obtained from the longest portion of the asymmetric quadriceps tendon.⁴ An initial score of the quadriceps tendon is made with the harvester, centered in the tendon's coronal plane, beginning approximately 3 cm proximal to the proximal pole of the patella. The harvester is started at the midpoint of the graft to ensure that it does not deviate too far medial or lateral, causing the graft to be too short. The dual blades of the harvester are pressed into the tendon to the full 5 mm depth of the harvester, with the adjustable width between the blades set at 9, 10, or 11 mm, depending on surgeon preference. If the sagittal thickness of the tendon is noted to be less than 5 mm on preoperative magnetic resonance imaging, a wider graft is excised to compensate for this, by widening the cutting guide blades to the maximum 11-mm setting. When choosing a wider, more shallow graft in these instances, the harvester is not fully pressed into the tendon to avoid violating the suprapatellar pouch. The initial 1-cm-long score is then continued 3 cm distally and 3 cm proximally, completing a 7-cm score of the tendon from the proximal pole of the patella. The tendon is cut using a back and forth technique aligned

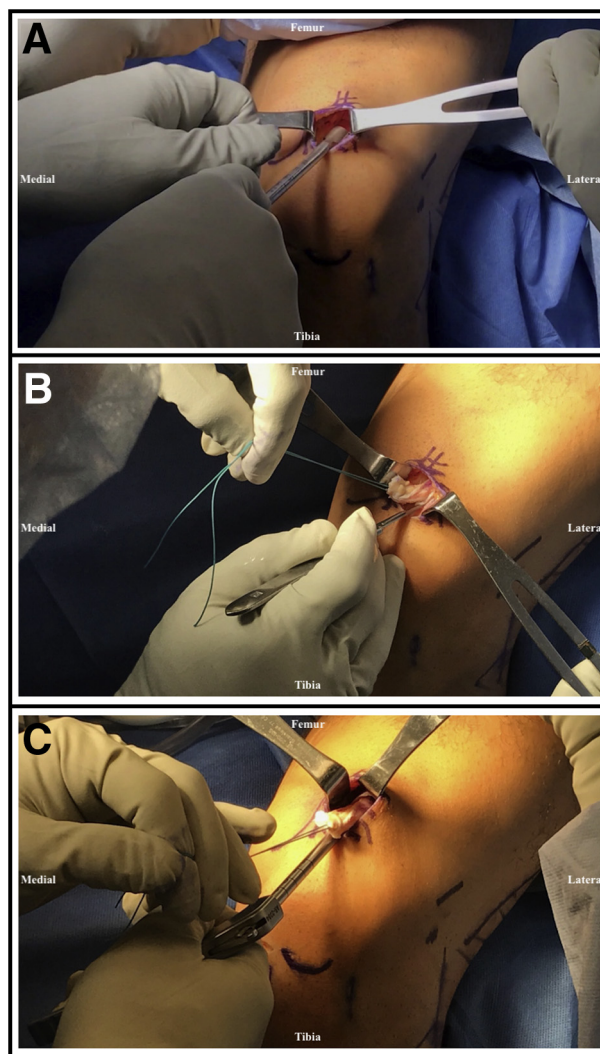


Fig 1. Patient in the supine position with left knee in flexion and a lateral post used. (A) After properly exposing the distal extent of the quadriceps tendon and the proximal pole of the patella, the quad tendon graft harvester (Arthrex) is used to score the tendon starting from 3 cm proximal to the proximal pole of the patella. This initial 1-cm-long score is then continued 3 cm distally and 3 cm proximally, completing a 7-cm score of the tendon from the proximal pole of the patella. (B) The distal quadriceps tendon is excised from its insertion on the patella using a No. 15 blade knife, taking care not to extend outside the medial and lateral bounds of the initial tendon score. A No. 1 Ethibond suture is whip-stitched through the free portion of the tendon to create a traction suture. The excision is continued to the proximalmost extent of our initial cutting guide score. It is important to maintain a consistent depth of excision during this process. (C) The quad tendon cutter (Arthrex) is used in line with the valgus anatomic axis of the femur until a 7-cm segment of the tendon is free, using the measuring guide on the handle as a reference. The tendon is then cut by releasing the safety handle and pulling the trigger.

with the valgus anatomic axis of the femur, taking care to remain at the 5mm depth at all times. The markings

on the harvester instrument handle are used to ensure proper graft length.

The exposure is then centered over the tendon's patellar insertion using distal retraction with the army-navy retractors. A No. 15 blade knife is used to excise the distal end of the quadriceps tendon from the patella, taking care not to extend outside the medial and lateral bounds of the initial tendon score. Once the distal tendon is detached from the patella, a No. 1 Ethibond (Ethicon, Somerville, NJ) suture is whip-stitched with 3 throws through the free portion of the tendon to create a traction suture. The tendon can then be manipulated using this traction suture in the succeeding steps. The excision is continued to the proximalmost extent of our initial cutting guide score using a No. 15 blade knife (Fig 1B). It is vital to maintain the initial depth of excision created by the cutting guide during this step to successfully harvest a partial-thickness graft.

The distal portion of the tendon is then inserted through a quad tendon cutter (Arthrex). This is also referred to as a "cigar cutter." The quad tendon cutter is used according to its technique guide.⁹ The tendon is tensioned manually using the traction suture, and steady force is applied to the quad tendon cutter in line with the valgus femoral anatomic axis (Fig 1C). It is crucial to ensure that the safety handle is not released prematurely during this step. The tendon is then dissected until a 7-cm segment of the tendon is free, as measured by the markings on the quad tendon cutter shaft. The quad tendon cutter will not strip the graft proximally because of the thickness of the graft, thus emphasizing the importance of releasing this portion of the tendon with sharp dissection before using the cutter. Finally, the tendon is cut by releasing the safety handle and pulling the trigger when the graft has reached 7 cm.

If a partial-thickness graft is achieved and the underlying vastus intermedius is identified, no closure of the soft tissue defect is necessary. However, if the suprapatellar pouch is violated, it should be repaired using No. 0 Vicryl (Ethicon, Somerville, NJ). Suprapatellar pouch integrity can be assessed by filling the joint with the arthroscopic fluid and examining for leaks at the harvest site. A moist ray-tech sponge is placed in the incision while attention is turned to the following steps.

Graft Preparation

The graft is brought to the back table. An Allis clamp is secured to the nonsutured end of the graft. Measuring with a ruler, the graft is marked with a marking pen 20 mm from each end of the graft. This should result in approximately 30 mm of graft between the 2 lines (Fig 2A). These 2 lines will serve as the starting points for fixation of each adjustable loop suspensory fixation device. The end of the graft formerly

attached to the patella will become the femoral end of the graft, prepared with 1 adjustable loop device (Arthrex TightRope Reverse Tensioning [RT]), and the former proximal end will serve as the tibial end, prepared with another adjustable loop device (Arthrex TightRope Attachable Button System [ABS]).

To prepare the tibial side, first thread the free ends of a heavy nonabsorbable suture (FiberTape; Arthrex) through a free Keith needle. It is preferable to use the smallest-caliber needle to maintain maximum graft integrity. Dilation of the eye of the Keith needle may be necessary to accommodate both ends of the free suture. Dilation can be done with the tip of a forceps. The needle is first inserted from the superior surface of the graft at the premarked line, 20 mm from the end of the graft, through the midsubstance of the tendon (Fig 2B). The free suture is pulled through the graft, leaving a loop of about 2 cm on the superior surface of the graft. The needle is then brought back through the inferior surface of the graft 2 mm proximal to the initial entry point, leaving a 2-cm loop on the inferior surface of the graft (Fig 2C). The Keith needle is removed. The middle of the adjustable loop device (TightRope ABS) is laid over the superior surface of the graft, oriented perpendicular to the graft's long axis, between the base of the superior free suture loop and the free suture ends (Fig 2D). The free ends are then brought through the loop, creating a cinch knot to secure the apex of the adjustable loop device to the superior surface of the graft (Fig 2E). The free suture cinch loop is first tightened by pulling the inferior loop, and then the inferior slack is tightened by pulling the free ends superiorly (Fig 2F).

The free suture limb nearest the surgeon is then threaded through the Keith needle in preparation to be whip-stitched over the ipsilateral adjustable loop limb. The needle is inserted through the inferior surface of the graft, about 4 to 5 mm distal to the adjustable loop apex in the midsubstance of the tendon, making a loop around the ipsilateral adjustable loop limb (Fig 3A). The needle is brought through this loop to lock the free suture over the adjustable loop limb. The needle is then brought through the graft again in the same fashion, continuing with 4- to 5-mm incremental whip-stitches (Fig 3B). It is not necessary to lock the whip-stitches after the first throw. Three to 4 whip-stitches are sufficient to tubularize the end of the graft (Fig 3C). This process is then repeated on the side of the graft furthest from the surgeon, using the other free suture limb (Fig 3D).

The other adjustable loop device (TightRope RT), is then fixed to the femoral end of the graft with an additional heavy nonabsorbable free suture (FiberTape) using the same method described in the previous steps (Fig 3 E and F). The free ends of the free suture are placed through the button on the adjustable loop

device, if the device contains a button, after tubularization of each side is complete. The Ethibond traction suture placed during harvest is cut at its base, as it is no longer needed.

The graft is then passed through the sizing block to determine the appropriate tunnel size. The ends of the graft can be trimmed if necessary to achieve sufficient tubularization. An additional line is then marked at the center of the graft (3.5 cm from each end). This will serve as an arthroscopic indicator for proper graft placement. The graft is then left on 20 N

of tension on the graft board while the sockets are prepared.

Arthroscopy

Standard anatomic sockets are retrodrilled at the femoral and tibial footprints with a retrodrill (FlipCutter; Arthrex), as previously described in the Graft Link all-inside technique.⁷ The femoral socket is reamed first, creating a socket that is at least 5 to 10 mm deeper than the length of the intraosseous portion of the graft end (25-30 mm deep for a 7-cm graft) (Fig 4 A and B).

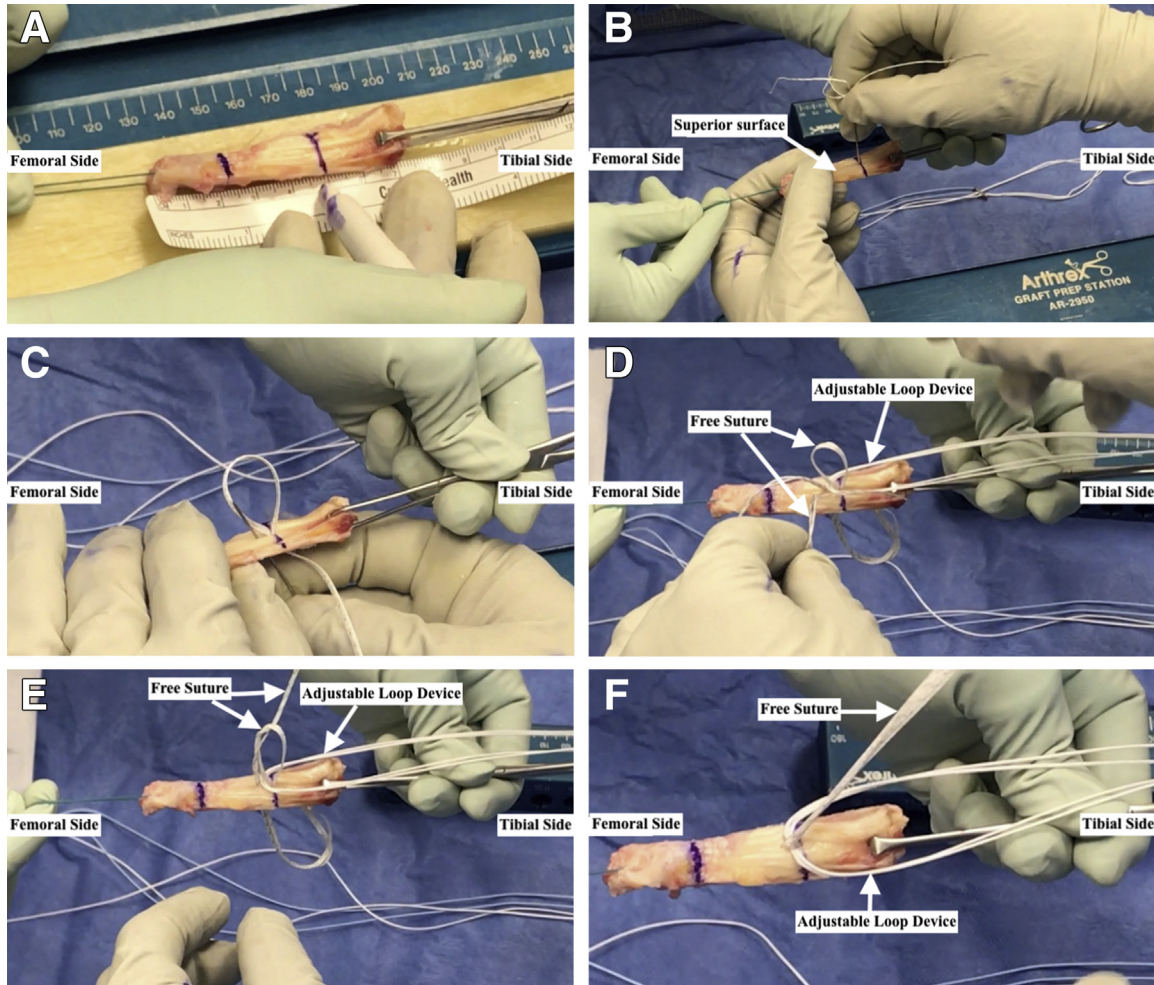


Fig 2. The graft is prepared on the back table. (A) The starting points for fixation of the adjustable loop devices to the graft are marked 20 mm from each end, resulting in 30 mm of graft between the 2 lines. The end of the graft formerly attached to the patella will become the femoral end of the graft, prepared with 1 adjustable loop device (Arthrex TightRope Reverse Tensioning [RT]), and the former proximal end will serve as the tibial end, prepared with another adjustable loop device (Arthrex TightRope Attachable Button System [ABS]). (B) A Keith needle, threaded with a heavy nonabsorbable suture (FiberTape; Arthrex), is inserted from the superior surface of the graft at the premarked line, through the midsubstance of the tendon. It is preferable to use the smallest-caliber Keith needle to maintain maximum graft integrity. (C) After the initial 2 cm loop is made on the superior surface of the graft, the needle is brought back through the inferior surface of the graft 2 mm proximal to the initial entry point, leaving a 2-cm loop on the inferior surface of the graft. (D) The middle of the adjustable loop device (TightRope ABS) is laid over the graft, oriented perpendicular to the graft's long axis, between the base of the superior free suture loop and the free suture ends. (E) The free ends are brought through the loop, creating a cinch knot to secure the apex of the adjustable loop device to the superior surface of the graft. (F) View of the graft after tightening the superior and inferior aspects of the cinch loop over the adjustable loop device.

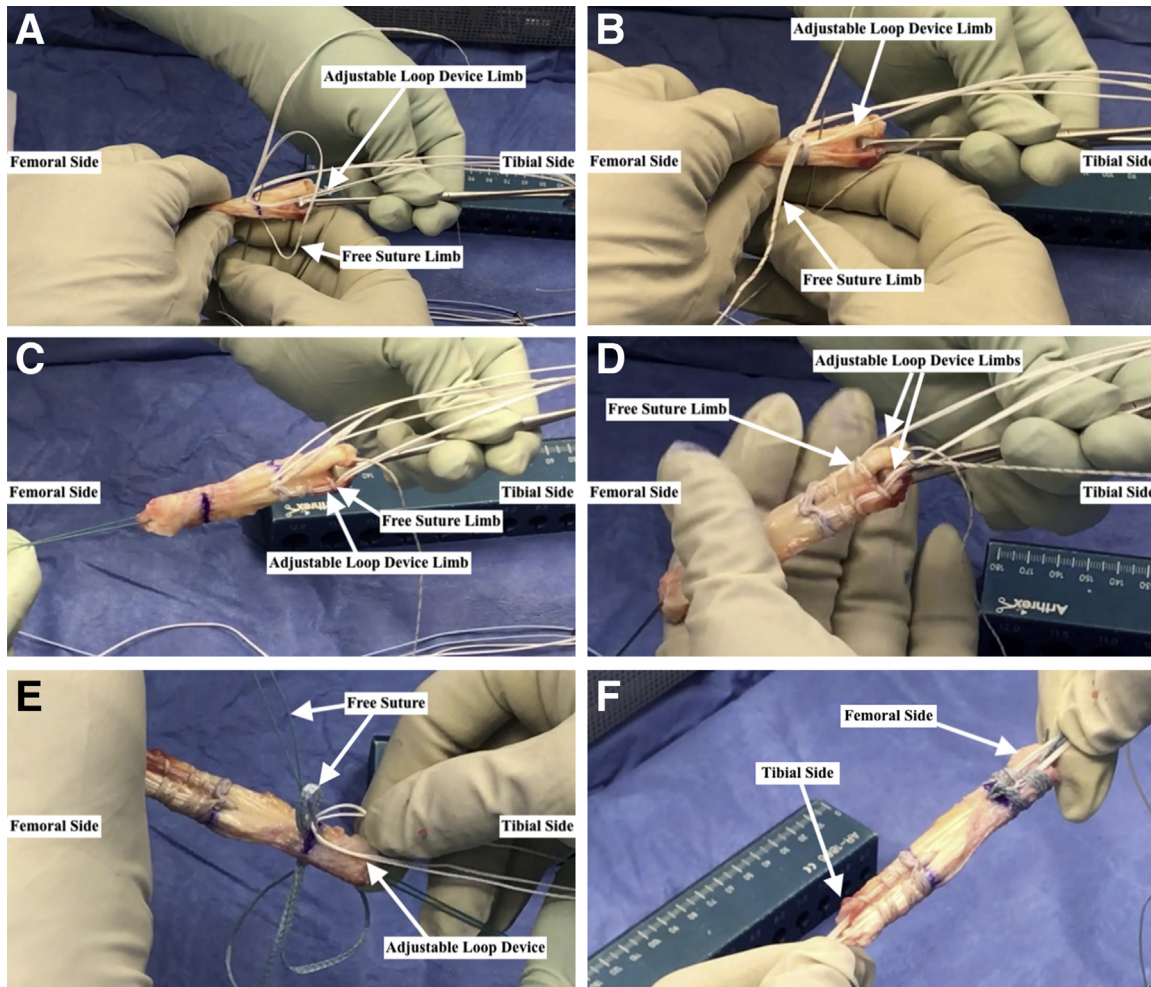


Fig 3. The graft is prepared on the back table. (A) The free suture limb nearest the surgeon is whip-stitched over the ipsilateral adjustable loop limb. The needle is brought through the inferior surface of the graft, 4-5 mm distal to the apex of the adjustable loop device to make a loop around the adjustable loop limb. The first whip-stitch is locked over the adjustable loop limb. (B) The needle is then brought through the graft again in the same fashion for a total of 3 to 4 whip-stitches in 4- to 5-mm increments. These are nonlocking whip-stitches. (C) Completed fixation of 1 adjustable loop limb. (D) Completed fixation of both adjustable loop limbs. (E) The other adjustable loop device (Arthrex TightRope Reverse Tensioning [RT]) is then fixed to the femoral end of the graft with an additional free suture (FiberTape; Arthrex) using the same method described in the previous steps. (F) Completed fixation of both adjustable loop devices to the tibial and femoral ends of the graft, using the Quad Link Technique. An additional line is then marked at the center of the graft (3.5 cm from each end). This will serve as an arthroscopic indicator for proper graft placement in the knee.

A socket depth that is too shallow relative to the length of the graft end will cause the ends to bottom out in the sockets and allow for an intra-articular graft length in excess of the recommended 3 cm. This can prevent proper tensioning of the graft and lead to residual laxity postoperatively. A free suture (FiberStick; Arthrex) is then passed from the femoral socket to the anterolateral portal and is docked (Fig 4C). The tibial socket is drilled and reamed in the same manner (Fig 4D) and prepared with another free suture (TigerStick; Arthrex) from the tibial socket to the anteromedial portal. The apex of the femoral socket free suture is then brought back into the knee from the anterolateral portal, passed through the anteromedial portal, and is docked.

A tunnel dilator at least the size of the graft is used to dilate the anteromedial portal. This ensures that the portal is large enough for the graft to pass. The femoral adjustable loop suspensory fixation device is then passed from the anteromedial portal to the femoral socket using the femoral socket free suture as a shuttle, under arthroscopic visualization from the anterolateral portal (Fig 4 E and F). The femoral end of the graft is brought into the femoral socket but not seated completely. A shuttling suture is threaded through the apex of the tibial adjustable loop-tensioning strands. The shuttling suture ends are brought through the tibial socket free suture. The tibial adjustable loop device is then brought through the tibial socket by pulling the

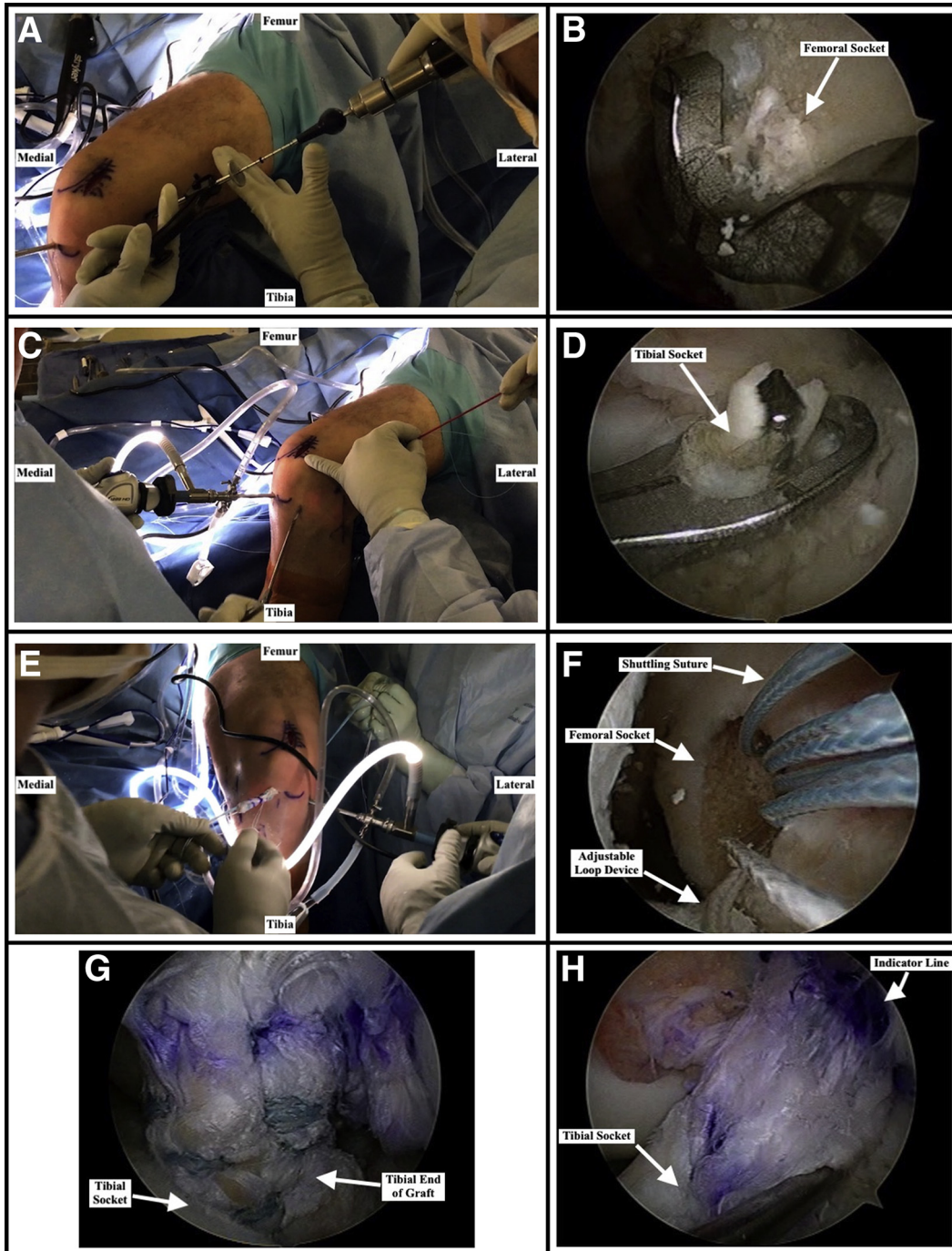


Fig 4. Patient in the supine position with left knee in flexion and a lateral post used. (A) A standard anatomic femoral socket is drilled using a retrodrill (FlipCutter; Arthrex), ensuring a socket at least 5-10 mm deeper than the length of the intraosseous portion of the graft end (25-30 mm deep for a 7-cm graft) is achieved to prevent graft laxity. (B) Arthroscopic view from the anteromedial portal of the femoral socket being drilled with the retrodrill. (C) A free suture (FiberStick; Arthrex) is passed from the femoral socket to the anterolateral portal and is docked. (D) A standard anatomic tibial socket is drilled using the retrodrill, under arthroscopic observation from the anterolateral portal. Again, it is important to ensure the socket is drilled at least 5-10 mm deeper than the length of the intraosseous portion of the graft end to prevent graft laxity. (E) The femoral adjustable loop device is passed from the anteromedial portal to the femoral socket using the femoral socket free suture as a shuttle, under arthroscopic visualization from the anterolateral portal. The femoral end of the graft is brought into the femoral socket but not seated completely. (F) Arthroscopic view from the anterolateral portal of the femoral adjustable loop device being brought into the femoral socket. (G) Arthroscopic view from the anterolateral portal of the tibial end of the graft being brought into the tibial socket, prior to being completely seated within the socket. (H) Arthroscopic view from the anterolateral portal of the final graft position prior to the tibial button being tied, the knee being ranged, and the femoral button being secured. The tibial socket is located at the inferior aspect of the image. The line drawn at the middle of the graft during the graft preparation stage (3.5 cm from the ends) is located at the superior aspect of the image. This line serves as an indicator that the graft is approximately centered in the knee.

tibial socket free suture out of the knee through the tibial socket (Fig 4G). The tibial end of the graft is seated into the tibial socket under direct arthroscopic visualization.

Graft Tensioning

The positions of the previously drawn graft markings, to the middle and both ends of the graft, are checked arthroscopically using a probe (Fig 4H). Once in a satisfactory position, a tibial button (TightRope ABS) is placed, tightened, and tied. The knee is then brought through a full range of motion for approximately 20 cycles, after which the femoral adjustable loop device (TightRope RT femoral button) is retensioned with the knee in full extension and tied. The free sutures (FiberTape) used to attach the adjustable loop devices to the graft are also tied over the buttons, creating dual fixation of both graft ends. The ends of both the adjustable loop devices and the free sutures are cut, and the incisions are closed in a manner of the surgeon's choosing.

Discussion

The quadriceps tendon as a graft for ACLR is not a new entity. Similar increases in its popularity have recurred about every decade since the technique's introduction in 1979 by Marshall et al.^{10,11} In the past, however, it has not sustained popularity as a primary graft source because of the size of incision once required for harvest, a belief that it had less tensile strength than other grafts, an overall lack of morphometric and outcome-based studies, and a learning curve associated with the procedure.^{10,12,13}

Recent advances in surgical instrumentation for graft harvest, particularly quadriceps-specific harvesters and cutters (Arthrex), now allow for a minimally invasive approach requiring an incision as small as 1.5 to 2 cm.^{5,13} Cadaveric and magnetic resonance imaging studies have better characterized the anatomic dimensions of the quadriceps tendon, allowing for a more reliable harvest.^{3,12} Lippe et al. found the tendon to consistently have more length and depth just lateral to midline.⁴ They suggest harvesting in this plane to obtain the desired graft dimensions.⁴

Although these advances in surgical instrumentation have made the graft harvest process less difficult, an initial learning curve exists. The anatomy of the quadriceps tendon can be highly variable between individuals with regard to both length and depth. The surgeon must take into account the valgus nature of the quadriceps tendon when harvesting to avoid inadvertently injuring the surrounding musculature. When using the quad tendon graft harvester (Arthrex), the joint capsule can be penetrated if the tendon is cut with excessive force. In addition, maintaining an even depth of graft excision with the No. 15 blade and the quad

tendon cutter (Arthrex) can be difficult, potentially resulting in areas of variable thickness of the graft.

Anatomic studies have highlighted the substantial size of the quadriceps tendon and identified a similar collagen fibril orientation to that of ligamentous tissue, with a bimodal pattern of alternating small- and large-diameter fibrils found on electron microscopy.^{3,4,14} This translates to a graft that closely resembles the native ACL both grossly and microscopically. Additionally, a biomechanical comparison between grafts from Harris and colleagues determined that the quadriceps tendon trended toward greater strength to failure measures than the patellar tendon.¹²

A current limitation of the all-inside ACLR technique using an all-soft-tissue quadriceps graft is the paucity of studies confirming acceptable outcomes for this specific technique. The only available outcome data for an all-soft-tissue quadriceps graft, to our knowledge, comes from Schulz et al., in a study of 55 patients in which graft fixation was accomplished using bioabsorbable cross-pins.⁶ They found satisfactory results using a variety of functional scoring systems at 24 to 36 months. In most existing outcome studies for quadriceps tendon ACLR, the grafts were harvested with a patellar bone plug. These studies suggest comparable functional outcomes to that of patellar bone–tendon–bone and hamstring autografts^{14–18} with better preservation of the extensor mechanism¹⁵ and less incidence of anterior knee pain.^{6,14} An all-soft-tissue quadriceps tendon graft avoids the potential morbidity associated with patellar block harvesting for a patellar bone–tendon–bone construct. Doubling or quadrupling the tendon, as is done with hamstring autografts, is unnecessary because of the robust size of a quadriceps graft. Harvesting the quadriceps tendon does introduce the theoretical risk of quadriceps tendon rupture; however, to our knowledge this has not been reported in the literature thus far.^{6,14–18} Favorable outcomes with quadriceps tendon–bone grafts illuminate the potential benefits of an all-soft-tissue quadriceps graft. However, further clinical outcome studies pertaining to this specific graft technique are needed to confirm these proposed benefits.

With recent improvements in quadriceps harvesting tools, the established all-inside approach for suspensory graft fixation, and the Quad Link technique presented in this study, an all-soft-tissue quadriceps graft is a viable, underused option for ACLR.

References

1. Kaeding CC, Pedroza AD, Reinke EK, et al; MOON Knee Group, Spindler KP. Change in anterior cruciate ligament graft choice and outcomes over time. *Arthroscopy* 2017;33:2007–2014.

2. Duchman KR, Lynch TS, Spindler KP. Graft selection in anterior cruciate ligament surgery: Who gets what and why? *Clin Sports Med* 2017;36:25-33.
3. Staeubli HU, Bollmann C, Kreutz R, Becker W, Rauschnig W. Quantification of intact quadriceps tendon, quadriceps tendon insertion, and suprapatellar fat pad: MR arthrography, anatomy, and cryosections in the sagittal plane. *AJR Am J Roentgenol* 1999;173:691-698.
4. Lippe J, Armstrong A, Fulkerson JP. Anatomic guidelines for harvesting a quadriceps free tendon autograft for anterior cruciate ligament reconstruction. *Arthroscopy* 2012;28:980-984.
5. Slone HS, Ashford WB, Xerogeanes JW. Minimally invasive quadriceps tendon harvest and graft preparation for all-inside anterior cruciate ligament reconstruction. *Arthrosc Tech* 2016;5:e1049-e1056.
6. Schulz AP, Lange V, Gille J, et al. Anterior cruciate ligament reconstruction using bone plug-free quadriceps tendon autograft: Intermediate-term clinical outcome after 24-36 months. *Open Access J Sports Med* 2013;4:243-249.
7. Lubowitz JH, Ahmad CS, Anderson K. All-inside anterior cruciate ligament graft-link technique: Second-generation, no-incision anterior cruciate ligament reconstruction. *Arthroscopy* 2011;27:717-727.
8. Crall TS, Gilmer BB. Anatomic all-inside anterior cruciate ligament reconstruction using quadriceps tendon autograft. *Arthrosc Tech* 2015;4:e841-e845.
9. Arthrex Inc. *Minimally Invasive Quad Tendon Harvest System—Surgical Technique*. Naples, FL: Arthrex Inc, 2015.
10. Slone HS, Romine SE, Premkumar A, Xerogeanes JW. Quadriceps tendon autograft for anterior cruciate ligament reconstruction: A comprehensive review of current literature and systematic review of clinical results. *Arthroscopy* 2015;31:541-554.
11. Marshall JL, Warren RF, Wickiewicz TL, Reider B. The anterior cruciate ligament: A technique of repair and reconstruction. *Clin Orthop Relat Res* 1979;143:97-106.
12. Harris NL, Smith DA, Lamoreaux L, Purnell M. Central quadriceps tendon for anterior cruciate ligament reconstruction. Part I: Morphometric and biomechanical evaluation. *Am J Sports Med* 1997;25:23-28.
13. Fink C, Herbolt M, Abermann E, Hoser C. Minimally invasive harvest of a quadriceps tendon graft with or without a bone block. *Arthrosc Tech* 2014;3:e509-e513.
14. DeAngelis JP, Fulkerson JP. Quadriceps tendon—A reliable alternative for reconstruction of the anterior cruciate ligament. *Clin Sports Med* 2007;26:587-596.
15. Lee S, Seong SC, Jo CH, Han HS, An JH, Lee MC. Anterior cruciate ligament reconstruction with use of autologous quadriceps tendon graft. *J Bone Joint Surg Am* 2007;89:116-126 (suppl 3).
16. Kim SJ, Lee SK, Choi CH, Kim SH, Kim SH, Jung M. Graft selection in anterior cruciate ligament reconstruction for smoking patients. *Am J Sports Med* 2014;42:166-172.
17. Kim SJ, Kumar P, Oh KS. Anterior cruciate ligament reconstruction: Autogenous quadriceps tendon-bone compared with bone-patellar tendon-bone grafts at 2-year follow up. *Arthroscopy* 2009;25:137-144.
18. Lund B, Nielsen T, Fauno P, Christiansen SE, Lind M. Is quadriceps tendon a better graft choice than patellar tendon? A prospective randomized study. *Arthroscopy* 2014;30:593-598.