

Surgery for Cystadenoma of the Retromolar Pad Area With Reconstruction Using a Buccal Fat Pad Flap: A Case Report

Review began 03/14/2022
Review ended 07/25/2022
Published 07/26/2022

© Copyright 2022

Watabe et al. This is an open access article distributed under the terms of the Creative Commons Attribution License CC-BY 4.0., which permits unrestricted use, distribution, and reproduction in any medium, provided the original author and source are credited.

Yukio Watabe¹, Shota Shinagawa¹, Shiro Shigematsu¹

1. Department of Dentistry and Oral Surgery, Tokyo Metropolitan Tama Medical Center, Fuchu-shi, JPN

Corresponding author: Yukio Watabe, yukiowatabe.omfs@gmail.com

Abstract

Salivary gland tumors can also occur rarely in the retromolar area, though common near the junction of hard and soft palate, labial mucosa, and buccal mucosa. Most salivary gland tumors in the retromolar pad area are malignant and should be excised. The cystadenoma is a rare, benign, salivary gland tumor. Importantly, incomplete resection of this tumor can lead to recurrence or cervical lymph node metastasis. We reported herein a case of cystadenoma arising in the right retromolar pad area in a 63-year-old male patient who underwent reconstruction using a buccal fat pad flap (BFPF) after the surgical removal of the tumor with a 10-mm margin left a defect with bone exposure. No evidence of recurrence or complication was found at the postoperative, three-year follow-up.

Categories: Otolaryngology, Plastic Surgery, Dentistry

Keywords: retromolar pad area, reconstructive surgery, salivary gland tumor, cystadenoma, buccal fat pad flap

Introduction

Salivary gland tumors are relatively rare in the oral cavity but can potentially affect the minor salivary glands significantly. Minor salivary gland tumors comprise fewer than 25% of salivary gland tumors [1]. The cystadenoma is a rare, benign, salivary gland tumor and accounts for 4% of salivary gland neoplasms [2]. It commonly arises on the hard palate, buccal mucosa, or rarely in the retromolar pad area [3-5]. The recommended treatment for a cystadenoma is complete surgical resection [6], but reconstruction of the retromolar pad area is critical to maintaining the function of the oral cavity.

The buccal fat pad flap (BFPF) is a reliable and straightforward method of treating intraoral soft tissue defects. It has been used to reconstruct maxillary defects induced by tumors since it was first reported in 1977 [7]. We herein describe a surgically resected cystadenoma for which reconstruction using a BFPF was performed to correct a defect with bone exposure left by the resection.

Case Presentation

A 63-year-old male patient was referred by his dentist to our hospital to treat an asymptomatic mass in the right retromolar pad area, which was discovered incidentally during dental treatment. There was no history of oral surgery and oral trauma. The patient had no history of smoking or alcohol consumption and no exposure to environmental carcinogens. Clinical examination revealed a mass of 17 mm x 10 mm without tenderness and a reddish area with discrete papules bordered by a peripheral whitish area on the lingual aspect in the right retromolar pad area (Figure 1).

How to cite this article

Watabe Y, Shinagawa S, Shigematsu S (July 26, 2022) Surgery for Cystadenoma of the Retromolar Pad Area With Reconstruction Using a Buccal Fat Pad Flap: A Case Report. Cureus 14(7): e27314. DOI 10.7759/cureus.27314

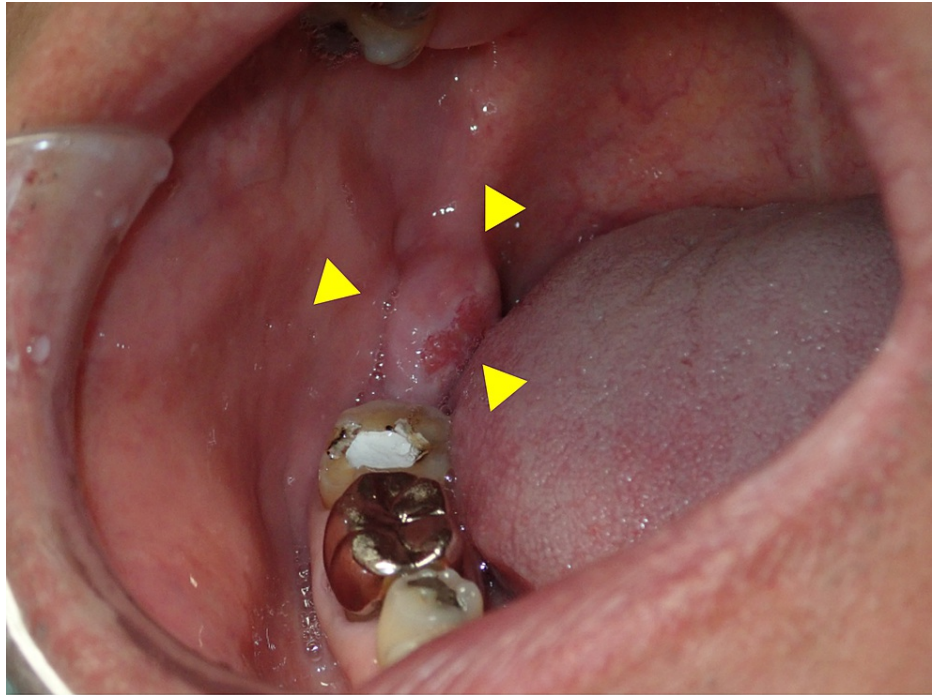


FIGURE 1: Intraoral photograph showing the tumor in the retromolar pad area

The patient's mouth opening was unconstrained. The patient had no difficulties in swallowing and eating. The patient had a history of hyperuricemia. Orthopantomography revealed no erosive destruction or changes in the trabecular bone marrow pattern in mandibular alveolar bone and no presence of radiolucency beneath the radiopaque-filling material involving the underlying pulp with an ill-defined radiolucency with loss of lamina dura in periapical root region of 19 (International Tooth Numbering System), suggestive of secondary caries with a chronic periapical abscess in the mandible (Figure 2).

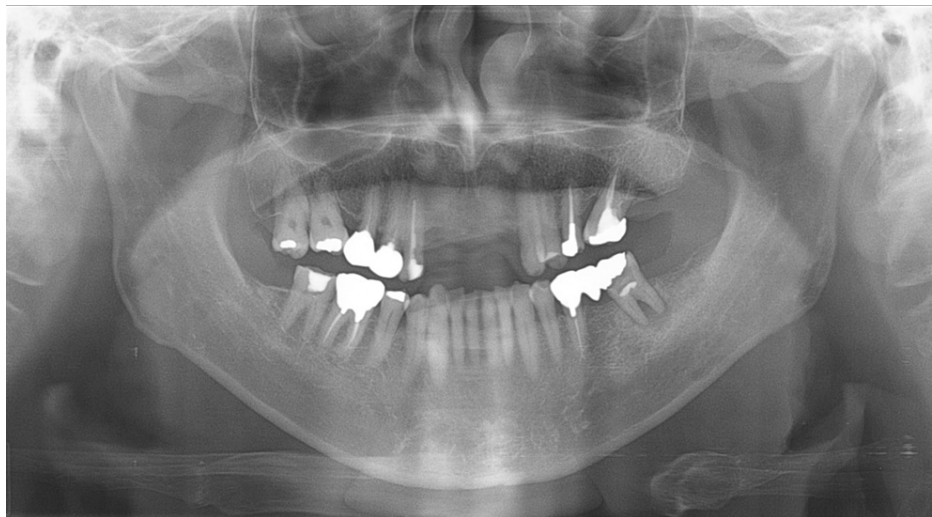


FIGURE 2: Orthopantomograph showing the right mandible without any bony invasion of the tumor

Contrast-enhanced magnetic resonance imaging (MRI) with short tau (TI) inversion recovery demonstrated a hypointense lesion with a sharp margin, round shape, and uniform density distribution lesion in the right retromolar area, which was 13 mm x 10 mm in size and had not invaded the surrounding tissue (Figure 3).

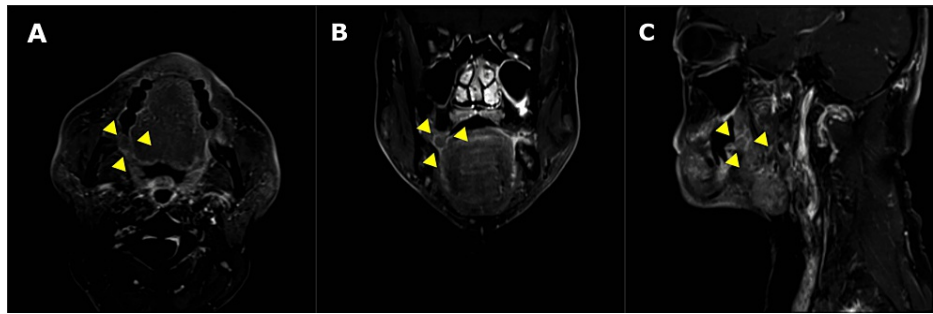


FIGURE 3: Short TI inversion recovery magnetic resonance image with contrast showing the lesion in the right retromolar area. (A) Axial plane, (B) coronal plane, and (C) sagittal plane.

Squamous cell carcinoma or malignant salivary gland tumor was provisionally diagnosed. An incisional biopsy was performed, and a sialadenoma papilliferum was diagnosed. However, since salivary gland tumors in the retromolar pad area are more frequently malignant tumors, total excision under general anesthesia was planned. The procedure included a wide tumor excision with a 10-mm margin. Because of its proximity to 47, the tooth was extracted. The inferior alveolar nerve was preserved during mass resection.

With mandibular bone exposure, the resection resulted in a sizable oral defect in the retromolar pad area. The oral defect was reconstructed using a BFPF (Figure 4, Panel A). Submucosa from the resection margin of the buccal mucosa was peeled and elevated cranially. The buccal muscle was incised cranially at the pterygomandibular ligament, and the buccal fat pad (BFP) was identified anterior to the medial pterygoid muscle. Blunt dissection was done, and the BFP pulled out anteriorly toward the oral defect without tension. The flap margin was sutured and fixed to the marginal oral mucosa with 4-0 nylon. The oral defect in the retromolar pad area was covered entirely with the BFP (Figure 4, Panel B). No additional skin grafting was performed because BFP flaps epithelialize spontaneously.

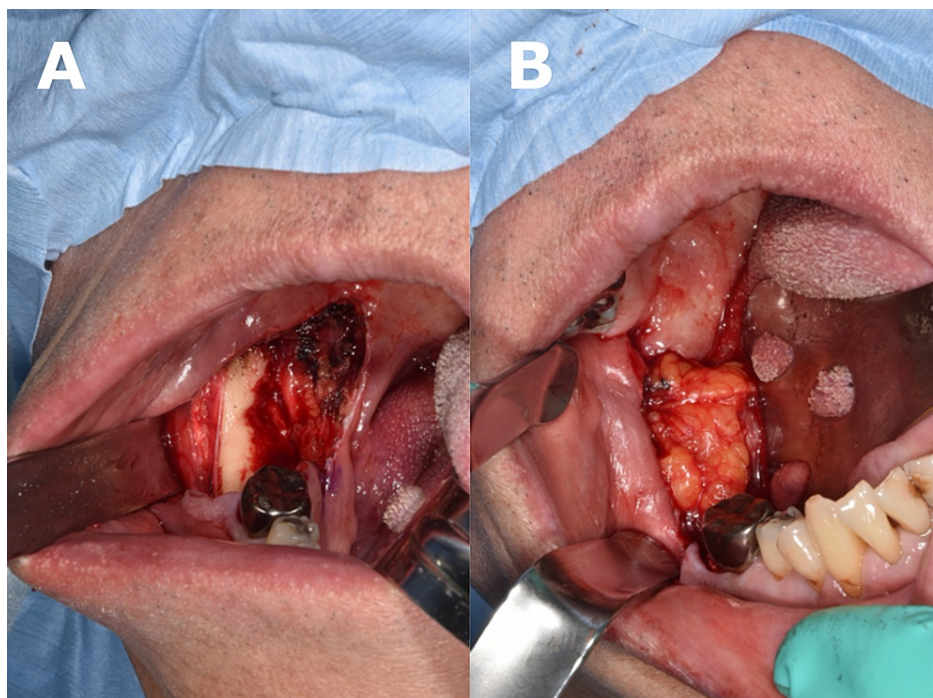


FIGURE 4: (A) Surgical site after the tumor resection. (B) Buccal fat pad exposure in the oral defect.

A thorough examination of the excised specimen led to the diagnosis of a cystadenoma (Figure 5, Panels A and B).

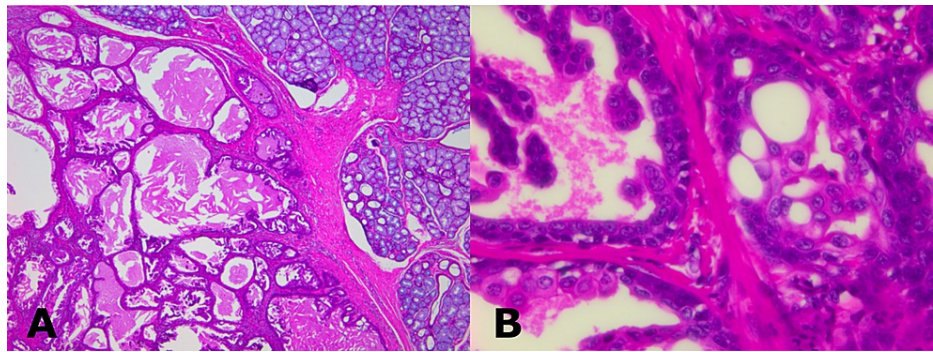


FIGURE 5: (A) Histological sections showing multiple cystic spaces of variable sizes with central eosinophilic material (hematoxylin and eosin stain, 40x). (B) Cystic cavity lined by bilayered epithelium consisting of columnar and flat epithelium exhibiting intraluminal papillary projections (hematoxylin and eosin stain, 400x).

Surgical antibiotic prophylaxis (ampicillin 3.0 g/day) was administered until the day after surgery. The patient began a dysphagia soft diet the day after surgery. Mouth opening exercises were started in the early postoperative period. The postoperative course was uneventful, and the patient's mouth opening was unconstrained. No recurrence was found at the three-year follow-up (Figure 6).

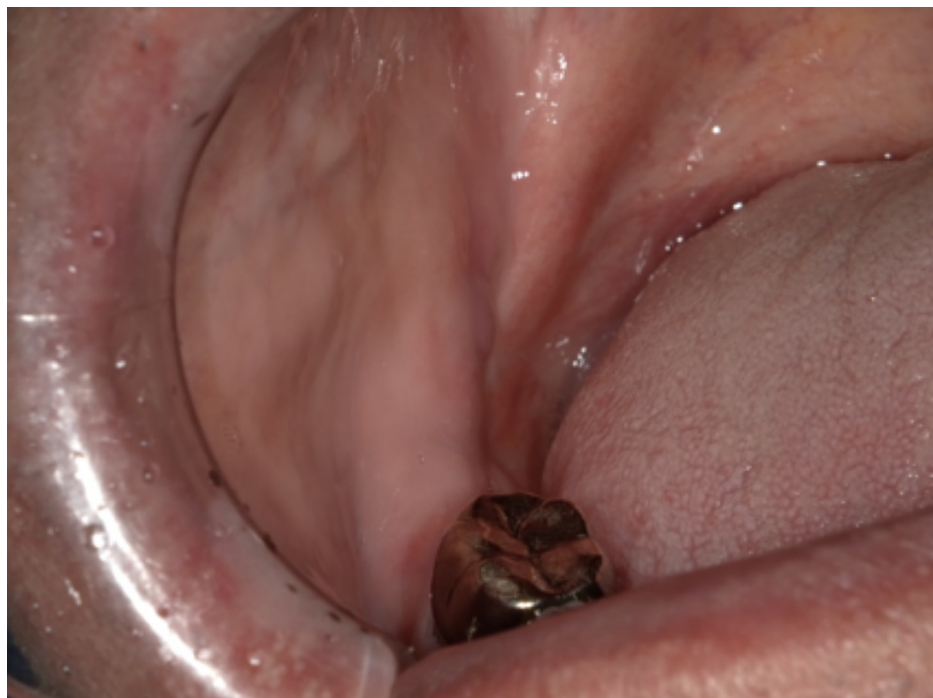

FIGURE 6: Intraoral photograph showing no scar contracture or recurrence at postoperative year 3

Discussion

We reported a rare case of cystadenoma in the retromolar pad area. It should be borne in mind that a neoplastic lesion developing in the retromolar pad area may be a malignant salivary gland tumor. Therefore, in the present case, we performed a wide resection and reconstructed the surgical defect using a BFPF with good outcomes.

Cystadenomas, which arise in the pancreas, ovary, prostate, or kidney [8-11], rarely occur in the retromolar pad area. When it occurs in the head and neck area, it is often found in the parotid gland, with a frequency of 45% [12]. The most frequent sites of cystadenoma development in the oral cavity are the hard palate, the

buccal mucosa, and the tongue [13], and rarely, the retromolar pad area [3-5]. Table 1 summarizes the case reports of cystadenoma in the retromolar pad area published in English since 2000.

Case	Authors (Year)	Age	Gender	Size (mm)	Symptom	Preoperative diagnosis	Treatment	Recurrence
1	Takahashi et al. (2008) [3]	43	Male	20 × 27	Swelling	Monomorphic adenoma	Excision	No
2	Sheetal et al. (2016) [4]	40	Female	30 × 40	Swelling	Pleomorphic adenoma	Excision	No
3	Wu et al. (2018) [5]	45	Female	None stated	Recurrent painless mass in the retromolar and submandibular regions	Cystadenoma	Excision	No
4	Present case	63	Male	13 × 10	Swelling	Sialadenoma papilliferum	Excision	No

TABLE 1: The reported case of cystadenoma arising in the retromolar pad area

In general, it was predominantly found in females [2]. Table 1 indicated no gender difference in the case of cystadenomas in the retromolar pad area. Some reports indicated no gender difference in the frequency of lesions [14]. Standard features of benign salivary gland tumors, including cystadenoma on CT and MRI, are sharp margins, round shape, and uniform density distribution [15]. In this case, findings characteristic of a benign salivary gland tumor were observed on MRI. However, most salivary gland tumors in the retromolar pad area are malignant [16], and a wide resection under general anesthesia was ultimately performed.

The wide excision in our patient left a defect with mandibular bone exposure in the retromolar pad area, which was corrected using a BFPF. The BFPF has the advantage of being simple and easy to perform. The BFPF consists of the main body with four extensions: the temporal, buccal, pterygoid, and pterygopalatine processes [17]. Generally, the BFPF can easily be accessed via a horizontal incision over the periosteum near the maxillary third molar [18]. After the resection, the BFPF was easily accessed in the present case by dissecting and elevating the buccal mucosa and incising the exposed buccal muscle in the surgical field. The failure rate of reconstructive procedures for oral defects using BFPF is low, thanks to the tissue's rich vascularization and rapid epithelialization [19].

According to a review of 12 studies, 89.1% of BFPF reconstructions had no associated adverse events, including infection, loss of graft, bleeding, fistula, dehiscence, and mouth opening limitation [20]. However, the BFPF has several shortcomings. First, the size of the defect that can be corrected with this procedure is less than 5 cm in diameter [21]. Importantly, constriction of mouth opening is a postoperative complication associated with reconstructive surgery using a BFPF. In a retrospective study, five of 32 patients with reconstruction using a BFPF for an oral defect after tumor resection had scar retraction and constriction of mouth opening. After reconstructive oral surgery using a BFPF, mouth opening training should be started on postoperative day 5 to avoid these complications [22].

In this case, the biopsy result was sialadenoma papilliferum. However, the resected specimen was finally diagnosed as a cystadenoma. Sialadenoma papilliferum usually occurred at the junction of the hard and soft palates and the floor of the mouth and histopathologically did not show multiple cystic cavities [23]. The histopathologic differential diagnosis of cystadenoma includes Warthin's tumor and cystadenocarcinoma. Warthin's tumor is characterized by subepithelial aggregates of lymphocytes and germinal centers. These characteristics were not observed in this case. Furthermore, there was no evidence of invasive growth in the surrounding area, and findings suggestive of cystadenocarcinoma were lacking.

Most salivary gland tumors in the retromolar pad area are malignant [16]. Although the present case was a cystadenoma, an accurate diagnosis of the minor salivary gland is often difficult, even if the biopsy results indicate a benign tumor. For this reason, even a minor salivary gland tumor in the retromolar pad area should be excised. Resection is recommended in this disease, and recurrence or malignancy is rare [24]. However, a previous study reported a case of cystadenoma recurrence in the retromolar pad at postoperative year 5 with a simultaneous cervical metastasis [5]. Although cystadenomas are a benign form of salivary adenoma, providing a sufficiently wide surgical margin is warranted, as in the present case.

Conclusions

We experienced a case of cystadenoma occurring in the retromolar pad area, which was widely resected. The surgical defect was reconstructed using a BFPF. Most salivary gland tumors in the retromolar pad area are

malignant, but a benign tumor may occasionally occur, as in the present case. Nonetheless, even a benign salivary gland tumor, especially a cystadenoma, should be excised completely to prevent a recurrence.

Additional Information

Disclosures

Human subjects: Consent was obtained or waived by all participants in this study. **Conflicts of interest:** In compliance with the ICMJE uniform disclosure form, all authors declare the following: **Payment/services info:** All authors have declared that no financial support was received from any organization for the submitted work. **Financial relationships:** All authors have declared that they have no financial relationships at present or within the previous three years with any organizations that might have an interest in the submitted work. **Other relationships:** All authors have declared that there are no other relationships or activities that could appear to have influenced the submitted work.

Acknowledgements

We are grateful to Mr. James R Valera for his assistance in editing the manuscript.

References

1. Pires FR, Pringle GA, de Almeida OP, Chen SY: Intra-oral minor salivary gland tumors: a clinicopathological study of 546 cases. *Oral Oncol.* 2007, 43:463-70. [10.1016/j.oraloncology.2006.04.008](https://doi.org/10.1016/j.oraloncology.2006.04.008)
2. El-Naggar AK, Chan JKC, Grandis JR, Takata T, Slootweg PJ: WHO Classification of Head and Neck Tumours. International Agency for Research on Cancer, Lyon, France; 2017.
3. Takahashi Y, Kawano K, Yanagisawa S, Yokoyama S: Cystadenoma arising from the retromolar region: a case report. *Oral Science International.* 2008, 5:61-4. [10.11277/osi.5.61](https://doi.org/10.11277/osi.5.61)
4. Sheetal, Ramesh V, Balamurali PD, Premalatha B, Chaudhary M: Cystadenoma in retromolar region: a case report. *J Clin Diagn Res.* 2016, 10:ZD17-8. [10.7860/JCDR/2016/20149.8679](https://doi.org/10.7860/JCDR/2016/20149.8679)
5. Wu WJ, Huang MW, Gao Y, Zhang JG: Cystadenoma of minor salivary gland with cervical metastasis: benign or malignant?. *J Oral Maxillofac Surg.* 2018, 76:670-5. [10.1016/j.joms.2017.07.151](https://doi.org/10.1016/j.joms.2017.07.151)
6. Kogi S, Onodera K, Tsunoda N, Kawai T, Miyamoto I, Takeda Y, Yamada H: Cystadenoma of the tongue: report of a case with long-term follow-up. *J Surg Case Rep.* 2020, 2020:269. [10.1093/jscr/rjaa269](https://doi.org/10.1093/jscr/rjaa269)
7. Egyedi P: Utilization of the buccal fat pad for closure of oro-antral and/or oro-nasal communications. *J Maxillofac Surg.* 1977, 5:241-4. [10.1016/s0301-0503\(77\)80117-3](https://doi.org/10.1016/s0301-0503(77)80117-3)
8. Tracht J, Reid MD, Hissong E, Sekhar A, Sarmiento J, Krasinskas A, Xue Y: Serous cystadenoma of the pancreas with complex florid papillary architecture: a case report and review of the literature. *Int J Surg Pathol.* 2019, 27:907-11. [10.1177/1066896919854544](https://doi.org/10.1177/1066896919854544)
9. Alobaid A, Elamir H, Abuzaid M, Abu-Zaid A: An extremely giant ovarian mucinous cystadenoma. *Gulf J Oncolog.* 2019, 1:83-6.
10. Nakamura Y, Shida D, Shibayama T, et al.: Giant multilocular prostatic cystadenoma. *World J Surg Oncol.* 2019, 17:42. [10.1186/s12957-019-1579-7](https://doi.org/10.1186/s12957-019-1579-7)
11. Mitome T, Yao M, Udaka N, et al.: Mucinous cystadenoma of a horseshoe kidney: a case report and literature review. *Can Urol Assoc J.* 2015, 9:E30-2. [10.5489/cuaj.2211](https://doi.org/10.5489/cuaj.2211)
12. Wang L, Zhang SK, Ma Y, Ha PK, Wang ZM: Papillary cystadenoma of the parotid gland: a case report. *World J Clin Cases.* 2019, 7:366-72. [10.12998/wjcc.v7.i3.366](https://doi.org/10.12998/wjcc.v7.i3.366)
13. Tjioe KC, de Lima HG, Thompson LD, Lara VS, Damante JH, de Oliveira-Santos C: Papillary cystadenoma of minor salivary glands: report of 11 cases and review of the English literature. *Head Neck Pathol.* 2015, 9:354-9. [10.1007/s12105-014-0602-0](https://doi.org/10.1007/s12105-014-0602-0)
14. Castro VL, Corrêa TF, Guimarães Vde C, Nery GV, Ferreira JB: Giant cystadenoma of the floor of the mouth: a case report. *Int Arch Otorhinolaryngol.* 2013, 17:101-4. [10.7162/S1809-9772013000100018](https://doi.org/10.7162/S1809-9772013000100018)
15. Liu Y, Li J, Tan YR, Xiong P, Zhong LP: Accuracy of diagnosis of salivary gland tumors with the use of ultrasonography, computed tomography, and magnetic resonance imaging: a meta-analysis. *Oral Surg Oral Med Oral Pathol Oral Radiol.* 2015, 119:238-45. [10.1016/j.oooo.2014.10.020](https://doi.org/10.1016/j.oooo.2014.10.020)
16. Waldron CA, el-Mofty SK, Gnepp DR: Tumors of the intraoral minor salivary glands: a demographic and histologic study of 426 cases. *Oral Surg Oral Med Oral Pathol.* 1988, 66:323-33. [10.1016/0030-4220\(88\)90240-x](https://doi.org/10.1016/0030-4220(88)90240-x)
17. Katre MI, Deshmukh SD, Dhanajkar PS, Keche P, Gaikwad A: Buccal fat pad a forgotten option of reconstruction in oral cancer. *Indian J Otolaryngol Head Neck Surg.* 2019, 71:248-52. [10.1007/s12070-018-1257-z](https://doi.org/10.1007/s12070-018-1257-z)
18. Shibahara T, Watanabe Y, Yamaguchi S, Noma H, Yamane GY, Abe S, Ide Y: Use of the buccal fat pad as a pedicle graft. *Bull Tokyo Dent Coll.* 1996, 37:161-5.
19. Neto JQO, Filho ELC, Andrade GS, Silveira DX, Carvalho AC: Technique of the buccal fat pad flap as an alternative for the surgical defect of pleomorphic adenoma. *J Craniofac Surg.* 2019, 30:798-9. [10.1097/SCS.00000000000004890](https://doi.org/10.1097/SCS.00000000000004890)
20. Kim MK, Han W, Kim SG: The use of the buccal fat pad flap for oral reconstruction. *Maxillofac Plast Reconstr Surg.* 2017, 39:5. [10.1186/s40902-017-0105-5](https://doi.org/10.1186/s40902-017-0105-5)
21. Rapidis AD, Alexandridis CA, Eleftheriadis E, Angelopoulos AP: The use of the buccal fat pad for reconstruction of oral defects: review of the literature and report of 15 cases. *J Oral Maxillofac Surg.* 2000, 58:158-63. [10.1016/s0278-2391\(00\)90330-6](https://doi.org/10.1016/s0278-2391(00)90330-6)
22. Dean A, Alamillos F, García-López A, Sánchez J, Peñalba M: The buccal fat pad flap in oral reconstruction. *Head Neck.* 2001, 23:383-8. [10.1002/hed.1048](https://doi.org/10.1002/hed.1048)
23. Fowler CB, Damm DD: Sialadenoma papilliferum: analysis of seven new cases and review of the literature.

- Head Neck Pathol. 2018, 12:193-201. [10.1007/s12105-017-0852-8](https://doi.org/10.1007/s12105-017-0852-8)
24. Onda T, Hayashi K, Takano N, Matsuzaka K, Shibahara T: A case of cystadenoma arising in the upper lip . Bull Tokyo Dent Coll. 2015, 56:49-55. [10.2209/tdcpublication.56.49](https://doi.org/10.2209/tdcpublication.56.49)