

Temporary Fixation Using a Long Femoral-tibial Nail to Treat a Displaced Medial Tibial Plateau Fracture in a 90-year-old Patient: A Case Report

V Batta¹, S Sinha², A Trompeter³

Learning Points for this Article:

A long femoral-tibial nail is a useful temporary fixation for displaced tibial plateau fractures in the very elderly with poor soft tissue cover.

Abstract

Introduction: Tibial plateau fractures are complex injuries in the elderly population. When traditional methods of fixation are not suitable, an alternative method needs to be chosen for a favorable outcome. We demonstrate a previously undescribed treatment for displaced tibial plateau fractures in the very elderly with poor soft-tissue integrity.

Case Report: A 90-year-old woman suffered an open, Gustilo Grade IIIA, displaced fracture of the tibial plateau. An intramedullary knee arthrodesis, the femoral-tibial nail was used to temporarily stabilize her fracture. She was able to weight bear immediately postfixation.

Conclusion: A long femoral-tibial nail allows favorable fracture and soft tissue healing, ease of nursing and immediate full weight-bearing. It shows good promise and should be considered as a management option when traditional methods are not applicable in select patients.

Keywords: Tibial plateau fracture, Elderly, Arthrodesis, Femorotibial nail.

Introduction

Tibial plateau fractures in the elderly are complex injuries that represent around 1% of all fractures and 8% of total fractures in persons above 65 years of age [1]. The choice of treatment is dictated by the severity of soft tissue injury, degree of articular depression and displacement, mechanical malalignment, age and mobility of the patient, systemic comorbidities, and skill of the operating surgeon [2]. The chosen treatment should primarily allow full and early weight-bearing since immobilization can lead to systemic complications and an increased hospital stay [1, 3].

Case Report

A 90-year-old woman presented with a left leg injury after a fall from standing. She has a background of osteoarthritis and osteoporosis and normally mobilized with a walking stick. On examination, her soft tissues were very friable, and there was a 10 cm full-thickness laceration over the fracture site. The radiograph (Fig. 1) showed a displaced medial condyle, Schatzker Type 4 fracture with 15 mm displacement, condylar widening of 12 mm, articular

step-off of 6 mm, and varus malalignment of 7°.

The options for treatment of this Gustilo Grade III open fracture were considered. Plaster cast would not allow for easy wound management or weight-bearing and risks nonunion, pressure sores, and venous thromboembolism/chest sepsis. Plate fixation in osteoporotic bone risks early failure, and again nonweight-bearing was deemed too risky to the patient's general health. Circular external fixation is challenging for the very elderly. Primary stemmed arthroplasty was discounted due to the open wound and the tibial tuberosity fragment. An arthrodesis nail was considered the best option to allow minimally invasive stabilization, soft tissue management, and immediate full weight-bearing postoperatively.

The patient was positioned supine on a pelvic traction table, and the wound was washed and debrided. After freehand reduction, a long hip to ankle anterograde intramedullary nail was inserted from the greater trochanter through the knee to just proximal to the ankle, with the knee joint fixed in 10° flexion. The femoral-tibial mechanical axis was restored to within 5° of the unaffected limb (Fig. 2) and closed primarily. The skin edges were preserved and skin flaps repaired with

Access this article online


Website:
www.jocr.co.in

DOI:
2250-0685.840

Author's Photo Gallery



Dr. Vineet Batta



Dr. Sharad Sinha



Dr. Alex Trompeter

¹Department of Trauma and Orthopaedic Surgery, Luton and Dunstable Hospital, Luton, LU4 0DZ, United Kingdom.

²Department of Trauma and Orthopaedics, St Richard's Hospital, Chichester, PO19 6SE, United Kingdom.

³Department of Trauma and Orthopaedic Surgery, St George's Hospital, Tooting, London, SW17 0QT, United Kingdom.

Address of Correspondence:

Dr. Vineet Batta,
Department of Trauma and Orthopaedic Surgery, Luton and Dunstable Hospital, Luton, LU4 0DZ, United Kingdom.
Email: battavineet77@gmail.com

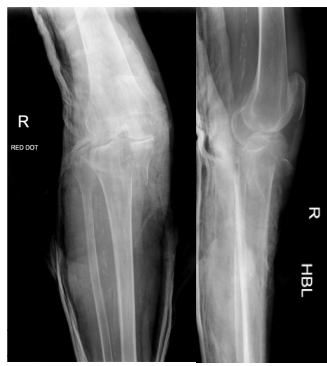

Figure 1: Pre-operative radiographs showing displaced medial tibial plateau fracture. (a) Anteroposterior view, (b) lateral view.

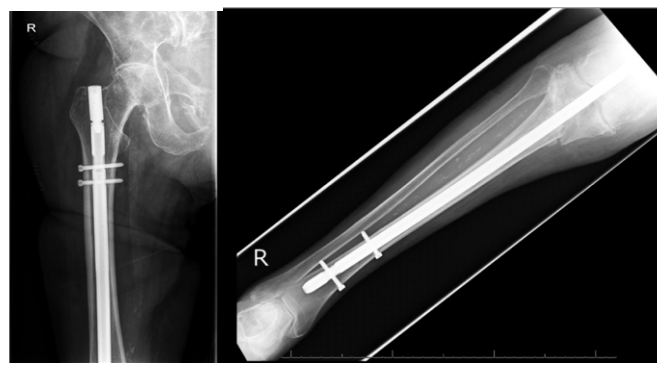


Figure 2: Immediate post-operative radiographs showing fixation of fracture with long femoral-tibial nail. (a) Anteroposterior (AP) view of proximal femur, (b) AP view of tibia.

steristrips.

By day 3 postoperatively, the patient was able to weight bear on the affected leg with assistance of a Zimmer frame and one physiotherapist. After 2 weeks, she was discharged to a rehabilitation center.

At 4-month follow-up, the soft tissue had healed and the fracture had united (Fig. 3). The patient was able to mobilize comfortably.

The intention was to remove the nail at 6 months after the index procedure, to restore knee motion; however, the patient was satisfied with the outcome and has declined further surgery.

Discussion

Open fractures in the elderly present an interesting surgical challenge. Approximately 60% of fractures in the elderly follow a fall. Interestingly, there is a high incidence of Gustilo Type III fractures in this patient cohort, particularly in females. The literature shows that male skin is thicker than female skin in all anatomical locations, and in addition, the skin atrophies/thins with age [4]. This leaves elderly female patients more vulnerable to open fractures.

The aims of treatment in this instance were to restore the mechanical axis and to allow unrestricted weight-bearing postoperatively. Immediate weight-bearing is an important criterion for surgeons to consider when treating lower limb fractures in the elderly. It has now been accepted that early mobilization is critical in reducing complications and mortality while improving functional recovery and accelerating discharge from the hospital.

The standard treatment of tibial plateau fractures is an open reduction and internal fixation (ORIF) with plate fixation. ORIF provides good fracture reduction and stability. However, there are data lacking on its use for very elderly patients with poor skin integrity. Soft tissue infection and wound necrosis are likely complications of ORIF in the elderly [5] and would have prevented its use in this case. Furthermore, the risk of construct failure on weight-bearing in osteoporotic bone is recognized in elderly patient fracture fixation.

An alternative is the use of an external fixator, but this is generally not well tolerated and results in poorer outcomes in elderly patients [6]. In very osteoporotic bone, it is often associated with pin-tract infection, loosening, and pin site fracture [7]. Complication rates can be as high as 80% using this treatment [8]. Due to the patient's severe osteopenia and tissue damage, this was not a feasible treatment option.

Arthroplasty was not considered as the risk of infection was too high, and the tibial tuberosity was a separate fragment.

Non-operative methods are used only for minimally displaced fractures [9]. A cast brace for this patient would not have allowed immediate full weight-bearing, and the condition of the soft tissues would have necessitated regular dressing for the fracture to heal. Again, not a viable option.

In recent years, knee arthrodesis using long femoral-tibial nail has become the treatment of choice for failed total knee arthroplasty and reconstruction after

tumor resection when the knee joint cannot be salvaged [10]. However, its use in acute displaced tibial plateau fracture as a temporary internal fixation in patient with severe soft tissue injury has not been described before. Its main benefit rests with its ability to allow immediate bearing in weakened bone where other options would fail.

There are several limitations of this form of treatment. Primarily, as the knee is fixed in 10° flexion until the nail is removed; there is a loss of knee function, necessitating gait retraining, and increased energy requirement.

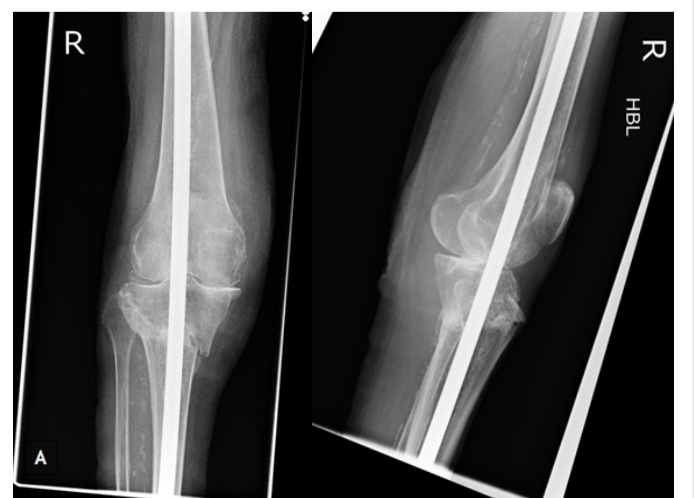

Figure 3: 16-week post-operative radiograph showing good fracture union and no secondary displacement. (a) Anteroposterior view, (b) lateral view.

Intraoperative risks such as intraarticular cartilage and ligament damage exist where the reamers and nail cross the knee. Even after the nail is removed, some percentage of knee range of movement would be permanently lost due to intracapsular adhesions and extra articular contracture. However, safely managing the soft tissues and allowing early rehabilitation with lower limb trauma remain the goals in this instance, and the long nail allowed for this.

Conclusion

A long femoral-tibial nail is a useful temporary fixation for displaced tibial plateau fractures in the very elderly with poor soft tissue cover. It permits favorable fracture and soft tissue healing, ease of nursing care, and permits immediate full weight-bearing. Further studies are needed to better define the indications, assess functional outcome, and complication rates of this treatment modality.

Clinical Message

In the very elderly, displaced tibial plateau fractures are not always amenable to standard treatments. In the right patient group, a long femoral-tibial nail could provide a temporary fixation for this to improve a number of clinical outcomes.

References

1. Frattini M, Vaienti E, Soncini G, Pogliacomi F. Tibial plateau fractures in elderly patients. *Chir Organi Mov* 2009;93(3):109-114.
2. Hsu CJ, Chang WN, Wong CY. Surgical treatment of tibial plateau fracture in elderly patients. *Arch Orthop Trauma Surg* 2001;121(1-2):67-70.
3. Kamel HK, Iqbal MA, Mogallapu R, Maas D, Hoffmann RG. Time to ambulation after hip fracture surgery: Relation to hospitalization outcomes. *J Gerontol A Biol Sci Med Sci* 2003;58(11):1042-1045.
4. Court-Brown CM, Biant LC, Clement ND, Bugler KE, Duckworth AD, McQueen MM. Open fractures in the elderly. The importance of skin ageing. *Injury* 2015;46(2):189-194.
5. Canadian Orthopaedic Trauma Society. Open reduction and internal fixation compared with circular fixator application for bicondylar tibial plateau fractures. Results of a multicenter, prospective, randomized clinical trial. *J Bone Joint Surg Am* 2006;88(12):2613-2623.
6. Su EP, Westrich GH, Rana AJ, Kapoor K, Helfet DL. Operative treatment of tibial plateau fractures in patients older than 55 years. *Clin Orthop Relat Res* 2004;421:240-248.
7. Manidakis N, Dosani A, Dimitriou R, Stengel D, Matthews S, Giannoudis P. Tibial plateau fractures: Functional outcome and incidence of osteoarthritis in 125 cases. *Int Orthop* 2010;34(4):565-570.
8. Oostenbroek HJ, van Roermund PM. Arthrodesis of the knee after an infected arthroplasty using the Ilizarov method. *J Bone Joint Surg Br* 2001;83(1):50-54.
9. Jensen DB, Rude C, Duus B, Bjerg-Nielsen A. Tibial plateau fractures. A comparison of conservative and surgical treatment. *J Bone Joint Surg Br* 1990;72(1):49-52.
10. Wood JH, Conway JD. Advanced concepts in knee arthrodesis. *World J Orthop* 2015;6(2):202-210.

Conflict of Interest: Nil
Source of Support: None

How to Cite this Article

Batta V, Sinha S, Trompeter A. Temporary Fixation Using a Long Femoral-tibial Nail to Treat a Displaced Medial Tibial Plateau Fracture in a 90-year-old Patient: A Case Report. *Journal of Orthopaedic Case Reports* 2017 Jul-Aug;7(4):36-38