

Successful Primary Medical Therapy with Somatostatin Receptor Ligand in Acromegaly with Thyroid Cancer

Shalini Sree Dharan and Nor Azmi Kamaruddin

Endocrinology and Diabetes Unit, Department of Medicine, National University of Malaysia

Abstract

Acromegaly is a rare disease with an annual incidence of 3 to 4 cases in a million.¹ Diagnosis is often delayed due to the slow progression of the disease. Persistent elevation of growth hormone (GH) in acromegaly causes a reduction in life expectancy by 10 years. Aside from multiple cardiovascular, respiratory and metabolic co-morbidities, it has also been proven to cause an increased incidence of cancer. The main treatment of acromegaly is surgical excision of the functioning pituitary adenoma. Multiple comorbidities, including obstructive sleep apnea (OSA), left ventricular hypertrophy (LVH) and soft tissue swelling, make surgery complicated, if not impossible. Medical therapy to reduce comorbidities may be indicated in certain situations. Somatostatin receptor ligands (SRL) are able to reduce, and possibly normalize, IGF-1 levels.² Reduction of insulin-like growth factor-1 (IGF-1), the main mediator of GH, is able to resolve headache, sweating, fatigue and soft tissue swelling, and also reduce ventricular hypertrophy. This case report illustrates the successful use of the SRL octreotide LAR in treating acromegaly. It also confirms the observation from several case series that thyroid cancer is the most common malignancy in acromegaly.

Key words: acromegaly, somatostatin receptor ligands, octreotide LAR, papillary thyroid cancer

INTRODUCTION

Acromegaly is characterized by somatic overgrowth, physical disfigurement, multiple co-morbidities and premature death. The main cause of this disorder is chronic hypersecretion of GH, mediating its effects directly or through IGF-1.

The control of GH secretion is the most important determinant in reducing mortality in acromegaly. Any therapy that is able to reduce GH and IGF-1 will alter the prognosis of a patient with acromegaly. Octreotide is able to normalize IGF-1 in 68% of patients and reduce GH to less than 5 µg/L in 53%.³ A multi-center prospective study demonstrated tumor shrinkage with octreotide in all 27 newly diagnosed patients with acromegaly, with median tumor volume reduction of 49% in microadenomas and 43% in macroadenomas.⁴ Thyroid cancer may also be an associated finding in long-standing undiagnosed acromegaly, as illustrated in this case report.

CASE

A 58-year-old Malay lady with underlying type 2 diabetes and hypertension for 2 years was admitted to a nearby hospital for lacunar stroke. During assessment, she was noted to have features of acromegaly. On further interview, she disclosed increased shoe (from 6 to 11) and

ring (14 to 26) sizes. She also experienced hoarseness, increased sweating, weight gain and higher blood pressure on monitoring. She also observed an enlarging goiter but denied obstructive symptoms. She had severe sleep apnea symptoms based on the Epworth Sleepiness scale. There were no known endocrine disorders or malignancy in her family.

Physical examination revealed marked features of acromegaly: frontal bossing, prognathism, increased interdental separation, thick lips and coarsened facial features. Her blood pressure was 160/90 mmHg, with no clinical evidence of heart failure. She had a hard goiter with palpable cervical lymph nodes. She had moist palms and skin tags. Visual field was intact on confrontation test.

Initial tests showed elevated IGF-1 (703 µg/L, reference range 35-210) and fasting GH (10.3 ng/mL, reference range up to 8). GH was not suppressed by oral glucose loading, with a nadir of 12.9 µg/L. Follicle stimulating hormone (26.5 IU/L) and luteinizing hormone (8.6 IU/L) were low for age. Other parameters were within reference ranges (prolactin 150 IU/mL, thyroid stimulating hormone 1.15 µIU/mL, free thyroxine 13.8 pmol/L, corrected Ca 2.36 mmol/L, serum Na 138 mmol/L, serum K 4.0 mmol/L and serum creatinine 44.9 µmol/L). HbA1c was 6.9%. Sleep study yielded an Apnea-Hypopnea Index (AHI) of 36.5, indicative of severe OSA. Echocardiogram performed in

ISSN 0857-1074

Printed in the Philippines

Copyright © 2017 by the JAFES

Received: March 17, 2017. Accepted: August 22, 2017.

Published online first: September 30, 2017.

<https://doi.org/10.15605/jafes.032.02.12>

*Corresponding author: Shalini Sree Dharan, MD
Endocrinology and Diabetes Unit, Department of Medicine
National University of Malaysia Medical Centre
Jalan Yaacob Latiff, 56000 Bandar Tun Razak, Cheras
Kuala Lumpur, Malaysia
Tel. No.: +603-91455555
Fax No.: +603-91456640
E-mail: drshalinisreedharan@gmail.com*

preparation for eventual surgery showed concentric LVH and diastolic dysfunction with an ejection fraction of 65%. Magnetic resonance imaging (MRI) of the pituitary revealed a 1.5 cm x 1.8 cm x 1.1 cm macroadenoma located at the anterior pituitary invading the right cavernous sinus and encasing the right internal carotid artery. There was a clear plane separating the pituitary from the optic chiasm (Figure 1A).

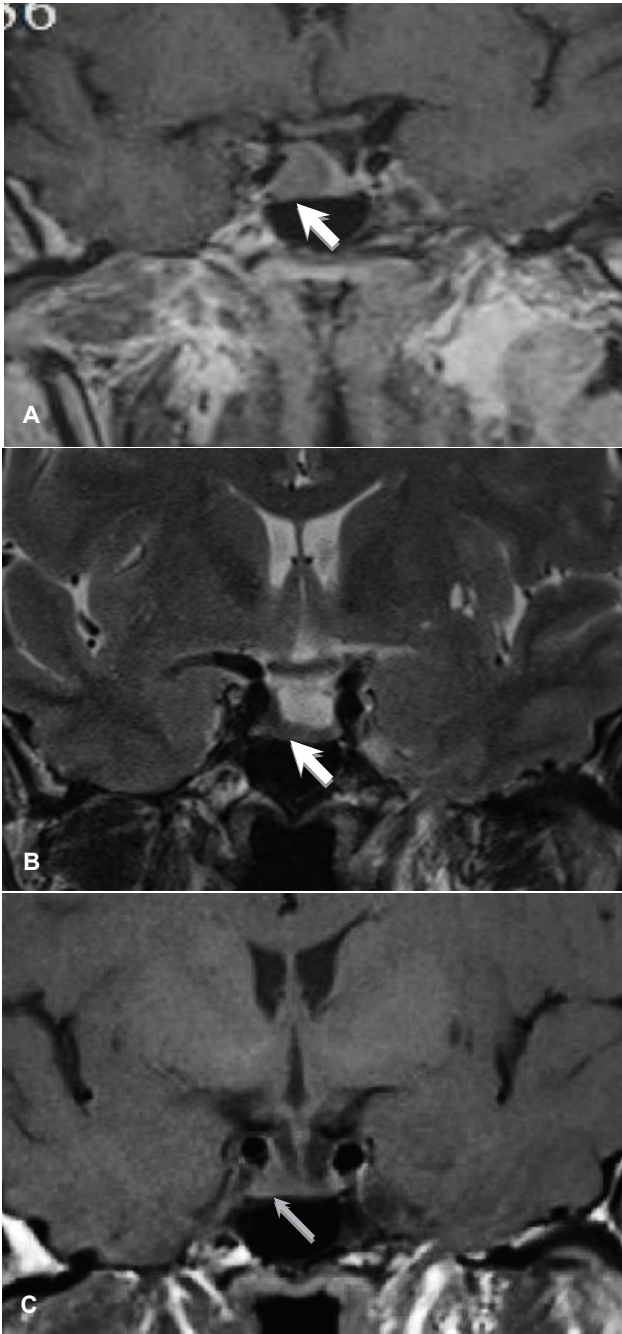


Figure 1. MRI of the pituitary gland, coronal view. **(A)** T1-weighted initial study showed a 1.5 cm x 1.6 cm x 1.1 cm adenoma (*white arrow*) on the right side of the pituitary invading the right cavernous sinus and encasing the right internal carotid artery. **(B)** on T2-weighted imaging, the tumor appeared hypointense, suggestive of dense granulation. **(C)** follow-up study showed reduction in size of the pituitary adenoma to 0.5 cm x 0.6 cm x 0.3 cm (*thin gray arrow*) after 6 months of octreotide LAR.

Neck ultrasonography showed multiple mixed solid and cystic nodules in both thyroid lobes. The thyroid nodule on the right lobe appeared solid and cystic, with wall calcification and no vascularity (Figure 2A). There were multiple predominantly solid thyroid nodules with internal microcalcifications on the left lobe, with the largest nodule measuring 3.2 cm x 3.2 cm x 4.6 cm located at the lower pole (Figure 2B). Subcentimeter cervical lymph nodes were also seen. Fine needle aspiration cytology of the thyroid nodule reported neoplastic thyroid epithelial cells displaying enlarged nuclei, nuclear grooves and intranuclear inclusions suggestive of papillary thyroid cancer.

Medical therapy with subcutaneous octreotide LAR 20 mg monthly for 6 months prior to surgery was initiated to alleviate cardiovascular, metabolic and respiratory comorbidities. Recent lacunar strokes were also a contraindication to immediate surgery. After 3 months of medical therapy, clinical features of acromegaly and OSA improved, and IGF-1 became normal.

She underwent total thyroidectomy with therapeutic anterior and left lateral neck dissection. Histopathologic evaluation revealed papillary thyroid cancer measuring 5 cm x 5 cm, with involvement of 5 of the 8 resected lymph nodes. Subsequent remnant ablation with radioactive iodine 120 mCi was done. Post-treatment whole body scan (WBS) showed uptake at the area of the thyroid bed.

Follow-up MRI after 6 months of octreotide LAR revealed a residual 0.5 cm x 0.6 cm x 0.3 cm pituitary microadenoma (Figure 1B). Transphenoidal adenomectomy was uneventful, with no post-operative pituitary hormonal deficit and diabetes insipidus. IGF-1 remained within normal range for age and gender.

DISCUSSION

The insidiousness of acromegaly often results in a late diagnosis, as seen in our patient. High GH and IGF-1 levels affect many tissues, causing cardio-metabolic consequences and respiratory complications mainly due to central and obstructive sleep apnea. Our patient presented with difficult to control blood pressure, stroke and severe OSA.

Treatment choices in acromegaly are dependent on several factors. In our patient, the macroadenoma was confined to the sella, with apparent invasion of the right cavernous sinus and encasement of the right internal carotid artery. As it was not near the optic chiasm, there were no visual and neurologic disturbances. Urgent surgical removal was not deemed necessary at that point.

SRL pre-treatment is not routinely recommended for acromegaly with macroadenoma.⁵ However, a somatostatin receptor ligand (SRL) or GH receptor antagonist such as pegvisomant may be used as initial adjuvant medical therapy in a patient with significant disease (moderate to severe signs and

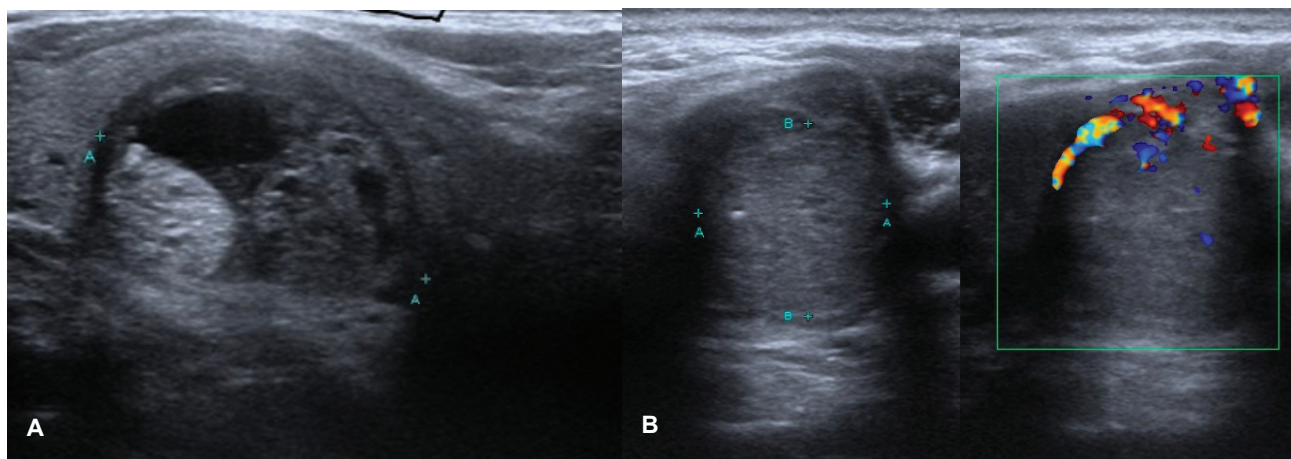


Figure 2. Thyroid ultrasonography. **(A)** mixed cystic and solid nodule with regular margin on the right lobe. **(B)** predominantly solid nodule with internal microcalcifications measuring 3.2 cm x 3.2 cm x 4.6 cm at the lower pole of the left lobe.

symptoms of GH excess without local mass effects) to improve cure rate. Pre-operative long-acting octreotide treatment in patients with invasive pituitary macroadenomas for 6 months improved metabolic, hemodynamic parameters and reduced duration of hospital stay.⁶ By reducing GH hypersecretion, SRLs are efficacious in decreasing tissue overgrowth in the heart and airways, thereby alleviating respiratory and cardiovascular co-morbidities. These were evident in our patient, as seen in the reduction of her IGF-1 and blood sugar levels, improvement in blood pressure and cardiac function, and reduction of severity of OSA leading to eventual discontinuation of continuous positive airway pressure. Tumor size was reduced by 67%, compared to approximately 50% reported in literature (Figure 1C). This reduction in size was accompanied by regression of cavernous sinus invasion, which improved surgical success.

Response to SRL is said to be dependent on tumor consistency and the amount of somatostatin receptor subtype 2 (sst2) expression. Tumors that are densely granulated respond better compared to fibrous ones. Hypointense tumor signal on T2-weighted MRI, which correlate with dense tumor granularity, portend a favorable SRL response, as observed in the patient (Figure 1B). These factors can be used to guide the choice of pharmacotherapy in treating acromegaly.

The control of IGF-1 levels may mitigate the signs, symptoms and complications of acromegaly. Nadir GH is the most important determinant of mortality, followed by blood pressure and heart disease.⁷⁻⁹ Symptom duration and diabetes seem to be less important determinants. Life expectancy becomes similar to the general population when GH levels are under control.^{7,8} Normalization of IGF-1 is also one of the goals of treatment in acromegaly. In a study of 466 acromegaly patients due to pituitary macroadenoma, SRL was able to normalize IGF-1 in 39.9%.⁹ This is mainly due to the downregulation of GH release through the sst2 receptor.

One of the main setbacks of pituitary surgery is the occurrence of post-operative pituitary hormonal failure. In an analysis of complications of transsphenoidal surgery, anterior pituitary insufficiency occurred in 19.4% of patients.¹ This risk, along with limited access to highly competent surgeons, have created a strong interest in medical therapy in acromegaly, with the goal of removing the risk of pituitary failure brought about by surgery.

Fifteen percent of mortality in acromegalic patients are attributed to malignancy. High levels of IGF-1 and IGF-binding protein 3 (IGFBP3) are seen in acromegaly. Activation of IGF-1 receptors causes cell proliferation and growth, whereas IGFBP3 promotes apoptosis. By inducing increased IGF-1 and IGFBP3 levels, excess GH promotes dysregulated cell growth characterized by dynamic signals for cell apoptosis as against cell growth. High GH leads to tissue growth, including the thyroid gland. Thyroid nodules are seen more frequently in acromegaly. Multinodularity and size correlates with duration of high IGF-1.¹⁰ Increased tissue growth suggests malignant transformation of the thyroid nodules, as seen in our patient. Thyroid cancer was found to be the most common type of malignancy in acromegaly.¹¹ Our case report underscores the importance of routine screening by ultrasonography of the thyroid in these patients.

With a tumor size of more than 5 cm, capsular invasion and involvement of central and ipsilateral lymph nodes, our patient had stage IV papillary thyroid cancer (T4aN1bM0) based on the American Joint Committee on Cancer (AJCC) classification. Treatment involved total thyroidectomy with central and left lateral lymph node resection plus remnant ablation with 100 to 200 mCi radioiodine (with post-treatment WBS).¹² Follow-up of papillary thyroid cancer includes monitoring for tumor recurrence in lymph nodes, measurement of thyroglobulin and regular neck ultrasound. Monitoring of differentiated thyroid cancer has moved away from regular WBS following the availability of very sensitive assays for detection of thyroglobulin and high quality neck ultrasonography.

CONCLUSION

Our case demonstrated the successful pre-operative use of octreotide LAR for 6 months, which resulted to remission of acromegaly without any pituitary hormonal failure. While pre-treatment with SRL is not generally recommended at this time, it was able to reduce tumor volume more than what has been commonly reported, and also improved our patient's outcome.¹³ Our case also emphasized the need for close evaluation for thyroid malignancy, aside from surveillance of colonic polyps and cancer. While surgery is the current main treatment of acromegaly, the use of medical therapy, particularly SRL, may achieve remission and improve survival rate. The role of medical therapy in acromegaly for IGF-1 normalization to control concomitant malignancy warrants further research and insight.

Ethical Considerations

Patient consent was obtained before submission of the manuscript.

Statement of Authorship

The author certified fulfillment of ICMJE authorship criteria.

Author Disclosure

The author declared no conflict of interest.

Funding Source

None.

References

- Colao A, Ferone D, Marzullo P, Lombardi G. Systemic complications of acromegaly: Epidemiology, pathogenesis, and management. *Endocr Rev.* 2004;25(1):102-52. PMID: 14769829. <https://doi.org/10.1210/er.2002-0022>.
- Ben-Shlomo A, Melmed S. Clinical review 154: The role of pharmacotherapy in perioperative management of patients with acromegaly. *J Clin Endocrinol Metab.* 2003;88(3):963-8. <https://doi.org/10.1210/jc.2002-020072>.
- Ezzat S, Snyder PJ, Young WF, et al. Octreotide treatment of acromegaly: A randomized, multicenter study. *Ann Intern Med.* 1992;117(9):711-8. PMID: 1416572. <https://doi.org/10.7326/0003-4819-117-9-711>.
- Bevan JS, Atkin SL, Atkinson AB, et al. Primary medical therapy for acromegaly: An open, prospective, multicenter study of the effects of subcutaneous and intramuscular slow-release octreotide on growth hormone, insulin-like growth factor-I, and tumor size. *J Clin Endocrinol Metab.* 2002;87(10):4554-63. PMID: 12364434. <https://doi.org/10.1210/jc.2001-012012>.
- Melmed S, Casanueva F, Cavagnini F, et al. Consensus statement: Medical management of acromegaly. *Eur J Endocrinol.* 2005;153(6):737-40. PMID: 16322377. <https://doi.org/10.1530/eje.1.02036>.
- Shen M, Shou X, Wang Y, et al. Effect of presurgical long-acting octreotide treatment in acromegaly patients with invasive pituitary macroadenomas: A prospective randomized study. *Endocr J.* 2010;57(12):1035-44. PMID: 21099129.
- Freda PU, Wardlaw SL, Post KD. Long-term endocrinological follow-up evaluation in 115 patients who underwent transsphenoidal surgery for acromegaly. *J Neurosurg.* 1998;89(3):353-8. PMID: 9724106. <https://doi.org/10.3171/jns.1998.89.3.0353>.
- Orme SM, McNally RJ, Cartwright RA, Belchetz PE. Mortality and cancer incidence in acromegaly: A retrospective cohort study. United Kingdom Acromegaly Study Group. *J Clin Endocrinol Metab.* 1998;83(8):2730-4. PMID: 9709939. <https://doi.org/10.1210/jcem.83.8.5007>.
- Colao A, Lombardi G. Growth hormone and prolactin excess. *Lancet.* 1998;352(9138):1455-61. PMID: 9808008. [https://doi.org/10.1016/S0140-6736\(98\)03356-X](https://doi.org/10.1016/S0140-6736(98)03356-X).
- Katznelson L, Laws ER Jr, Melmed S, et al. Acromegaly: An endocrine society clinical practice guideline. *J Clin Endocrinol Metab.* 2014;99(11):3933-51. PMID: 25356808. <https://doi.org/10.1210/jc.2014-2700>.
- Dagdelen S, Cinar N, Erbas T. Increased thyroid cancer risk in acromegaly. *Pituitary.* 2014;17(4):299-306. PMID: 23836362. <https://doi.org/10.1007/s11102-013-0501-5>.
- Haugen BR, Alexander EK, Bible KC, et al. 2015 American Thyroid Association management guidelines for adult patients with thyroid nodules and differentiated thyroid cancer: The American Thyroid Association Guidelines Task Force on thyroid nodules and differentiated thyroid cancer. *Thyroid.* 2016;26(1):1-133. PMID: 26462967. PMID: PMC4739132. <https://doi.org/10.1089/thy.2015.0020>.
- Carlsen SM, Lund-Johansen M, Schreiner T, et al. Preoperative octreotide treatment in newly diagnosed acromegalic patients with macroadenomas increases cure short-term postoperative rates: a prospective, randomized trial. *J Clin Endocrinol Metab.* 2008;93(8):2984-90. PMID: 18492760. <https://doi.org/10.1210/jc.2008-0315>.

Authors are required to accomplish, sign and submit scanned copies of the JAFES Author Form consisting of: (1) Authorship Certification, that all the requirements for authorship have been met by each author, and that the final version of the manuscript has been read and approved by all authors; (2) the Author Declaration, that the article represents original material that is not being considered for publication or has not been published or accepted for publication elsewhere; (3) the Statement of Copyright Transfer [accepted manuscripts become the permanent property of the JAFES and are licensed with an Attribution-Share Alike-Non-Commercial Creative Commons License. Articles may be shared and adapted for non-commercial purposes as long as they are properly cited]; and the ICMJE form for Disclosure of Potential Conflicts of Interest. For original articles, authors are required to submit a scanned copy of the Ethics Review Approval of their research as well as registration in trial registries as appropriate. For manuscripts reporting data from studies involving animals, authors are required to submit a scanned copy of the Institutional Animal Care and Use Committee approval. For Case Reports or Series, and Images in Endocrinology, consent forms, are required for the publication of information about patients; otherwise, authors declared that all means have been exhausted for securing such consent. Articles and any other material published in the JAFES represent the work of the author(s) and should not be construed to reflect the opinions of the Editors or the Publisher.