

# Long-term outcomes of sigmoid vaginoplasty in patients with disorder of sexual development – our experience

Ved Bhaskar, Rahul J. Sinha, Seema Mehrotra, C. N. Mehrotra, Vishwajeet Singh

Department of Urology, King George's Medical University, Lucknow, Uttar Pradesh, India

## Abstract

**Introduction:** To report our experience with sigmoid vaginoplasty in patients with different forms of disorder of sexual development and their long-term follow-up.

**Materials and Methods:** This is a retrospective study of patients who underwent sigmoid vaginoplasty between July 2004 and June 2015 at our center. Follow-up included a physical examination to assess vaginal length and width, cosmetic appearance of the neovagina, and occurrence of any complications.

**Results:** The current study included eight patients with mean age 19.5 years. The mean operative time was 164 min. No significant intraoperative or immediate postoperative complications occurred. Follow-up period ranges from 21 months to 12 years with mean of 7.5 years. In all patients, the neovagina was found to have a satisfactory cosmetic appearance. Seven patients are sexually active and satisfied.

**Conclusion:** Sigmoid vaginoplasty is safe and acceptable procedure in patients having vaginal agenesis. Sigmoid vaginoplasty has acceptable cosmetic results and complication rate.

**Keywords:** Disorder of sexual development, neovagina, sigmoid vaginoplasty

**Address for correspondence:** Dr. Ved Bhaskar, Department of Urology, King George's Medical University, Lucknow, Uttar Pradesh, India.

E-mail: ved2203@gmail.com

**Received:** 23.05.2017, **Accepted:** 04.09.2017

## INTRODUCTION

Neovagina creation may be required for vaginal agenesis found in cases of disorders of sexual development (DSD). Mayer-Rokitansky-Kuster-Hauser syndrome (MRKH) is the most common cause of vaginal absence. It involves vaginal agenesis [Figure 1], uterine tissue remnants and normal ovaries. Complete and partial androgen insensitivity syndrome is the other common variant of DSD which result in short vagina in the presence of male gonads [Figure 2].

The ideal method of vaginal replacement should provide a vaginal substitute with a vault of sufficient size, adequate

introital opening, and a cosmetically acceptable external appearance with minimal morbidity and excellent long-term function. Proper counseling is of utmost importance in these patients. These patients face huge psychological stress because they are unable to have successful sexual intercourse or bear children.

Successful sexual intercourse should be the primary end point when choosing the method for vaginal substitution. The use of bowel segments for vaginoplasty has been shown to provide excellent results without the necessity of prolonged dilatation. Few studies have reported long-term results. We present our experience of 12 years in 8 patients

This is an open access journal, and articles are distributed under the terms of the Creative Commons Attribution-NonCommercial-ShareAlike 4.0 License, which allows others to remix, tweak, and build upon the work non-commercially, as long as appropriate credit is given and the new creations are licensed under the identical terms.

**For reprints contact:** reprints@medknow.com

**How to cite this article:** Bhaskar V, Sinha RJ, Mehrotra S, Mehrotra CN, Singh V. Long-term outcomes of sigmoid vaginoplasty in patients with disorder of sexual development – our experience. Urol Ann 2018;10:185-90.

Access this article online	
Quick Response Code:	Website: www.urologyannals.com
	DOI: 10.4103/UA.UA_88_17

who underwent bowel vaginoplasty with emphasis on their sexual and social outcomes.

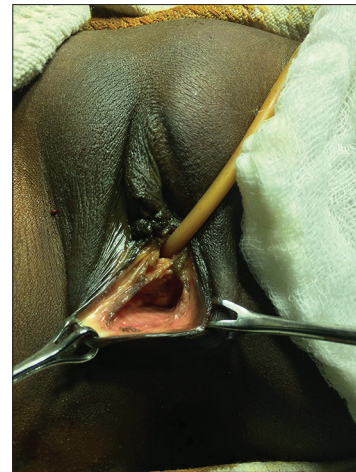## MATERIALS AND METHODS

This is a retrospective study of patients who underwent sigmoid vaginoplasty between July 2004 and June 2015 at our center. It includes 8 patients of which 5 had Mullerian aplasia, 2 had complete androgen insensitivity syndrome, and 1 patient was previous failed vaginoplasty done elsewhere for treatment of vaginal aplasia.

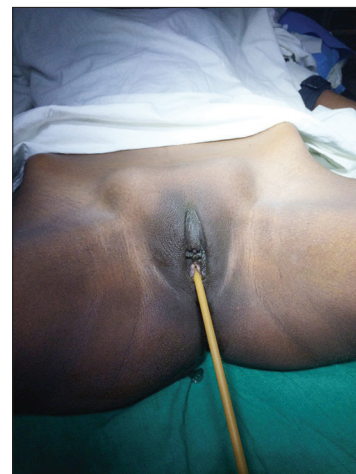All patients underwent careful history taking and physical examination. Approximate length of the vagina was assessed by introducing an infant feeding tube. Preoperative work up included physical examination, abdominal and pelvic ultrasonography, endocrinological assessment and karyotyping. Magnetic resonance imaging was performed in cases in which the ultrasound description was inconclusive. Informed consent, after explaining the potential benefits and risks of sigmoid vaginoplasty and the surgical or nonsurgical alternatives to create neovagina, was obtained from all the patients and/or their parents. All patients underwent sigmoid vaginoplasty under general anesthesia after antibiotic and mechanical bowel preparation. It was performed by a single surgeon (VS) who has assisted and independently performed several such surgeries.

Peritoneal cavity was entered through Pfannenstiel incision. Excision of gonads was done in patients of testicular feminizing syndrome [Figure 3]. Approximately, 10–15 cm long segment of sigmoid colon was mobilized on its vascular pedicle [Figure 4]. The continuity of colon was restored by a single layer end-to-end anastomosis using 3-0 absorbable sutures. The proximal end of the isolated segment of sigmoid was closed in 2 layers and fixed to sacral promontory. H-shaped incision was given at the proposed vaginal site for reconstruction. Lower end of the sigmoid segment was brought down to the perineum by creating a tunnel between the bladder anteriorly and rectum posteriorly. The edges of the neovaginal pit were sutured to the distal end of the sigmoid segment [Figure 5]; a Vaseline soaked vaginal mold was kept in the lumen for 48 h [Figure 6]. Foley catheter was inserted into the urinary bladder for 3–4 days. Postoperatively, the patients were explained self-care of neovagina by daily irrigation for cleaning of mucus.

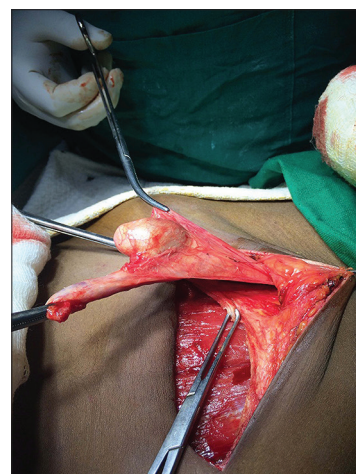
Follow-up included a physical examination to assess the length and width of neovagina, cosmetic appearance of the neovagina and occurrence of any complications.



**Figure 1:** Stenotic vagina in patient with disorder of sexual development

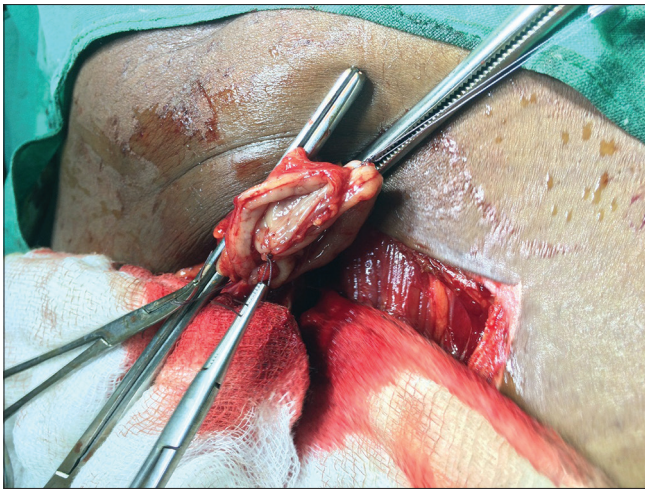


**Figure 2:** Bilateral gonads in inguinal region in patient with testicular feminizing syndrome

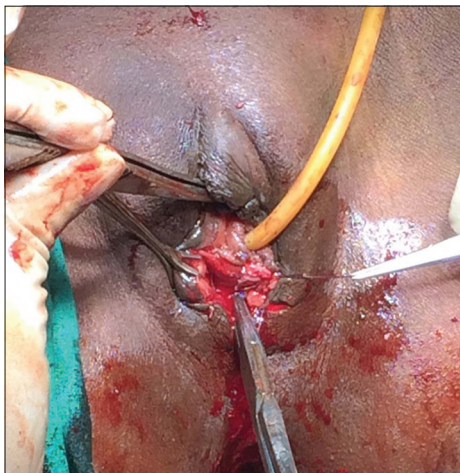


**Figure 3:** Gonadectomy

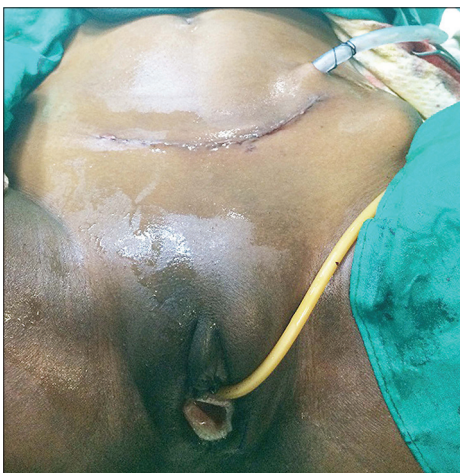A nonstandardized questionnaire was used to assess the physical, functional, and sexual outcomes of these patients [Table 1].



**Figure 4:** Mobilization of sigmoid segment on its vascular pedicle



**Figure 5:** Sigmoid edges sutured to vaginal pit



**Figure 6:** Vaginal mold inserted for 48 h

## RESULTS

The results are summarized in Table 2. Five patients with mullerian aplasia had karyotype of 46XX.

**Table 1: Self assessment questionnaire**

Question number	Questions	Yes	No
1	Are you satisfied with physical appearance of your neovagina?		
2	Do you require routine cleaning of neovagina?		
3	Do you have regular sexual intercourse?		
4	Do you need lubricating agent during sexual activity?		
5	Did you experience any pain during sexual activity?		
6	Do you have any episode of bleeding per neovaginal during sexual activity?		
7	Do you have any alteration in bowel habits (e.g., constipation) postsurgery?		
8	Are you satisfied with your sexual life?		

**Table 2: Results**

Patients characteristics	Variables
Total number of patients	8
Diagnosis-MRKH	5
Diagnosis-testicular feminizing syndrome	2
Naive cases	7
Previously failed case	1
Mean operative time (min)	164 (140-205)
Estimated mean blood loss (mL)	210 (150-240)
Mean hospital stay (days)	8.5 (7-10)
Major complications	0
Bowel-related complaints	0
Follow-up	7.5 years (21 months to 12 years)

MRKH: Mayer-Rokitansky-Kuster-Hauser syndrome

Hormonal profile (follicular stimulating hormone, luteinizing hormone, and estradiol) was normal according to the age- and sex-matched reference range. On ultrasonography, rudimentary or absent uterus was found. Two patients presented with primary amenorrhea and were diagnosed as complete androgen insensitivity syndrome, their karyotype was 46XY. Both were reared as females. Their gonads were palpable on physical examination in inguinal region or labia majora. They had elevated serum testosterone levels in comparison to normal age- and sex-matched reference range. The remaining patient had a history of previous failed vaginoplasty. Her physical examination revealed a stenotic, contracted vagina secondary to vaginoplasty using skin graft elsewhere.

Mean operative time was 164 min (range 140–205 min). No significant intraoperative or immediate postoperative complications occurred. The patients were discharged within 7–10 days. Their follow-up period ranged from 21 months to 12 years with mean of 7.5 years. Their neovagina was found to have an excellent cosmetic appearance. Seven patients are sexually active and satisfied. Mild dyspareunia was reported by 2 patients initially but disappeared with time. One patient developed mild stenosis which was treated with serial dilatations.

Routine cleaning was required by one patient initially due to excess mucus production while another one required the use of lubricating agent during sexual intercourse. None of the patients have developed long-term complications such as prolapse, colitis or adenocarcinoma or alteration of bowel habits as per their latest follow-up.

## DISCUSSION

Vaginal agenesis occurs in MRKH syndrome in approximately 1 in 5,000 live female births; it results from failure of the sinovaginal bulbs to develop and form the vaginal plate. Although first described by Mayer and then Rokitansky in the early 19<sup>th</sup> century, Kuster and Hauser have defined the renal and skeletal anomalies present in few of these individuals.<sup>[1]</sup> The diagnosis is often made during adolescence when the patients present with primary amenorrhea and normal puberty. These patients have 46, XX karyotype, female external genitalia, and normal ovarian function, explaining the delay in their diagnosis.

Testicular feminizing syndrome is another common form of DSD where though the patient has a male genetic make-up (karyotype XY), the phenotype is that of female and they are usually reared as females. These patients have a shallow vagina and complete absence of mullerian duct structures along with the presence of male gonads.

Many methods of vaginal reconstruction are reported. A nonoperative technique which is known as Frank procedure may be used when a vaginal dimple or pouch is present; it involves progressive mechanical dilation using graduated hard dilators to create a progressive invagination of the vaginal dimple.<sup>[2]</sup> The disadvantage of this method is that it is time-consuming and causes persistent discomfort which often results in noncompliance. It is not recommended in patients with only skin dimple as they have poorer results.<sup>[3]</sup>

Surgical techniques include McIndoe procedure which involves insertion of a mold covered with split thickness skin graft taken from the buttocks into the created neo-vaginal space followed by postoperative vaginal dilation.<sup>[4]</sup> Others have used full thickness skin graft from the buttocks or skin flap based on labia majora,<sup>[5]</sup> peritoneum from the Douglas pouch,<sup>[6]</sup> amnion,<sup>[7]</sup> oxidized regenerated cellulose fabric,<sup>[8]</sup> and muscle flaps.<sup>[9]</sup> The high percentage of vaginal stenosis, inadequate vaginal length, vaginal dryness, and dyspareunia was reported as drawbacks of these techniques.<sup>[10]</sup> The

incidence of dyspareunia directly correlates with the length of the neo-vagina, with an incidence of 100% if the vaginal length is <6 cm.<sup>[11]</sup> Vecchiotti procedure was originally developed in Italy as a simpler way to create a neovagina.<sup>[12,13]</sup> It is based on the concept of surgically placed traction system for accelerated dilation of the rudimentary vagina using a vaginal bead or “olive.” Originally devised as an open abdominal technique, this surgery can now be performed laparoscopically. However, these modalities require long-term vaginal dilatation and stenting by a vaginal mold at night which affects the patient’s psychological condition; these modalities are unsuitable in pediatric group.<sup>[10]</sup>

The use of bowel segment for vaginoplasty was reported first in 1904 by Baldwin. His description included isolation of a U-shaped sigmoid colon that was anastomosed to the perineum. This procedure had high mortality and was abandoned in the early 1970s.<sup>[14]</sup> Goligher reported on a small but positive experience using a pedicled portion of the sigmoid colon for constructing a neovagina in the early 1980s,<sup>[15]</sup> while Hanna was the first to report on purely pediatric experience using an ileal pouch in 1987.<sup>[16]</sup> Although any part of the bowel including colon, caecum or ileum may be used for bowel vaginoplasty but sigmoid colon is preferred because it has the following advantages according to Rajimwale *et al.*:<sup>[17]</sup> (1) it is self-lubricating; (2) mucus production is less of a problem than with the use of small bowel; (3) it grows with the child when used before puberty; (4) there is minimal risk of stenosis; (5) it is close to the perineum; (6) it can easily be mobilized on its vascular pedicle; and (7) it does not require molds or stenting. Sigmoid vaginoplasty thus provides a cosmetically acceptable neovagina with a good length, natural lubrication, and obviating the need for mold and/or dilatation. We prefer sigmoid neovagina due to the advantages mentioned above.

In a recent review by McQuillan and Grover, he mentions that bowel vaginoplasty has been the most commonly performed procedure till date and it gives the longest vaginal length (average length 12.87 cm). Most of the articles reviewed are case reports or series and hence any conclusive data regarding the best method of treatment is still a matter of debate.<sup>[18]</sup>

In our series, no intraoperative or intestinal complications occurred. Intestinal complications are rarely reported with sigmoid vaginoplasty. Good preoperative bowel preparation, previous experience with bowel surgery and meticulous suturing are prerequisites to avoid such complications. In our department, we use different bowel segments for

neobladder formation and other procedures on regular basis. Hence, we are well versed with bowel surgery.<sup>[19]</sup>

Although excessive mucus production has been reported in the majority, it decreases with time and is not a major concern for most patients.<sup>[20]</sup> In our series, excessive mucus production was reported by one patient in perioperative period which required regular cleaning, but it subsided with time.

Mucosal or entire neovaginal prolapse has been reported, with an incidence of up to 14%.<sup>[21]</sup> However, we did not encounter this complication as we regularly perform sigmoidopexy by fixing the proximal sigmoid segment to the sacral promontory. Variable incidence of introital stenosis has been reported with sigmoid vaginoplasty ranging from 8.1% to 19.3%.<sup>[21,22]</sup> The possibility of anastomotic site stricture can be decreased by selecting a bowel segment of good blood supply and length that can be mobilized and pulled easily to the perineum without tension, creation of a proper space between bladder and rectum and meticulous anastomosis at the hymen.<sup>[22]</sup>

The need for regular vaginal dilatation after sigmoid vaginoplasty is debatable. When we analyzed our data, we found that only one patient who was not sexually active developed stenosis and needed serial dilatation. Therefore, we do not recommend it routinely but propose regular postoperative dilatation (at least once/week) of the neo-vagina till the patient is sexually active is commenced.

None of the patients in our series had major postoperative or long-term complications. However, rare long term complications merit discussion. Ulcerative colitis has been reported in neovagina in few patients. Patients with hereditary polyposis syndromes, such as familial polyposis, Gardner syndrome, and nonpolypous colon cancer may develop polyps or neoplasia in the diverted sigmoid colon.<sup>[23]</sup> Diversion colitis, a rare idiopathic disorder may occur after isolation of intestinal segment from the fecal stream.<sup>[24]</sup> However, these diseases are uncommon in India and may be the reason for their absence in our patients.

We recommend sigmoid vaginoplasty as the preferred treatment modality because of its large lumen, thick wall resistant to trauma, adequate secretion allowing lubrication, not necessitating prolonged dilatation, and short recovery time. The limitation of this study is its retrospective design and small number of patients.

## CONCLUSION

In our experience, sigmoid vaginoplasty is safe and acceptable procedure to treat the patients with vaginal

agenesis. It has acceptable cosmetic results and minimal complication rate.

## Financial support and sponsorship

Nil.

## Conflicts of interest

There are no conflicts of interest.

## REFERENCES

- Rink RC, Kaefer M. Surgical management of intersexuality, cloacal malformation, and other abnormalities of the genitalia in girls. In: Walsh PC, Retik AB, Vaughan ED Jr., Wein AJ, editors. *Campbell's Urology*. 8<sup>th</sup> ed., Vol. 3. Ch. 69. Philadelphia: WB Saunders Company; 2002. p. 2431-6.
- Frank RT. The formation of an artificial vagina without operation. *Am J Obstet Gynecol* 1938;35:1053-5.
- Hensle TW, Gjertson CK, Reiley EA. Vaginal reconstruction: A review. *AUA Update Series* 2005;24:29.
- Mcindoe A. The treatment of congenital absence and obliterative conditions of the vagina. *Br J Plast Surg* 1950;2:254-67.
- Sadove RC, Horton CE. Utilizing full-thickness skin grafts for vaginal reconstruction. *Clin Plast Surg* 1988;15:443-8.
- Sheth NP, Chainani MS, Sheth SN. Vaginoplasty from peritoneal tube of Douglas' pouch for congenital vaginal agenesis. *Eur J Pediatr Surg* 2003;13:213-4.
- Ashworth MF, Morton KE, Dewhurst J, Lilford RJ, Bates RG. Vaginoplasty using amnion. *Obstet Gynecol* 1986;67:443-6.
- Jackson ND, Rosenblatt PL. Use of interced absorbable adhesion barrier for vaginoplasty. *Obstet Gynecol* 1994;84:1048-50.
- Joseph VT. Pudendal-thigh flap vaginoplasty in the reconstruction of genital anomalies. *J Pediatr Surg* 1997;32:62-5.
- Nowier A, Esmat M, Hamza RT. Surgical and functional outcomes of sigmoid vaginoplasty among patients with variants of disorders of sex development. *Int Braz J Urol* 2012;38:380-6.
- de Souza AZ, Maluf M, Perin PM, Maluf Filho F, Perin LF. Surgical treatment of congenital uterovaginal agenesis: Mayer-Rokitansky-Küster-Hauser syndrome. *Int Surg* 1987;72:45-7.
- Fedele L, Bianchi S, Frontino G, Fontana E, Restelli E, Bruni V, *et al.* The laparoscopic vecchietti's modified technique in Rokitansky syndrome: Anatomic, functional, and sexual long-term results. *Am J Obstet Gynecol* 2008;198:377.e1-6.
- Veronikis DK, McClure GB, Nichols DH. The vecchietti operation for constructing a neovagina: Indications, instrumentation, and techniques. *Obstet Gynecol* 1997;90:301-4.
- Baldwin JF. XIV. The formation of an artificial vagina by intestinal transplantation. *Ann Surg* 1904;40:398-403.
- Goligher JC. The use of pedicled transplants of sigmoid or other parts of the intestinal tract for vaginal construction. *Ann R Coll Surg Engl* 1983;65:353-5.
- Hanna MK. Vaginal construction. *Urology* 1987;29:272-5.
- Rajimwale A, Furness PD 3<sup>rd</sup>, Brant WO, Koyle MA. Vaginal construction using sigmoid colon in children and young adults. *BJU Int* 2004;94:115-9.
- McQuillan SK, Grover SR. Dilatation and surgical management in vaginal agenesis: A systematic review. *Int Urogynecol J* 2014;25:299-311.
- Singh V, Yadav R, Sinha RJ, Gupta DK. Prospective comparison of quality-of-life outcomes between ileal conduit urinary diversion and orthotopic neobladder reconstruction after radical cystectomy: A statistical model. *BJU Int* 2014;113:726-32.
- Kapoor R, Sharma DK, Singh KJ, Suri A, Singh P, Chaudhary H, *et al.* Sigmoid vaginoplasty: Long-term results. *Urology* 2006;67:1212-5.

21. Parsons JK, Gearhart SL, Gearhart JP. Vaginal reconstruction utilizing sigmoid colon: Complications and long-term results. *J Pediatr Surg* 2002;37:629-33.
22. Imperato E, Alfei A, Aspesi G, Meus AL, Spinillo A. Long-term results of sigmoid vaginoplasty in a consecutive series of 62 patients. *Int Urogynecol J Pelvic Floor Dysfunct* 2007;18:1465-9.
23. Froese DP, Haggitt RC, Friend WG. Ulcerative colitis in the autotransplanted neovagina. *Gastroenterology* 1991;100:1749-52.
24. Toolenaar TA, Freundt I, Huikeshoven FJ, Drogendijk AC, Jeekel H, Chadha-Ajwani S, *et al.* The occurrence of diversion colitis in patients with a sigmoid neovagina. *Hum Pathol* 1993;24:846-9.