



Imaging Spectrum of Neurological Manifestations of Hemophagocytic Lymphohistiocytosis in Pediatrics: A Case Series

Geethapriya Sivaramalingam¹ Afiya VK¹ Bagyam Raghavan¹ Jayaraj Govindaraj¹

¹Department of Radiology, Apollo Speciality Hospital, Chennai, Tamil Nadu, India

Address for correspondence Afiya VK, DNB (Radiodiagnosis), Department of Radiology, Apollo Cancer Institutes, Padma Complex, Anna Salai, Chennai 600035, Tamil Nadu, India (e-mail: afiyaaafi4@gmail.com).

Indian J Radiol Imaging 2023;33:548–554.

Abstract

Hemophagocytic lymphohistiocytosis (HLH) is an uncommon condition, which can result either from a primary genetic abnormality affecting children or secondary to various conditions like malignancy or infection predominantly in adults. HLH is associated with immune dysregulation, resulting in an uncontrolled overproduction and infiltration of lymphocytes and histiocytes. The infiltration predominantly involves liver, spleen, lymph nodes, and central nervous system. Neuroimaging features on magnetic resonance imaging are highly nonspecific and variable. The most typical findings include periventricular white matter hyperintensities and diffuse atrophy. Ring or nodular enhancing or nonenhancing focal parenchymal lesions may be seen. Here, we present three pediatric cases of primary HLH with a wide spectrum of imaging findings involving cerebral and cerebellar cortex, white matter, deep gray matter, and brain stem. The findings in these patients range from small nonenhancing hemorrhagic lesions and enhancing small lesions to ill-defined mass with mass effect and midline shift. Lesions in deep gray matter including thalamus, basal ganglia, and also brain stem in HLH are rarely described in literature. Early diagnosis of HLH and timely management can improve the course of the disease.

Keywords

- ▶ hemophagocytic lymphohistiocytosis
- ▶ neuroimaging
- ▶ pediatric

Introduction

Hemophagocytic lymphohistiocytosis (HLH) is a rare, non-malignant, life-threatening disorder, due to excessive immune system activation. HLH typically affects infants and young children, though it may affect any age group. HLH commonly affects the liver, spleen, lymph nodes, bone marrow, lungs, and central nervous system (CNS); while it very rarely affects musculoskeletal system and skin. Approximately 30% of patients with HLH show neurological abnormalities.¹

This case series includes three pediatric patients with primary HLH, who presented with CNS manifestations, which were confirmed by genetic analysis and HLH 2004 criteria.

Case 1

A 6-year-old boy presented with recurrent fever, hepatosplenomegaly, pancytopenia, and bone marrow aspiration showing significant hemophagocytosis (▶ **Figs. 1–3**). HLH genetic testing showed familial HLH. Magnetic resonance imaging (MRI) brain showed CNS involvement and was treated with etoposide and intrathecal methotrexate. After 3 months of treatment, allogeneic hematopoietic stem cell transplantation (HSCT) was done. Pre-HSCT workup MRI showed regression of most of the findings. Six months post-HSCT follow-up MRI showed further regression of the lesions.

article published online
August 21, 2023

DOI <https://doi.org/10.1055/s-0043-1772495>.
ISSN 0971-3026.

© 2023. Indian Radiological Association. All rights reserved.
This is an open access article published by Thieme under the terms of the Creative Commons Attribution-NonDerivative-NonCommercial-License, permitting copying and reproduction so long as the original work is given appropriate credit. Contents may not be used for commercial purposes, or adapted, remixed, transformed or built upon. (<https://creativecommons.org/licenses/by-nc-nd/4.0/>)
Thieme Medical and Scientific Publishers Pvt. Ltd., A-12, 2nd Floor, Sector 2, Noida-201301 UP, India

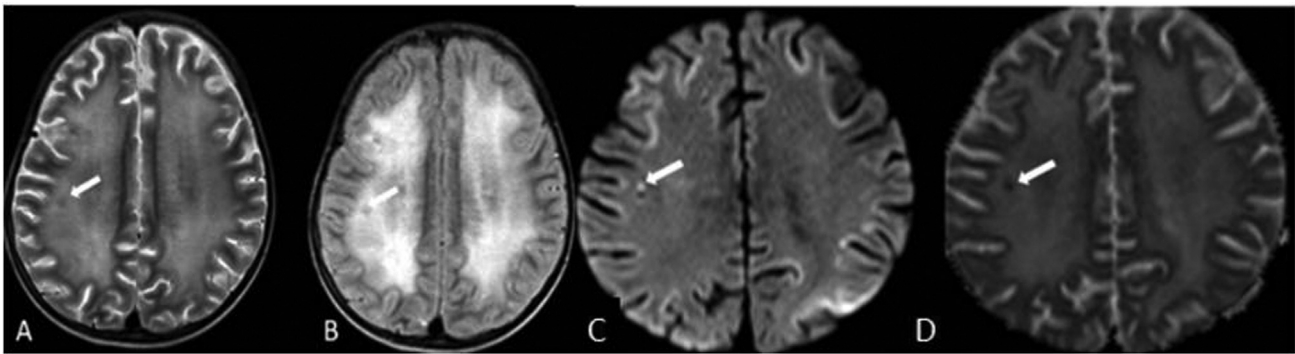


Fig. 1 Case 1: Diffuse increased signal intensity is seen in periventricular white matter of bilateral cerebral hemispheres on (A) axial T2-weighted (T2W) and (B) axial fluid-attenuated inversion recovery (FLAIR) imaging. (C) Axial diffusion-weighted imaging and (D) axial apparent diffusion coefficient (ADC) show restricted diffusion with low ADC values in subcortical U fibers of bilateral frontal, parietal, and occipital cortices with corresponding increased signal intensity on FLAIR imaging. White arrow shows T2W and FLAIR hypointense parenchymal lesion showing restricted diffusion with low ADC values in right centrum semiovale.

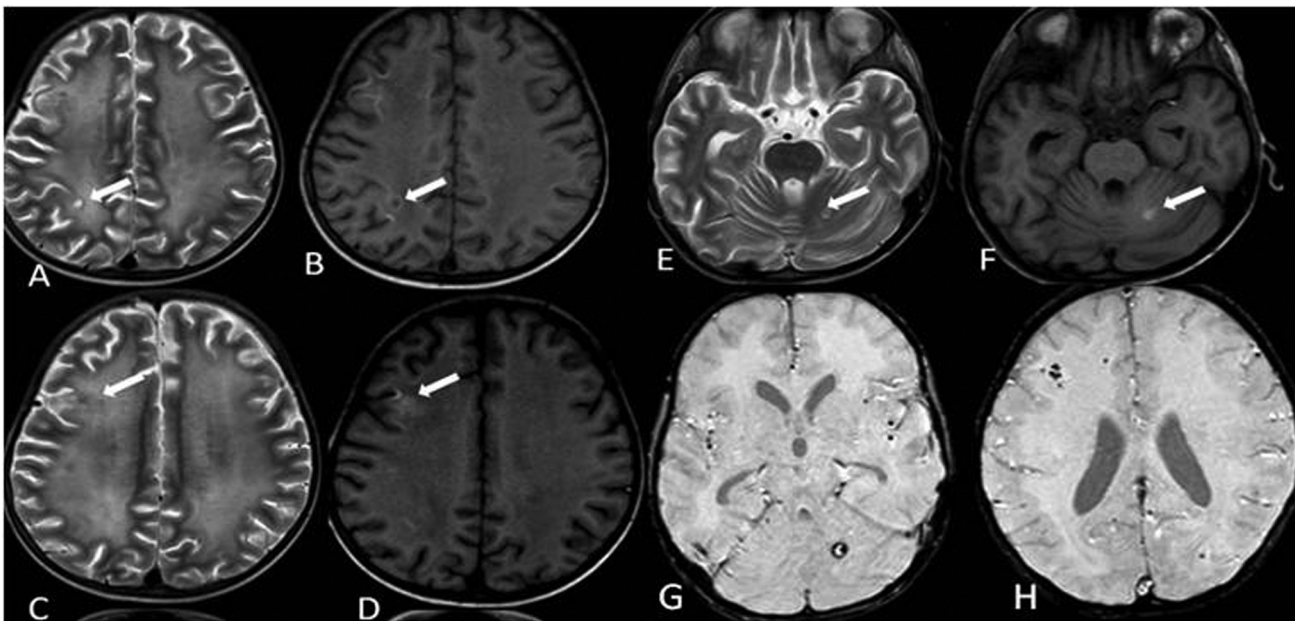


Fig. 2 Case 1: (A) Axial T2-weighted (T2W) and (B) axial T1W showing T2 hyperintense lesion with peripheral hypointensity in right posterior centrum semiovale (white arrow). (C) Axial T2W and (D) axial T1W showing T2 hypointense and T1 hyperintense lesion in right middle frontal gyrus (white arrow). (E) Axial T2W and (F) axial T1W showing hyperintense lesion in left cerebellar hemisphere (white arrow). (G) and (H) Axial susceptibility-weighted imaging showing foci of signal loss on gradient imaging within the lesions, suggestive of hemorrhagic residue.

Case 2

A 7-year-old boy presented with history of multiple episodes of fever, infections, refractory seizures, pancytopenia, and hepatosplenomegaly (► Fig. 4). Genetic testing showed RAB 27 gene mutation; thus, diagnosis of Griscelli syndrome-type 2 was made. Cerebrospinal fluid (CSF) analysis showed few lymphocytes. MRI brain was performed to evaluate CNS involvement of HLH. The patient underwent HSCT and improved symptomatically.

Case 3

A 6-year-old girl, a diagnosed case of congenital HLH with STX mutation, underwent MRI as a part of a pre-HSCT workup (► Figs. 5 and 6). The girl underwent haploidentical

HSCT and later presented with fever, pansinusitis, and sepsis on day 15 post-HSCT. Invasive fungal sinusitis was diagnosed and MRI brain with orbits was performed.

Discussion

HLH is a multisystem disorder with aggressive proliferation of activated macrophages and histiocytes, commonly affecting the CNS. CNS imaging findings in HLH may mimic other disease entities and can be a diagnostic challenge. In our study, we had a wide spectrum of neuroimaging findings (► Table 1).

Pathophysiology

HLH is characterized by uncontrolled activation of macrophages, which accumulates in tissues and leads to organ damage by excessive production of cytokines. Primary HLH is

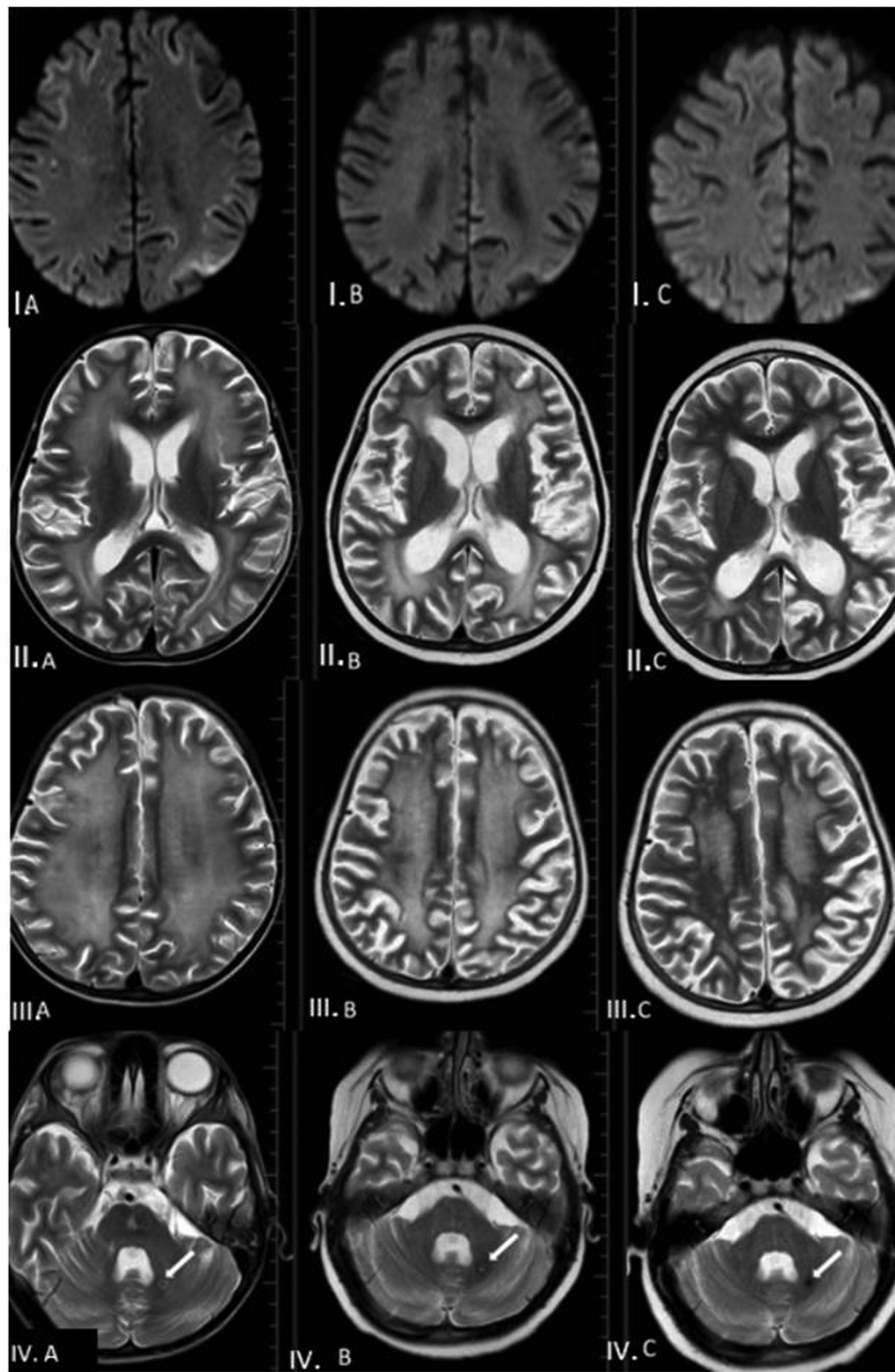


Fig. 3 Case 1: (IA) Initial magnetic resonance imaging (MRI) showing restricted diffusion in subcortical U fibers of bilateral frontal, parietal and occipital cortices, (IB) Pre-hematopoietic stem cell transplantation (HSCT) MRI showing regression of the same, (IC) MRI post 6 months HSCT showing resolution of the same. (IIA) Initial MRI showing normal ventricles, sylvian fissures, cortical sulci and cisternal spaces, (IIB) Pre-HSCT MRI and (IIC) MRI post 6 months HSCT showing minimal dilatation of all ventricles, sylvian fissures, cortical sulci and cisternal spaces. (IIIA) Initial MRI showing increased signal intensity on T2-weighted and fluid-attenuated inversion recovery imaging in periventricular white matter of bilateral cerebral hemispheres. (IIIB), Pre-HSCT MRI and (IIIC) MRI post 6 months HSCT showing regression of the same. (IVA) Initial MRI showing hemorrhagic lesion in left cerebellum (white arrow), (IVB) Pre-HSCT MRI and (IVC) MRI post 6 months HSCT showing further regression of the same.

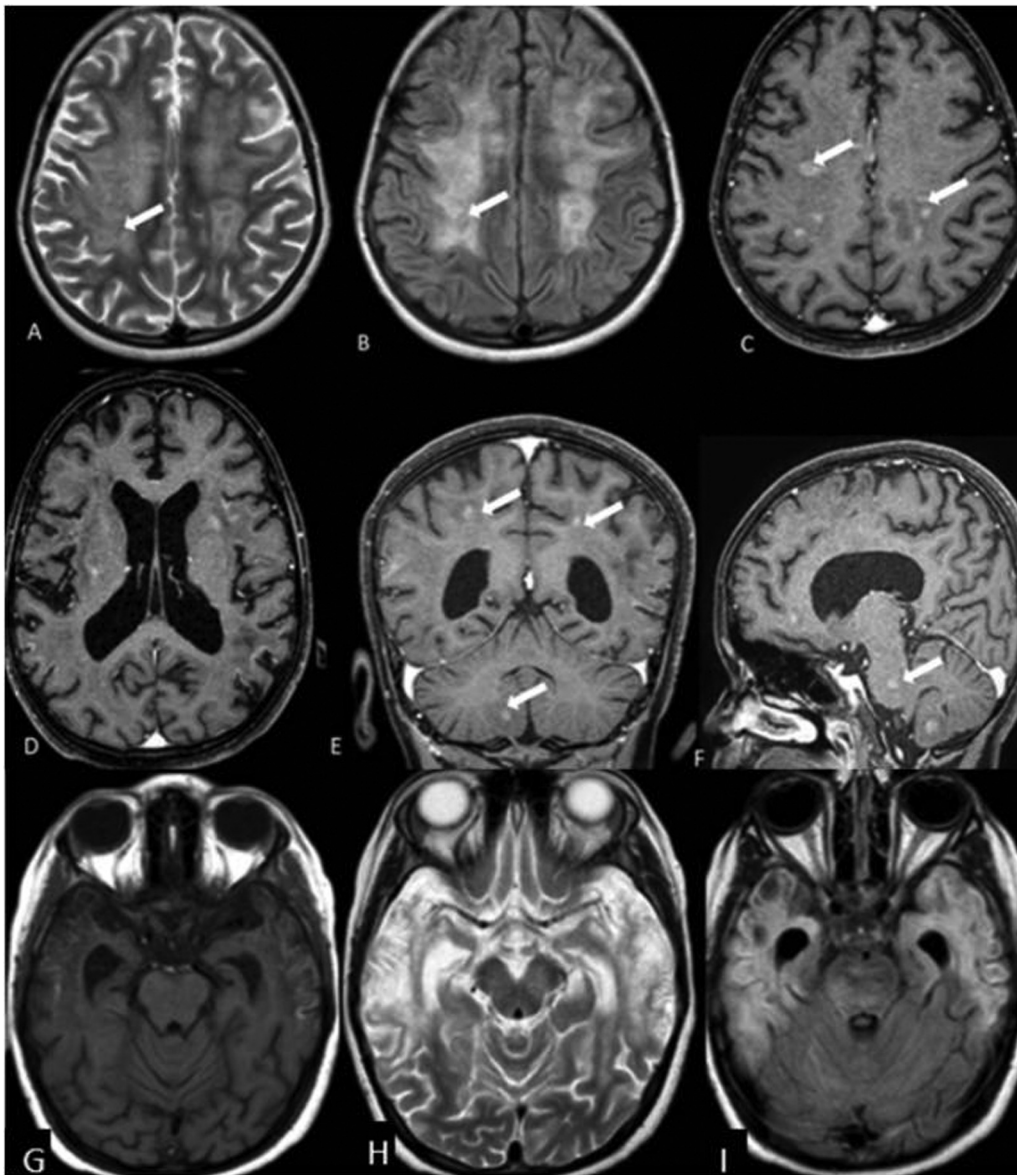


Fig. 4 Case 2: (A) Axial T2 and (B) axial fluid-attenuated inversion recovery (FLAIR), (C) and (D) axial postcontrast T1, (E) coronal postcontrast T1, and (F) sagittal postcontrast T1 showing ill-defined heterogeneous lesions involving bilateral fronto-parieto-occipital cortices, bilateral subcortical, and deep periventricular white matter, bilateral basal ganglia, corona radiata and centrum semiovale, pons, brain stem, and right cerebellum (white arrow). The lesions appear heterointense on T2 and FLAIR images. No signal loss is seen on gradient imaging (not shown here). On contrast administration nodular enhancement is seen. No mass effect or midline shift is seen. (G) Axial T1W T1-weighted (T1W), (H) axial T2W, and (I) axial FLAIR showing cystic encephalomalacia with gliosis, volume loss, and cortical laminar necrosis in bilateral temporal gyri.

an autosomal recessive condition with defective genes involved in cytotoxic granule exocytosis. Primary HLH can be associated with immunodeficiency syndromes like Griscelli syndrome type-2, Chediak-Higashi syndrome, Hermansky-Pudlak syndrome type-2, and X-linked proliferative syndrome type-2.² Secondary HLH is associated with infection, malignancy, rheumatologic, or iatrogenic (transplantation, immune suppression, immune activation).³

Neuropathological stages of HLH consist of three stages correlating with the severity of the disease and the amount of lymphocytic and histiocytic infiltration.⁴ Stage 1 is leptomeningeal infiltration. Stage 2 is additional involvement of the adjacent brain parenchyma with perivascular infiltrations. Stage 3 is the final stage of massive parenchy-

mal infiltration with demyelination, parenchymal necrosis, and calcification.

Clinical Features

The most common presentation includes fever, pancytopenia, and hepatosplenomegaly. The most commonly affected systems include hematologic, hepatic (hepatitis, coagulopathy), central nervous (seizures, altered mental status), and pulmonary (► Table 2).

Diagnostic Criteria

The diagnosis of HLH is based on the presence of molecular diagnosis of an HLH gene mutation or by the presence of 5 of 8 criteria from the HLH-2004 trial (► Table 3).⁵

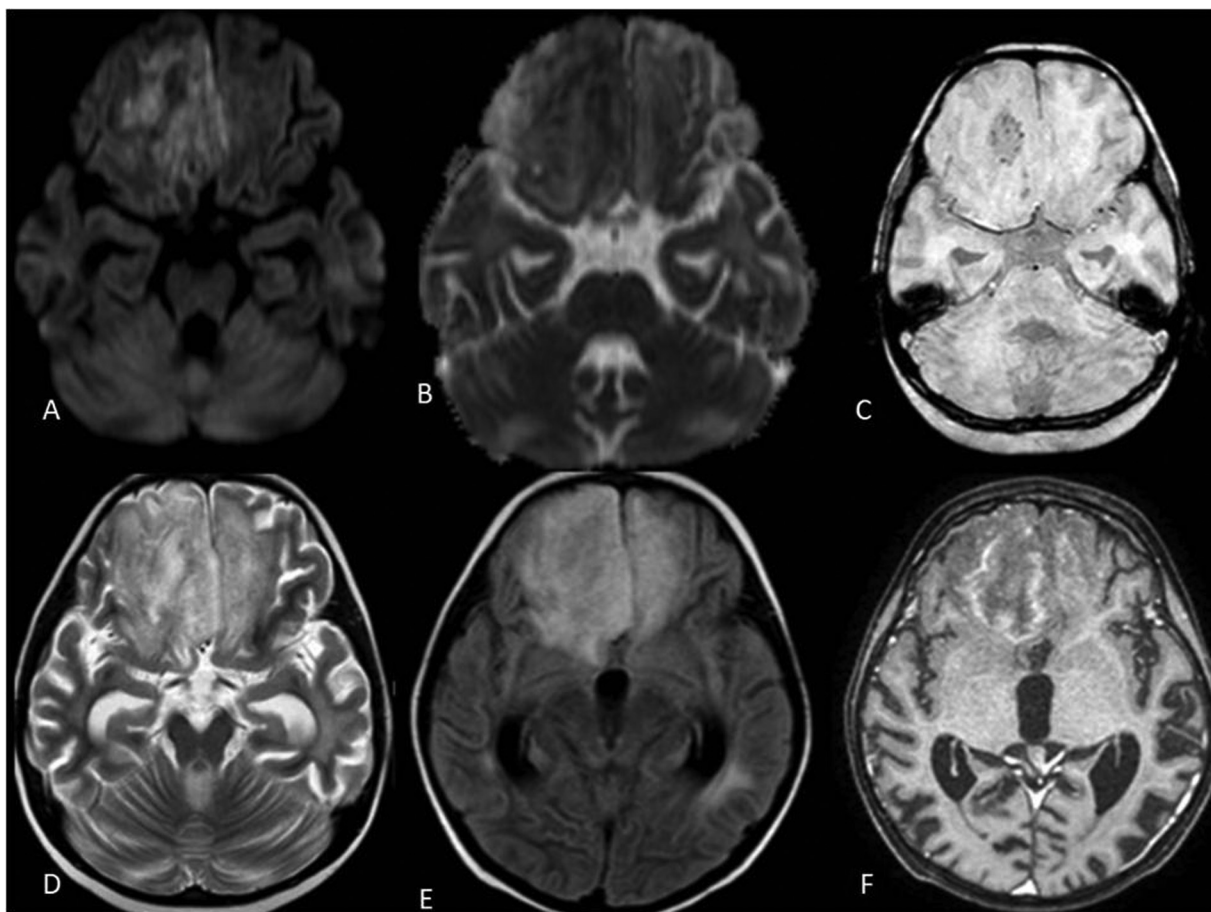


Fig. 5 Case 3: (A) Axial diffusion-weighted imaging, (B) axial apparent diffusion coefficient (ADC), (C) axial susceptibility-weighted imaging, (D) axial T2-weighted (T2W), (E) axial fluid-attenuated inversion recovery (FLAIR), and (F) axial postcontrast T1W showing ill-defined heterogeneous lesion involving bilateral basifrontal cortices, right superior frontal cortex, and subcortical white matter. The lesion appears heterointense on T2 and FLAIR images. Patchy areas of restricted diffusion with corresponding low ADC values are seen foci of signal loss with “blooming” are seen within the lesion in right basifrontal cortex, suggestive of hemorrhage. On contrast administration, mild-to-moderate heterogeneous patchy predominantly peripheral enhancement is seen. Mass effect and midline shift are seen.

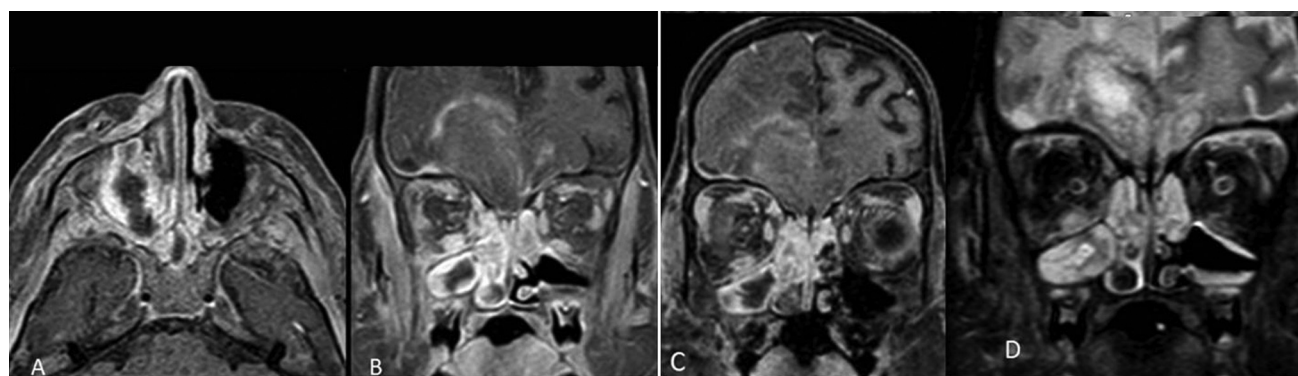


Fig. 6 Case 3: (A) Axial T1 postcontrast, (B) and (C) coronal T1 postcontrast, and (D) short tau inversion recovery (STIR) coronal images showing bilateral maxillary (right > left), sphenoid and ethmoidal sinusitis with soft tissue thickening and edema in right retromaxillary fat plane, pterygomaxillary fissure, and periorbital region. STIR imaging shows hypointensities in right maxillary sinus and right inferior turbinate, which are nonenhancing on contrast imaging—Imaging features are suggestive of fungal sinusitis with suspicious extraconal extension.

Imaging Features

There are no imaging guidelines in HLH and the workup depends on clinical presentation. It is recommended to perform CSF studies and MRI brain even in patients without CNS symptoms.⁶ Abnormal imaging findings are seen in

patients with HLH, who have no CSF abnormalities or neurologic symptoms.⁷

The most common imaging finding is diffuse cerebral atrophy. Other findings are white matter lesions, demyelination,⁵ increased T2 hyperintensity in white matter, and

Table 1 Comparison showing typical neuroimaging features described in literature and the findings in our study

Neuroimaging features of HLH described in literature	Finding in case 1	Finding in case 2	Finding in case 3
Diffuse cerebral atrophy	Diffuse cerebral atrophy	Diffuse cerebral atrophy	Diffuse cerebral atrophy
Diffuse white matter edema	Diffuse white matter edema	Diffuse white matter edema	Diffuse white matter edema
Rim/nodular enhancing or nonenhancing white matter and cortical lesions	Nonenhancing white matter and cortical lesions	Nodular enhancing white matter and cortical lesions	Rim enhancing white matter and cortical lesion
Deep gray matter lesions	–	Deep gray matter lesions	–
Leptomeningeal enhancement	–	–	–
Hemorrhage, calcification or necrosis	Hemorrhage	Necrosis, cystic encephalomalacia, cortical laminar necrosis	Hemorrhage
Subdural collections	–	–	–
Perineural and perivascular enhancement	–	–	–

Abbreviation: HLH, hemophagocytic lymphohistiocytosis.

Table 2 Imaging features of HLH involving various systems

CNS	Pulmonary	Abdomen	Musculoskeletal
Diffuse cerebral atrophy	Alveolar or interstitial infiltrates	Hepatosplenomegaly	Periosteal new bone formation
White matter lesions and demyelination	Pleural effusion	Hepatic steatosis	Healing fractures
Cortical and subcortical lesions with or without variable nodular or ring enhancement	Peribronchial thickening	Ascites	Osteonecrosis
Hemorrhage, calcification, necrosis	Centrilobular nodules	Gallbladder wall thickening, periportal echogenicity	–
Diffuse brain edema	Consolidation	Nephromegaly, increased cortical echogenicity	–
Subdural collections	Ground glass opacities	–	–

Abbreviations: CNS, central nervous system; HLH, hemophagocytic lymphohistiocytosis.

Table 3 Clinical criteria from the HLH-2004 trial for diagnosis of HLH

1. Fever ($\geq 38.5^{\circ}\text{C}$)
2. Splenomegaly
3. Cytopenia (at least 2 of 3: hemoglobin < 9 g/dL, platelets $< 100,000/\mu\text{L}$, absolute neutrophil count $< 1,000/\mu\text{L}$)
4. Hypertriglyceridemia (fasting triglycerides > 265 mg/dL) and/or hypofibrinogenemia (fibrinogen < 150 mg/dL)
5. Hyperferritinemia (ferritin > 500 ng/mL, although it is usually $> 3,000$ ng/mL)
6. Elevated soluble CD25 (IL-2 receptor α , two standard deviations above age-adjusted norms)
7. Low or absent natural killer cell activity (cytotoxicity assay)
8. Hemophagocytosis in bone marrow, spleen, lymph node, or liver

Abbreviations: HLH, hemophagocytic lymphohistiocytosis; IL-2, interleukin-2.

focal lesions in cortical and subcortical regions with variable nodular or ring enhancement or leptomeningeal enhancement. Patchy areas of T2 hyperintensity involving white

matter represent patchy distribution of histiocytes infiltrating brain tissue. Inflammation may be seen along the spinal roots or cranial nerves showing enhancement.⁸ T2

hypointense parenchymal lesions are also described in the literature which was assumed to be caused by calcifications or hemorrhage. Restricted diffusion with low apparent diffusion coefficient values may be seen, which suggests active inflammation in the brain.⁹ Subdural collections may also be seen.

Various differential diagnoses are meningoencephalitis like aspergillosis and tumors with diffuse brain involvement (lymphoma, leukemia). The differential diagnosis for hemorrhagic lesions involving deep gray matter includes acute necrotizing encephalopathy (ANE) and acute hemorrhagic encephalomyelitis (AHEM). ANE typically involves bilateral thalami with necrosis and hemorrhage being the predominant findings.¹⁰ AHEM is a rare and severe form of acute disseminated encephalomyelitis in which variable involvement of the central gray matter is seen in addition to tumefactive white matter lesions.

Conclusion

The most common neuroimaging manifestation of HLH is multifocal parenchymal lesions and atrophy.¹¹ Though MRI findings of HLH are nonspecific, it helps in evaluating the CNS involvement and extent of the disease in a diagnosed case of HLH and for follow-up.

Funding

None.

Conflict of Interest

None declared.

References

- Henter JI, Nennesmo I. Neuropathologic findings and neurologic symptoms in twenty-three children with hemophagocytic lymphohistiocytosis. *J Pediatr* 1997;130(03):358–365
- Rosado FG, Kim AS. Hemophagocytic lymphohistiocytosis: an update on diagnosis and pathogenesis. *Am J Clin Pathol* 2013;139(06):713–727
- Fukaya S, Yasuda S, Hashimoto T, et al. Clinical features of haemophagocytic syndrome in patients with systemic autoimmune diseases: analysis of 30 cases. *Rheumatology (Oxford)* 2008;47(11):1686–1691
- Kollias SS, Ball WS Jr, Tzika AA, Harris RE. Familial erythrophagocytic lymphohistiocytosis: neuroradiologic evaluation with pathologic correlation. *Radiology* 1994;192(03):743–754
- Horne A, Trottestam H, Aricò M, et al; Histiocyte Society. Frequency and spectrum of central nervous system involvement in 193 children with haemophagocytic lymphohistiocytosis. *Br J Haematol* 2008;140(03):327–335
- Jordan MB, Allen CE, Weitzman S, Filipovich AH, McClain KL. How I treat hemophagocytic lymphohistiocytosis. *Blood* 2011;118(15):4041–4052
- Fitzgerald NE, McClain KL. Imaging characteristics of hemophagocytic lymphohistiocytosis. *Pediatr Radiol* 2003;33(06):392–401
- Chiapparini L, Uziel G, Vallinoto C, et al. Hemophagocytic lymphohistiocytosis with neurological presentation: MRI findings and a nearly miss diagnosis. *Neurol Sci* 2011;32(03):473–477
- Gratton SM, Powell TR, Theeler BJ, Hawley JS, Amjad FS, Tornatore C. Neurological involvement and characterization in acquired hemophagocytic lymphohistiocytosis in adulthood. *J Neurol Sci* 2015;357(1-2):136–142
- Van Cauter S, Severino M, Ammendola R, et al. Bilateral lesions of the basal ganglia and thalami (central grey matter)-pictorial review. *Neuroradiology* 2020;62(12):1565–1605
- Malik P, Antonini L, Mannam P, et al. MRI patterns in pediatric CNS hemophagocytic lymphohistiocytosis. *Am J Neuroradiol* 2021;42(11):2077–2085