

Samiran Bandyopadhyay

---

## 3.1 Overview of Systemic Illness

Like other animals pet and companion birds are also prone to systemic illness. This is presented in the form of certain clinical signs and symptoms which is known as “sick-bird syndrome.” The pet birds have their unique physiology and anatomy and their metabolic turnover is quite high. The feeding practice adopted by owner may have an impact over their health status. Birds are kept confined with limited exercise and they are deliberately kept isolated from their foraging behaviour. All these may have an impact over their health status. Diagnosis of these diseases is necessary to adopt a correct treatment or management protocol. However, this is rather complex in caged birds as many of the birds may not exhibit any clinical manifestation as such. By the time these symptoms are presented birds become really sick. Many of systemic diseases are presented with same cluster of symptoms. Moreover, they have a tendency to hide their illness as common tendency of all prey animals. Therefore, the observable and detectable clinical signs indicate a grave concern. Even a little manipulation may lead to serious consequences.

There are certain symptoms which must be borne into mind indicating towards general illness

1. Huddling of the birds together
2. Consistent ruffled feather or any change in plumage
3. Change of wings position (dropped/elevated)
4. Sitting low on perch or only at one side or bottom of the cage
5. Any observable change of colour of the beak
6. Convulsion/ataxia/trembling
7. Ambulatory disturbance/walking in an imbalanced manner
8. Walking in circle

9. Any detectable lump or swelling on any part of its body
10. Any kind of weakness
11. Anorexia
12. Self-mutilation
13. Discharge from eyes or nares
14. Any change or abnormality in color, volume, consistency, and number of droppings
15. Respiratory difficulty
16. Lameness or pain.

The symptoms which require emergency interventions are

1. Dyspnoea
2. Ascites
3. Convulsion
4. Trauma and bleeding
5. Collapse
6. Burn injury.

Behavioural changes are also good indicators of systemic illness. The changes which must be looked after are as follows—

1. The affected birds do not response to any kind of stimuli
2. They will have abnormal changes in vocalizations
3. Lethargy and inactivity
4. Mental stupor or over aggression
5. Reluctant to play
6. Any change in eating or drinking behaviour.

There are certain points which must be taken seriously when the dietary formulation of the companion birds are followed as many of systemic diseases originate from there itself.

1. Many of caged or companion birds are highly sensitive to dyes preservatives used in many feed formulation. This can cause anaphylactic reaction with serious health problem.
2. High calorie diet with all seed or nuts often cause the serious problem like cardiomyopathy, atherosclerosis, fatty liver syndrome etc.
3. Mycotoxin in diet is a great source of problem like pneumonia and toxic hepatopathy leading to micro hepatica, hepatic cirrhosis and toxic nephropathy
4. Ample potable drinking water is required to maintain electrolyte balance and good hydration and keep the renal system in good health.

## 3.2 Disorders of Endocrinological Origin

### 3.2.1 Avian Goiter/Thyroid Enlargement or Hyperplasia

Thyroid gland enlargement or thyroid hyperplasia is detected in various pet birds like pigeons, macaw and other birds. It is generally caused due to dietary deficiency of iodine. The birds which are kept on seed based diet are more prone to develop this disease particularly when the seeds are grown on soil deficient on iodine. Therefore, pellet based diet is preferable when thyroid hyperplasia is detected in a flock. This is very common in various species of pet birds like pigeons, canaries, cockatiels, macaw, and budgerigars (budgies). Goiter has been detected in penguins also. Other than neoplasia, this is the most common cause of death of budgerigars. Certain breeds of pigeons are also more prone like White Carneau.

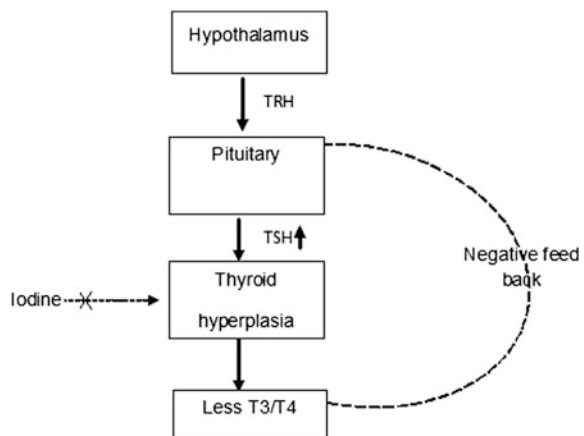
#### 3.2.1.1 Etiology

Various factors were detected to cause thyroid hyperplasia or goiter in pet birds. The most common cause is iodine deficiency. The birds which are solely placed under iodine deficient seed or grain diet are more likely to develop thyroid hyperplasia. Again more consumption of goitrogenic agents (kale, cabbage, broccoli, soybean, flax, rapeseed, turnips etc.) or their incorporation in the diet may lead to develop goiter. Again chronic infection of thyroid gland or toxicity due to ingestion of organophosphates and chlorinated biphenols were reported to cause thyroid hyperplasia.

#### 3.2.1.2 Pathophysiology

Due to iodine deficiency (Fig. 3.1) the production of thyroxine hormone is diminished and decreased blood concentration of thyroxine give a signal to brain which sensitizes the thyroid gland for optimum production of thyroxine through

**Fig. 3.1** Insufficient dietary iodine leads to goiter



thyroid stimulating hormone (TSH). Thus the thyroxin producing cells are increased in number leading to development of thyroid hyperplasia.

### 3.2.1.3 Clinical Findings

- The thyroid enlargement may be large enough to be visible by clinicians. The gland is located in thyroid cartilage near upper respiratory tract.
- The enlargement may sometimes occlude the passage of trachea with development of dyspnoea or respiratory distress.
- The pressure on oesophagus and crop may lead to difficulty in swallowing which may lead to apathy to take food resulting in weight loss. Recurrent vomiting or regurgitation may be developed due to pressure on proventriculus.
- Likewise pressure on heart, major vessels, lung or air-sac may lead to convulsion and sudden death.
- Change of voice is often noticed in the affected birds.
- Due to diminished concentration of thyroxine, the birds may be lethargic, depressed with reduced metabolic rate and develop dermatological symptoms like loss of feathers and chronic itching.
- Reproductive problems like retardation in sexual maturity, embryonic death and reduced hatchability may be noticed in birds with goiter.
- The clinical presentation of goiter is different in pigeon to some extent. The affected birds may be lethargic and obese with palpable enlarged mass at thoracic inlet (Fig. 3.2). The birds become immunocompromised and presented with ruffled or distorted feathers and plumage. There is accumulation of fluid under skin with puffy appearance (myxedema). Affected pigeons exhibit lower hatchability and reduced fertility.



**Fig. 3.2** A pigeon suffering from avian goiter showing enlargement of thyroid gland. The bird was presented with complications like dyspnoea, painful swallowing and progressive emaciation (Courtesy Suman Biswas, ARD Department, Government of West Bengal, India)

### 3.2.1.4 Pathology

Gross pathological changes include bilateral enlargement of thyroid gland with more number of translucent and distended follicles in the capsule with dark red or black haemorrhages. Histologically, the hyperplastic glands are detected with enlarged columnar or cuboidal epithelial cells with no apparent colloid or follicular lumen. Thyroid hyperplasia may be confused with thyroid adenoma or adenocarcinoma. In carcinoma, there is severe distortion and destruction of the whole gland. The poorly differentiated cells may be observed to infiltrate the capsule and surrounding tissue.

### 3.2.1.5 Diagnosis

- Thyroid enlargement with change of voice may be the cardinal sign.
- X-ray of the neck region of the affected birds will reveal thyroid enlargement with dorsal or ventral displacement of trachea or oesophagus.
- Blood examination for estimation of serum thyroxine concentration.
- By this method T4 level is estimated. However, no separate kit is available for avian species for T4 estimation and as the concentration of serum T4 is too low in birds, it is not always possible to precisely determine the concentration using feline or canine testing kits, especially when it drops down below 0.2 µg/dl.
- Many workers suggested TSH stimulation test as better alternative for diagnosis of hypothyroidism. In this case 1.0–2.0 U of TSH is injected intramuscularly and two samples are collected at 4 h before or 6 h after the administration of TSH. In healthy birds, T4 level should at least double in concentration following administration of TSH. In pigeons, the second blood collection is usually done after 24 or 32 h of 0.1 or 1 U of TSH injection. In healthy birds, serum T4 level should increase by 2.5 folds above the basal level.

### 3.2.1.6 Treatment

Iodine supplementation is the mainstay of therapy. In severe cases, sodium/potassium iodide may be injected. For a 30–35 g of budgerigar the dietary requirement of iodine is about 20 µg per week. This is usually done by injecting 0.01 ml/budgie once, IM in the form of 20% sodium iodine in saline. For oral supplementation a stock solution of 2 ml Lugol's iodine in 30 ml water should be prepared and one drop of stock solution is to be mixed in 250 ml drinking water. This is to be used daily for treatment, 2–3 times per week for prevention.

L-thyroxine is often advocated in psittacine birds. It is generally given at the dosage of 0.02–0.04 mg/kg body weight at every 24 h. However, its administration needs special care as in healthy or euthyroid birds; it may create the problems like cardiomyopathy and congestive heart failure. Goiter may be prevented by supplementation of trace amount of iodine in the diet.

### 3.2.2 Diabetes Mellitus

Diabetes mellitus (DM) is frequently reported in granivorous birds including the domestic pigeons and the disease is characterized by polyphagia, polydipsia, polyuria and chronic weight loss. Persistent hyperglycemia and glycosuria are mainly demonstrated in the affected birds. It is more common in budgerigars, cockatiels and galahs. Among others, larger psittacine, toucans, mynahs are also affected.

#### 3.2.2.1 Pathophysiology

The underlying mechanism of diabetes is poorly understood in birds. Unlike mammals where insulin has a predominant role in DM, in birds blood glucose level seems to be controlled by a complex hormonal milieu. In comparison to mammalian pancreas, avian pancreas has a low proportion of insulin secreting cells and 5–6 times higher number of glucagon producing cells. Circulating glucagon concentration in avian blood is 10–50 times higher than the mammalian blood. Glucagon as a catabolic hormone plays a pivotal role in gluconeogenesis, lipolysis and glycogenolysis to augment the blood glucose level, while insulin controls the entry of glucose in the cells and its utilization. In birds particularly in granivorous species, Glucagon is considered to play a more relevant role for development of DM. However, other factors like somatostatin, growth hormone, epinephrine, thyroxine, prolactin, pancreatic polypeptides and corticosteroid may have a modulatory role in development of persistent hyperglycemia. Hyper production of any of these hormones either due to tumor of the hormone producing cells or due to paraneoplastic syndrome may lead to such condition. Islet cell carcinoma with DM has been described in a parakeet.

In general, DM may occur in three forms in birds—

1. Type I DM: It is purely of pancreatic origin due to selective destruction of pancreatic cells. This form of the DM is more common in toucans and parrots.
2. Type II DM: The type II DM is associated with some other diseases or conditions like obesity and iron storage diseases.
3. Type III DM: It is linked with pancreatic diseases like pancreatic neoplasia, pancreatic insufficiency and pancreatitis. Some insulin inhibitory chemicals or drugs like megestrol acetate, medroxyprogesterone acetate or corticosteroids.

#### 3.2.2.2 Clinical Findings

Clinical manifestation of the birds is straightforward—

1. Polyuria
2. Polyphagia
3. Polydipsia
4. Chronic weight loss.

Sometimes, this disease is associated with other non-specific signs like obesity, vomiting and lethargy. However, the affected birds generally maintain a good appetite.

### 3.2.2.3 Diagnosis

The main diagnosis is based on the detection of persistent hyperglycemia and glycosuria. However, detection of blood glucose level is tricky in birds as the avian blood glucose level is higher than in mammalian. Therefore, consistently higher level of blood glucose 38–44 mmol/l is indicative of DM in birds. Other than glucose, presence of ketone bodies in urine is also indicative of DM in birds. Clinical symptoms in some other conditions often resemble with the classical symptoms of DM in birds. Polyuria/polydipsia (PU/PD) syndrome is very common in pigeons which fed the squabs crop milk possibly due to decreased concentration of circulating prolactin. Likewise, infection of paramyxovirus serotype-1 may cause lasting PU/PD syndrome in pigeons. Again psychogenic PU/PD is also not uncommon in caged birds. Further, glycosuria has been detected in birds like African Grey Parrot without hyperglycemia. Thus glycosuria, even though an important indicator, cannot be considered alone for diagnosis of DM in avian. Moreover, other conditions like diabetes insipidus, medication with corticosteroids, diuretics, progesterone, renal or hepatic insufficiency, other hormonal irregularities should be considered before definite diagnosis of DM in birds.

### 3.2.2.4 Treatment

Management of DM is always a challenge. In birds it is more difficult as it is not easy to monitor the blood glucose level and thereby to evaluate the effect of the hypoglycemic drugs. The main objective of the treatment is to lower down the blood glucose level and maintain it. The treatment constitutes of insulin and other hypoglycemic drugs like sulfonylurea. The acute rise of blood glucose level can be treated with short acting insulin @ 0.1–0.2 U/kg. However, to maintain the blood glucose level persistently long acting insulin is prescribed with a varying dose (0.067–3.3 U/kg OD/BID) depending upon the clinical improvement and the blood glucose or urinary glucose level. Insulin is recorded to cause hypoglycemic shock in human. However, such instances were not recorded in birds. But possibility of such fallout cannot be denied. To avoid such happenings repeated sampling is required to monitor the blood glucose level making this quite difficult in birds. Oral hypoglycemic agents like sulfonylurea is good alternative. Sulfonylurea is known to stimulate the pancreatic beta cell to secrete endogenous insulin and to increase tissue sensitivity towards insulin. However, its efficacy in birds with insulin resistance is not properly known. Although insulin has been reported for treatment of DM in birds, its real efficacy is controversial in granivorous birds which are known to exhibit insulin insensitivity. Carnivorous birds may be more amicable to insulin therapy.

Dietary management of the affected birds is good option. In many cases dietary management itself is enough to control DM in birds without any antidiabetic drug

intervention. It is important to avoid high calorie diet or diet with high fat like sunflower oil. This can control obesity. Increasing fiber supplement is also an important part for clinical resolution of DM in birds.

---

### 3.3 Cardiovascular Diseases

Due to some predisposing factors cardiac diseases are not uncommon in pet birds. Depending upon the data of retrospective pathology, almost 10–40% pet birds are presumed to be affected by cardiac diseases. Nevertheless, these abnormalities are rarely detected ante-mortem. Restricted movement with lack of adequate exercise, nutritional deficiency, stresses associated with acclimatization and persisting hypertension are few of the factors that are responsible for cardiac diseases in pet birds.

Among various congenital heart diseases, intraventricular septal defect, duplicitas cordis, multiplicatis cordis and ectopis cordis were reported in pet birds. Again most of these conditions were recorded during post-mortem examination. As the avian heart is always under substantial pressure, most of the congenital disorders lead to early embryonic death.

#### 3.3.1 Pericardial Diseases

Two kinds of pericardial diseases are frequently noted in pet birds—pericarditis and pericardial effusion either in the form of hemopericardium or hydropericardium. Pericarditis is the inflammation of pericardium and its associated tissue occurs mostly due to infectious organism. Mycotic infection originated from respiratory tract, *Mycobacterium* infection or trichomoniasis in pigeons may lead to pericarditis. Visceral gout with deposition of uric acid crystals may also cause severe pericarditis in caged birds. Hemopericardium develops mostly from trauma whereas hydropericardium (Fig. 3.3) results from dietary protein deficiency and congestive heart failure.

##### 3.3.1.1 Clinical Findings

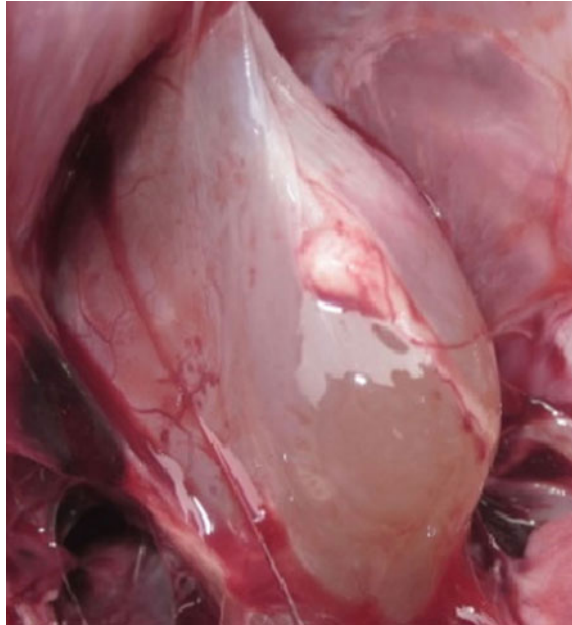
Most of the conditions are difficult to diagnose as clinical symptoms are nonspecific and clinicians have to rely on radiography showing increased cardiac silhouette. On the other hand, other test like echocardiography and endoscopy may be used as reliable alternative.

Birds with pericardial effusion may show few characteristic symptoms like—

- Decreased exercise intolerance,
- Coughing,
- Respiratory trouble or dyspnoea
- Abdominal distension.



**Fig. 3.3** Hydropericardium in a bird (Courtesy Amrit Dhara)



Congestion of liver and ascites may be detected additionally in case of hydropericardium.

### 3.3.1.2 Treatment

Pericardial effusion especially hydropericardium is usually treated with furosemide @ 0.15–2 mg/kg IM, SC or PO q12–24 h or some other diuretics along with acetylcholine esterase inhibitors. Overdose of furosemide can lead to dehydration and electrolyte imbalance. Lorikeets are very much sensitive to this drug, therefore, extra precaution is required.

### 3.3.2 Myocardial Diseases

Myocarditis or myocardial diseases are recorded in pet birds mainly resulting from systemic viral, bacterial, mycotic or protozoal infection. Infection with polyomavirus, chlamydia, sarcocystis and *E. coli* is not uncommon in birds. Moreover, chronic toxicity such as consumption of furazolidone often leads to myocarditis in birds. Increased preload during contraction as happened due to atherosclerosis or pulmonary hypertension may lead to aberrations in myocardial contractility. Haemosiderosis along with vulvar insufficiency was detected to cause myocardial failure in myna birds. Besides, vitamin E or selenium deficiency, right ventricular hypertrophy/dilatation was found to be associated with myocardial diseases. Chronic systemic mycosis often results in right sided enlargement of atrium and

ventricle resulting in failure of myocardial contractility. Prolonged stress during transportation may also lead to myocardial failure.

### **3.3.3 Arrhythmias**

#### **3.3.3.1 Cardiac Arrhythmia**

Cardiac arrhythmia is known as irregular heart beat where the heartbeat is too irregular, fast or slow. Many of the arrhythmia are asymptomatic and may not require treatment where as others is life threatening. Most of the arrhythmia noted in the pet birds are normal in nature and has been traced due to various predisposing factors. Sinus bradycardia has been observed in birds due to hypothermia. Long term anaesthesia often leads to hypothermia and bradycardia. Several organophosphorus or organochlorine compounds are also known to cause bradycardia via vagal stimulation. Again blood potassium concentration is an important parameter to control the cardiac rhythm. Hyperkalaemia or hypokalaemia, thiamine deficiency and deficiency of vitamin E may cause sinus bradycardia. Similarly sinus tachycardia with elevated heart rate is often asymptomatic and do not cause a potential damage unless the heart rate is too high to reduce the cardiac output. Most of the sinus tachycardia cases are associated with pain, nervousness and stress factors.

#### **3.3.3.2 Atrial Tachycardia**

It occurs when the electrical impulses are generated in some abnormal places (ectopic pacemakers) other than SA node and characterized by consistent rapid heart rate. This condition may be characterized by P on T wave in ECG where the P and T waves are super imposed. Atrial tachycardia may be seen with avian influenza virus infection. Atrial fibrillation is characterized by rapid and irregular heart beat and characterized by no P wave and an irregular ventricular rate in ECG. The QRS complexes are wide and are with higher amplitude indicating ventricular hypertrophy with inconsistent SS interval. The electrical impulses are generated from atrium rapidly and in an irregular manner and reaches to the AV node. There may be other type of supraventricular tachycardia where the rapid and irregular impulses are generated near the AV node junction.

#### **3.3.3.3 AV Node Arrhythmia or Heart Block**

AV node arrhythmia or heart block is not very infrequent in birds. It is especially due to incoordination of the atrial and ventricular depolarisation due to the incoordination in the electrical conduction system within heart. The first-degree atrioventricular block or PR prolongation the electrical conduction from atria to ventricle through AV node is delayed and reflected in ECG in the form of increased PR interval. Several diseases are known to cause such conditions like medication or application of anaesthetic agents like halothane, cardiotoxicants, excessive exertion,

electrolyte imbalance, myocardial infarction, myocarditis and AV nodal disease. In ECG, PR interval may be increased almost 3–4 times. Many of the cases lead to severe bradycardia which can be reversed by atropine. Second degree block occurs when one or more atrial impulses fail to be conducted to the ventricle and Mobitz I/Wenckebach phenomenon which is characterized by gradual prolongation of PR interval followed by dropped “P wave” (or absence of QRS complex) has been recorded in racing pigeons, raptors and parrots. Third degree heart block or complete heart block where the impulses generated in SA node of the atrium does not propagate to ventricle and both the atrium and ventricle behave independently. In ECG the PR interval will vary abruptly and there will be no relationship between P wave and QRS complex. The birds may be under haemodynamic instability and the condition was noted in electrolyte imbalance like hypokalemia in birds.

#### **3.3.3.4 Ventricular Premature Complex**

Ventricular premature complex or premature ventricular contraction is noticed in a number of conditions where ventricular contraction occurs before the atrial contraction takes place leading to insufficient cardiac output and body is haemodynamically compromised. This is noted as skipped beat and the unlike normal heart beat where the heartbeat is initiated at SA node, in VPC, the heartbeat starts from Purkinji fibre. The VPC appears in large and bizarre shape and can be differentiated from the normal ECG finding very easily. VPC normally is recorded when the blood circulation to the cardiac muscle is severely compromised like—myocardial ischemia. There are other several conditions where such VPC can be recorded like hypoxia, smoking, thyroid problem, myocarditis, pericardial effusion, hypokalaemia, vitamin E or thiamine deficiency, lead poisoning etc. Ventricular tachycardia is a condition where the heart rate becomes too rapid due to improper electrical activity in ventricle. Such condition is observed in birds mostly due to myocardial hypoxia and myocardial infarction with abnormal ECG findings. It may lead to ventricular fibrillation where the heart loosed its pumping activity leading to cardiac arrest and death. The ECG records abnormal QRS complexes which are not properly formed and shaped.

#### **3.3.3.5 Treatment**

1. Cardiac glycosides like digoxin @ 0.02–0.05 mg/kg bodyweight at every 12 h followed by 0.01 mg/kg bodyweight as maintenance dose are effective to slow down the heart rate, improve the coronary circulation and reduce the oxygen demand in cardiac muscle with positive inotropic effect.
2. Angiotensin converting enzyme (AGE) inhibitors like enalapril @ 5 mg/kg/day followed by a maintenance dose @ 1 mg/kg/day is known to induce diuresis, reduce blood pressure and cardiac load.
3. Beta-blocker (propranolol) @ 0.2 mg/kg/day is effective to overcome arrhythmia in birds.

### 3.3.4 Congestive Heart Failure

Congestive heart failure (CHF) occurs due to the persistent failure of the heart to pump blood effectively and that can lead to congestion in the systemic circulation resulting in fluid accumulation. Generally pulmonary venous congestion occurs due to left sided heart failure whereas systemic venous congestion starts with right sided heart failure. CHF is associated with incapacitated heart to maintain the cardiac output.

In general the pathophysiology of CHF is very complex. Owing to venous congestion, the blood circulation is reduced to kidney stimulating the renin-angiotensin mechanism and activation of the angiotensin I and II and aldosterone leading to retention of water and sodium. Ultimately in LHF, pulmonary oedema occurs whereas hepatomegaly and splenomegaly occurs with ascites and anasarca in RHF.

There are various causes for CHF in birds like

1. Any damage of the heart like disorders of pericardium, myocardium and endocardium which may interfere the blood circulation resulting in CHF.
2. Myocardial weakness, ischemia and infraction.
3. The right sided AV node thickening in birds may lead to valvular insufficiency and CHF.

#### 3.3.4.1 Clinical Findings

The birds may be presented with prolonged weakness, ascites, coughing, complains of exercise intolerance, dyspnoea, syncope and cyanosis. Hepatomegaly may be observed in few cases.

#### 3.3.4.2 Diagnosis

1. LHF may be accompanied by muffled lung sound due to pulmonary fluid accumulation where as in RHF, heart sound may be muffled due to hepatomegaly.
2. Chest radiograph may give the indication of cardiomegaly, pulmonary oedema and pleural or pericardial effusion.
3. Electrocardiography may be used to detect arrhythmia, atrial or ventricular defect.

#### 3.3.4.3 Treatment

The birds should not be put under any stress or exertion. Strenuous exercise or activities should be avoided.

1. Oedema should be treated with diuretics like furosemide @ 0.15–2 mg/kg q12–24 h. To avoid sudden drop of blood pressure due to increased dose of furosemide it may be given on alternate day.
2. Angiotensin converting enzyme inhibitor enalapril may be given to inhibit renin-angiotensin-aldosterone activity @ 0.5 mg/kg two times a day.
3. Further to support myocardial function digoxin may be given @ 0.02–0.05 mg/kg once a day.

### 3.3.5 Arteriosclerosis and Atherosclerosis

Arteriosclerosis means thickening and hardening of the arteries and there are various kinds of arteriosclerosis and of them atherosclerosis is very common among captive birds. The word atherosclerosis has come from the Greek word “athero” (gruel or porridge) and “sclerosis” which means hardening. The incidence is exuberantly high among few species of birds particularly among Psittaciformes (parrots, parakeets etc.), Anseriformes (swan, geese, duck etc.), Columbiformes (pigeons, doves, etc.) and Galliformes (fowl, pheasants, etc.). In pet birds particularly those which are affected by senility between 8–15 years of age and those belong to psittacine birds like African grey parrots, amazons and cockatoos are frequently affected by atherosclerosis. This is a chronic inflammatory reaction particularly affecting the layer between tunica intima and elastic lamina of the major vessels of heart, arteries and peripheral vessels leading to deposition of lipid followed by formation of fibrous plaques. These plaques are constituted of lipids, cholesterol, proteoglycans, collagen, cellular waste substances, calcium, foam cells, macrophages, and other leukocytes. Although, the process starts at a very young age, clinical signs may take time to develop and in most of the cases this remains undetected.

#### 3.3.5.1 Etiology

Although it is assumed that development of atherosclerosis may be spontaneous, several factors are implicated to facilitate its development like sedentary life style of the captive birds, lack of exercise, diet rich in fats or cholesterol and hyperlipidaemia. Excessive fats in diet are thought to be responsible for inducing chronic inflammation leading to atherosclerosis. Endothelial inflammation and formation of immune complexes are responsible for such plaque formation. Fatty liver disease was also recorded to be associated with atherosclerosis.

#### 3.3.5.2 Clinical Symptoms

The symptoms of arteriosclerosis are often misleading. In many cases it remains undetected throughout the life span. In certain cases it may be exhibited as fainting, falling and sudden death. The affected birds may show the symptoms of dyspnoea, exercise intolerance, coughing, nervous symptoms, paresis, paralysis, seizures, limb weakness etc. The gradual plaque formation and deposition causes the thickening of

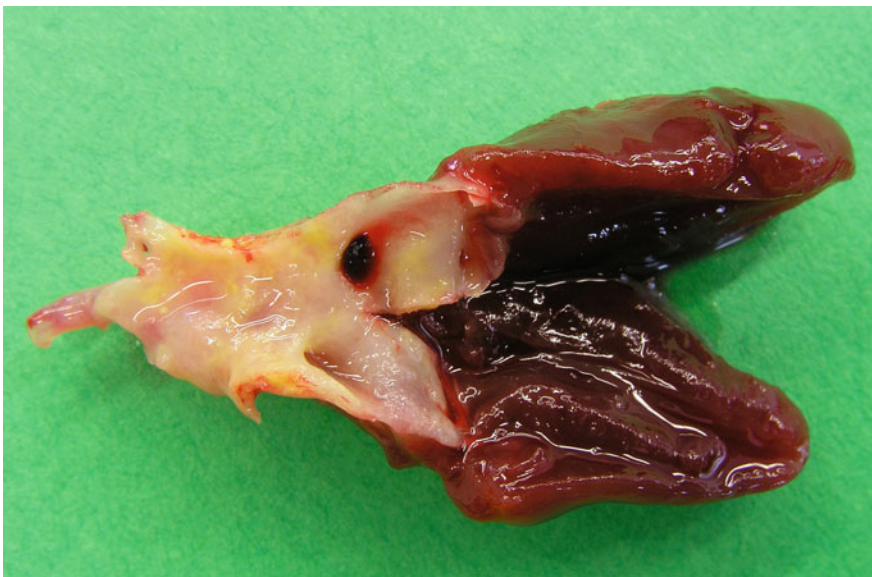intima and intraluminal protrusion which causes narrowing of the blood vessels with reduction of blood supply and oxygen to the major organs and peripherals. This subsequently leads to development of clinical signs. Gradual thinning of arterial membrane may lead to formation of aneurism, sudden rupture and death due to severe blood loss.

### 3.3.5.3 Diagnosis

Blood cholesterol level has a significant correlation with development of atherosclerosis and therefore, periodic measuring the blood cholesterol level is required to predict the possible occurrence of the disease. Many workers have suggested that elevated level of blood cholesterol, VLDL (very-low-density lipoprotein), LDL (low-density lipoprotein) and low level of HDL (high-density lipoprotein) may give indication of such occurrence. Radiography is useful for detection of formation of increased atherosclerotic plaques as reflected by increased density of the major arteries (Fig. 3.4).

### 3.3.5.4 Treatment and Management

The affected birds should be kept on low fat and more fibre diet. An attempt must be made to make them exercise and play so as to reduce obesity and risk of further damage. Application of beta-blockers (like propranolol) or calcium channel blockers (diltiazem, verapamil and enalapril @ 0.25–0.5 mg/kg/day, PO) may be effective. Isoxpurine was also reported to be effective in a separate study.



**Fig. 3.4** Presence of plaques at the blood vessel of a bird with atherosclerosis (Courtesy Prof. Richard Hoop, University of Zurich, Switzerland)

Dietary PUFAs, especially omega-3 fatty acids (alpha-linolenic acid (ALA), eicosapentaenoic acid (EPA), and docosahexaenoic acid (DHA)), play an important role in the prevention of atherosclerosis by inhibiting inflammation within the blood vessels, reducing plaque formation, and by other means that protect the vessels. EPA is known to reduce the risk of atherosclerosis by shifting the plasma and platelet fatty acid profile. Fishes, flaxseed, camelina, rapeseed, chia seed, and walnuts are good source of omega-3 fatty acids.

---

## 3.4 Ophthalmic Problems

### 3.4.1 Conjunctivitis

Conjunctivitis is one of the most common problems encountered in the pet birds. In general, it may be of primary origin only affecting the conjunctiva or may have been originated from the problems of the eye lids or other periorbital parts. Both the palpebral or bulbar conjunctiva along with the nictating membrane is affected. Most of the case of the conjunctivitis are originated from bacterial, viral, mycoplasma or chlamydia infection which may be primary or may be secondary to respiratory infection specially sinusitis. Many times systemic infection like septicaemia may lead to development of conjunctivitis. Mycoplasma infection often exhibits the symptoms of respiratory infection with conjunctivitis. Likewise adeno viral infection also causes systemic illness along with conjunctivitis. Pox virus infection often produces characteristic lesions and can be easily diagnosed with detection of intracytoplasmic inclusion bodies whereas cytomegalovirus infection, a common nuisance in Gouldian finches, is responsible for swollen and congested conjunctiva and accumulation of huge amount of serous exudate. Chlamydial infection also causes injected conjunctiva with watery or serous discharge in cockatiels. Similarly, mycoplasma is also known to cause swollen conjunctiva in cockatiels, budgerigars and house finches. Fungal infection, (*Aspergillus* sp., *Candida* sp., and *Cryptococcus neoformans*) is associated as secondary to bacterial infection in conjunctivitis. However, they are more associated with immune-suppressed birds with systemic illness.

Foreign bodies may also lodge in the conjunctiva and cause such abnormality. Irritation from chemicals such as smoke aerosols or chemical fumes may cause such irritable and chronic conjunctivitis. Metaplasia with hyperkeratosis of the conjunctival epithelium was observed in birds associated with vitamin A deficiency.

### 3.4.2 Keratitis

Inflammation of cornea is often seen in birds along with conjunctivitis and termed as keratoconjunctivitis. Keratitis usually exhibits similar kind of symptoms like conjunctivitis with reddening of the bulbar conjunctiva with increased vascularization;

however, mostly keratitis appears in the form of corneal opacity with accumulation of muco-purulent discharge or pus in the cornea. Keratitis occurs frequently due to bacterial or fungal infection apart from injuries from the foreign objects or conditions like stromal degeneration as recorded in pet birds. Vitamin A deficiency in birds especially in caged birds is not uncommon due to a particular type of diet and this may lead to drying up of the cornea leading to a condition known as Xerophthalmia. If the condition persists for a long period it may be developed in Keratoconjunctivitis sicca.

Persisting mycotic infection often leads to development of corneal ulceration with accumulation of white–yellowish proliferative exudate (Fig. 3.5). Microsporidial keratitis is not uncommon in psittacine birds and frequently appears in chronic form with conjunctival reddening and corneal opacity. Infective microsporidia can be recovered from infected conjunctival or corneal swab following staining with Gram stains and trichrome stains. Birds with mycosporidial keratoconjunctivitis have a



**Fig. 3.5** Severe keratoconjunctivitis in a bird (*Courtesy* Suman Biswas, ARD Department, Government of West Bengal, India)



record of long history of suffering from non-healing conjunctival inflammation or ulceration despite rigorous antibiotic or antifungal therapy. Topical flubiprofen or systemic application of flunixin (2–4 mg/kg BID) or meloxicam (0.2–0.5 mg/kg BID) along with antibiotic therapy like amoxicillin-clavulinic acid @ 125 mg/kg BID for 5 days or cefotaxime @ 75–100 mg/kg IM BID for 5 days is effective. Tarsorrhaphy using the third eye lid is often practised to narrow the opening of the eyelid; however, its success is still to be determined as expertise is required.

### 3.4.3 Cataracts

This is often common in birds; however, it is quite difficult to determine the aetiologies' leading to development of cataracts. Generally, in many species of the birds, cataracts are mostly due to hereditary origin linked to an autosomal recessive gene like Falconiformes and Cuculiformes (Yorkshire and Norwich canaries). On the other hand in a wide range of species it is acquired following some metabolic diseases like diabetes, toxicity or local and severe infection of the eye. Physical trauma, UV or microwave radiation and lightening stroke may lead to such condition. Viral infection (like avian encephalomyelitis infection), vitamin E and selenium deficiency may also be responsible for such cataract development. The condition can be detected with corneal opacity with cloudiness of the eyes, vision impairment and reluctance of the birds to detect or spot the feeds and to move. The affected birds are less responsive to normal stimuli. Treatment is not rewarding in most of the cases, however, phacoemulsification with intraocular lens implantation is practised in many cases with success. In general, clinicians should go for aggressive application of ophthalmic preparation of antibiotics with NSAID in the initial stages if suspected to be associated with local infection and trauma.

### 3.4.4 Uveitis

This is a condition associated with inflammation of the middle part of the eye—that the junction area between sclera and conjunctiva. In addition to the trauma and infection, uveitis may result from neoplasia and immune mediated inflammation. Rupture of the lens, reo-virus infection and infestation by *Toxoplasma* are the leading causes for uveitis. Systemic infection with *Mycoplasma*, *Pasteurella*, *Salmonella* and other pathogens may also lead to septicaemia and uveitis. The affected birds exhibit the signs like blepharospasms, photophobia, presence of blood clots (hyphema) or inflammatory exudate or pus (hypopyon) in anterior chamber, miosis (excessive constriction of pupil), dyscoria (abnormal shaped pupil) and corneal edema.

Treatment includes topical application of antibiotics and anti-inflammatory drugs.

### 3.4.5 Exophthalmos

It is relatively rare in pet birds. However secondary disease may lead to such conditions like periorbital traumatic injuries and haemorrhages, orbital fractures, orbital abscesses which often spread from peri-nasal sinuses as recorded in Amazon and African grey parrots. Retro-bulbar sinusitis is another cause of exophthalmos. In psittacines, infection of the Harderian gland may develop into exophthalmos. Neoplastic diseases of the adjoining areas like-glioma of the optic nerve, osteosarcoma of the orbital or nasal bones or adenocarcinoma may also lead to exophthalmos.

### 3.4.6 Panopthalmitis

It is the inflammation of the whole eye including, eyelids, uvea, conjunctiva and sclera and periocular diffuse swelling is noticed in and around the eyeball including infra-orbital sinus and nasal glands.

This is mostly due to traumatic injury or infection and extension of the injuries from adjoining areas of the eyes. Several infective agents like *Staphylococcus* spp., *Escherichia coli*, *Streptococcus* spp. *Pasteurella multocida* *Actinobacillus* spp. *Pseudomonas* spp *Plasmodium* and *parvovirus* are known to cause the condition. Apart from these chemical or physical irritants like smokes, chemical fumes, environmental toxins are such irritants to precipitate the condition. Many times panopthalmitis is associated with infraorbital sinusitis particularly, in psittacines and develops puffiness over the orbital cavity.

Clinical symptoms are associated with the similar pictures as noticed in other cases described above. Local and systemic antibiotic and anti-inflammatory therapy are warranted with debridement of the scar tissues formed commonly in viral infection.

### 3.4.7 Optical Neuropathy

Optical nerve degeneration and neuritis is commonly due to traumatic injury or infection leading to partial blindness or reduced light reflexes in birds. Moreover, adenoma or neoplastic changes in the pituitary gland may also cause compression over the optic nerve with degeneration in case of parakeets. Persisting viral infection and immune-reaction may cause optical nerve injury.

### 3.4.8 Examination of Eyes

Examination of the ocular reflex is one of the major criteria to examine the vision of the birds. Menace reflex is tested by quick approach of any object or head towards

eye and the positive response can be recorded with eye blink, rapid withdrawal of the head or aggressive behaviour with beaks. Palpebral reflex may be evaluated by touching the skin at the lateral or medial edge of the eyelid. A quick covering with nictating membrane is seen in healthy cases. Corneal reflex can be tested with touching of the cornea with moist cotton symmetrically in both the eyes.

#### **3.4.8.1 Schirmer Tear Test**

It is an effective test to evaluate the tear production in animals using paper strips. However, its efficacy in birds is not well established due to wide variation in results. Generally the value ranges between 3–12 mm in healthy birds. An effective alternative of this test is thread test using pH indicator phenol red. The variation in results is much reduced in this test because of the less irritating reaction of the test materials.

#### **3.4.8.2 Other Methods**

Tonometry using a commercially available pressure indicator may be used to measure the intraocular pressure. In healthy birds it ranges from 9–25 mmHg. Apart from these modern techniques like ultrasonography, electroretinography and fluorescein angiography are used to evaluate the eye. Electroretinography is normally used to detect the retinal disease and electrodes are placed on cornea and skin at the sides of the eye. The eyes are subjected to various types of stimuli and their reflexes are noted electrically to evaluate the functions of various retinal cells like rods and cones. Fluorescein angiography is conducted to study the blood flow and blood vessels in the eyes following intravenous injection of a special dye—fluorescein. This can detect minute haemorrhages, atrophy of vessels and retinal diseases.

---

### **3.5 Pulmonary and Airway Diseases**

The respiratory system consists of air passage the tubes that supply air to the lung and respiratory system for passage of oxygenated blood through the capillary bed lying on lung parenchyma and alveoli. The very purpose of the respiratory tract is the exchange of fresh and foul air. Due to constant exposure of the environmental air the capillary bed of alveoli and air sac are very vulnerable to gas, vapors, toxic ingredients, various microbes and toxic particles. At the same time the system is also prone to injury from the haematogenous insults. To protect from the environmental hazard the bronchioles are layered with ciliated epithelial cells and there is also a water protein layer enriched with lysozyme to protect from the pathogens. The non-ciliated granular clara cells lining the bronchioles are important for detoxification of the foreign proteins and drugs. However, alveoli contain a very delicate structure consisting of three layers—endothelium, alveolar interstitium and alveolar epithelium consisting of type I and II pneumocytes. Pulmonary surfactant

with phospholipid is instrumental to maintain the surface tension and to stabilize the alveoli preventing its collapse during expiration. Besides, the pulmonary defense mechanism is coordinated by mucociliary defense mechanism and mononuclear phagocyte system of the respiratory system (alveolar and interstitial macrophages). Mucus is produced by goblet and submucosal cell and contains water, glycoprotein, lipid and salt. Mucociliary defense mechanism can protect the initial insult by dissolving the foreign agents like bacteria, toxic gas and foreign injurious particles and propelling them out.

Alveolar macrophages are derived from blood monocytes and are highly active phagocytic cells which can readily ingest bacteria and other particles reaching to the alveoli. They usually kill the ingested bacteria by releasing lysozyme and incorporating them within phagosome.

### 3.5.1 Sinusitis

Because of the complex and tortuous nature of infra-orbital sinus, many of the pet birds usually suffer from sinusitis.

#### 3.5.1.1 Etiology

Besides, bacterial (*Staphylococcus*, *Pseudomonas*, *Pasteurella*, *E. coli*, *Klebsiella*, *Haemophilus*, *Mycobacterium* in few occasions), viral (reovirus, poxvirus, herpes virus, ILT, avian influenza virus) and fungal (*Aspergillous*, *Candida* and *Mycoplasma*) infection, irritation of the sinus mostly due to ammonia intoxication is seen in birds when they are kept poorly ventilated areas/farms or in congested manner in the cages. Besides, excessive air pollution, intensive use of smoking for mosquito repulsion may lead to sinusitis. Insertion of foreign body in the sinus, neoplastic or benign growth may result in sinusitis. Different pet birds may be detected with sinusitis with cockatiels, macaws and pigeons having higher incidences.

#### 3.5.1.2 Clinical Findings

Sinusitis is usually represented with acute or chronic oculo-nasal discharge, nasal blockage, open mouth breathing, distension of the nasal orifices/nares, hyperinflation of the cervico-cephalic air sac and exophthalmos with dyspnea with oculo-nasal discharge matting the feathers around the beaks or head. Constant irritation of the nares may be noticed with incessant scratching of the head or cervical areas and shaking of the head. In few cases, due to excessive accumulation of exudates, the birds may be unable to open their beak—commonly referred as “locked jaw syndrome” as detected in animals with tetanus. If aggressive therapy is not undertaken, animals may die. This is most common in cockatiels.

#### 3.5.1.3 Diagnosis

In general, clinical symptoms are indicative of sinusitis. However, diagnosis is rather tricky if the clinicians need to identify the foreign body or any growth in the

sinus. The clinicians may take the help of contrast radiograph, CT scan or MRI and endoscopy to find out the cause of infection.

#### **3.5.1.4 Treatment and Management**

Successful recovery of sinusitis requires aggressive therapy as failure of timely treatment may lead to life-threatening situation for the affected birds. Removal of the nidus of infection like foreign body is the first step. It substantially reduces the symptoms and suffering of the affected bird. Correction of nutritional deficiency like deficiency of zinc or vitamin A leading to hyperplasia of the epithelial lining needs to be corrected with proper supplementation.

First the blocked sinus should be flushed with lukewarm saline to clear the blockage. Acetylcysteine dilution may be another option which can effectively remove the thickened mucus for their mucolytic property. If blockage is severe enough, surgical debridement and drainage may be required. Although it is effective, caution must be taken to avoid injury to nasal or ocular nerve. Nasal drop containing sorbitol and beta adrenergic blocker like xylometazoline/oxymetazoline hydrochloride and nasal spray with fluticasone propionate are good alternative to offer relief to the affected birds—as we experienced clinically. If inflammation is severe enough local application of NSAID and dry hot fomentation are useful. Oral or parenteral antibiotic like potentiated amoxicillin and fluoroquinolones are good choice. However, prior confirmation with antibiotic sensitivity test is better before initiation of therapy.

### **3.5.2 Rhinitis**

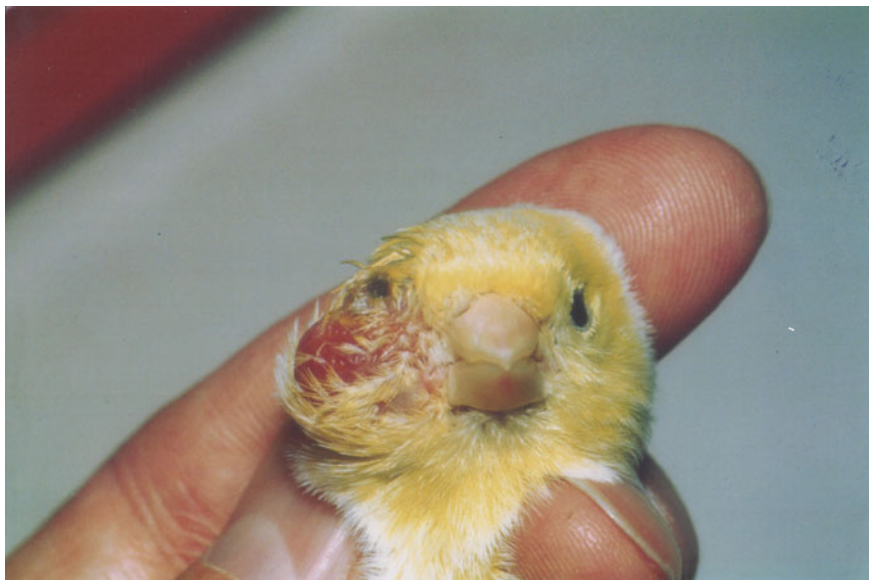#### **3.5.2.1 Etiology**

Like any other animals and birds, rhinitis is very common in pet birds. Mostly rhinitis or rhinotracheitis may occur due to allergic origin following irritations caused by infectious pathogens, dust, and gas. Hypertrophy of ceres, development of rhinolith and *Knemidocoptes* infection may lead to the development of rhinitis. In general, rhinitis is mostly detected among parrots, cockatoo and budgerigars.

Choanal atresia—failure of the choana membrane to close properly may be important reason for persistent rhinitis. During such cases, the nasal secretion fails to come in the oral cavity with swelling of infraorbital sinus (Fig. 3.6). This is more common in cockatoos and parrots. Rhinolith is another anatomical obstruction which may lead to constant nasal irritation and rhinitis.

#### **3.5.2.2 Clinical Findings**

Common symptoms are severe nasal and ocular discharge of watery consistency in the initial stage. Further, the discharge turns into muco-purulent nature mostly due to secondary bacterial infection. There may be asymmetry of the size of the nares.



**Fig. 3.6** Infraorbital sinusitis in a canary (*Courtesy Petra Maria Burgmann, Canada*)

The birds may manifest symptoms like constant sneezing, rubbing of the head and nares due to constant tickling and irritation.

### **3.5.2.3 Diagnosis**

Diagnosis is mostly dependent on clinical observation. However, rhinolith is not always detected at the external nares. The choanal atresia needs to be detected with flushing of the saline water at the nares and the saline fails to go into the oral cavity which ascertains the presence of persistent membrane or bony plate at the palate of the nasal cavity. Rhinography using contrast media may also be used for the same purpose for definite diagnosis.

### **3.5.2.4 Treatment and Management**

Surgical correction for removal of the boney plate or membrane and manual removal of the rhinolith may improve the clinical condition. Simple rhinitis often improves with oral anti-allergic drugs like chlorpheniramine maleate and cetirizine hydrochloride. Suspect of excess mucus accumulation in URT can be managed with mucolytic or expectorant of ambroxal hydrochloride. Although, clinical improvement was reported by many clinicians with these drugs, it should be monitored with strict clinical supervision. Vitamin C is good adjunct therapy used by many veterinarians to reduce stress and enhance the immunity of the caged birds.

### 3.5.3 Tracheitis

#### 3.5.3.1 Etiology

Tracheitis is seen in pigeons, parrots, cockatoos and cockatiels. Bacterial infection like *Pseudomonas aeruginosa*, *E. coli*, *K. pneumonia* are very common. Other than bacterial infection various viral (herpesvirus, ILT, paramyxovirus, adenovirus and cytomegalovirus) parasitic (*Sternastoma tracheacolum*, *Trichomonas gallinae* or *Syngamus trachea*) and fungal (*Mucor* and *Aspergillous*) infection were reported previously. Foreign body lodgment in the trachea as occurred in cockatiels with millet, or pigeons and parrots with rice bran or gram seed may cause severe tracheitis or tracheal obstruction with secondary infection. Extramural masses with goiter, neoplastic growth and boney growth may cause tracheal compression or tortuousness leading to severe dyspnea.

#### 3.5.3.2 Clinical Findings

The disease starts with acute onset of dyspnea. The extreme breathing trouble often initiates with stretching of the neck and open mouth breathing. Further, the bird may exhibit the symptoms like wing drooping and bobbing of the tail. Extramural growth may be seen or felt with palpation of neck region. Breathing or respiration may accompany with wheezing sound with rales which are audible from considerable distance. Infection or further involvement of larynx may be reflected with a change in voice.

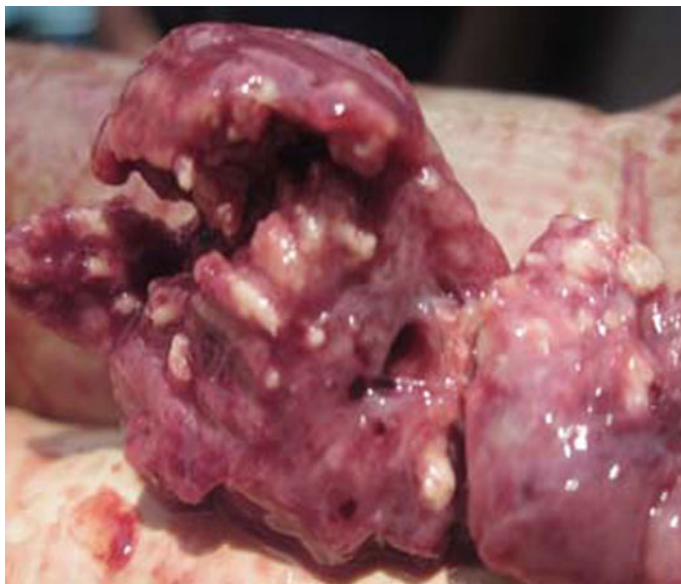#### 3.5.3.3 Diagnosis and Treatment

The tracheal compression can be best judged with contrast radiography whereas the tracheal obstruction may be visualized with tracheal endoscopy.

Airway catheterization is the only option to relieve the birds with tracheal obstruction/tracheal compression/stenosis. Surgical removal or debridement may be helpful for correction of formation of caseous or diphtheritic membrane, lodgment of foreign bodies or formation of granulomas. Tracheotomy is another helpful technique to relieve the birds. Oral or parenteral medication with antibiotics (Cephalosporins) in case of suspected bacterial infection and antifungal (amphotericin B, itraconazole) in fungal infection is advocated along with anti-allergic medication. To clear out the mucus or exudate or to facilitate the expectoration ambroxal hydrochloride and acetyl cysteine are useful. Nebulization with amphotericin B is very effective technique.

### 3.5.4 Diseases of the Lung

There are many factors responsible for diseases of lung and its associated structure in the pet birds. However, pneumonia and bronchitis (Fig. 3.6) develops mostly from bacterial (*K. pneumonia*, *E. coli* and *P. multocida*, *Mycobacterium* and *Mycoplasma*) viral (paramyxovirus, herpesvirus, avian influenza), fungal (*Mucor*,



**Fig. 3.7** Severe pneumonia in a bird (Courtesy Amrit Dhara)

Aspergillous, Cryptococcus) or parasitic (*Cryptosporidium* spp., *Toxoplasma* spp., *Sternastoma* spp., *Sarcocystis* spp., *Atoxoplasma* spp.) infection (Fig. 3.7).

Air sac mite is one such parasite which may affect any part or entire respiratory tract. Such parasite may be present in the nasal orifice of the infested parasite to the tiny air sacs. The air sac mites are more common among the birds like canaries, budgies, cockatiels and finches. Among them canaries and finches commonly suffer from air sac mites. The air sac mite is otherwise known as *Stemostoma tracheacolum*. This mite usually spends their whole life span within the respiratory tract of the birds. From hatching of eggs to complete their life cycle it normally took not more than seven days.

Air sac mites are commonly transmitted by infested birds. The coughed up materials, moist droplets and discharges may carry such parasites and enter in the air sac of healthy birds. Contaminated drinking water is the primary source of such pathogens.

The clinical manifestation depends upon the severity of infestation. The mite—*Stemostoma tracheacolum* has a peculiar habit to travel all along the respiratory tract. This is very irritating and may be responsible for repeated coughing in the affected birds. Mild infestation may not exhibit any noticeable symptom. In severe infection variety of symptoms may be developed and that may be confusing with common bacterial infection of the respiratory tract. Many birds develop sudden change in their voice and that can be a notification for air mite infection. Breathing trouble is a very common symptom and the affected birds may be seen with open



mouth breathing. Excessive salivation and shaking of the tail may be seen in some occasions. Generally the birds are seen to make whistling and clicking sounds while they take breathing. Such sounds are usually audible from distance. Symptoms are worse when the birds are in stress. Exercise, sudden fear, even excessive handling of the birds may produce such results. Severe air sac mite infestation may lead to the death of the birds also. Common respiratory symptoms like coughing, sneezing, mucopurulent discharge from nasal or ocular areas, labored breathing are seen among these birds.

Ivermectin and moxidecton are recommended for treatment. Intradermal application of ivermectin is usually given for three times in a weekly interval.

### **3.5.5 Pulmonary Hypersensitivity in Birds**

One of the major discussed hypersensitivity affecting the lung of human being is known as farmer's lung and this is due to type III hypersensitivity reaction to the inhaled fungal spore of actinomycete. Similar kind of pulmonary hypersensitivity has been noticed in macaw birds due to feather dander of other birds housed in same farm like cockatoos. Such hypersensitivity may also occur due to ingestion of foreign protein leading to congestion, edema, hemorrhage and emphysema although; they are less common among pet birds. Inhalation of toxic gases like nitric oxide, hydrogen sulphide, ammonia may be hazardous causing severe bronchiolitis, edema and interstitial pneumonia with fibrosis. Further these toxic gases may destruction or necrosis of bronchial cells and pneumocyte type I cells. Affected birds display chronic sinusitis, watery or mucopurulent nasal discharge, chronic coughing and poor exercise tolerance. Treatment option includes antihistaminic drugs like pheniramine malleate, cetirizine and corticosteroids depending upon the severity of symptoms. Underlying cause of allergic reactions must be removed to provide a permanent solution.

---

## **3.6 Diseases of Bone and Muscles**

### **3.6.1 Rickets and Osteomalacia**

Both rickets and osteomalacia occur due to defective mineralization of the bone owing to deficiency of vitamin D, calcium and phosphorous. Rickets is a condition of the young or juvenile birds when both the bones and cartilages undergoing endochondral ossification are affected while osteomalacia or osteoporosis is a disease of mature skeleton in adult birds.

#### **3.6.1.1 Clinical Findings and Pathophysiology**

Active form of vitamin D is responsible for intestinal absorption of calcium, maintenance of normal calcium level in blood and its proper deposition for

mineralization of bones. Inadequate vitamin D3 level due to lack of exposure of UV radiation/sunlight, lack of Vitamin D3 receptors, hypoparathyroidism, defective vitamin D3 activation, renal failure and defective gastrointestinal absorption may lead to such inadequate vitamin D3 level. Dietary deficiency of calcium may cause such condition due to improper and inadequate mineralization of the osteoid and cartilaginous matrix. Similar condition may occur in phosphorous deficiency and it is an essential ingredient of calcium phosphate required for such mineralization.

The most prominent changes in both the condition are enlargement of the ends of the long bones and costochondral junctions. The long bones may bend under body weight. Bones and beaks are extremely soft like rubber. The thickening of the costochondral junctions may appear like string of beads—"rachitic rosary". Abnormality and stiffness of gait and soft pliable appearance of bones, beaks and claws are noticed with severe retardation in growth. Affected lay birds show reduced hatchability and thin and soft shelled eggs.

### **3.6.1.2 Diagnosis**

Radiographic examination shows bending and bowing of long bone, distortion and widening of the growth plates.

### **3.6.1.3 Treatment**

External application or parenteral vitamin D3 therapy is required; however, it must be borne in the mind that exuberant vitamin D3 therapy may promote dystrophic mineralization leading to soft tissue calcification. After initial vitamin D3 injection, the affected birds may be subjected to UV irradiation by sunray exposure. Chronic vitamin D3 deficiency may be corrected by dietary changes especially with specialized diet. However, corrective therapy may require long period for clinical recovery. Surgical intervention may be required for correction of excessive bone deformity taking a due consideration of its feasibility.

## **3.6.2 Osteopetrosis**

The word "osteopetrosis" came from a Latin word "petra" which means stone. This name itself denotes that this condition is related with increased bone formation and density. This is also known as "osteosclerosis" from the Greek word "sclerosis" means hardening.

### **3.6.2.1 Clinical Findings and Pathophysiology**

This is a condition mostly seen in case of laying hen. This is characterized by formation of increased bone formation in the medullary cavity of the long bone like radius, ulna, femur and petroid bones. Other than birds, some other domestic animals like cattle, horse, sheep and dogs are also affected. In many domestic animals it is generally linked to a hereditary defect leading to decreased bone resorption

owing to osteoclast abnormality and defective bone remodelling. The bone density and bone mass both are increased and the affected bone becomes cartilaginous with absolutely no medullary cavity. However, the affected bones are brittle and are susceptible to fracture. In birds it is mostly occurred due to stimulation caused by estrogen. In reproductively active hens the condition is very common as such hyper estrogenic response is common to meet the higher demand of calcium for laying eggs. However, condition like hyper estrogenic diets, cystic ovarian diseases or ovarian hyperplasia and ovarian carcinoma may promote such condition.

### **3.6.2.2 Diagnosis**

Radiological evidence of increased bone density and history of frequent fractures may give the clinician the clue of such pathological condition.

### **3.6.2.3 Treatment**

In case of laying birds where the condition is purely physiological, no treatment is required. However, for pathological conditions, hormonal therapy like ovarian neoplasia or cystic ovarian diseases, partial or complete ovariectomy may be done. As it is quite difficult to execute and may not be possible, hormonal therapy like leuprolide acetate, HCG may be given as non-invasive approach.

## **3.6.3 Osteodystrophy**

Osteodystrophy is a general term referring to disorder of bone arising from faulty or defective nutrition and such condition in birds is characterized by increased osteoclastic resorption of bone and further replacement by fibrous tissue.

This condition basically appears due to demineralization of bone mostly due to feeding of the birds either a calcium deficient diet or feeding a diet containing excessive phosphorous. The birds are often fed with seed only diet which have high phosphorous: calcium ratio. Similarly, diet like nuts, fruits and vegetables also lack optimum calcium. Thus feeding of such kind of diet excessively leads to stimulation of the parathyroid gland to release parathyroid hormone which causes resorption of calcium from bone to maintain calcium homeostasis in blood. Excessive phosphorous in the diet interfere with gastrointestinal calcium absorption.

The lesions are characterized by increased osteoclastic resorption of cancellous and cortical bone and replacement by proliferated fibrous tissue. The articular surfaces of the long and weight bearing bones collapse and tend to fracture. The bones may bend and bow with deformity in the vertebrae and ribs.

The condition is mostly taken care of by nutritional rectification. Surgical intervention is required when there is urgent need for repairing the fractures.

### 3.6.4 Osteitis and Osteomyelitis

Inflammation of bone is known as osteitis and that of the medullary cavity is known as osteomyelitis. It is a chronic condition characterized by necrosis and destruction of bone, their removal and subsequent replacement by new bone.

#### 3.6.4.1 Clinical Findings and Pathophysiology

The condition is associated with compound fracture or neoplasia caused by numerous kinds of pathogens including bacteria (both aerobic or anaerobic), virus and fungus (like *Candida* and *Aspergillous*). Although it is not uncommon that infection has started following entry of the pathogen via open fracture, infection may also be initiated via hematogenous route. Bacteria are generally localized at metaphyseal area where the medullary veins join with capillaries and there is establishment of infection due to slow turbulence and flow of blood. Due to low phagocytic activity in this area, it is easy for the bacterial pathogens to kick start infection from this area. Further the infection spreads to medullary cavity resulting in osteomyelitis.

Clinically the osteomyelitis is characterized by painful gait and posture. The affected bird is unable to move or fly with painful lameness. In radiography, there will be definite lysis of the affected bone and soft tissue inflammation around the affected bone may be observed. Formation of abscess often leads enlargement of the affected area with expansion of the bone outline.

#### 3.6.4.2 Diagnosis

Diagnosis is often based on clinical and radiological interpretation. Hematological observations include heterophilia, leukocytosis and basophilia.

#### 3.6.4.3 Treatment

Before initiation of therapy a culture sensitivity test must be performed to determine optimum antimicrobial therapy. A number of antibiotics are effective depending on the type of infective organism like gentamicin, neomycin, ceftiofur, lincomycin, tobramycin and cefalothin. Antibiotic coated biomaterials like polymethyl-methacrylate beads should be placed to obtain effective and high concentration of antibiotic following surgical correction and debridement of the affected bone and tissues. Systemic antibiotic therapy should be continued for at least 2–3 months.

### 3.6.5 Nutritional Myopathy

Nutritional myopathy occurs in the birds which are kept on the meal rich in unsaturated fatty acids resulting in vitamin E and selenium deficiency. Both vitamin E and selenium play important role in protecting the cell membrane of the muscle from free radicals. In the time of deficiency, the cell membrane becomes physiologically defective with rapid influx of calcium in the cytosol and then in mitochondria. The mitochondria fail to work further with rapid fall in cellular energy

supply. Thus there will be wide spread destruction of the myositis with muscle fibre necrosis. Such condition results in muscle weakness and cardiomyopathy. Nutritional rectification may recover the affected birds rapidly.

---

## **3.7 Diseases of Skin, Feather, Beak and Cere**

### **3.7.1 Feather Cyst**

Development of feather cyst is a common problem in pet birds. It is commonly detected in macaw, canaries and parrots.

#### **3.7.1.1 Cause**

Feather cyst usually develops in the course of new feather generation. The newly grown feathers sometimes fail to grow and instead curl within and transforms in the cyst. The cysts are usually painful and impede in developing new feather. Generally injury or infection at the point of newly grown feathers is also associated with feather cyst. However, canaries are thought to be genetically predisposed for development of feather cyst. In canaries feather cyst is believed to be benign neoplasm of the feather follicle. Several dermal papillae forms within a single follicle result in entangling of the feathers.

#### **3.7.1.2 Clinical Findings**

Feather cysts are usually painful. Once developed and if not removed by surgical intervention, the cyst usually continues to grow with the growing feather and large swelling develops. It may develop at any region over the body. In parrots it is more common at the feathers of wing. Canaries usually develop more than one cyst at a time and surgical intervention is not pragmatic in those birds where many feather cysts are detected at a time.

#### **3.7.1.3 Treatment**

Topical application of antibiotic and periodic washing with the antiseptic is advocated to reduce the pain, infection and pruritus. Frequent application of 5% tincture iodine along with neomycin and tolnaftate solution helps to check the infection.

### **3.7.2 Feather Duster Diseases**

This is the disease of budgerigar. It is also known as Chrysanthemum syndrome. This is thought to be caused by a lethal recessive genetic disorders or budgerigar herpes virus. The affected bird is lethargic and prostrated, unable to fly with excessive growth of the flight or contour feathers and tail. Most of the affected birds die at a very young age.

### 3.7.3 Straw Feather Diseases

Likewise canaries also suffer from a congenital disorder known as straw feather disease where the feather fails to grow from the sheath and the feathers appear like straw. A similar condition is also noted in homer and fantail pigeons which are known as “porcupine feather”.

### 3.7.4 Alopecia and Baldness

#### 3.7.4.1 Occurrence and Presentation

In canaries, cockatiels and zebra finches, baldness is noticed with loss of feathers at the back of the head. In each of these birds, it is very difficult to detect the exact causes for the loss of feathers in head. Cockatiels are noted to suffer from baldness on head due to loss of crest feathers. This is also known to be hereditary disorder. Certain color patterns of the feathers are also known to cause such loss of feathers. In canaries, three factors are known to play for such baldness like—hereditary, endocrinological or hormonal deficiency and sex of the birds. In canaries, baldness is more common among male than the female birds. In contrast, finches of either sex suffer from such baldness in head and it is believed to be mostly caused by feather picking by a dominant group of birds.

#### 3.7.4.2 Treatment

As baldness in budgerigars and cockatiels is not properly understood, treatment of the affected bird is very difficult. Supplementation of thyroid and testosterone is practiced by many. In canaries, the dominant group should be separated to avoid such feather picking. L-thyroxine is to be supplemented orally at the dose of 0.02–0.04 mg/kg q24 h if hypothyroidism is suspected.

### 3.7.5 Self-mutilation

This is probably the most complicated syndrome affecting the pet birds causing a severe skin problem which is difficult to treat.

#### 3.7.5.1 Etiology

To date, the etiological factors leading to such self-mutilation is unexplored and may vary depending upon the management practices and the types of the birds.

In budgerigars and love birds formation of polyfolliculosis with thickening of the pulp cap and feather sheath may lead to extreme pruritus and such self-mutilation.

Again *Agapornis pox* or love bird pox virus infection may lead to such pruritus and mutilation in lovebirds.

In cockatiels, such self-mutilation is very common as a result of intestinal protozoal infection like giardiasis. Such infection often leads to vitamin E and selenium deficiency and protein losing enteropathy. This leads to dry flakes and poor feathering often tempting the birds for self-mutilation.

Herpes virus infection is another factor to incite for such temptation.

### **3.7.5.2 Clinical Findings**

Birds are extremely pruritic, irritating and damage their own body parts with repeated biting, picking or chewing. Skin of the chest, tail, wing and other region of the trunks may be affected. Sometimes, the cage-mates may mutilate each other resulting in severe feather or skin damage.

### **3.7.5.3 Diagnosis**

Diagnosis of self-mutilation, feather chewing, biting or picking is difficult as it is poorly understood. However, complete blood profile, serum chemistry and presence of other diseases should be investigated to eliminate the predisposing factors, if any. Stress factors including extreme or adverse climate conditions like extreme cold climate of winter or hot temperature in summer, social stress may instigate such condition. Low humidity in winter may induce extreme pruritus leading to self-mutilation. Lack of fresh air, sunlight, light/dark cycle is the important factors to be considered. Nutritional deprivation is another cause for such condition. Basic diets are often deficient in essential skin nutraceuticals like zinc, vitamin A, E or omega-3—fatty acids that may cause such skin or feather abnormality. Again, preservatives, pesticides, dye present in diet may have such deleterious consequences. The general systemic disorders like neoplasm, hepatic dysfunction, coelomic cavity granuloma, hypothyroidism, allergy and zinc toxicities should be looked for as these may induce such intense pruritus. Other psychological factors must be considered when such mutilating behavior is noticed like prolonged captivity, lack of interaction with the flock or with the owner, lack in the scope of reproductive behavior.

### **3.7.5.4 Treatment**

The stress factors must be minimized by giving the scope for sound sleep, good physical exercise.

## **3.7.6 Psittacine Beak and Feather Disease**

Psittacine Beak and Feather Disease (Pbfd), also known as neonatal feather dystrophy is an infectious disease caused by Circo virus.

### **3.7.6.1 Clinical Findings**

This disease is characterized by lethargy, loss of appetite, regurgitation, diarrhoea, deformity of the feathers and loss of feathers. Sometimes, infection may be

accompanied by other bacterial infection and Polyoma virus. A large number of caged birds like—cockatoos, macaws, African grey parrots, parakeets, and Lovebirds are affected. The infection mostly affects the young birds with a profound damage in several organs like liver, brain and immune system. Due to severe immune-suppression, the birds may die of secondary bacterial and fungal infection. Other than the dystrophic feather, beaks may also show some abnormality like overgrowth of beaks and symmetrical lesions on beaks.

### **3.7.6.2 Diagnosis and Treatment**

Diagnosis is based on haemagglutination inhibition test. Currently no therapy is available for the diseases. Only efforts may be made to overcome secondary infection.

## **3.7.7 Feather Destructive and Plucking Behavior**

It is associated with self-mutilation behavior discussed earlier. This condition has been noticed in a number of birds including parrots (such as Amazons or African Greys), Cockatoos, Macaws and Cockatiels. Its successful treatment is very difficult as it is not possible in most of the time to identify the underlying cause of such syndrome.

### **3.7.7.1 Etiopathology**

It is quite difficult to determine the exact etiology of such condition as it may be of multifactorial origin. In many cases physical, psychological and other factors may contribute for such development. The main factors are discussed here—

1. Endocrinological complication: Exclusively hypothyroidism often contributes to such feather plucking behavior. Such low level of thyroid usually leads to loss of feather with a thickened greasy appearance of skin.
2. Malnutrition: Deficiency of some key minerals like zinc, hypovitaminosis A, E and lack of essential fatty acid may lead to loss of skin and feather texture in birds. Dry skin with abnormal keratinization may cause such syndrome.
3. Boredom and stress: Psittacine birds are intelligent which need a constant physical and mental stimulation for their wellbeing. If the birds are left alone and the birds are not in interaction with other birds of the flock or they are not getting intimate touch of human beings such destructive behavior may be developed.
4. Improper wing trimming often causes as irritation which instigate the birds to develop such habit.
5. Heavy metal toxicity, aerosol contamination, smoke, excessive humid environment are other triggering factors.
6. It may completely psychological when the birds are trying to capture the attention of the owner or some kind of anxiety or stress may stimulate the birds



to develop such kind of syndrome. This ultimately leads to obsessive compulsive or stereotyped behavior pattern of feather destruction.

7. During vitellogenesis with enlargement of oviduct and ovary, the affected birds may feel discomfort and may exhibit such feather plucking in the areas of thigh and ventral abdomen.
8. Parasitic infection, particularly giardiasis is associated with such problem.
9. Systemic illness like hepatopathy, pancreatitis, renal diseases, neoplasia, and osteomyelitis may also triggers such behaviour due to chronic stress and discomfort exerted on the birds (Fig. 3.8).

### 3.7.7.2 Treatment and Management

Once the problem is identified, efforts must be made to relieve the stress of the birds either by keeping it busy with some destructible toys and varieties of feed. The environment of the birds must be changed. It will extenuate its stress and boredom. The birds may be let to spend some time outside its cage. Owner may spent time with it playing and talking.

Counselling or behavioral modification of the birds may be rewarding. However, it may require the identification of the proper cause. The birds may be sensitized for a brief exposure to such cause and then adjusted with extending the degree or time of such exposure. This ultimately changes the behavioral pattern of the birds. The birds may be left with a favorite toy to play or it may be allowed to be distracted with TV or radio.

Few clinicians recommend Elizabethan collar or some kind of such physical barrier. However, it may further increase the anxiety and increase the problem.



**Fig. 3.8** Feather damage in a ring necked parrot (*Courtesy* Mousam Das, Animal Resources Development Department, Government of West Bengal, India)

### Behavior or mood modifying psychoactive drugs

1. Benzodiazepines are good mood elevator. It works by inhibition of dopamine and potentiation of GABA.  
Diazepam @ 0.5 mg/kg PO q8–12 h or 0.25–0.5 mg/kg IM or IV or lorazepam @ 0.1 mg/kg PO q12 h may be given.
2. Tricyclic antidepressants potentiate serotonin and are sedative and anxiolytic with anticholinergic activity. Following drugs may be tried—  
Amitriptyline @ 1–5 mg/kg PO q12–24 h for at least 30 days or  
Clomipramine 0.5–2.0 mg/kg PO q12–24 h for 2–3 weeks or  
Doxepin @ 0.5–1.0 mg/kg PO q12 h at least for 2 weeks
3. Butyrophenones like haloperidol @ 0.1–0.4 mg/kg PO q12–24 h or 1–2 mg/kg IM every 2–3 weeks may be advocated to control the symptoms.
4. Medroxyprogesterone acetate @ 5–25 mg/kg IM every 4–6 weeks have a good anti-inflammatory effect over the integumentary system.
5. Antihistaminics like diphenhydramine @ 2–4 mg/kg PO q12 h and hydroxyzine @ 2 mg/kg PO q8 h may be used when the pruritus is extreme or some allergic disorders are suspected.

### 3.7.8 Skin and Feather Disease Associated with Endocrinological Disorders

There are few instances where skin and feather diseases are associated with hypothyroidism or thyroiditis. In such cases, birds usually exhibit symptoms like change in the colour or complex of feather or plumage, non-pruritic feather loss and anemia. Many birds may be obese which will hardly respond to dietary restriction and exercise. Blood profile may reflect the changes like non-regenerative anemia, hypercholesterolemia, mild leukocytosis and heterophilia. The birds failed to moult for more than one year. In cockatiels, hypothyroidism is associated with loss and darkening of feathers with a greasy appearance. The diagnosis of hypothyroidism is difficult in birds as the basal T4 level is very low and even beyond detection. TSH stimulation test may be confirmative; however, commercial unavailability of avian TSH stands in the way of such diagnostic test. The suspected cases may be treated with thyroxine therapy.

### 3.7.9 Delayed Moulting

Delayed moult is a frequent problem encountered in many pet or caged birds.

#### 3.7.9.1 Etiology

Several factors are implicated for such delayed moult in birds like lack of essential nutrients, endocrinological imbalance like hypothyroidism, chronic egg laying

syndrome or other concurrent illness including hypothyroidism. Lack of diurnal rhythm is an important factor responsible for delayed moult in caged birds.

### **3.7.9.2 Clinical Findings**

The affected birds display symptoms like loss of feathers, abnormality of plumage or feathers, bald spot, untidy plumage, brittle, frayed and discolored feathers. The male birds may be associated with complete or partial loss of vocalization. There may be drastic loss or excessive egg production in female birds with depression, chronic weight loss and lethargy.

### **3.7.9.3 Treatment and Management**

Management of such delayed moult is difficult as it requires many tricky manipulations. Nutritional supplementation is essential to manage the preexisting nutrient deficiency. Care must be taken to tackle the endocrinal imbalance like hypothyroidism or chronic egg laying syndrome. The diurnal rhythm for the affected birds must be established with 12–14 h of sleep time.

## **3.7.10 Abnormality of Beaks**

Abnormal presentation of the beak has been reported in many caged as well as companion birds including Amazon parrots, macaw, cockatoos, rosella and quaker. This condition causes great disturbance in picking the feeds for the birds. Moreover, it reduces the beauty of the pet birds kept in houses as show purpose.

### **3.7.10.1 Etiology**

Till date the cause of abnormal beaks is poorly understood. However, it may be due to acquired or congenital. Congenital abnormality is presumed to be associated with improper incubation temperature, aeration, ventilation, humidity and incorrect turning of eggs. This is mostly seen in case of rosella and Amazon parrot. The acquired abnormality is detected due to mechanical damage or compression as recorded frequently due to exuberant pressure applied when the birds are hand fed. Malnutrition or poor calcification may also cause softening and bending of the beaks. Other causes like mechanical trauma, PFBD virus or *Knemidocoptes* infestation may lead to such condition.

### **3.7.10.2 Clinical Findings**

The maxilla of the affected birds grows abnormally on the side (Fig. 3.9). This lateral deviation usually starts from the cere or tip of the beak. The affected birds usually fail to pick the feed particles and feed dropping from the mouth parts is very common. This situation is very commonly observed in macaws. Manibular prognathism is common in young cockatoos.



**Fig. 3.9** Overgrown beak (*Courtesy Petra Maria Burgmann, Canada*)

### 3.7.10.3 Treatment and Management

Clinical management of beak abnormality is easy when it is started at a very young age and the beak is rather soft. Gentle figure pressure applied over the abnormal beak may facilitate the beak to be reshaped in normal position. Such light digital pressure must be applied at least 10 times for 3–4 occasions in a day in 4 h interval. The birds may be allowed or encouraged to pick hard feed pellets. If the affected birds are very old or the beak has been hard with too much calcification, it is rather difficult to manage the abnormality with digital or manual pressure. In such cases, beak may be trimmed off with grinding the overgrown maxilla to allow it back in the normal position. Acrylic ramps or prostheses may be applied to correct the maxillary deviation. Orthodontic manipulation like trans-sinus pinning may be applied to rectify the lateral deviation. Similarly, such manipulation may be applied to correct the mandibular prognathism with extension of the craniofacial hinge joint into normal positioning.

### 3.7.11 Hyperextension of Maxilla and Mandible

Hyperextension of maxilla is a common nuisance detected among the macaws possibly due their constant habits of biting or picking the hard surface or solid object. This causes a forceful extension of the maxilla leading to subluxation of palatine bone. Traumatic injury may also lead to such condition. Hyperextension of the mandible may be associated with mechanical injury, damage to germinal epithelial layers, malnutrition, PFBD or *Knemidocoptes* infection and neoplasia.

In many cases, this is associated with chronic liver disease. The maxillary hyperextension is managed under general anesthesia where a blunt artery forceps is introduced through infraorbital sinus to lift the palatine bone and disengage the infraorbital plate for normal positioning of maxilla. Mandibular extension may be managed with proper nutritional supplementation, corrective measures to manage the liver diseases and trimming of the part when required.

### 3.7.12 Problem of Cere

Cere is a naked skin structure situated at the base of the maxilla and the external nares is situated within cere in case of parrots, pigeons and owls. In many birds cere may be hypertrophied due a number of factors especially due to hyperoestrogenism in female budgerigars and in many birds due to hypovitaminosis A and *Knemidocoptes* infection. Such problem may also cause discoloration of cere. Chronic illness or sartoli cell tumors in male budgerigars may cause such discoloration.

Cere abscess is a common condition in cage birds during the time of winter due to chronic respiratory infection. The condition can be easily detected with abnormal swelling, painful hyperemia, chemosis and accumulation of pus materials in the cere. Asymmetry of the nares may be detected in the birds suffering from such chronic respiratory infection or chronic rhinitis. There may be accumulation of creamy exudates and hardened materials in the form of calculi in the nares. These are known as rhinoliths. In general, treatment protocol involves extensive flushing of the area or surgical debridement to remove all the tissue exudates with prolonged antibiotic therapy. Care must be taken to remove the rhinoliths.

---

## 3.8 Diseases of the Urinary Tract

### 3.8.1 Kidney Diseases

Kidney diseases are not uncommon in birds either in the form of nephritis or nephrolithiasis. Avian kidneys are bilaterally symmetrical and lie within renal fossa. The kidney is moderately vascularized with supply of vasculature from aorta, ischiadic and external iliac arteries in the form of cranial, caudal and middle renal arteries. Interestingly, the avian kidneys have both reptilian and mammalian type of nephrons. The reptilian nephrons are more in cortex region where as the mammalian types are redundant in the cortico-medullary junction.

### 3.8.2 Renal Hypoplasia or Aplasia

Unilateral renal aplasia or hypoplasia is not uncommon in birds, however, it is mostly asymptomatic and detected during necropsy. Divisional aplasia particularly

the cranial kidney region has been noted in birds. Rarely, aplasia of middle or caudal kidney is observed.

### 3.8.3 Renal Cyst

It is another congenital disorder detected in birds. It may be solitary or multiple. Generally solitary cyst revealed no clinical significance. However, severe lesions with multiple cysts may lead to renal failure.

### 3.8.4 Nephritis with Renal Failure

It is the inflammation of kidney associated with various systemic symptoms and is mostly occurred due to infectious and non-infectious causes.

#### 3.8.4.1 Infectious Causes

A number of viral infections like Adenovirus, Circovirus, Coronavirus, Herpesvirus, Orthomyxovirus, Polyomavirus, Paramyxovirus, Poxvirus, and Retrovirus were noted to cause nephritis in birds. Many psittacine birds were known to be affected with adeno virus and the disease is characterized by non-specific and general enlargement of kidney. Although in many of the birds adeno viral infection is incidentally observed in necropsy (in love birds), polyomavirus infection may cause severe glomerulonephritis in non-budgerigar psittacine birds due to large scale deposition of IgG and viral antigen complexes and type III hypersensitivity reactions. In general, polyomaviral infection causes slight enlargement of kidneys. Non-budgerigar parrots are detected with anasarca and ascites with polyoma viral infection probably due to protein losing nephropathy or virus induced hepatic necrosis leading to hepatic failure to produce albumin in sufficient amount to maintain the colloidal hydrostatic pressure. Among other viral pathogens, important is the Paramyxovirus 1 which causes interstitial lymphoplasmacytic nephritis in pigeons.

Several bacterial pathogens are known to cause nephritis and bacteria mostly spread from ureter or via haematogenous route. Infection via blood mostly localize in the glomerular region. However, birds died of persisting and overwhelming bacteraemia or septicaemia may have bacterial burden mostly in the cortical regions with extensive multifocal lesions and interstitial nephritis. Wide varieties of gram positive or negative bacteria like *Staphylococcus*, *Streptococcus*, *Enterobacteriaceae*, *Listeria* sp., *Erysipelothrix rhusiopathiae*, *Pasteurella* sp., *Chlamydia* and *Mycobacterium* spp. are known to cause kidney infection in finches, canaries and other psittacine birds.

Fungal infection is very severe generally arising from the air sac or mycotic pneumonitis. Sometimes, infection in the form of fungal thrombosis may elicit severe necrotizing reaction in kidney tissue through haematogenous route.

Parasitic infestation like *Cryptosporidium*, *Isospora* and *Eimeria* are known to cause severe monocytic and plasmocytic interstitial nephritis in goose and ducks, however, these infections are rarely severe in pet birds. *Encephalitozoon hellem* is a potential cause of mononuclear interstitial nephritis in love birds and budgerigars with several focal lesions.

#### 3.8.4.2 Non-infectious Causes

Apart from the infectious causes, dehydration may lead to deposition of uric acid crystals in the renal tubules with severe inflammatory reactions and nephritis. Gross necropsy reveals renal swelling with white coloured chalky deposits. Transient dehydration is reversible and kidneys are able to cope up with, however, prolonged dehydration may be potentially damaging for kidneys. Similarly excessive salt ingestion may also lead to such condition.

Metastatic or dystrophic calcification with nephritis or nephrosis is commonly detected in nestling budgerigars, cockatiels and macaws particularly which are on excess calcium or vitamin D3 in the diet. In general diets having more than 0.7% of calcium usually trigger the development of such calcification. Vitamin D3 or their analog facilitates increased intestinal absorption of calcium and hypercalcemia resulting in calcium deposits in soft tissues including kidney. On the other hand deficiency of vitamin A may also cause degeneration of ureter epithelial cells with deposition of crystals and renal damage.

Besides, renal amyloidosis, renal lipidosis, exertional or high intensity exercise induced myoglobinuric nephrosis, disseminated intravascular coagulation (DIC), hemochromatosis, haemoglobin deposits may cause renal failure. Renal lipidosis is mostly associated with the birds on high fat/cholesterol diet or the birds like parrots and cockatiels with chronic active hepatitis. Toxic nephropathies are not uncommon in pet birds. Nephrotoxicity was detected among the birds particularly which are exposed to high concentration of aminoglycosides as a part of therapeutic or prophylactic strategies. Heavy metals like lead, zinc, several mycotoxins, including oosporein, citrinin, and ochratoxin may lead to such renal failure and nephritis. Sudden fluid loss may cause renal hypo-perfusion with decreased blood supply or ischemic damage to kidneys with tubular necrosis, proteinuria, and urate deposition.

Renal tumours and carcinoma is not uncommon in pet birds particularly in budgerigars. The most common symptom is unilateral or bilateral lameness/paralysis due to compression over the ischiadic nerve that passes through kidney.

#### 3.8.4.3 Clinical Findings

1. Anorexia
2. Polydipsia and polyuria
3. Regurgitation

4. Articular or visceral gout
5. High degree of prostration
6. Abdominal distension and ineffective straining mostly detected when associated with nephrolithiasis or urolithiasis.

#### **3.8.4.4 Diagnosis**

It is based on clinical findings indicating towards renal failure or symptoms of nephritis or nephrosis. Urine samples must be examined meticulously for any change. Urine samples must be checked for traces of protein, sugar, ketone bodies, blood or haemoglobin. Persistent low specific gravity of urine may indicate towards chronic renal failure. Change in pH (normally 6.0–7.5) also gives indication towards acidosis or alkalinity due to bacterial metabolism. Urine sediments should be examined after staining with methylene blue for presence of mononuclear cells like lymphocytes or neutrophils (>2–3/HPF indicates infection), bacteriuria, cellular, granular or other casts and desquamated epithelial cells.

Radiography enables the clinicians to assess normal shape and size of kidney and dystrophic or metastatic calcification can be detected with radio-dense deposits in the renal parenchyma.

Water deprivation test may be conducted confirm diabetes insipidus. The birds should be kept on gradual water restriction @ 10% for 3–5 days and then on complete withdrawal of water. The failure to concentrate urine indicates towards DI. Plasma protein, body weight and PCV should be closely monitored during the test. Similarly, to distinguish between neurogenic or psychogenic and nephrogenic vasopressin response test is done where the bird is given an oral dose of desmopressin acetate @ 0.02–0.2 mg/kg and reduction in polyuria or polydipsia within 30 min may confirm the neurogenic DI.

#### **3.8.4.5 Treatment**

In case of hyperuricaemia the birds should be treated with the following drugs—

1. Allopurinol: 100 mg tablet should be crushed in 10 ml of water and 1 ml of the same should be diluted in 30 ml of drinking water. This should be given several times a day and the birds should be kept under close supervision during treatment as it may induce skin allergies and hepatitis.

Alternative drugs are colchicine @ 0.04–0.2 mg/kg at every 24 h interval and probenecid. However, their use, dosage and safety are still unexplored.

In case of glomerulonephritis which is more common in older birds treatment with aspirin @ 1 mg/kg every day with dietary supplementation of omega-3 and omega-6 fatty acid (1:6) @ 1 ml/kg may give good response.

The affected birds must be kept under good hydration with fluid therapy in nephrolithiasis or acute renal toxicity to boost up the blood supply and eliminate the toxins @ 100 ml/kg/day for first 3 days followed by 50–75 ml/kg/day till the blood uric acid level returns to normal level.



### 3.8.5 Avian Gout

Gout is one the most important and common problem encountered in birds. It is also common in human and reptiles. The condition is caused by deposition of uric acid on body organs (visceral gout) in joints (articular gout) or in the ureters (renal constipation). It is also known as avian nephropathy or avian urolithiasis.

The disease has been detected in poultry as well as various pet birds like pigeons, cockatiels, and budgerigars (budgies). The birds which are on seed based diet and those which are fed on high protein diet.

#### 3.8.5.1 Etiology

The exact cause of avian gout is often difficult to diagnose and misleading. However, successful management often depends upon determination of the factor responsible for development of gout. In general the causes may be divided in three categories—nutritional, infectious and toxicogenic.

High level of dietary protein is mostly incriminated for development of gout. However, other factors like high calcium in diet, hypervitaminosis D3, deficiency of vitamin A may be accountable for it. High level of calcium in diet may lead to kidney damage. Sometimes marginal phosphorus deficiency may also cause it. Phosphorus is essential to protect the calcium induced kidney damage. On the other hand phosphorous acts as urinary acidifier thus prevent the formation of urate crystals in kidney or ureter. Vitamin A is also required to maintain the epithelial lining of renal tubules. Water deprivation, cold weather and other stress factors may also be responsible for gout in the pet birds. Many pet owners preferred to keep parrots on fruits. High fructose content of the fruits is believed by many to cause gout in human; however, it has not been properly confirmed.

Viral infectious agents like avian nephritis virus and nephropathogenic strains of infectious bronchitis virus may act as important predisposing factor for gout with prior damage to kidney either by virus or by the deposition of antigen-antibody complex on glomerulus with prolonged infection. Polyomavirus infection in parrot is also believed to cause kidney damage and gout. The involvement of avian pathogenic *E. coli* in gout cannot be denied also.

The list of toxins whose role is suspected in gout is too long and difficult to enumerate. However, antibiotics like aminoglycosides, mycotoxins and other toxic agents like ochratoxin A, oosporein, and deoxynivalenol (DON), excess of vitamin D, calcium, sodium all can have a potential role to induce kidney damage.

Further, poor kidney response, water deprivation, cold weather and other impending stress factors interfering the kidney's ability to adequately excrete uric acid may be responsible.

#### 3.8.5.2 Pathophysiology

Primary gout mostly results from abnormal breakdown of the protein which leads to high level of uric acid in the circulation and kidney fails to compensate the overproduction of this metabolite and excretion is no longer possible leading to deposition of uric acid crystals. The secondary gout develops due to malfunction of the

kidney which may occur due to chronic kidney diseases, over medications, overeating, consumption of increased dietary proteins, high level of vitamin D and low level of vitamin A, poor blood circulation, poor physical activity which is very common in caged birds, dehydration and stress or other environmental factors which may compromise the ability of kidney to eliminate uric acid.

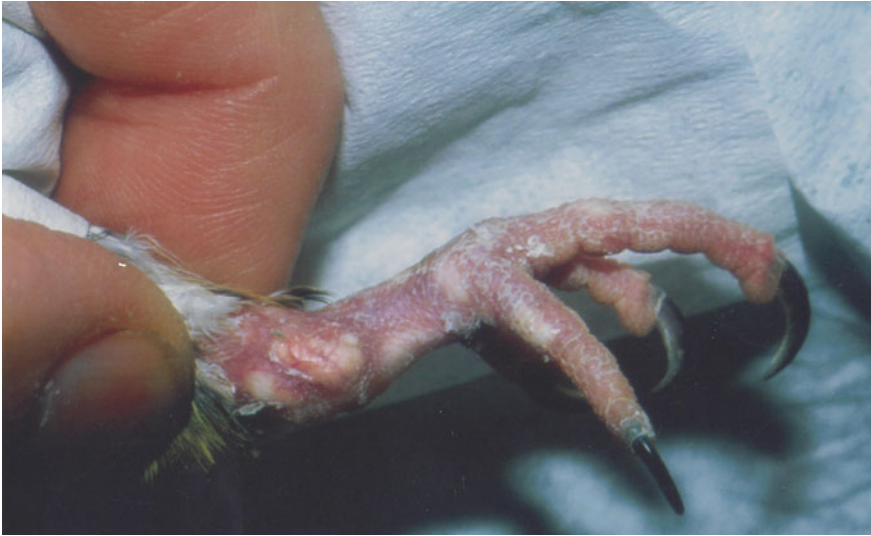Uric acid is produced in liver following breakdown of dietary proteins and deamination of the amino acids. Almost 80% of the nitrogenous waste is being excreted in the form of uric acid in birds via tubular secretion. As this process is independent of tubular water reabsorption, hydration status of the birds hardly influence the uric acid excretion. However, impairment of kidney function may interfere the excretion of uric acid leading to hyperuricemia. In human hyperuricemia occurs when the plasma concentration of uric acid is more than 380–400  $\mu\text{mol/l}$ . However, solubility of uric acid is higher in birds due to higher body temperature as well as higher sodium concentration in the avian plasma. However, when renal function is severely compromised at the level of about 70%, plasma uric acid concentration is abruptly elevated with deposition of uric acids in several locations. The high dietary protein level was often recorded to precipitate high uric acid level in the birds. This is common in budgerigars for the protein concentration of the feeding pellets. Surplus protein is catabolized and nitrogenous waste is converted into uric acid. When the total amount of uric acid produced overpower the clearing efficacy of the kidney, hyperuricemia develops and uric acid is deposited in various places. The higher plasma concentration of uric acid often leads to the development of articular gout with formation of deformed limbs and joints. Synovial joints sheaths and joints are preferred predilection sites possibly because of the lower temperature of these areas. Gradual accumulation of uric acid leads to formation of “tophi” and nodules.

Water deprivation, vitamin A deficiency, renal infection and other factors may contribute to development of urate crystals in kidney collecting ducts and tubules. Thus the condition may develop urinary incontinence in the affected birds like oliguria or anuria—a condition called acute obstructive uropathy. During such condition, tubular secretion of uric acid severely compromised leading to elevation of plasma uric acid and precipitation of uric acid in various sites including the articular areas. Several visceral organs are affected with deposition of uric acid. The site of predilection varies like heart, joints, liver and kidney. In several occasions the affected birds may be dead without any significant clinical manifestations which are more common in articular gout. The cause of death is not properly known, however, acute renal tubular failure may result hyperkalaemia leading to cardiac arrest.

### 3.8.5.3 Clinical Findings

Gout may occur in two forms—visceral and articular form. Articular form mostly affects the joints and visceral form affects the internal organs.

Joints are swollen, enlarged, painful and stiff which is evident by the continuous effort from the birds to shift their weight from one to another foot and exhibit a shuffling gait (Fig. 3.10).



**Fig. 3.10** Articular gout in a bird (*Courtesy Petra Maria Burgmann, Canada*)

With their wings affected, birds are unable to fly.

In initial stages, the urate deposition in internal organs is clinically not significant and may not be detected. However, in advanced stages affected birds become offed, lethargic, prostrated. There may be a tendency of chronic weight loss with abnormal droppings.

It is not unusual to see sudden death of the affected birds.

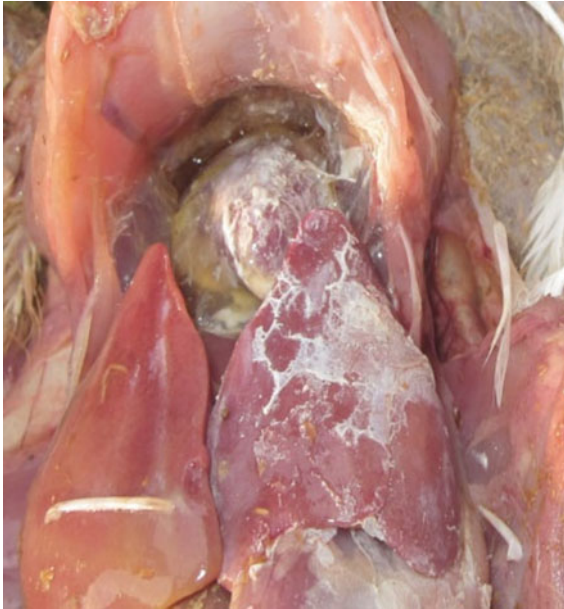#### **3.8.5.4 Pathology**

In case of visceral gout gross pathological changes may be noticed when the dead birds are opened for PM examination. Uric acid precipitate as calcium sodium urate crystals in kidney and on the serous membranes of the liver, heart, air sacs, and joints (Figs. 3.11 and 3.12).

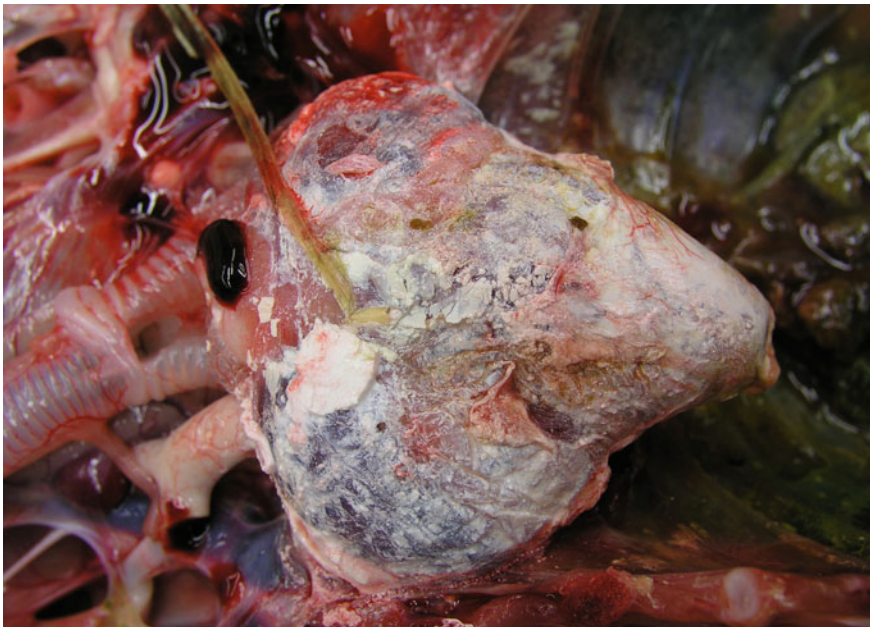In chronic cases urate deposition may be seen in trachea also. This usually appears as chalky white deposit. There is marked changes of the affected kidney like loss of lobulation and atrophy with white discolouration due to deposits of uric acid. The unaffected kidney is usually enlarged to compensate the loss of function of the affected one. The ureters are enlarged with engorgement by urate crystals. In articular gout the affected portions are swollen. When affected portions are cut open, a white semisolid material comes out.

#### **3.8.5.5 Diagnosis**

The diagnosis of avian gout is often straight forward, particularly when it occurs in the form of articular gout. The characteristic changes of the joints and limbs indicate the development of the disease. However, visceral form of the diseases



**Fig. 3.11** Chalky white deposit of uric acid crystals indicating visceral gout (*Courtesy Amrit Dhara*)



**Fig. 3.12** Chalky white deposit of uric acid crystals in pericardium of a bird (*Courtesy Prof. Richard Hoop, University of Zurich, Switzerland*)

appears without any significant clinical changes. The affected birds may die suddenly without any indication either due to cardiac arrest or acute obstructive uropathy. In such cases the bird should be carefully examined with a detailed description of diet, water intake, environmental factors, and other existing health problems. Blood should be checked for elevated uric acid level. PM examination of the dead birds may reveal the presence of chalky white deposition of urate crystals in many places like—joint fluid, heart, kidney and liver.

### 3.8.5.6 Treatment

The treatment requires a holistic approach for successful treatment of the affected birds. Adequate water supply is the mainstay of therapy. The birds may be given subcutaneous or intravenous fluid like normal saline or supplementation for acute management of the water deprivation. Ringer's lactate is often recommended for restoration of sodium potassium imbalance. In case of articular gout the birds become anorectic and proper dieting is required with high calorie content for restoration of body weight. A low protein diet is preferred to prevent the rise of plasma uric acid concentration. Calcium, phosphorous, magnesium, sodium and vitamin D3 levels should be reduced in affected birds to avoid kidney mineralisation.

Other approaches include supplementation of vitamin A which is essential for repairing the damage of tubular epithelial cells and thus prevent the foci for infection or uric acid deposition. Acidification of urine using ammonium chloride, ammonium sulphate, DL-methionine, and methionine hydroxy analog is advocated to dissolve and flush out the crystals.

Medication involves application of allopurinol (10–30 mg/kg, PO, bid) or colchicines (0.04 mg/kg, PO, sid-bid). However, their efficacy is still to be understood in birds. Many studies pointed out that although allopurinol may be an effective therapy of gout in mammals, same is not true for birds. Allopurinol may cause nephrotoxic damage due to its derivative oxypurinol or due to the crystals of xanthine, hypoxanthine. Furosemide @ 1 mg/kg may be given to counteract the oliguria or anuria. However, its efficacy in acute obstructive uropathy is questionable. Corticosteroids and butorphenol are indicated for management of pain.

The prognosis for a bird with gout is generally poor. Most birds will need to be treated for life or the condition will quickly reappear if therapy is discontinued. If arthritis from gout is severe, it is possible to surgically remove the uric acid crystals from the joint. Often the damage to the joints or organs is irreversible.

### 3.8.6 Avian Urolithiasis

Avian urolithiasis is the main cause of obstruction in the lower urinary tract. Although it occurs in both males and females, urolithiasis is more common in males in case of mammals due to their long, narrow urethra. In birds the most common site of obstruction is cloaca or ureter. The one or both ureter may be

involved. The calculi are mainly composed of uric acid crystals and proteinaceous matrix.

### 3.8.6.1 Etiology

A common predisposing factor in case of the birds is the period of egg incubation when the birds sit tightly over the egg which causes ineffective purgation of the cloacal content and deposition of the uric acid crystals and formation of urolith. Thus it is disease primarily of the laying flocks. Other factors include—

- Deficiency of vitamin A or B vitamins
- Bacterial infection leading to cystitis, urethritis, nephritis
- Infection with nephropathic strain of infectious bronchitis virus
- Excess dietary calcium and phosphorous
- Deprivation of water
- Alteration of urine pH due to dietary change
- Presence of mycotoxin like ochratoxin and oosporein in feed
- Nephritis.

### 3.8.6.2 Clinical Findings

The mortality rate may reach up to 20–50% in the affected population. Sudden death is the prominent symptom noticed in most of the conditions.

- Besides the birds may exhibit
- Chronic anorexia
- Weight loss
- Anaemia with pale comb.

Frequent ineffective or non-productive straining and pasting of white chalking materials around the cloaca is noticed in many birds.

### 3.8.6.3 Post-mortem Findings

The ureters are generally distended containing hard compacted white mass composed of calcium sodium urate (Fig. 3.13).

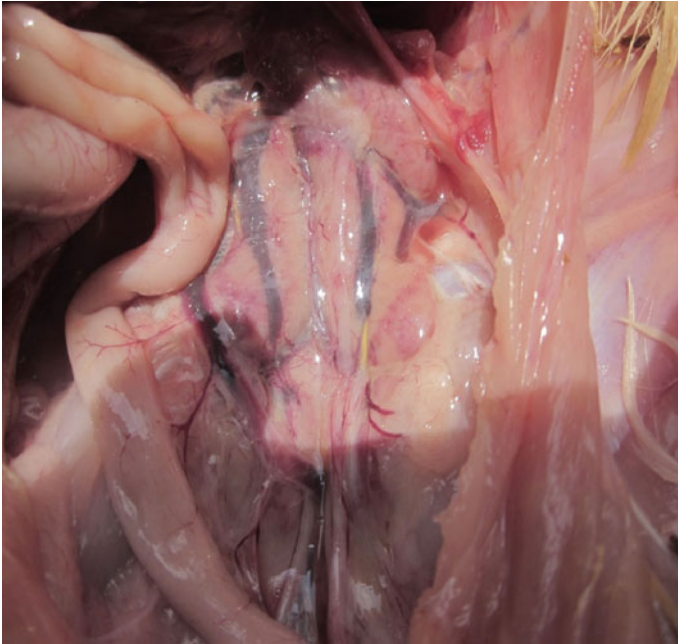
The obstruction may lead to swelling of the kidneys—hydronephrosis (Fig. 3.12). It is not unusual to find the atrophied kidneys in long standing cases..

### 3.8.6.4 Diagnosis

Urethral obstruction can be diagnosed by palpating a distended and painful bladder.

Post-mortem finding may give a definite diagnosis.

Radio-dense calculi can usually be seen under X-ray. However, contrast radiography or intravenous pyelography and ultrasonography are effective to locate radiolucent calculi.



**Fig. 3.13** Hydronephrosis due to obstructive urolithiasis (*Courtesy Amrit Dhara*)

### 3.8.6.5 Treatment

1. Arrange must be taken to ensure optimum uptake of water by the affected birds.
2. Dietary modification to acidify the urine using ammonium chloride, ammonium sulphate and methionine is helpful.
3. In many cases surgical intervention may be helpful but recurrence is common and care must be taken to avoid urethral stricture. Using forceps it is possible to break and remove the cloacal calculi. Post-surgical antibiotic therapy is recommended in such intervention.

---

## 3.9 Diseases of the Reproductive Tract

### 3.9.1 Metritis, Salpingitis and Impacted Oviduct

The disease involves inflammation of the oviduct and shell gland. The metritis and salpingitis along with egg binding or dystocia often leads to impacted oviduct characterized by accumulation of inflammatory exudate, excess mucin, albumen,

and soft-shelled or malformed eggs. These materials often become thickened and get adhered to the wall of the oviduct.

### 3.9.1.1 Etiology

The condition is more commonly seen among the psittacines. Few factors were identified to cause such condition like age, lack of nutrition, calcium deficiency, egg trapping, abnormal egg production, chronic egg laying syndrome or other reproductive diseases. Viral infection like infectious bronchitis, Newcastle disease or hematogenous bacterial infection with *E. coli*, *Salmonella* spp., *Klebsiella* spp. and *Pseudomonas aeruginosa* may predispose the birds with such condition.

### 3.9.1.2 Clinical Findings

Depending upon the severity of the lesion and conditions the birds may exhibit the signs like abdominal distension, pain, lethargy, weight loss, dyspnoea and anorexia. There may be history of infertility or embryonic death. The eggs are abnormally shaped, malformed with tinges of blood. Putrid or haemorrhagic discharges may be noticed from the cloaca with flaccid vent.

### 3.9.1.3 Diagnosis

The clinical symptoms with previous history of excessive egg laying, dystocia, egg binding are suggestive of the disease. Case of metritis or salpingitis without any impaction may be associated with flaccid vent with occasional cloacal discharges. Blood picture reveals the presence of leucocytosis especially with heterophilia and monocytosis indicating systemic inflammatory reaction. Such conditions can also reveal blood biochemical changes like high total protein, cholesterol, and triglyceride concentrations. Radiography, USG may be used to detect abdominal fluid accumulation, egg trapping/dystocia and impacted oviduct with inflammatory exudate.

### 3.9.1.4 Treatment

1. Broad spectrum antibiotics (Enrofloxacin @ 15 mg/kg IM twice daily; Amoxycillin trihydrate @ 150–250 mg/kg) along with fluid therapy (isotonic fluid @ 50–100 ml/kg) are advocated to check the infection and rejuvenate body condition.
2. NSAID like meloxicam @ 0.2 mg/kg orally or SC SID may be used to reduce the inflammation and provide relief.
3. PGE<sub>2</sub> may be used to relax the uterovaginal sphincter and to increase motility of the oviduct. Salpingohysterectomy is advocated in extreme cases.



### **3.9.2 Excessive Egg Laying or Chronic Egg Laying Syndrome**

This disease or condition is noticed mostly among cockatiels and other small birds like budgerigars and lovebirds. The affected birds lay more than what they usually do or produce more eggs than normal. The birds may exhibit larger clutches of egg laying or repeat clutches. In general, wild cockatiels lay 1–2 clutches of eggs per year. However, pet cockatiels with CES may lay more than 2 clutches of eggs during this period. This condition if left untreated may lead to serious conditions like egg binding, salpingitis, metritis, egg yolk peritonitis and pathological fractures with depletion of body calcium reserve.

#### **3.9.2.1 Etiology**

Multiple causes were detected to have a complex relationship with development of such condition. The birds fed on high calorie, carbohydrate or fat rich diets, those which are given sweet food items like fruits or seeds are more prone. Besides, intimate bonding to other bird in the cage or owner, secure and congenial nest or egg laying sites, exposure to extended photoperiod (>10–12 h) and inappropriate diurnal rhythm are known to be important risk factors. Hormonal imbalance may also drive such condition in pet birds.

#### **3.9.2.2 Clinical Findings**

The clinical manifestations may not be indicative and no specific symptoms may be observed other than laying of eggs over extended period of time or clutches. The affected birds may show signs of poor health status, depression, lethargy weight loss and frequent pathological fractures. Otherwise poor reproductive tract status may be evident with discharges, dystocia, impacted oviduct, cloacal prolapse, abnormal eggs, and egg yolk peritonitis. The birds may show changes in defecation.

#### **3.9.2.3 Diagnosis**

The chronic egg laying behaviour itself is indicative; however, biochemical indication of hypercalcemia, radiographic evidence of hyperostosis and eggs in the oviduct, hyper-triglyceridaemia, and hyper-cholesterolaemia may further reinforce the diagnostic confirmation.

#### **3.9.2.4 Management and Prevention**

The management of such syndrome is tricky and may require the expertise of an experienced veterinarian. Multiple factors must be considered before intervention.

Counselling of the affected birds is important when the other companion bird is detected to have an intimate relation with the diseased one. The removal of the companion bird is necessary. The owner must be made aware how his behaviour may bring such changes in the pet. The client education and training is important. He must be taught what kind of his dealing may sexually stimulate the birds. The

laid eggs must not be removed from the cage or it may be replaced with an artificial one. This may be helpful to stop such egg laying behaviour at least temporarily.

The change of food habit is very important. A feasible approach can be done by reducing the level of readily available sugar or carbohydrate and fat in the food and increasing the fibre portion. Indulging the foraging behaviour among the pet birds is also an important factor for rapid recovery.

The birds should not be exposed to photoperiod beyond 8 h. The surrounding environment of the birds needs to be changed as the affected birds may have an optimum and congenial atmosphere for laying their eggs. Changing the atmosphere, cage often substantially decrease their attachment and easiness for laying eggs.

As calcium reserve is substantially depleted, a supply of calcium in the form of 10% Calcium gluconate @ 50–100 mg/kg, SC, IM or oral Calcium glubionate @ 25 mg/kg, twice daily should be given.

Hormonal therapy alone is seldom effective unless other interventions are not taken. Leuprolide acetate as GnRH agonist may be given @ 700–800 mcg/kg, IM, every 2–3 wk. Similarly, GnRH agonist deslorelin acetate in the form of implants of 4.7 and 9.5 mg at every 3–6 months is effective. Medroxyprogesterone acetate @ 5–25 mg/kg every 6 weeks is also suggested by many clinicians along with HCG @ 500–1000 IU/kg every 2–4 weeks. As antibodies to HCG develop rapidly concurrent application of corticosteroid is implicated to induce immune suppression.

### 3.9.3 Egg Binding

Egg binding or dystocia is a common phenomenon among the love birds, cockatiels and budgerigars. This is an emergency condition when the affected birds are dyspnoeic and fainted and corrective measures are immediately required.

#### 3.9.3.1 Etiology

There are various factors which may cause such condition. Very young as well as old birds are more prone. Besides, malnutrition, calcium deficiency, diseases of oviduct—like myositis, metritis and salpingitis, loss of muscular tonicity, malformed egg and abnormally big eggs, vitamin A deficiency, chronic egg laying syndrome, inappropriate environment are commonly associated with such disease. Egg binding in large psittacine birds is generally attributed to obesity, behavioural abnormalities and environmental effect. Systemic illness, environmental stress or infection involving the urogenital system may also cause such egg binding.

#### 3.9.3.2 Clinical Findings

The birds are generally depressed and show abnormal distension of abdomen. The eggs may not be always palpable. The birds usually lay egg at an interval of 23–26 h, therefore, appropriate time gap must be given and the birds should be kept on watch. In severe cases, birds are dyspnoeic with a “penguin like posture” and may collapse.



**Fig. 3.14** Retention of egg/egg binding in a lovebird (Courtesy Prof. Elena Circella, Avian Diseases Unit, Department of Veterinary Medicine, University of Bari, Italy)

### 3.9.3.3 Diagnosis

Clinical presentation may indicate dystocia (Fig. 3.14). Abdominal manipulation may reveal the presence of eggs. However, the soft shell eggs may not be palpable. Radiography may be helpful to detect the abnormal location of the egg.

### 3.9.3.4 Management

Birds are kept in a comfortable, stress free warm and humid chamber. To increase the muscle tone of the oviduct, 10% Calcium gluconate @ 50–100 mg/kg, injection should be given at every 6 h. The birds may be fed highly digestible and carbohydrate rich food to provide immediate energy. Intra-cloacal PGE2 gel application may stimulate uterovaginal sphincter dilation and subsequent release of eggs. Manual

manipulation may be necessary in few cases. Oxytocin injection @ 5–10 U/kg, IM may be given. If the bird is dyspnoeic, immediate intervention should be done for ovocentosis and egg collapse. The egg content should be extruded out using a large gauge needle and eggs may be collapsed with digital manipulation.

### 3.9.4 Egg Yolk Peritonitis

This condition is also referred as egg yolk coelomitis or egg peritonitis and is a common cause of abdominal distension in laying hens of all age groups among the pet birds, most commonly in cockatiels.

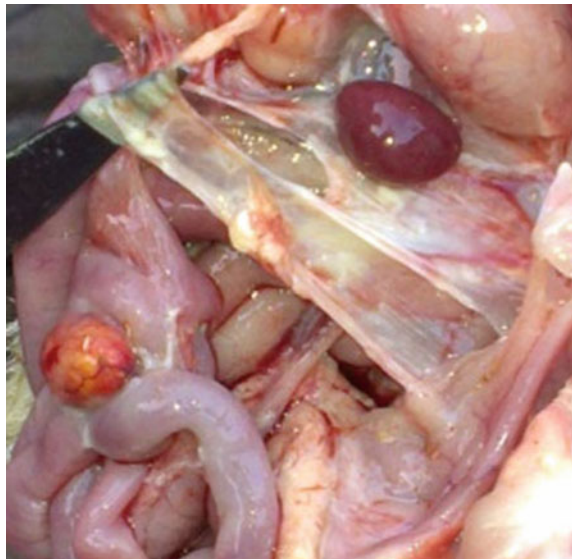
#### 3.9.4.1 Etiology

It is generally thought to be a common sequela of chronic reproductive disease and detected after salpingohysterectomy as in most of the cases there remains the residual of ovarian tissues and ovulation occurs in the peritoneal or coelomic cavity. There are other possible factors which can trigger such condition like metritis/salpingitis, cystic ovarian disease, neoplasia, ectopic ovulation, egg impaction, reverse peristalsis, ruptured oviduct and failure of the infundibulum to entrap the egg yolk due to pre-existing diseases like infection, trauma, disease or excessive fat deposition.

#### 3.9.4.2 Pathophysiology

The egg yolk as such is not responsible for more than a mild inflammatory reaction as it is rapidly reabsorbed by the peritoneum. However, as the egg yolk is an

**Fig. 3.15** Egg yolk peritonitis in a bird (*Courtesy Amrit Dhara*)



excellent source of nutrient, secondary infection can hardly be avoided causing a severe peritonitis and systemic reaction. Sometimes already contaminated or infected egg yolk spilled in the coelomic cavity may cause the infection. Most common secondary invaders include *E. coli*, *Staphylococcus* spp., *Salmonella* spp. etc. Ultimately it leads to localized or diffused fibrinous peritonitis (Fig. 3.15) and ascites. The infection may spread and lodge to different organs causing pancreatitis, hepatitis, splenitis, nephritis, multi-organ failure and death.

### 3.9.4.3 Clinical Findings

The birds may exhibit severe abdominal distension, fluffed feathers, dyspnoea, lethargy, severe straining, lack of vocalizations, depression, and pain on palpation of the abdominal region, swollen vent soiled with yolk-coloured droppings, ascites, and neurological symptoms due to severe septicaemia. A more common sequel among the broiler birds is abdominal herniation due to increased intra-abdominal pressure with distension of abdomen.

### 3.9.4.4 Diagnosis

A severe case of peritonitis with septicaemia brings considerable changes in blood profile characterized by leucocytosis and heterophilia. Abdominocentesis may be done when ascites is suspected. The peritoneal fluid will have an albumin like yellow cooked appearance. The exudate may be caseous with offensive smell. The abdominal fluid will contain egg yolk, fat globules, fibrin deposit, bacteria and heterophils, macrophages, lymphocytes or other PMN. Bacteriological investigation with the fluid will be helpful to reveal the infective organisms. Serum amylase level will be high if there is concurrent pancreatitis. Radiography reveals the egg binding, an enlarged oviduct and presence of abdominal fluid. Similarly, ultrasonography is helpful to detect peritoneal fluid accumulation along with inflammation of the internal organs.

### 3.9.4.5 Treatment

If the affected bird is suffering from respiratory distress, abdominocentesis may be performed to relieve the patient. A long term therapy is required to support the bird with fluid, antibiotics and NSAID. If there is suspicion of oviduct impaction or egg binding or presence of exudate in the oviduct, PGE<sub>2</sub> may be used to relax the uterovaginal sphincter and facilitate the clearance of oviductal content with stimulation of contractility. Although most of the birds respond to this management and intervention, salpingohysterectomy is required in extreme cases. In case of broilers hens with many number of ovarian follicles develop a problem known as erratic oviposition and defective egg syndrome (EODES) characterized by abnormal eggs, oviductal herniation, prolapse, internal ovulation and egg peritonitis. This is managed by avoiding light stimulation of the pullets.

### **3.9.5 Cystic Ovarian Disease**

The ovarian cysts may be of congenital origin or acquired following neoplasia or oophoritis. The affected birds are generally not capable of laying eggs for many years. Cysts may be developed either in solitary or multiple forms.

#### **3.9.5.1 Clinical Findings**

The birds with small or solitary cyst may not present any symptoms. However, those are with multiple large sized cysts exhibit various symptoms like abdominal distension, swelling, pain, discomfort, ascites and respiratory distress. Fluid accumulation in the abdominal cavity may be confirmed by abdominal palpation. Budgerigars and canaries are commonly detected with such condition.

#### **3.9.5.2 Diagnosis**

Radiography and USG may be used to detect accumulated fluid, the cysts and other space occupying lesions. Abdominocentesis may be employed to check the nature of accumulated fluid.

#### **3.9.5.3 Treatment**

If the affected birds is dyspnoeic and indicates any emergency, it should be immediately relieved by abdominocentesis.

Antibiotic therapy may be given in case of secondary infection. GnRH agonists, leuprolide acetate and HCG are useful in primary cases. In case of severe infection or when malignancy is suspected ovariectomy may be suggested.

### **3.9.6 Prolapse of Cloaca**

Birds with excessive straining are prone to cloacal prolapse. There are few behavioural factors which have been identified for cloacal prolapse like sexual overwork, masturbation by male cockatoos, intimate dependence or relation with the owner, delayed weaning, tendency to hold the defecation. Besides, oviductal diseases, metritis, salpingitis, diarrhoea, constipation, abdominal straining due to distention of enlargement of visceral organs may lead to such condition.

Cloacal prolapse is easy to correct and treat if detected early. However, if it is left untreated, the prolapsed tissue may develop inflammatory changes, becomes oedematous and necrotic and is very difficult to repose. Hyperosmotic fluid, sugar should be placed to reduce the oedema and the tissue needs to be flushed and cleaned with normal saline. Then the prolapsed portion is to be replaced. It may be lubricated for easy rectification. Silver sulphadiazine, neomycin or gentamicin solution may be given to protect from further infection. Suture may be given to prevent prolapse. Behavioural modification is necessary for permanent cure. Cloacopexy with vent reduction may be required in extreme cases.

## 3.10 Malignancy and Tumours

Neoplastic diseases are detected among the pet birds in variable frequency. Due to limited works it is difficult to predict on their real time epidemiology, however, compared to the age, the occurrence is quite high. Cutaneous form of neoplasm is quite common. Neoplasms of other organs including the visceral one are also not uncommon. However, no systemic study has been conducted to determine the risk factors associated with such occurrence. Like human and other animals, it is thought that chronic irritation, stress, long term consumption of toxic chemicals, lack of antioxidants in foods and environmental factors are responsible for induction of neoplasia.

### 3.10.1 Pituitary Neoplasia

Pituitary adenoma is the most frequently reported endocrine neoplasia in birds particularly among the young male budgerigars. The adenoma or adenocarcinoma of pituitary gland involves the chromophobe cells of the anterior lobe.

#### 3.10.1.1 Clinical Findings and Pathophysiology

Due to development of space occupying lesion and increased intracranial pressure with compression of cranial nerve, optic chiasm and hypothalamus neurological symptoms may be developed like—seizures, convulsion, circling, depression, somnolence, fatigue, loss of consciousness and behavioural changes. Pressure on eyeballs may cause mydriasis, unilateral or bilateral exophthalmos, visual impairment, and blindness with infiltration of neoplastic cells in the optic nerve.

Pituitary adenoma is often associated with polydipsia and polyuria probably mediated by decreased concentration of anti-diuretic hormone and increased concentration of adrenocorticotrophic hormone. Pituitary adenoma with posterior lobe compression may cause decreased transport and storage of ADH. Similarly, increased secretion of ACTH causes cortical hyperplasia, release of corticosteroid and steroid induced diuresis. Changes in pigmentations may be noted in budgerigars and cockatiels as reflected by changes in feather and cere colour.

#### 3.10.1.2 Treatment

In general no treatment option is available. To control seizures or convulsion phenobarbital @ 5–8 mg/kg orally BID may be given. The dose requires to be increased gradually.

### 3.10.2 Thyroid Adenocarcinoma

The thyroid hyperplasia is very common among the budgerigars reared in iodine deficient soil regions. Similarly, thyroid adenoma adenocarcinoma is not very infrequent among the birds. It is relatively common in human and pet dogs and cats. Thyroid cancers usually arise from cancer of follicular and para-follicular cells of the thyroid gland. The malignant cells may give rise to carcinoma comprising of well differentiated or poorly differentiated anaplastic cells.

Histologically, thyroid cancers may be of various types—

1. Papillary thyroid cancer
2. Follicular thyroid cancer
3. Medullary thyroid cancer
4. Anaplastic and poorly differentiated thyroid cancer
5. Non-invasive follicular thyroid neoplasm.

#### 3.10.2.1 Causes

Among pet birds thyroid cancer has been detected among budgerigars and cockatiels. In general, it is difficult to determine the cause of thyroid neoplasm. However, genetic and environmental factors are often thought to play an important role for such development. Continued exposure to natural or artificial ionizing irradiation may lead to such circumstances.

#### 3.10.2.2 Clinical Findings

The disease starts with formation of unilateral swelling or nodule around the thyroid gland at neck region. Thyroid cancer may occur in euthyroid birds therefore, symptoms of hypo or hyperthyroidism may or may not accompany. Other symptoms include dyspnoea, change or loss of voice due to pressure on recurrent laryngeal nerve or other non-specific symptoms like melena, weight loss and sudden collapse.

#### 3.10.2.3 Diagnosis

The clinical symptoms, plasma thyroid profile along with USG of the thyroid region to detect any mass and status of the thyroid tissue may give some indication. Fine needle aspiration from the mass and its histological examination usually gives the confirmatory diagnosis. Thyroid adenomas are characterized by large follicles which are lined by columnar epithelial or cuboidal cells with minimum or no colloid. The adenocarcinoma reveals poorly differentiated cells which may invade the capsule or surrounding structures. Generally thyroid carcinoma is constituted of aberrant, large and firm structure with considerable distortion of thyroid and non-thyroid surrounding tissue.



#### 3.10.2.4 Treatment

As prognosis is poor, treatment should be initiated with proper consideration of feasibility. Aggressive surgical intervention may be done for thyroidectomy followed by chemotherapy and radiation.

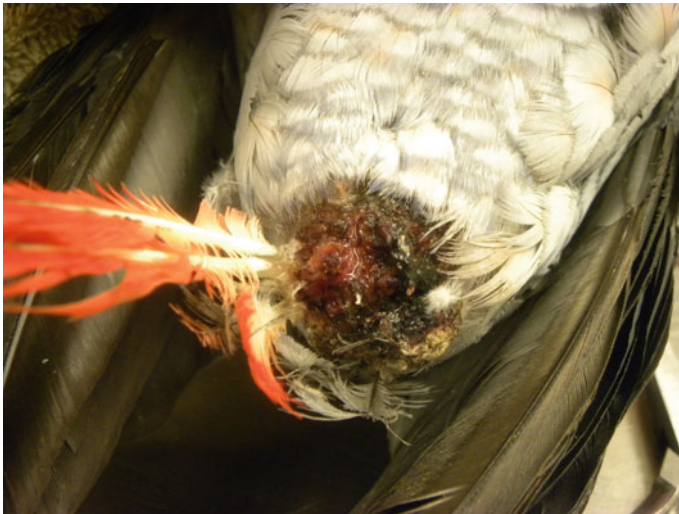### 3.10.3 Squamous Cell Carcinoma

Squamous cell carcinoma (SCC) is the cancer of a kind of epithelial cells and it is comprised of undifferentiated or poorly differentiated squamous cells. Although it is mostly detected in integumentary system including beak, skin, phalanges, wings however, its occurrence is also detected in the muco-epithelial cell lining of gastrointestinal system (oesophagus, oral cavity, crop), respiratory system (nasal or infraorbital sinus). Metastasis occurs rarely but not impossible. However local invasion occurs very frequently.

There is no known definite cause for SCC, however, constant irritation or chronic inflammation may be a triggering factor for it. Similarly chronic exposure to sunlight or UV radiation may be another responsible factor.

#### 3.10.3.1 Clinical Findings

The SCC develops most commonly at skin, beak, wings, and phalanges, in the oral cavity, oesophagus, crop and sinuses (Fig. 3.16). In the skin or outer surface there may be formation of tumours and bleeding ulcers which are not amenable to treatment leading to necrosis. The beaks may be deformed with overgrowth. The



**Fig. 3.16** Squamous cell carcinoma in an African grey parrot (*Courtesy* Kenneth R. Welle, Clinical Assistant Professor, University of Illinois, United States)

tumours in oral cavity, oesophagus and sinuses cause severe haemorrhagic and necrotic nodules. The birds may suffer from dysphagia, anorexia, regurgitation, dyspnoea, depression, keratoconjunctivitis with exophthalmos and severe oculo-nasal discharges. Secondary bacterial or fungal infection is possible in these lesions.

### **3.10.3.2 Diagnosis**

Confirm diagnosis can be done by collection of fine needle aspirate from the suspected tissue sample and biopsy of the lesion. Microscopically, the SCC appears as well differentiated or poorly differentiated cells that form nests and cords with keratin centres. Cells are detected to be diffusely infiltrative. SCC may affect the uropygial gland where it needs to be differentiated from adenoma. In adenoma where solitary firm nodule or mass is developed and histologically well differentiated cells are observed. However, the carcinomatous growth tends to be constituted of poorly or undifferentiated cells and is usually, inflamed, haemorrhagic and infected with secondary bacterial invasion.

### **3.10.3.3 Treatment**

Surgical excision of the mass/growth is the best option for treatment. It may be accompanied by radiation and chemotherapy. Radiation therapy with strontium-90 probe has given some promising result in SCC involving uropygial gland. Similarly cobalt-60 has been used with intra-lesional chemotherapy using carboplatin and cisplatin.

## **3.10.4 Xanthoma**

Xanthoma is the non-cancerous tumours which appear in the form of diffuse thickening or little masses and dimple over the integuments. Psittacine birds including cockatiels and budgerigars are commonly affected. High fat deposition is common cause of xanthomas in birds.

### **3.10.4.1 Clinical Findings**

The lesion can appear in any part of the body. However, wing tips, breast and legs, cloaca, vent and ventral abdominal regions are most likely noticed with xanthomas. The areas are extremely irritating and often cause pruritus in the birds. This leads to erosion and bleeding in the self-traumatised areas. Secondary bacterial infection may complicate the condition further. In case of budgerigars the xanthomas tend to expand and extend to the other areas like neck, breast, side of the wings and joints and restrict the activity of the bird. Infiltrated areas are friable and may be easily damaged. It may become ulcerated and easily infected further. Moreover, due to high vascularization of the areas and destruction of capillaries with the enlarged mass often led to sudden haemorrhagic episodes and sudden death.

### **3.10.4.2 Treatment**

No particular therapy is available for the condition. Nutritional supplementation particularly with vitamin A may relieve the condition to some extent. In several cases surgical intervention to excise the portion is only effective remedy. However, if the xanthomas are big enough, surgical amputation is not recommended as it is difficult to close the lesion and control bleeding. Seed based diet with high cholesterol content is considered to play an important role for xanthoma. Therefore, affected birds should be kept on a balanced diet with more supplementation of fruits and vegetables. This may reverse the hyperlipidaemia and help to reduce its accumulation in the cutaneous or subcutaneous layer.

### **3.10.5 Fibrosarcomas**

Fibrosarcoma is the neoplastic cells originated from mesenchymal cells or fibroblasts with the ability to produce collagen and usually involve the soft tissues of wing, leg, phalanges, head, beak, cere and trunk. This is a common neoplastic disorder detected among a variety of caged birds like macaws, budgerigars, cockatiels and parrots.

#### **3.10.5.1 Clinical Findings**

Clinically fibrosarcomas appear as solitary or multiple nodules with roots and they tend to be ulcerative, haemorrhagic and prone to secondary infection. Visceral form of fibrosarcoma involves multiple organs like liver, spleen, pancreas, abdominal cavity, proventriculus, small intestine, testes and ovary. They are locally invasive and may metastasize to other organs and even to muscles and bones. The visceral form develops symptoms depending upon the organs and degree of involvement.

#### **3.10.5.2 Treatment**

Surgery with radiation therapy is recommended. Superficial form may be surgically removed; however, prognosis is guarded for visceral form.

### **3.10.6 Lipoma and Liposarcoma**

Lipoma is the most frequently observed benign tumour detected among the pet birds. It is the neoplastic growth developed from the adipocytes or lipocytes. Liposarcomas are malignant form and arise from immature adipocytes and lipoblast. Lipoma is soft and smooth round shaped where as liposarcomas are firm, highly vascular and poorly encapsulated.

### 3.10.6.1 Risk Factors

It is very common among the budgerigars followed by cockatoos and amazon parrots. Possibly in budgerigars there is some degree of genetic predisposition. Besides, high fat/energy diet and obesity are the other factors that may lead to such lipoma. Liposarcomas are found in sternum and uropygial gland area. The liposarcomas are locally invasive and can metastasize to other areas including skeletal muscle, liver or other organs of abdominal cavity. Liposarcomas were described in cockatiels, budgerigars, conure, African grey parrot, and quaker parakeet.

### 3.10.6.2 Clinical Findings

The birds are usually presented with solitary or multiple nodules in the skin or subcutaneous tissue particularly in the sternal or abdominal region. Besides, lipoma may be present in wings, legs, back, neck and uropygial gland region. The mass usually varies from 0.3 to 4 cm in diameter. Arising from thoracic or mesenteric fat the lipoma may be developed in the internal organ like ovary and liver. The mass may be itchy, traumatized and ulcerated and secondary bacterial or fungal infection is not impossible.

### 3.10.6.3 Treatment

Dietary management is necessary. The birds should be kept on low energy and low fat diet. Affected birds should be also encouraged for exercise. This can be substantially helpful for utilization of fat and reduction of the size of lipoma. Surgical excise of lipoma may be executed if it causes any clinical problem for the birds. Large lipoma affecting air sac may cause respiratory difficulty in birds. Besides, lipoma affecting wings and limbs may interfere with their movement. Generally lipoma and liposarcoma are highly vascular, therefore proper care must be taken before surgical intervention.

## 3.10.7 Neoplasia of Liver

Neoplasia of liver in birds may be of primary origin or it may be secondary to metastasis from other organs. Among the primary hepatic neoplasia, hepatocellular carcinoma and bile duct carcinoma are very frequent. Cholangiocarcinoma are the most common hepatic neoplasia reported among the captive and free ranging birds. This originates from the bile duct epithelial cells causing obstruction of the bile duct. Further involvement of hepatic parenchyma is also very common.

Bile duct neoplasia may be detected in the intra-hepatic, extrahepatic or peri-hilar region of liver. Although not clearly known, chronic inflammatory process with stasis of the bile duct leading to hyperplasia or metaplasia of bile duct may lead to cholangiocellular carcinoma.

Clinical symptoms include abdominal distention, change in liver function test, pain, generalized itching, mal-digestion, weight loss and emaciation. Neurological symptoms like somnolence, ataxia and seizures may be exhibited by the affected

birds due to hepatic encephalopathy. Haematogenous spread of cholangiocellular carcinoma to distant organs like lung, kidney and pleura has been reported. It is potentially fatal disease with very little therapeutic option except rapid identification and surgical excision of the primary neoplasia.

Hepatocellular carcinoma or malignant hepatoma is also detected among the birds. Viral infection or chronic exposure to mycotoxin may be triggering factor for initiation of HCC. Clinical symptoms include, abdominal enlargement with fluid accumulation, painful palpable enlarged hepatic lobes, regurgitation and offensive foul smelling diarrhoea. The affected birds are often presented with debilitated and emaciated stage. Metastasis is rarely detected to occur in lung. Treatment is not effective however; hepatectomy to remove the affected part may be tried.

### **3.10.8 Pancreatic Neoplasia**

Neoplasia of pancreas—pancreatic adenoma and adenocarcinoma were reported in Amazon parrots, macaws and large psittacine birds. The human pancreatic cancer was linked to various risk factors like over consumption of alcohol, meat, smoking however, such association was not established in birds. The pancreatic cancer mostly involves the neoplasia of cells of the gland that produces digestive enzymes. The pancreatic duct epithelium as well as acinar cells is involved. Clinical symptoms include, unexplained weight loss, improper digestion and abdominal enlargement or effusion.

### **3.10.9 Renal Neoplasm**

Renal neoplasm is occasionally detected in the budgerigars. It is generally associated with articular gout, abdominal distension and inability to perch or ambulate. The exact etiology is not known; however, it is generally associated with and originated from embryonic nest cells in kidney. Renal carcinoma may metastasize to adjacent bone, muscle and liver. Due to compression over the sacral plexus clinical posture related symptoms are exhibited. Due to aggressive metastasis, it is quite difficult to treat renal neoplasm. Surgical excision of the affected part/kidney and planting radioisotope may be tried.

### **3.10.10 Lymphosarcoma**

Lymphosarcoma (malignant lymphoma) is the cancer of lymphoid organs and is a common neoplasm of psittacines and passerines. The cancer tissue may affect multiple organs and most common site of metastasis is liver followed by kidney and spleen. Although many of leukaemia were linked to viral infection in domestic

animals like feline pan-leukaemia virus, such association was not found in pet birds. Other areas like GI tract, skin, bone, oviduct, lungs, sinuses, thymus, testes, brain, mesentery, trachea, and pancreas may be involved with metastatic growth of lymphosarcoma.

#### **3.10.10.1 Clinical Findings and Pathology**

The clinical symptoms vary with the organ/tissue involved. The involved visceral organs like liver, pancreas, spleen and kidney are abruptly enlarged. Thickening and opacity are noticed following serosal infiltration of neoplastic lymphoid cells which ultimately causes enlargement and paleness of the internal organs. In case of cutaneous involvement, lesions are noticed in head and neck region. Other symptoms include anorexia, weight loss, depression, coelomic distention, paresis, lameness, blindness, regurgitation, or dyspnoea. In many cases of exophthalmos in psittacines particularly among young African grey parrots have been identified as a sequel to retrobulbar lymphoma. The neoplastic lymphocytes can be microscopically identified with little or moderate amounts of amphophilic to eosinophilic cytoplasm and a central nucleus containing reticulated to coarse chromatin.

#### **3.10.10.2 Diagnosis**

Clinical symptoms may not provide sufficient clues for diagnosis of lymphosarcoma. However, the cases may be suspected on the basis of persistent anaemia (PCV < 35%), marked leucocytosis and lymphocytosis in complete blood count accompanied by symptoms like fatigue, depression, weight loss, respiratory difficulty, abnormal and enlarged mass in the coelomic cavity (particularly in visceral organs like liver, pancreas, kidney), abdominal pain, peripheral lymphadenopathy. Imaging technique like radiograph and USG may be helpful to detect such masses. Fine needle aspiration and biopsy of such masses will be helpful for confirmatory diagnosis.

#### **3.10.10.3 Treatment**

Surgical removal of the affected part of organ or mass followed by chemotherapy using the drugs like chlorambucil, doxorubicin, vincristine sulphate and cyclophosphamide constitute the major part of therapy with variable results. To control severe anaphylactic or allergic reaction anti-allergic drugs like diphenhydramine hydrochloride and corticosteroid like dexamethasone are advocated.

### **3.10.11 Ovarian Neoplasia**

Various forms of ovarian neoplasms were reported in pet and free ranging birds of which gonadal neoplasm of stromal cell origin is the most frequent. These neoplasms appear as solitary or multiple nodular, pale masses with haemorrhage and necrosis. The second most frequently reported ovarian neoplasm is the ovarian carcinoma or adenocarcinoma which usually appears as large firm, pedunculated or lobulated masses. Ovarian carcinoma may metastasize to remote organs like

mesenteric lymph nodes, liver, pancreas, intestine etc. Clinical symptoms may vary depending upon the involvement of organs and spread. The birds may reflect symptoms like abdominal distension, ascites, enlargement of abdominal masses, paralysis or paresis, weight loss, depression etc. Left leg paresis or paralysis of wings is seen often with occasional development of paraneoplastic symptoms like exostosis of bone and cartilage.

### 3.10.12 Chemotherapy and Radiotherapy in Treatment of Neoplastic Diseases in Caged Birds

Due to paucity of study very limited information is available regarding use of chemotherapy or radiation treatment for treatment of neoplastic diseases in birds. In general most of the studies indicated that chemotherapy is well tolerated by the birds, however, neoplasia is not responsive to chemotherapeutic treatment at optimum level. Similarly, radiation therapy works slowly over the tumour in avian system than that in mammalian counterparts. Before initiation of chemotherapy or radiotherapy, a thorough understanding of biology of tumours and effect of the respective treatment is necessary.

**Vincristine**, also known as leurocristine, is widely used for treatment of transmissible venereal granuloma in dogs. It binds with tubulin protein and causes disruption of mitotic spindle. Thus the separation of the dividing cell from its chromosome is inhibited during metaphase arresting the cell cycle. Thus the cells undergo apoptosis. It has been reported as a chemotherapeutic agent for treatment of malignant lympho-reticular neoplasia in African grey parrot, lymphoma in a Moluccan cockatoo and duck with lymphoma and leukaemia. However, as vincristine affects a wide range of dividing or proliferating cells, it may cause myelosuppression leading to pancytopenia, immunosuppression and neurotoxicity apart for gastrointestinal irritation.

Cisplatin, carboplatin and oxaliplatin are the platinum containing anticancer drugs which interfere with DNA replication by cross linking with them and the cell division or mitosis is interrupted. This ultimately leads to cell division arrest and cells undergo apoptosis. Cisplatin was reported to be used in fibrosarcoma, squamous cell carcinoma, pancreatic duct and bile duct carcinoma in pet birds. A dose of 1 mg/kg infused over 1 h was recommended by previous study conducted in cockatoos. Several adverse reactions like bone marrow suppression, regurgitation symptoms and weight loss were reported following cisplatin therapy.

L-asparaginase was reported for treating the case of lymphoma in a Moluccan cockatoo. It is an enzyme of bacterial origin. This enzyme causes hydrolysis of L-asparagine to L-aspartic acid and ammonia particularly in leukemic cells. Deprivation of asparagine leads to inhibition of protein synthesis and arrest of cell cycle leading to cell death. Adverse reaction like loss of weight, lethargy, in-appetence and regurgitation symptoms was reported in birds. Doxorubicin was reported to treat the cases of osteosarcoma in parrot and lymphoma in a Moluccan cockatoo. It acts as an intercalating agent and inhibits the topoisomerase II in dividing cell

population like cancer cells. Similarly cyclophosphamide and chlorambucil were also reported for treatment of lymphoma in birds.

Radiation therapy undergoes through a revolutionary changes in recent years. Previously radiation was given through orthovoltage X-ray machines or very large activities of 64-cobalt and 137-cesium. However, due to extreme adverse reactions these are no longer used. In veterinary practices linear accelerators are used as ionizing radiation to treat neoplasia either by powerful X-ray machines for deep seated tumours or electron beams to treat integumental neoplasia.

---

## 3.11 Hepatic, Pancreatic and Enteric Diseases

### 3.11.1 Hepatopathy

Hepatitis, the inflammation of liver is very common in pet birds.

#### 3.11.1.1 Etiology


Although infection is primary cause of hepatitis, trauma either by direct injury from motor vehicle or by deposition of uric acid crystals may also cause severe hepatopathy. Several hepatotoxic drugs, aflatoxin, gossypol, ergot, pesticides, ingestion of heavy metals are often responsible for causing hepatopathy. Infectious hepatitis may occur by three routes—direct penetration, hematogenous route and ascending through biliary system. As the liver receives blood from two routes—arterial blood from hepatic artery and blood from GI tract via portal vein, infection often starts through hematogenous route. Inflammation may involve only liver parenchyma—hepatitis or only biliary duct—cholangitis or involves the both—cholangiohepatitis depending upon the cause of hepatic insult or organism.

Several haemoprotozoa (*Haemoproteus*, *Plasmodium*, and *Leucocytozoon*) are known to cause severe hepatitis, however they are not too frequent among the pet birds. Similarly other protozoan infections like *Trichomonas*, *Histomonas* several trematodes and nematodes can cause hepatopathy. Several bacterial pathogens which are known to cause enteritis and septicemia like *Salmonella* spp., *E. coli*, *Pseudomonas* spp., *Yersinia* spp. and *Campylobacter* spp. may also cause hepatomegaly, hepatic necrosis with infiltration of PMN cells especially heterophils. Bacterial pathogens could be detected from kupffer cells and hepatic macrophages. Endotoxins liberated from virulent bacteria in GI tract may affect the liver by entering through portal circulation.

Among the viral pathogens which are responsible for causing hepatic insufficiency are Paramyxovirus, Circovirus, Reovirus, Adenovirus, Polyomavirus and Herpes virus. Depending on the type of strains involved the severity of the lesions varies. In general, they are responsible for multifocal necrosis with several spots of hemorrhagic changes. *Rickettsia* spp. like *Aegyptianella pullorum* and fungal pathogen *Aspergillus* sp. may cause hepatitis.



**Fig. 3.17** Ascites in a bird due to hepatopathy (Courtesy Amrit Dhara)



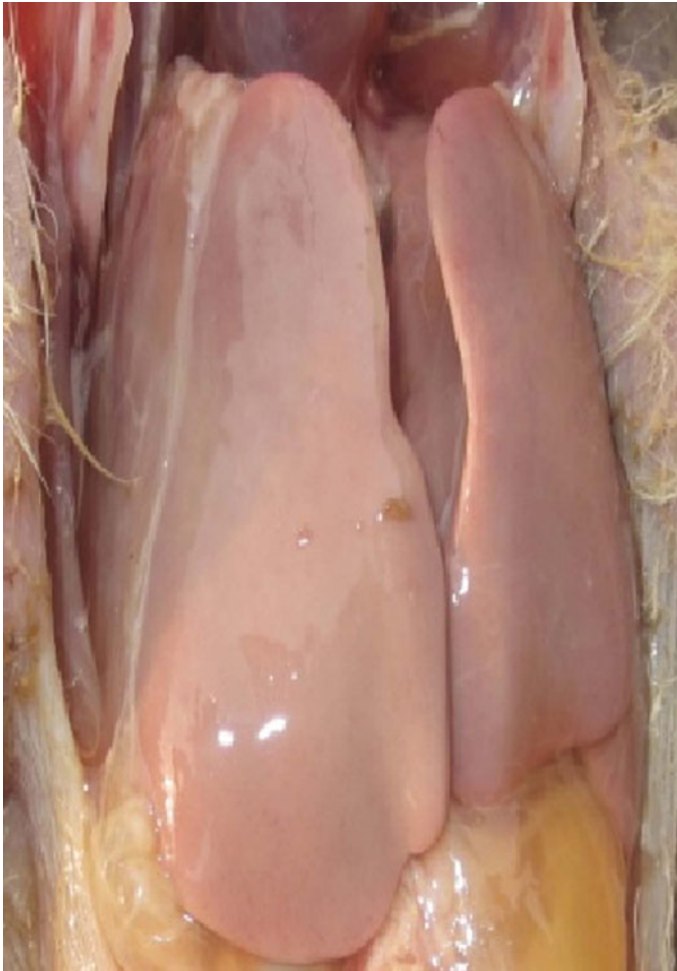
### 3.11.1.2 Clinical Findings and Pathology

During hepatic insufficiency the liver fails to synthesize optimum amount of albumin which maintains the colloidal osmotic pressure. Therefore, there will be effusion of fluid due to overpowered hydrostatic pressure with accumulation of fluid, hydro-peritoneum, ascites, hydro-pericardium and anasarca (Fig. 3.17). Portal hypertension may also significantly contribute to such condition.

Due to failure to synthesize coagulation factors, petechial hemorrhages and coagulopathies are noticed among the affected birds. It is not uncommon to notice sudden death of the affected birds due to extensive internal hemorrhages. Increased serum level of ammonia may lead to hepatic encephalopathy with signs like seizures and behavioral abnormalities. With swelling of the hepatic cells and cholangitis, the normal flow of bile may be hampered leading to cholestasis.

Affected birds develop biliverdinaemia which may cause biliverdin stained wastage a green discoloration. The birds may suffer from indigestion, diarrhea and weight loss. Hepatic enlargement can be felt by palpation over the area and it may incite significant painful reaction.

The hepatic failure to clear out the toxic metabolite and accumulation of bile salt may lead to extreme pruritus and skin reactions. The affected bird may develop dyspnea due to pressure exerted by enlarged liver capsule or by accumulation of fluid in air-sac.



**Fig. 3.18** Toxic hepatopathy in a bird

### 3.11.1.3 Diagnosis

The diagnosis is mainly done by serum analysis for any indication towards elevation of liver specific enzymes like aspartate amino transferase (AST), gamma glutamyl transferase (GGT) and glutamate dehydrogenase. Blood bilirubin level must be taken into consideration. Radiography and ultrasonography may indicate the presence of changes like accumulation of fluid, hepatomegaly and cirrhosis of liver. Toxic hepatopathy may reveal a gross abnormality with discoloration (Fig. 3.18).

### 3.11.1.4 Treatment and Management

Special and modified diet is required for management of hepatic failure in birds. High fiber diet may help to eliminate the toxins as well as to reduce the production of ammonia. Similarly to support the protein loss, quality protein may be given, however, a due consideration must be given not to facilitate the ammonia production. Readily available glucose is required in hepatopathy as it helps in regeneration of damaged liver as well as to expel out the toxin by supplying glucuronic acid. Diuretics are helpful to reduce the burden of accumulated fluid or edema aided by abdominocentesis. Adequate vitamin A, E and D may be given for detoxification and reduce the oxidative damage to liver. Silymarin is an effective drug to help the liver recover. When cholestasis is suspected ursodeoxycholic acid may be given. Respective antimicrobial or anti-parasitic therapy may be given to control the infection.

## 3.11.2 Pancreatitis

Inflammation of pancreas, pancreatitis may be acute or chronic. In birds it may be primary or secondary due to some bacterial or viral infection, heavy metal toxicity (zinc and selenium) and neoplasia. A major predisposing factor contributing to pancreatitis is high fat diet. Sometimes pancreatitis may be of idiopathic origin.

### 3.11.2.1 Pathophysiology and Clinical Findings

Pancreatic injury often releases activated digestive enzymes in the pancreatic parenchyma which further causes auto-digestion of the tissue and inflammatory changes in pancreatic parenchyma. Inflammatory mediators with infiltration of polymorph nuclear (PMN) cells cause further damage to pancreatic tissue. The enzymes like phospholipase A, elastase, trypsin and chymotrypsin play an important role for digestion of pancreatic tissue. Mild inflammation often causes edema of pancreas. However, acute hemorrhagic changes are not uncommon due to sudden inflammation.

Pancreatitis is always life-threatening if appropriate management and therapeutic intervention is not taken. The symptoms are vague and not indicative for confirmatory diagnosis. The affected birds may reveal the signs of indigestion, abdominal pain, frequent regurgitation, polydipsia, polyphagia, weight loss and abdominal discomfort.

### 3.11.2.2 Diagnosis

Elevation of serum amylase and lipase is indicative of pancreatitis. However, further investigation is needed for confirmatory diagnosis.

### 3.11.2.3 Treatment

Treatment of pancreatitis is very difficult. It requires an appropriate dietary management like low fat or fat free diet. Antibiotics and analgesics may be given along with fluid therapy for managing the cases as and when required. The sources of toxicity leading to such condition must be identified and removed.

## 3.11.3 Bacterial Enteritis

Like other mammals and domestic animals pet birds are frequently suffering from bacterial enteric infections where the organisms like *E. coli*, *Clostridium* spp., *Chlamydomphila psittaci* and *Salmonella* spp. are frequent perpetrators. Among them *E. coli* infection is the most common as the organism is present in GI tract of the healthy birds as a commensal and may cause disease either as primary pathogen during conducive environment or as a secondary invader following viral, protozoal or fungal infection. Enterotoxigenic *E. coli* and the endotoxin liberated from these organisms may cause severe life-threatening infection. Infection by Gram positive anaerobic spore forming *Clostridium perfringens* type A and C can cause severe infection in young birds following abrupt changes in diet. They are responsible for foul smelling diarrhea with occasional hemorrhagic spots in fecal samples, necrotic enteritis, malignant edema and gangrenous dermatitis. Diagnosis can be done by gram staining the fecal samples revealing boat shaped Gram positive spore forming bacillus. The small intestine reveals presence of petechial hemorrhagic spots. Treatment with apple cider vinegar (10 ml/l of drinking water), penicillin and metronidazole (40–80 mg/l water) can be effective. Both the *E. coli* and *Clostridial* infections are common in psittacine birds particularly among cockatoos. *Salmonella* is another food and water borne infectious bacterial pathogen which is responsible for necrotic and ulcerative enteritis, diarrhea, respiratory infection, airsacculitis, and sinusitis, septic arthritis associated with hepatomegaly, splenomegaly, orchitis and oophoritis. This is a common pathogen detected in all the items present in close contact of the birds and adults may serve as asymptomatic carrier. Treatment is usually done by oral or systemic antibiotic especially aminoglycosides like amikacin (20 mg/kg, IM) and enrofloxacin (30 mg/kg, IM) depending upon the severity of infection. Plenty of water and electrolyte must be given to affected birds to prevent their collapse due to excessive dehydration.

## 3.11.4 Protozoal Enteritis

*Cryptosporidia* is small form of coccidian parasite which affects a large number of hosts including birds. The parasites live in the epithelial cell lining of the GI tract

and are responsible for destruction of the villi of the enterocytes. It causes chronic diarrhea, in-appetence, weight loss and periodic hemorrhagic droppings. In many of the birds it may cause asymptomatic colonization. Infection is acquired through faeco-oral route. Infective oocysts are discharged via feces and susceptible birds may be infected by consuming such cysts. The feces may be stained by Giemsa stain for demonstration of the oocysts. Treatment is done by paromomycin sulphate.

Like other animals and poultry birds, pet birds are also susceptible to the coccidia which mainly infect the intestinal mucosa. Two of the genera are important—*Eimeria* and *Isospora*. The infective oocysts are shed with the feces and infection is generally acquired by ingestion of sporulated oocysts. Sporozoites released thereby, penetrate the intestinal epithelial cells to cause the disease. With the multiplication and destruction of the epithelial lining the affected birds manifest symptoms for their inability to digest and absorb nutrients. Young birds are mostly affected with symptoms like weight loss and diarrhea. The infection may be detected and confirmed based on the clinical symptoms and demonstration of oocysts in fecal smear. Affected birds may be treated successfully with anti-coccidial drugs like sulphadimethoxine and amprolium.

*Hexamita columbae* and *H. meleagridis* are known to cause anorexia, weight loss, severe diarrhea in pigeons, game and love birds, cockatiels, lorikeets and parrots. Fresh fecal samples should be examined for presence of protozoa. Nitroimidazole is generally effective however, periodic examination is necessary to check the efficacy of treatment. Affected birds should be given oral glucose solution to check hypoglycemia in affected birds.

### 3.11.5 Microsporidiosis (Encephalitozoonosis)

This is an immunosuppressive disease characterized by anorexia, lethargy, weakness, diarrhea, stunting, ruffled feathers, weight loss and neonatal mortality due to infection by acid fast Gram positive obligate intracellular protozoa. This is commonly detected among parrots, Amazons, lovebirds, budgerigars and finches. Many of the affected birds may exhibit ophthalmic symptoms like blepharospasms, corneal edema, chronic conjunctivitis and sinusitis. Treatment involved oral administration of albendazole @ 50 mg/kg once daily for 5 days.

---

## 3.12 Deficiency, Nutritional and Metabolic Diseases

Avian nutrition has gone through a revolutionary change when it comes to commercial poultry farming. However, such development is not true in every aspect when it concerns to the companion or cage birds. Despite the availability of formulated diets and practice of hand feeding, the birds used to suffer from deficiency, nutritional and metabolic diseases. One of the main causes of such deficiency or metabolic problem is that owners prefer to give the birds only what they like. This

leads to feeding of the bird only seeds or pellets. Many times the birds are enthusiastically fed with nuts and other fat rich diets. Such selective consumption may lead to nutritional deficit and metabolic upset.

### **3.12.1 Obesity**

Like human beings and pet dogs, modern life style and food-habits make the caged and pet birds prone to obesity. Obesity is a real problem which invites other diseases and act as risk factor for the life-threatening emergency like sudden cardiac failure or syncope with respiratory failure or circulatory collapse. A bird is considered obese when its body weight is approximately 20% higher than the normal or usual one or when it attains a body condition or keel score of 4 out of 5.

#### **3.12.1.1 Risk Factors**

There are certain risk factors which makes the caged birds obese.

1. Galahs, macaws, Amazon parrots, and quaker parrots are usually more likely to be obese.
2. Over feeding of the birds or exuberance of food.
3. Sedentary life style and lack of exercise mostly because of small cage size with little opportunity to move
4. High fat diet like seeds, nuts, table food etc.

#### **3.12.1.2 Consequences**

The obese birds are prone to some disease conditions like lameness and arthritis due to constant overwork of the limbs to bear over-weight. The high fat diet and little body movement give little scope to metabolize the lipid leading to hyperlipidaemia and deposition of cholesterol or lipid in the blood vessels and liver. Thus, such birds usually suffer from fatty liver syndrome and atherosclerosis. The coronary thrombosis and sudden cardiac failure is not uncommon. Birds may also succumb to severe blood loss due to sudden rupture of the major arteries with atherosclerosis and aneurism.

#### **3.12.1.3 Management**

There is not medication which can directly help to control obesity. The birds should be given pelleted diet and fibre rich food with little or no fat. Ample opportunity to exercise should be given to the affected bird providing a larger cage with stir to climb or walk and flight cage. Similarly, rope or spiral rope may help them to exercise. Placing multiple food bowls help them to move and feed with enough scope of exercise.

### 3.12.2 Metabolic Bone Disease (MBD)

This is a complex of symptoms associated with loss of structural and functional integrity of bone, cartilages and skeleton deformity. This is also associated with other forms of bone diseases like rickets (in young), osteomalacia (in adults), secondary nutritional hyperparathyroidism, fibrous osteodystrophy, osteoporosis and cage layer paralysis or fatigue syndromes. The disease complex is generally associated with vitamin D, calcium and phosphorous deficiency in diet.

#### 3.12.2.1 Etiology

The can occur in both the very young and old birds and mostly linked to calcium, phosphorous and vitamin D deficiency. Birds which are kept only on seed diet are more prone to the condition as calcium to phosphorus ratio in most seeds is poor due to high phosphorous and low calcium content. Seeds with high oil content are responsible for triggering such condition. As the caged birds have low exposure of sunlight, they are more susceptible to vitamin D<sub>3</sub> deficiency. In African grey parrots such condition is characterized by fibrous osteodystrophy and is commonly associated with hypocalcaemia, hypovitaminosis D<sub>3</sub> with deformities and curvature of long bones and vertebrae. The birds kept on all meat diet (raptors) are known to develop the condition within 2–4 weeks.

#### 3.12.2.2 Clinical Findings

In young birds the MBD is reflected as stunted growth, bowing of bones, spontaneous fracture, vertebral deformities, inability to perch and improper plumage formation.

Adult birds develop symptoms like osteomalacia with frequent fractures with the slightest trauma, abnormal mounting, egg binding, or cloacal prolapse. Egg production drops significantly and the birds may lay soft shelled eggs. With the fall of hatchability and egg production, embryonic death may also be noticed very frequently. Other symptoms include depression, lethargy, polydipsia, polyuria, regurgitation, ruffled feather with feather pricking and diarrhoea. Diarrhoea occurs usually due to polydipsia. Due to persisting hypocalcaemia the birds may exhibit frequent nervous disorders like seizures, paresis, paralysis and hypercalcaemic tetany.

#### 3.12.2.3 Pathophysiology

MBD is usually associated with dietary supply of proper calcium, phosphorous and availability of vitamin D for utilization of them. Exposure of sunlight is essential for conversion of vitamin D<sub>3</sub> in active form—1, 25 dihydrocholecalciferol. This active form is instrumental for absorption of calcium from diet through GI tract in the blood and their deposition in bone. Sunlight is absorbed and utilized in the bare surfaces of feet and shanks for activation of vitamin D. Lack of vitamin D may lead to improper mineralization of bone and skeletal deformity. On the other hand, lack of proper calcium phosphorous ratio (2:1) may lead to failure of calcium absorption.

High phosphorous level impairs the calcium absorption with formation of insoluble calcium phosphate complex.

#### **3.12.2.4 Diagnosis**

The case of MBD may be diagnosed on the basis of clinical finding and diet history. Serum calcium level (total and ionized) and 25-hydroxycholecalciferol are usually low. Radiographic investigation may reveal improper bone mineralization, decreased radio-density of bones and evidence of fractures.

#### **3.12.2.5 Treatment**

The birds should be placed with proper diet with rich supply of calcium and phosphorous in proper ratio, exposure to sunlight/ultraviolet light for sufficient period. In case of fractures it should be repaired with splinting or bandaging along with pain management with NSAID drugs. The birds should be given ample scope for exercise.

### **3.12.3 Hypovitaminosis A**

Vitamin is a major nutraceutical and ingredient to maintain the structural and functional integrity of the epithelial tissue and it is crucial to provide a healthy immune system.

#### **3.12.3.1 Etiology**

In formulated diet for poultry or caged birds maize or other green plant is the only portion to supplement the requirement for vitamin A or its precursor carotenoids. Therefore, when the caged birds are provided only seed diets or diets with a mixture of seeds and pellets, they may suffer from vitamin A deficiency. Even some owner over-enthusiastically feed the birds with nuts and table food which suppresses the appetite of their pets to take maize or green foods at optimum level.

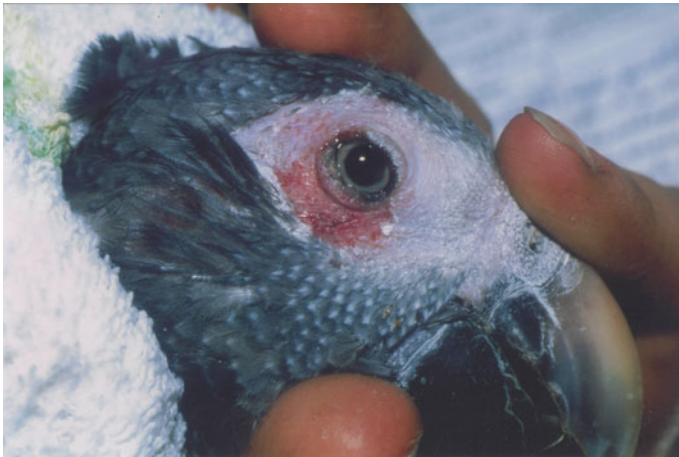#### **3.12.3.2 Clinical Findings and Pathology**

Deficiency of vitamin A leads to metaplasia of epithelial linings in the respiratory, urogenital, gastrointestinal and integumentary system. The mucus secretory cells of oropharynx, choana, nasal sinuses, trachea and conjunctiva are keratinized and stop to function. This causes inflammatory exudate and cellular debris leading to watery nasal discharge and accumulation of caseous exudate in nasal sinuses, eye and trachea. White or yellowish pustules may form in the trachea or esophagus. As vitamin A deficiency leads to loss of mucosal protection and barrier and suppression of immunoglobulin production, secondary bacterial or viral infection may be observed in respiratory, gastrointestinal or urogenital system. Loss of integrity to the renal tubular system may lead to loss of urinary clearance and urate crystal deposition. This may cause creamy white deposition on kidney with loss of lobulation. Due to the loss of production of acid muco polysaccharides there may be





**Fig. 3.19** Hypovitaminosis in African Grey parrot (*Courtesy Petra Maria Burgmann, Canada*)



**Fig. 3.20** Hypovitaminosis in African Grey parrot (*Courtesy Petra Maria Burgmann, Canada*)

total derangement of bone and cartilage formation particularly in the young birds. Vision is impaired due to keratinization of the conjunctiva (xerophthalmia). In general, the birds exhibit conjunctivitis, peri-orbital swelling, occulo-nasal discharge, sinusitis, polydipsia, polyuria, ruffled feather with poor feather quality, pododermatitis and loss of appetite (Figs. 3.19 and 3.20).

### 3.12.3.3 Treatment

Change in diet is an essential requirement to supply vitamin A. Good quality pelleted diet with maize or greens may be a good source. Dry formulation of vitamin A in acetate or palmitate along with an antioxidant (ethoxyquin) may be mixed with diet. Carotenoid rich spirulina is another option to use in deficient diet. In deficient population parenteral vitamin A can be given @ 100,000 U/kg, IM to treat the cases of hypovitaminosis A.

## 3.12.4 Excess Iron Deposition in Liver

This disease is also referred as iron storage disease or hemochromatosis which is characterized by excessive deposition of iron in the liver. This has been recorded in few psittacine species, mynahs, toucans and in some zoo birds.

### 3.12.4.1 Etiology

This condition is associated with excessive intake of dietary iron. Some genetic predisposition also plays a role for such development. Intake of citrus food or the foods rich in vitamin C facilitate the absorption of dietary iron.

### 3.12.4.2 Clinical Findings and Pathophysiology

The disease develops when the hepatic storage of iron is increased manifold and the lysosomes of the hepatocytes are unable to store iron anymore and release the iron reserve in the cytosol. This causes excessive oxidative damage of cell membrane and cellular proteins and nucleic acids.

In most of the cases affected birds develop and exhibit the symptoms simulating hepatic damage. The birds are anorectic and gradually lose their body weight. The abdomen is distended due to hepatic enlargement and developing ascites possibly due to decreased albumin synthesis and consequent drop in the colloidal osmotic pressure. Biliverdinaemia and biliverdinuria are seen in most of the birds. Post-mortem examination shows abnormality in liver, spleen and heart.

### 3.12.4.3 Diagnosis

The condition can be diagnosed on the basis of history, clinical symptom, and post-mortem examination. Liver is seen enlarged, golden brown in colour with scattered dark foci. Iron storage can be detected in hepatocytes and kupffer cells on histopathological examination of the collected tissue samples through biopsy or necropsy. This is associated with hepatic inflammation with infiltration of heterophils and lymphocytes.

### 3.12.4.4 Treatment

As the condition is associated with more iron in the body, efforts must be taken to reduce iron intake, reduce the absorption of dietary iron and facilitate the iron elimination from body. Affected birds must be given a food formulation with low

iron level (within 50–100 ppm). Ascorbic acid present in the citrus food usually transform iron from its ferric ( $\text{Fe}^{3+}$ ) to readily absorbable ferrous ( $\text{Fe}^{2+}$ ) form, therefore, such citrus food must be avoided to minimize iron absorption. Owners should be advised so that they avoid giving the affected birds citrus fruits. Tanin, diets rich in fiber and phytate may be supplemented to the birds. To eliminate iron storage in the body periodic phlebotomy may be practiced (10% of body weight, once in a week). Iron chelating agent deferoxamine @ 100 mg/kg may be given PO/IM/SC once a day.

### 3.12.5 Fatty Liver Syndrome

This syndrome is more common in caged laying birds. The birds which are kept on high energy diet rich in carbohydrate and fat like all seed diets or nuts and the birds which lead a sedentary life style with limited scope of exercise are more prone to such condition.

Liver in birds are metabolically very active during egg laying and is the main site for lipogenesis. However, high energy diet, limited or no exercise, high environmental temperature lead to deposition of excessive fat in liver and abdominal cavity (Figs. 3.21 and 3.22).

Affected birds may die of hepatic enlargement and rupture following haemorrhage. Microscopically, enlarged hepatocytes are seen containing large fat globules. The condition can be managed with low energy diet, exercise and supplementation of lipotropic agents like choline, inositol and manganese.

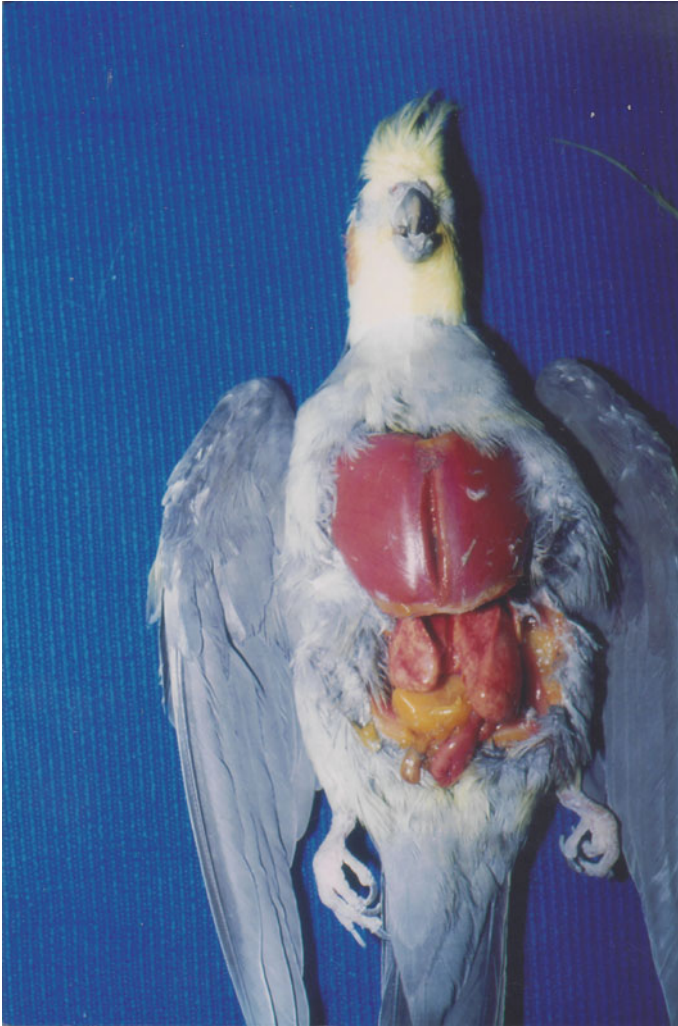### 3.12.6 Avian Amyloidosis

Amyloidosis is a disease mainly of the adult birds and caused by heavy extracellular deposition of normally autologous soluble amyloid proteins or their fragments in different important visceral organs and in the joints in characteristic fibrillary form. Once deposited, they become insoluble and resistant to proteolytic enzyme under normal physiological condition. This makes such amyloidosis an irreversible phenomenon.

Depending of the composition or characteristic of the fibrillary protein the common amyloid may be of four types—AL, AA, ATTR, and A $\beta$ 2 M. In animal, caged, wild and domesticated birds majority of the amyloid cases were found as AA type.

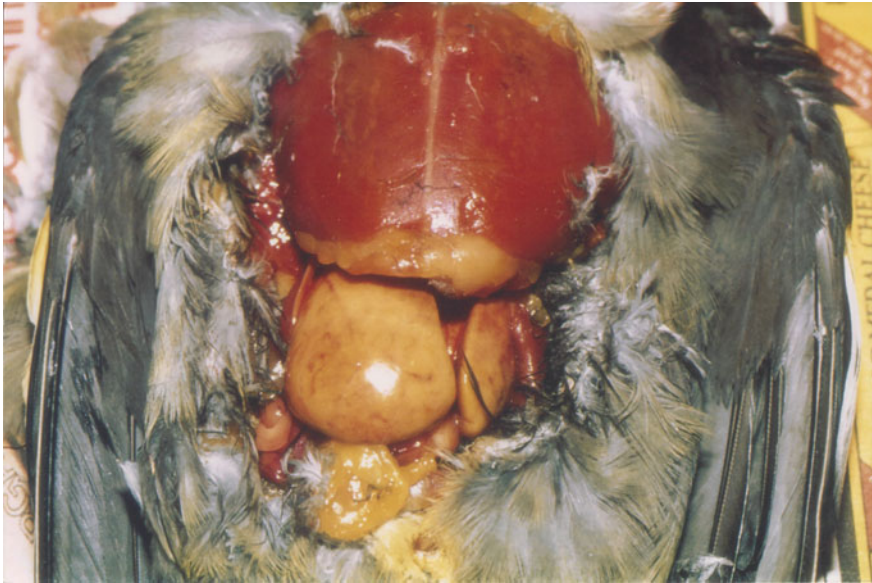
#### 3.12.6.1 Etiology

The exact cause of amyloidosis is still obscure. Pathogenesis of AA-amyloidosis is complex and of multifactorial origin. In general it is thought that the syndrome is associated with abnormal protein metabolism, chronic debilitating diseases like avian tuberculosis, inflammations or tumours which may trigger a strong elevation in serum of serum amyloid A (apoSAA), an important acute phase reactant and the



**Fig. 3.21** Fatty liver in a cockatiel (*Courtesy Petra Maria Burgmann, Canada*)

AA precursor protein. This precursor protein is necessary for amyloid AA type development and certain amino acid substitutions may facilitate amyloidogenicity for unstable intermediate protein conformations required for the whole process. Other favouring factors include—amyloid-enhancing factor, an altered basement membrane protein and the presence of certain inorganic ions such as calcium and sulphate. Recent studies have suggested that vaccination may also be a triggering factor for induction of amyloidosis in commercial birds. In general it is thought that amyloid may be of primary origin where no triggering or inciting cause can be identified or it may be secondary to prolong infection with a persistent antigenic

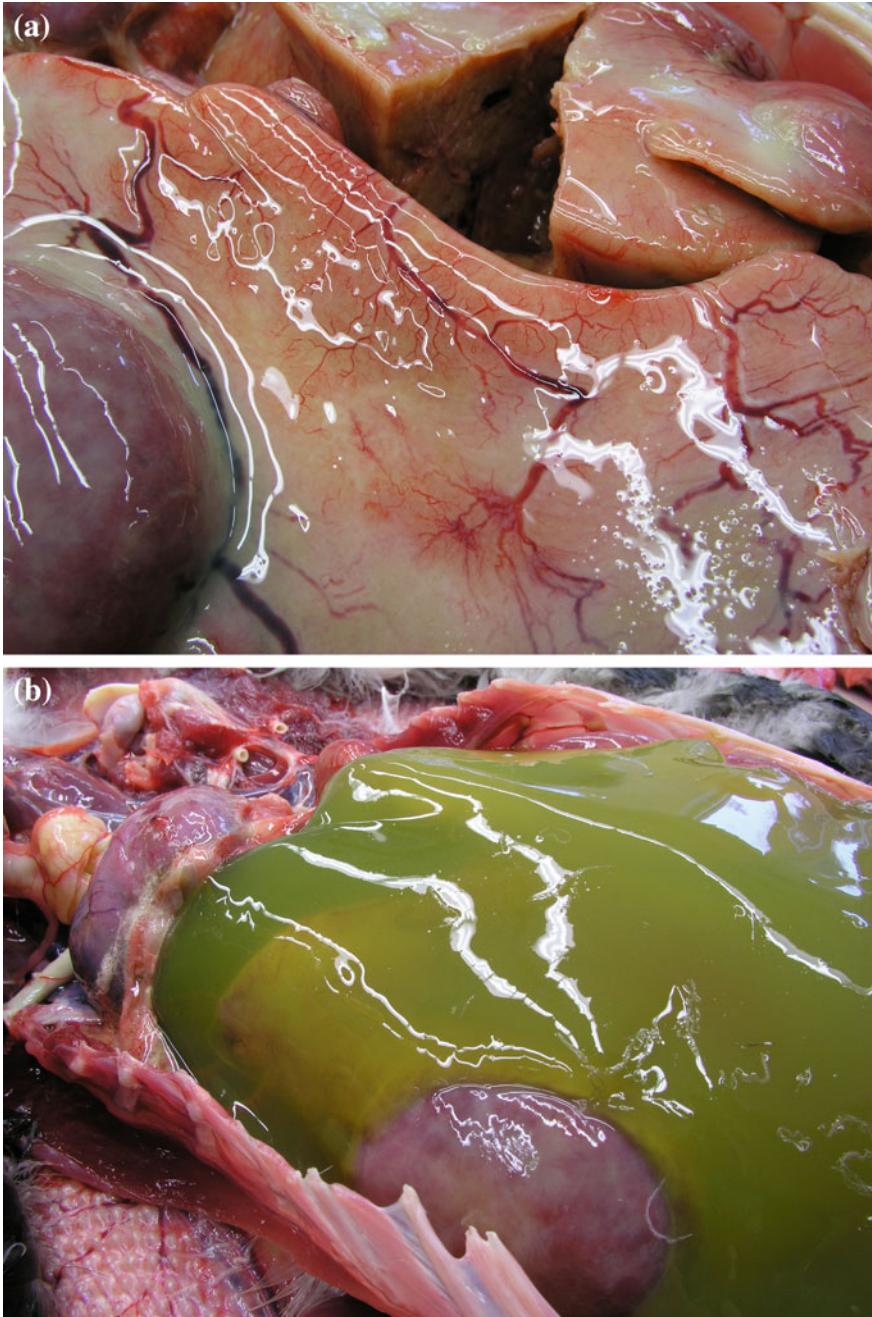


**Fig. 3.22** Fatty liver in an African grey parrot (Courtesy Petra Maria Burgmann, Canada)

stimulation. In case of ducks persistent stress is generally thought as an inciting factor for amyloidosis. Amyloid arthropathy was reported with *Enterococcus faecalis* and *Mycoplasma synoviae* infection. Some degree of genetic predisposition too was reported to be associated with amyloidosis.

### 3.12.6.2 Clinical Findings and Pathology

The clinical presentation of the disease is non-specific and vague. However, most of the internal organs are affected. Among different visceral organs, liver, spleen and kidneys undergo characteristic changes like extensive enlargement, loss of lobules with rounded margins and pale discoloration (Fig. 3.23). Organs like proventriculus, large intestine, heart, gonads and endocrine organs are less affected. In case of ducks, swelling of feet and legs is very common with oedema. In few instances the affected ducks develop enlargement of ventral abdomen with ascites. This is probably due to circulatory collapse associated with hepatic amyloidosis. In such cases liver is usually enlarged and friable. It becomes brown to tan coloured. In chickens hepatic amyloidosis causes decreased egg production and sudden mortality due to ruptures of liver and haemorrhage. In amyloid arthropathy, the joints are swollen and painful and the affected birds show lameness and they are disinclined to move. Synovial fluid is thick and contains several yellow to green coloured deposits.



**Fig. 3.23** Amyloidosis in bird affecting different organs (*Courtesy Prof. Richard Hoop, University of Zurich, Switzerland*)

### 3.12.6.3 Diagnosis

Due to vague and nonspecific clinical symptoms, it is rather difficult to diagnose the disease ante-mortem. Diagnosis is based on post-mortem finding. Tissue biopsy sample through cloaca or subcutaneous tissue aspirate may be tried to collect for histopathological examination. The tissues are usually examined via congo red staining or immune-histochemical staining using specific anti-sera. In hepatic tissue, histologically, amyloid is seen as pale-pink material and generally deposited in the space between the sinusoids and the hepatocytes. Hepatic chords may be atrophied despite hepatomegaly due to amyloidosis. A recent study in avian arthropathy in chickens revealed significant elevation in serum amyloid A (SAA) and serum amino acids like serine, glycine, isoleucine and phenylalanine.

### 3.12.6.4 Treatment

Currently there is no available therapeutic protocol for avian amyloidosis. However, one experimental study revealed ameliorative effect of methylprednisolone in amyloid arthropathy. In human patients anti-mitotic and anti-inflammatory drugs, like colchicine and dimethyl sulphoxide (DMSO) were used with successful outcome. However, their effect is still to be studied in birds.

---

## Bibliography

- Abrams GA, Paul-Murphy J, Murphy CJ (2002) Conjunctivitis in birds. *Vet Clin N Am Small Anim Pract* 5:287–309
- Andreasen JR Jr, Andreasen CB, Latimer KS et al (1995) Thoracoabdominal myelolipomas and carcinoma in a lovebird (*Agapomis* sp.). *J Vet Diagn Investig* 7:271–272
- Appleby RC (1984) Diabetes mellitus in a budgerigar (*Melopsittacus undulatus*). *Vet Rec* 115:652–653
- Baker JR (1996a) Causes of mortality and morbidity in exhibition budgerigars in the United Kingdom. *Vet Rec* 139:156–162
- Baker JR (1996b) Survey of feather diseases of exhibition budgerigars in the United Kingdom. *Vet Rec* 139:590–594
- Bates G, Tucker RL, Ford S et al (1999) Thyroid adenocarcinoma in a bald eagle (*Haliaeetus leucocephalus*). *J Zoo Wildl Med* 30:439–442
- Baumeister RF, Scher SJ (1988) Self-defeating behavior patterns among normal individuals: review and analysis of common self-destructive tendencies. *Psychol Bull* 104:3–22
- Bavelaar F, Beynen A (2003) Severity of atherosclerosis in parrots in relation to the intake of  $\alpha$ -linolenic acid. *Avian Dis* 47:566–577
- Bavelaar F, Beynen A (2004) Atherosclerosis in parrots. A review. *Vet Q* 26:50–60
- Beaufrère H (2013) Avian atherosclerosis: parrots and beyond. *J Exot Pet Med* 22:336–347
- Beaufrère H, Ammersbach M, Reavill DR et al (2013) Prevalence of and risk factors associated with atherosclerosis in psittacine birds. *J Am Vet Med Assoc* 242:1696–1704
- Beaufrère H, Nevarez J, Tully TN Jr (2010) Cloacolith in a blue-fronted amazon parrot (*Amazona aestiva*). *J Avian Med Surg* 24:142–145
- Bennett R, Mader D (1996) Cloacal prolapse. In: Mader DR (ed) *Reptile medicine and surgery*. WB Saunders Company, Philadelphia, pp 355–358
- Bermudez AJ, Hopkins BA (1995) Hemoglobinuric nephrosis in a rhea (*Rhea americana*). *Avian Dis* 39:661–665

- Bezuidenhout A, Penrith M, Burger W (1993) Prolapse of the phallus and cloaca in the ostrich (*Struthio camelus*). J S Afr Vet Assoc 64:156–158
- Blackmore D (1966) The clinical approach to tumours in cage birds. J Small Anim Pract 7:217–223
- Blaxland J, Borland ED, Siller W et al (1980) An investigation of urolithiasis in two flocks of laying fowls. Avian Pathol 9:5–19
- Blus LJ, Locke LN, Stafford CJ (1977) Ruptured-yolk peritonitis and organochlorine residues in a royal tern. Avian Dis 21:445–447
- Bohorquez F, Stout C (1972) Aortic atherosclerosis in exotic avians. Exp Mol Pathol 17:261–273
- Bowles H, Lichtenberger M, Lennox A (2007) Emergency and critical care of pet birds. Vet Clin N Am Small Anim Pract 10:345–394
- Bowles HL (2002) Reproductive diseases of pet bird species. Vet Clin N Am Small Anim Pract 5:489–506
- Burgos-Rodríguez AG (2010) Avian renal system: clinical implications. Vet Clin N Am Small Anim Pract 13:393–411
- Burgos-Rodríguez AG, Garner M, Ritzman TK et al (2007) Cutaneous lymphosarcoma in a double yellow-headed Amazon parrot (*Amazona ochrocephala oratrix*). J Avian Med Surg 21:283–289
- Butcher GD, Beck CC (1996) Avian Goiter (Thyroid Hyperplasia or Dysplasia). University of Florida Cooperative Extension Service, Institute of Food and Agriculture Sciences, EDIS. <http://edis.ifas.ufl.edu/vm029>. Accessed 7 Nov 2016
- Candeletta SC, Homer BL, Garner MM et al (1993) Diabetes mellitus associated with chronic lymphocytic pancreatitis in an African grey parrot (*Psittacus erithacus erithacus*). J Assoc Avian Vet 7:39–43
- Canny CJ, Ward DA, Patton S et al (1999) Microsporidian keratoconjunctivitis in a double yellow-headed Amazon parrot (*Amazona ochrocephala oratrix*). J Avian Med Surg 13:279–286
- Caruso K, Cowell R, Meinkoth J et al (2002) Ab-dominal effusion in a bird [egg yolk peritonitis]. Vet Clin Pathol 31:127–128
- Casares M, Enders F, Montoya J (2000) Comparative electrocardiography in four species of macaws (genera *Anodorhynchus* and *Ara*). J Vet Med Ser A 47:277–281
- Chong K, Apostolov K (1982) The pathogenesis of nephritis in chickens induced by infectious bronchitis virus. J Comp Pathol 92:199–211
- Circella E, Legretto M, Pugliese N et al (2014) Psittacine beak and feather disease-like illness in Gouldian finches (*Chloebia gouldiae*). Avian Dis 58:482–487
- Clayton LA, Ritzman TK (2006) Egg binding in a cockatiel (*Nymphicus hollandicus*). Vet Clin N Am Small Anim Pract 9:511–518
- Coleman CW (1991) Bile duct carcinoma and cloacal prolapse in an orange-winged Amazon parrot (*Amazona amazonica amazonica*). J Assoc Avian Vet 5:87–89
- Cong W, Meng QF, Shan XF et al (2014) Seroprevalence and risk factors associated with hepatitis E virus infection in three species of pet birds in northwest China. Sci World J 2014:296285
- Cosgrove A (1962) An apparently new disease of chickens: avian nephrosis. Avian Dis 6:385–389
- Couvillion CE, Maslin WA, Montgomery RM (1990) Multiple feather follicle cysts in a wild turkey. J Wildl Dis 26:122–124
- Cowan DF (1968) Avian amyloidosis I. General incidence in zoo birds. Pathol Vet Online 5:51–58
- Cowen B, Wideman R, Rothenbacher H et al (1987) An outbreak of avian urolithiasis on a large commercial egg farm. Avian Dis 31:392–397
- Crosta L, Gerlach H, Bürkle M et al (2003) Physiology, diagnosis, and diseases of the avian reproductive tract. Vet Clin N Am Small Anim Pract 6:57–83
- de Matos R, Morrissey JK (2005) Emergency and critical care of small psittacines and passerines. Semin Avian Exotic Pet Med 14:90–105
- de Wit M, Schoemaker NJ (2005) Clinical approach to avian cardiac disease. Semin Avian Exotic Pet Med 14:6–13



- de Wit M, Schoemaker NJ, Kik MJ et al (2003) Hypercalcemia in two Amazon parrots with malignant lymphoma. *Avian Dis* 47:223–228
- Dennis PM, Bennett RA (2000) Ureterotomy for removal of two ureteroliths in a parrot. *J Am Vet Med Assoc* 217:865–868
- Desmarchelier A, Langlois I, Desmarchelier M (2015) Transient diabetes mellitus in a domestic ferret (*Mustela putorius furo*). *Can Vet J* 56:737–740
- Desmarchelier M, Langlois I (2008) Diabetes mellitus in a nanday conure (*Nandayus nenday*). *J Avian Med Surg* 22:246–254
- Donatti RV, Resende M, Ferreira FC et al (2014) Fatal proventricular dilatation disease in captive native psittacines in Brazil. *Avian Dis* 58:187–193
- Doneley B (2016) Avian medicine and surgery in practice: companion and aviary birds. CRC Press, Boca Raton, Florida
- Doukaki C, Kik MJ, Ducatelle R et al (2014) Thyroid adenocarcinoma in two parrots. *Vet Rec* 2:e000101
- Effron M, Griner L, Benirschke K (1977) Nature and rate of neoplasia found in captive wild mammals, birds, and reptiles at necropsy. *J Natl Cancer Inst (Bethesda)* 59:185–198
- El-Bahrawy A, Zaid A, Sunden Y et al (2015) Pathogenesis of pancreatitis in chickens after experimental infection with 9a5b Newcastle disease virus mutant isolate. *J Comp Pathol* 153:315–323
- Encinas-Nagel N, Enderlein D, Piepenbring A et al (2014) Avian bornavirus in free-ranging psittacine birds, Brazil. *Emerg Infect Dis* 20:2103–2106
- Finlayson R (1965) Spontaneous arterial disease in exotic animals. *J Zool (Lond)* 147:239–343
- Foerster SH, Gilson SD, Avery Bennett R (2000) Surgical correction of palatine bone luxation in a blue-and-gold macaw (*Ara ararauna*). *J Avian Med Surg* 14:118–121
- Foster R, Smith M (2016) Birds: enlargement of thyroid gland. <http://www.peteducation.com/article.cfm?c=15+1829&aid=2755>. Accessed 5 Sept 2016
- Fredrickson T (1987) Ovarian tumors of the hen. *Environ Health Perspect* 73:35
- Fricke C, Schmidt V, Cramer K et al (2009) Characterization of atherosclerosis by histochemical and immunohistochemical methods in African grey parrots (*Psittacus erithacus*) and Amazon parrots (*Amazona* spp.). *Avian Dis* 53:466–472
- Gallerstein G (1994) The complete bird owner's handbook. Howell Book House, New York
- Gancz AY, Wellehan JF, Boutette J et al (2007) Diabetes mellitus concurrent with hepatic haemosiderosis in two macaws (*Ara severa*, *Ara militaris*). *Avian Pathol* 36:331–336
- Gonçalves GAM, Salgado BS (2012) Post-mortem lesions of urolithiasis in a lesser seed finch (*Sporophila angolensis*). *Acta Veterinaria Brasilica* 6:52–55
- Goodwin MA, Krabill VA (1989) Diarrhea associated with small-intestinal cryptosporidiosis in a budgerigar and in a cockatiel. *Avian Dis* 33:829–833
- Gross W, Siegel P (1959) Coliform peritonitis of chickens. *Avian Dis* 3:370–373
- Guerin J-L, Gelfi J, Dubois L et al (2000) A novel polyomavirus (goose hemorrhagic polyomavirus) is the agent of hemorrhagic nephritis enteritis of geese. *J Virol* 74:4523–4529
- Guzman DS (2016) Avian soft tissue surgery. *Vet Clin North Am Exot Anim Pract* 19:133–157
- Hadley TL (2010) Management of common psittacine reproductive disorders in clinical practice. *Vet Clin N Am Exot Anim Pract* 13:429–438
- Hafner S, Harmon BG, Stewart RG et al (1993) Avian keratoacanthoma (dermal squamous cell carcinoma) in broiler chicken carcasses. *Vet Pathol* 30:265–270
- Hakimuddin F, Abidi F, Jafer O et al (2016) Incidence and detection of beak and feather disease virus in psittacine birds in the UAE. *Biomol Detect Quantif* 6:27–32
- Harcourt-Brown NH (1996) Torsion and displacement of the oviduct as a cause of egg-binding in four psittacine birds. *J Avian Med Surg* 262–267
- Hartup BK, Dhondt AA, Sydenstricker KV et al (2001) Host range and dynamics of mycoplasmal conjunctivitis among birds in North America. *J Wildl Dis* 37:72–81

- Hausmann JC, Mans C, Gosling A et al (2016) Bilateral Uveitis and Hyphema in a Catalina Macaw (*Ara ararauna* × *Ara macao*) with multicentric lymphoma. *J Avian Med Surg* 30:172–178
- Heffels-Redmann U, Enderlein D, Herzog S et al (2011) Occurrence of avian bornavirus infection in captive psittacines in various European countries and its association with proventricular dilatation disease. *Avian Pathol* 40:419–426
- Hess L (2000) Obesity and its consequences in an Amazon parrot (*Amazona aestiva aestiva*). In: Proceedings of the 21st annual conference and expo of the association of avian veterinarians, Portland, Oregon, USA, pp 119–120
- Hochleithner M (1993) No therapy for feather duster budgerigars. *J Assoc Avian Vet* 7:98–98
- Hollander W, Riddle O (1946) Goiter in domestic pigeons. *Poult Sci* 25:20–27
- Hoppes S, Gurfield N, Flammer K et al (2000) Mycotic keratitis in a blue-fronted Amazon parrot (*Amazona aestiva*). *J Avian Med Surg* 14:185–189
- Hoppes SM, Tizard I, Shivaprasad HL (2013) Avian bornavirus and proventricular dilatation disease: diagnostics, pathology, prevalence, and control. *Vet Clin North Am Exot Anim Pract* 16:339–355
- Howard B (1992) Health risks of housing small psittacines in galvanized wire mesh cages. *J Am Vet Med Assoc* 200:1667–1674
- Hubben K, Shirer JF, Enold GL (1964) Transmissible pituitary chromophobe adenoma in the parakeet. *Avian Dis* 8:203–208
- Hvenegaard AP, Safatle A, Guimaraes MB et al (2009) Retrospective study of ocular disorders in Amazon parrots. *Pesqui Vet Bras* 29:979–984
- Ibi K, Murakami T, Goda WM et al (2015) Prevalence of amyloid deposition in mature healthy chickens in the flock that previously had outbreaks of vaccine-associated amyloidosis. *J Vet Med Sci* 77:1241–1245
- Imada T, Yamaguchi S, Kawamura H (1979) Pathogenicity for baby chicks of the G-4260 strain of the picornavirus “avian nephritis virus”. *Avian Dis* 41:582–588
- Imada T, Yamaguchi S, Mase M et al (2000) Avian nephritis virus (ANV) as a new member of the family Astroviridae and construction of infectious ANV cDNA. *J Virol* 74:8487–8493
- Ivanics E, Rudas P, Salyi G et al (1999) Massive goitre (*Struma parenchymatosa*) in geese. *Acta Vet Hung* 47:217–231
- Jackson MK, Phillips SN (1996) Necrotizing hepatitis in pet birds associated with *Pseudomonas fluorescens*. *Avian Dis* 40:473–476
- Julian R (1982) Water deprivation as a cause of renal disease in chickens. *Avian Pathol* 11:615–617
- Kahn CM, Kahn M (2005) The Merck veterinary manual. <http://www.merckvetmanual.com/mvm/search.html?st=pet+birds&start=1&context=%2Fmvm>
- Kaikabo A, Mustapha A, Yaroro I et al (2007) Occurrence of egg impaction and peritonitis in a flock of commercial laying hens in Damaturu Nigeria. *Nig Vet J* 28:56–58
- Kaleta EF (1990) Herpesviruses of birds—a review. *Avian Pathol* 19:193–211
- Keller KA, Beaufre H, Brandão J et al (2013) Long-term management of ovarian neoplasia in two cockatiels (*Nymphicus hollandicus*). *J Avian Med Surg* 27:44–52
- Keymer I (1980) Disorders of the avian female reproductive system. *Avian Pathol* 9:405–419
- Krautwald-Junghanns M-E, Braun S, Pees M et al (2004) Research on the anatomy and pathology of the psittacine heart. *J Avian Med Surg* 18:2–11
- Landman WJ (1999) Amyloid arthropathy in chickens. *Vet Q* 21:78–82
- Landman WJ, Gruys E (1998) Amyloid arthropathy in an Indian peafowl. *Vet Rec* 142:90–91
- Landman WJ, Gruys E, Gielkens AL (1998a) Avian amyloidosis. *Avian Pathol* 27:437–449
- Landman WJ, vd Bogaard AE, Doornbal P et al (1998b) The role of various agents in chicken amyloid arthropathy. *Amyloid* 5:266–278
- Lewis JC, Kottke BA (1977) Endothelial damage and thrombocyte adhesion in pigeon atherosclerosis. *Science* 196:1007–1009
- Lightfoot TL (2010) Geriatric psittacine medicine. *Vet Clin N Am Exot Anim Pract* 13:27–49

- Lightfoot TL, Yeager JM (2008) Pet bird toxicity and related environmental concerns. *Vet Clin N Am Exot Anim Pract* 11:229–259
- Loukopoulos P, Bautista AC, Puschner B et al (2015) An outbreak of thyroid hyperplasia (goiter) with high mortality in budgerigars (*Melopsittacus undulatus*). *J Vet Diagn Investig* 27:18–24
- Lucké B, Schlumberger H (1949) Neoplasia in cold-blooded vertebrates. *Physiol Rev* 29:91–126
- Lumeij J (2000) Pathophysiology, diagnosis and treatment of renal disorders in birds of prey. *Rap Biomed* 3:170–178
- Luppi MM, de Melo AL, Motta RO et al (2007) Granulomatous nephritis in psittacines associated with parasitism by the trematode *Paratanaisia* spp. *Vet Parasitol* 146:363–366
- Mans C, Brown CJ (2007) Radiographic evidence of atherosclerosis of the descending aorta in a grey-cheeked parakeet (*Brotogeris pyrrhopterus*). *J Avian Med Surg* 21:56–62
- Mathey W (1967) Respiratory acariasis due to *Sternostoma tracheacolum* in the budgerigar. *J Am Vet Med Assoc* 150:777–780
- Mayer J, Donnelly TM (2012) Clinical veterinary advisor, birds and exotic pets, 1: Clinical veterinary advisor. Elsevier Health Sciences
- Millichamp NJ (2002) Ophthalmic disease in exotic species. *Vet Clin N Am Exot Anim Pract* 5:223–241
- Murakami T, Inoshima Y, Sakamoto E et al (2013a) AA amyloidosis in vaccinated growing chickens. *J Comp Pathol* 149:291–297
- Murakami T, Muhammad N, Inoshima Y et al (2013b) Experimental induction and oral transmission of avian AA amyloidosis in vaccinated white hens. *Amyloid* 20:80–85
- Mutinelli F, Corro M, Catania S et al (2008) Multiple feather follicle cysts in a Moroseta hen (*Gallus gallus*). *Avian Dis* 52:345–347
- Nakamura K, Ohtsu N, Nakamura T et al (2008) Pathologic and immunohistochemical studies of Newcastle disease (ND) in broiler chickens vaccinated with ND: severe nonpurulent encephalitis and necrotizing pancreatitis. *Vet Pathol* 45:928–933
- Nap A, Lumeij J, Stokhof A (1992) Electrocardiogram of the African grey (*Psittacus erithacus*) and Amazon (*Amazona* spp.) parrot. *Avian Pathol* 21:45–53
- Nedorost N, Maderer CA, Kolodziejek J et al (2012) Identification of mixed infections with different genotypes of avian bornaviruses in psittacine birds with proventricular dilatation disease. *Avian Dis* 56:414–417
- Noonan BP, de Matos R, Butler BP et al (2014) Nasal adenocarcinoma and secondary chronic sinusitis in a hyacinth macaw (*Anodorhynchus hyacinthinus*). *J Avian Med Surg* 28:143–150
- Nyholm NEI (1981) Evidence of involvement of aluminum in causation of defective formation of eggshells and of impaired breeding in wild passerine birds. *Environ Res* 26:363–371
- Ogawa H, Sanada Y, Sanada N et al (2011) Proventricular dilatation disease associated with avian bornavirus infection in a Citron-crested Cockatoo that was born and hand-reared in Japan. *J Vet Med Sci* 73:837–840
- Oglesbee BL, Hamlin RL, Klingaman H et al (2001) Electrocardiographic reference values for macaws (*Ara species*) and cockatoos (*Cacatua species*). *J Avian Med Surg* 15:17–22
- Olsen GH (2003) Oral biology and beak disorders of birds. *Vet Clin N Am Exot Anim Pract* 6:505–521
- Panigrahy B, Mathewson JJ, Hall CF et al (1981) Unusual disease conditions in pet and aviary birds. *J Am Vet Med Assoc* 178:394–395
- Parisi L, Clubb S (2010) What is your diagnosis? Proventricular dilatation disease. *J Avian Med Surg* 24:152–154
- Paterson S (2008) Skin diseases of exotic pets. Wiley, Oxford
- Pees M, Straub J, Krautwald-Junghanns M-E (2004) Echocardiographic examinations of 60 African grey parrots and 30 other psittacine birds. *Vet Rec* 155
- Perry RA, Gill J, Cross GM (1991) Disorders of the avian integument. *Vet Clin N Am Small Anim Pract* 21:1307–1327

- Phalen DN, Logan KS, Snowden KF (2006) *Encephalitozoon hellem* infection as the cause of a unilateral chronic keratoconjunctivitis in an umbrella cockatoo (*Cacatua alba*). *Vet Ophthalmol* 9:59–63
- Pilny AA (2008) The avian pancreas in health and disease. *Vet Clin North Am Exot Anim Pract* 11:25–34
- Pilny AA, Luong R (2005) Diabetes mellitus in a chestnut-fronted macaw (*Ara severa*). *J Avian Med Surg* 19:297–302
- Pinkster C (2016) T-cell Lymphosarcoma in a six-months old Indian Ringneck parrot. In: Annual conference of association of avian veterinarians Australian Committe Ltd. <http://www.aavac.com.au/files/08-2016.pdf>. Accessed 07 Nov 2016
- Pollock C (2006) Diagnosis and treatment of avian renal disease. *Vet Clin N Am Exot Anim Pract* 9:107–128
- Rae M (1995) Endocrine disease in pet birds. *Semin Avian Exotic Pet Med* 4:32–38
- Raidal SR, Sarker S, Peters A (2015) Review of psittacine beak and feather disease and its effect on Australian endangered species. *Aust Vet J* 93:466–470
- Ramis A, Gibert X, Majo N et al (1999) Metastatic oral squamous cell carcinoma in a Montagu's harrier (*Circus pigargus*). *J Vet Diagn Investig* 11:191–194
- Ratcliffe HL (1933) Incidence and nature of tumors in captive wild mammals and birds. *Am J Can* 17:116–135
- Reavill DR (2004) Tumors of pet birds. *Vet Clin N Am Exot Anim Pract* 7:537–560
- Reavill DR, Dorrestein GM (2010) Pathology of aging psittacines. *Vet Clin N Am Exot Anim Pract* 13:135–150
- Reece R (1992) Observations on naturally occurring neoplasms in birds in the state of Victoria, Australia. *Avian Pathol* 21:3–32
- Rembert MS, Smith JA, Strickland KN et al (2008) Intermittent bradyarrhythmia in a Hispaniolan Amazon parrot (*Amazona ventralis*). *J Avian Med Surg* 22:31–40
- Rich GA (2003) Syndromes and conditions of parrotlets, pionus parrots, poicephalus, and mynah birds. *Semin Avian Exotic Pet Med* 12:144–148
- Rivera S, McClearen JR, Reavill DR (2009) Treatment of nonepitheliotropic cutaneous B-cell lymphoma in an umbrella cockatoo (*Cacatua alba*). *J Avian Med Surg* 23:294–302
- Romagnano A (1996) Avian obstetrics. *Semin Avian Exotic Pet Med* 5:180–188
- Rosen LB (2012) Avian reproductive disorders. *J Exot Pet Med* 21:124–131
- Roskopf W Jr, Woerpel R (1982) Egg yolk peritonitis in a California desert tortoise. *Calif Vet* 3:13–15
- Rotstein DS, Flowers JR, Wolfe BA et al (2005) Renal trematodiasis in captive double-toothed barbets (*Lybius bidentatus*). *J Zoo Wildl Med* 36:124–126
- Rubbenstroth D, Rinder M, Stein M et al (2013) Avian bornaviruses are widely distributed in canary birds (*Serinus canaria f. domestica*). *Vet Microbiol* 165:287–295
- Rubinstein J, Lightfoot T (2014) Feather loss and feather destructive behavior in pet birds. *Vet Clin North Am Exot Anim Pract* 17:77–101
- Rupley AE (1997) Manual of avian practice. Philadelphia WB Saunders
- Russell W (1970) Iodide goiter in penguins. *J Zoo Animal Med* 24–27
- Sarker S, Moylan KG, Ghorashi SA et al (2015) Evidence of a deep viral host switch event with beak and feather disease virus infection in rainbow bee-eaters (*Merops ornatus*). *Sci Rep* 5:14511
- Sasipreeyajan J, Newman JA (1988) Goiter in a cockatiel (*Nymphicus hollandicus*). *Avian Dis* 32:169–172
- Schlumberger HG (1954) Neoplasia in the parakeet I. Spontaneous chromophobe pituitary tumors. *Cancer Res* 14:237–245
- Schmidt RE, Reavill DR (2002) Thyroid hyperplasia in birds. *J Avian Med Surg* 16:111–114
- Schmidt RE, Reavill DR (2008) The avian thyroid gland. *Vet Clin North Am Exot Anim Pract* 11:15–23
- Schmidt RE, Reavill DR, Phalen DN (2008) Pathology of pet and aviary birds. Wiley

- Sedacca CD, Campbell TW, Bright JM et al (2009a) Chronic cor pulmonale secondary to pulmonary atherosclerosis in an African Grey parrot. *J Am Vet Med Assoc* 234:1055–1059
- Sedacca CD, Campbell TW, Bright JM et al (2009b) Chronic cor pulmonale secondary to pulmonary atherosclerosis in an African Grey parrot. *J Am Vet Med Assoc* 234:1055–1059
- Seibert LM (2006) Feather-picking disorder in pet birds. In: *Manual of parrot behavior*, pp 255–265
- Sevimli A, Yagci A, Bulbul A (2013) Matrix metalloproteinase, vitamin A and methylprednisolone effects on experimentally induced amyloid arthropathy. *Biotech Histochem* 88:336–344
- Sevimli A, Yalcin M, Cangul IT et al (2012) Investigation of serum amino acid and serum amyloid A concentrations in chickens with amyloid arthropathy. *Vet Q* 32:17–23
- Shivaprasad HL, Phalen DN (2012) A novel herpesvirus associated with respiratory disease in Bourke's parrots (*Neopsephotus bourkii*). *Avian Pathol* 41:531–539
- Shuster KA, Brock KL, Dysko RC et al (2012) Polytetrafluoroethylene toxicosis in recently hatched chickens (*Gallus domesticus*). *Comp Med* 62:49–52
- Silvanose C, Bailey T, Naldo J et al (2001) Bacterial flora of the conjunctiva and nasal cavity in normal and diseased captive bustards. *Avian Dis* 45:447–451
- Simone-Freilicher E (2007) Use of isoxsuprine for treatment of clinical signs associated with presumptive atherosclerosis in a yellow-naped Amazon parrot (*Amazona ochrocephala auripalliata*). *J Avian Med Surg* 21:215–219
- Souza MJ, Newman SJ, Greenacre CB et al (2008) Diffuse intestinal T-cell lymphosarcoma in a yellow-naped Amazon parrot (*Amazona ochrocephala auripalliata*). *J Vet Diagn Investig* 20:656–660
- Spadafori G, Speer B (1999) *Birds for dummies*. IDG Books Worldwide, Foster City, CA
- Srinivasan P, Balasubramaniam GA, Murthy TRGK et al (2013) Bacteriological and pathological studies of egg peritonitis in commercial layer chicken in Namakkal area. *Asian Pac J Trop Biomed* 3:988–994
- Steenjens A, Veldman KT, Mevius DJ et al (2002) Molecular epidemiology of unilateral amyloid arthropathy in broiler breeders associated with *Enterococcus faecalis*. *Avian Pathol* 31:31–39
- Strunk A, Wilson GH (2003) Avian cardiology. *Vet Clin N Am Exot Anim Pract* 6:1–28
- Tanabe Y (1965) Relation of thyroxine secretion rate to age and growth rate in the cockerel. *Poult Sci* 44:591–596
- Tidemann SC, McOrist S, Woinarski JC et al (1992) Parasitism of wild Gouldian finches (*Erythrura gouldiae*) by the air-sac mite *Sternostoma tracheacolum*. *J Wildl Dis* 28:80–84
- Tully TN, Dorrestein GM, Jones AK (2009) *Handbook of Avian Medicine*. W.B. Saunders, Edinburgh
- Turrel JM, McMillan MC, Paul-Murphy J (1987) Diagnosis and treatment of tumors of companion birds II. *AAV Today* 1:159–165
- Vice C (1992) Myocarditis as a component of psittacine proventricular dilatation syndrome in a Patagonian conure. *Avian Dis* 36:1117–1119
- Vink-Nooteboom M, Schoemaker N, Kik M et al (1998) Clinical diagnosis of aneurysm of the right coronary artery in a white cockatoo (*Cacatua alba*). *J Small Anim Pract* 39:533–537
- Wade LL, Newman SJ (2004) Hemoglobinuric nephrosis and hepatosplenic erythrophagocytosis in a dusky-headed conure (*Aratinga weddelli*) after ingestion of garlic (*Allium sativum*). *J Avian Med Surg* 18:155–161
- Wadsworth P, Jones D (1979) Some abnormalities of the thyroid gland in non-domesticated birds. *Avian Pathol* 8:279–284
- Walsh AL, Shivaprasad H (2013) Unusual lesions of atherosclerosis in psittacines. *J Exot Pet Med* 22:366–374
- Web A (2014) Birds: Loss of voice/changes in voice. <https://www.beautyofbirds.com/lossofvoice.html>. Accessed 7 Nov 2016

- Welchman Dde B, Ainsworth HL, Jensen TK et al (2013) Demonstration of *Ornithobacterium rhinotracheale* in pheasants (*Phasianus colchicus*) with pneumonia and airsacculitis. *Avian Pathol* 42:171–178
- Wensman JJ, Jaderlund KH, Holst BS et al (2014) Borna disease virus infection in cats. *Vet J* 201:142–149
- Wideman JRR, Rocish WB, Satnick JL et al (1989) Methionine hydroxy analog (free acid) reduces avian kidney damage and urolithiasis induced by excess dietary calcium. *J Nutr* 119
- Wideman R, Closser J, Roush W et al (1985) Urolithiasis in pullets and laying hens: role of dietary calcium and phosphorus. *Poult Sci* 64:2300–2307
- Willis AM, Wilkie DA (1999) Avian ophthalmology, Part 2: Review of ophthalmic diseases. *J Avian Med Surg* 13:245–251
- Wisser J, Ippen R (1991) Goiter incidence among zoo birds. *Wiener Tierärztliche Monatsschrift* 78:362–365
- Worell AB (2012) Current trends in avian pediatrics. *J Exot Pet Med* 21:115–123
- Zandvliet MM (2005) Electrocardiography in psittacine birds and ferrets. *Semin Avian Exotic Pet Med* 14:34–51
- Zhang W, Shen Q, Mou J et al (2008) Hepatitis E virus infection among domestic animals in eastern China. *Zoonoses Public Health* 55:291–298