

ORIGINAL ARTICLE

Advantages of the modified double ring areolar incision over the traditional areolar incision in multicentric breast fibroadenoma surgery

Mingliang Zhang, Gongjin Shen, Song Zhang, Zhen Cui & Jun Qian

Department of Oncology Surgery, First Affiliated Hospital of Bengbu Medical College, Bengbu, China

Keywords

Areola incision; breast benign tumor; double-ring areola incision.

Correspondence

Mingliang Zhang, Department of Oncology Surgery, First Affiliated Hospital of Bengbu Medical College, No. 287 Changhuai Road, Bengbu City, Anhui Province 233030, China.
Tel: +86 552 308 6187
Fax: +86 552 308 6026
Email: kzhlrp@163.com

Received: 28 March 2017;

Accepted: 17 April 2017.

doi: 10.1111/1759-7714.12456

Thoracic Cancer 8 (2017) 423–426

Abstract

Background: This study was conducted to investigate the clinical advantages of modified double ring areola incision (MDRAI) compared to ordinary areola incision (OAI) in multicentric breast fibroadenoma in women.

Methods: Sixty cases of multicentric benign breast tumor were recruited from the First Affiliated Hospital of Bengbu Medical College from January to December 2016. The cases were divided into two groups according to surgical approach: MDRAI ($n = 20$) and OAI ($n = 40$). The operation duration, intraoperative blood loss, drainage time, and postoperative recurrence rate in the first six months were compared.

Results: The mean age and tumor locations were not statistically different between the groups ($P > 0.05$). However, more lesions and larger tumor diameter were found in the MDRAI group than in the OAI group, with statistical difference ($P < 0.05$). The operation duration and drainage time of the two groups were not statistically different for unilateral or bilateral lesions ($P > 0.05$). However, the intraoperative blood loss was statistically different between the two groups ($P < 0.05$). All 60 cases received six months of follow-up. Eight recurrent cases were found in the OAI group, but none in the MDRAI group. The recurrence rate was significantly different ($\chi^2 = 4.62, P < 0.05$).

Conclusion: Compared with OAI, MDRAI offers greater advantages in the aspects of blood loss and recurrence for the treatment of breast benign tumor, especially for multicentric larger lesions.

Introduction

Fibroadenoma is the most common benign tumor of the female breast.¹ Up to 10–20% of this tumor is multicentric with ≥ 2 foci and located in the same or different breast quadrants.² In multicentric breast fibroadenoma patients with no obvious symptoms, clinical follow-up should be conducted.³ However, in cases with obvious pain, anxiety, breast shape change, or malignant potential, surgical resection is needed.³ Achieving both thorough resection and aesthetic appearance simultaneously has been a constant challenge among breast surgeons. The creation of the “areolar incision” addressed this concern to a certain extent.⁴ However, this method had some limitations in clinical practice, particularly in tumors located at the breast edge,

large tumors, tumors distributed in more than three quadrants, sagging breasts, breasts with a large areola, and co-occurrence with a mastitis lump. In this study, we improved the areolar incision method and achieved good results using double ring incision in the surgical management of the disease.

Methods

Patients

A total of 60 cases of breast fibroadenoma were selected from the First Affiliated Hospital of Bengbu Medical College from January to December 2016. All patients were

preoperatively examined and assessed to have no contraindication against surgery. The entire treatment plan was relayed to the patients and their families. Malignant cases, which were determined by intraoperative rapid frozen pathology, were eliminated from this study. Eligible cases were retrospectively divided into two groups according to surgical approach: ordinary areola incision (OAI) and modified double ring areola incision (MDRAI). In the OAI group, the mean age was 28.5 ± 6.2 years old; 26 patients presented with unilateral lesions, while 14 cases had bilateral lesions. In the MDRAI group, the mean age was 27.3 ± 5.8 years old; 12 patients showed unilateral lesions, while eight harbored bilateral lesions. The institutional ethics committee of the First Affiliated Hospital of Bengbu Medical College approved the study and signed informed consent was obtained from all included patients.

Method

All patients underwent preoperative imaging examination and surface markers were applied for the number, location, and range of breast lesions. In the OAI group, the following process was conducted. With the patient in the supine position, lidocaine local anesthesia was injected into the planned incision area. An arc-shaped incision was then created at the edge of the areolar skin junction, depending on lesion conditions (size, location, and range). Incision lengths of more than 50% of the areolar circumference were avoided to prevent damage to the nipple blood supply. The skin, subcutaneous tissue, and fat were cut layer by layer up to the gland surface. Separation was continued from the space between the gland surface and the fat layer to the focus using a hook. The fat layer was then cut, and the lesions, along with a few of the normal surrounding glands, were resected. The specimens were sent for flash-frozen examination. Careful hemostasis was performed on the exposed wound surface with the aid of a hook. The

normal glands were then closed symmetrically on the residual surface by an absorbable line. For multiple masses located in other quadrants, these steps were repeated. A negative-pressure drainage tube was used on the wound surface for large masses or inflammatory lesions. Each incision was sutured continuously or interruptedly with an absorbable line. The chest was then wrapped postoperatively with elastic bandage.

In the MDRAI group, the preoperative examination, intraoperative posture, and anesthesia were the same as in the OAI group. The following procedures were then applied. On the basis of the lesion specifications (size, location, range, areolar size, sagging breast, etc.), a 360° ring incision was first created at the areolar edge or on the areola. A second 360° ring incision was then made 0.5–2.0 cm from the first incision (depending on the specific lesion circumstances). The skin epidermis between the two rings was carefully removed with a thin blade, whereas the dermis and subcutaneous vascular network were retained. The subcutaneous and fat tissues were cut layer by layer (Fig 1). The remainder of the procedure and the drainage tube placement principle were the same as those in the OAI group. The normal glands were freed and retained and a gland flap was created. Finally, the first and second incision rings were sutured continuously or interruptedly by an absorbable line. A schematic diagram of the different incision methods is demonstrated in Figure 2.

Statistical analysis

Statistical analysis was performed using STATA 11.0 statistical software (<http://www.stata.com>). Measurement data were expressed by $\bar{x} \pm s$ and the comparison between groups was made based on a *t*-test of the sample mean. The enumeration data were expressed with a relative number, and the comparison between groups was made based on an χ^2 test. $P < 0.05$ was considered statistically significant.

Results

General patient characteristics

The mean age of the patients and tumor locations were not statistically different between the MDRAI and OAI groups ($P > 0.05$). However, more lesions and larger tumors were found in the MDRAI group than in the OAI group, with statistical difference ($P < 0.05$) (Table 1).

Operation outcomes

The operation and drainage durations in the two groups were not significantly different for unilateral or bilateral lesions ($P > 0.05$); however, the intraoperative blood loss

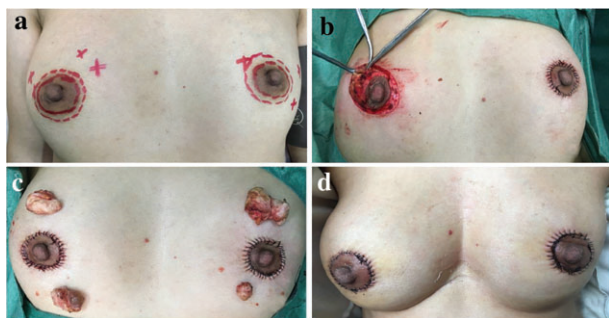

Figure 1 Surgical procedure of modified double ring areola incision for multicentric breast benign tumor. (a) Tumor location, (b) tumor separation and removal, (c) postoperation, and (d) two days postoperation.

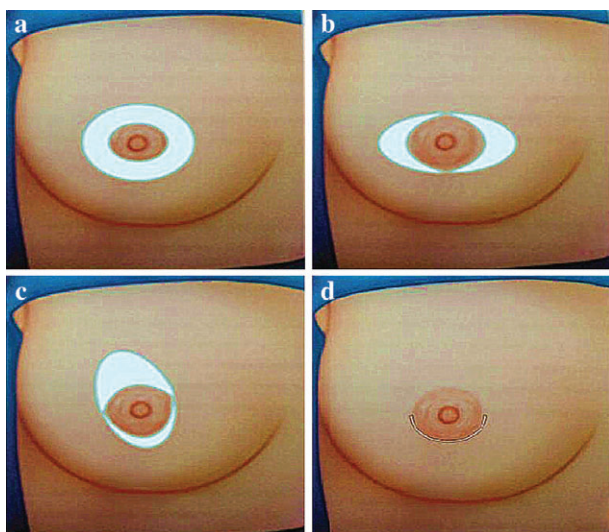


Figure 2 Schematic diagram of the different incision methods. (a) Double-ring areola incision, (b,c) modified double ring incision to adapt different requirements, and (d) ordinary areola incision.

was statistically different between the groups ($P < 0.05$) (Table 2).

Postoperative recurrence

All 60 cases received six months of follow-up. Eight cases of recurrence were found in the OAI group but none in the MDRAI group, with statistical difference ($\chi^2 = 4.62$; $P < 0.05$).

Discussion

The majority of breast masses in young patients are benign. Fibroadenoma accounts for the major portion at approximately 68%, while breast cancer accounts for less than 1%.⁵ Benign asymptomatic fibroma can be conservatively observed and regularly followed up.^{6,7} However,

Table 1 General patient characteristics

Item	MDRAI (n = 20)	OAI (n = 40)
Age (years)	27.3 ± 5.8	28.5 ± 6.2
Lesion		
Unilateral breast N (%)	12 (60.0)	26 (65.0)
Bilateral breast N (%)	8 (40.0)	14 (35.0)
Number of tumors		
Unilateral breast (mean ± SD)	3.9 ± 1.4	2.5 ± 0.7*
Bilateral breast (mean ± SD)	6.6 ± 1.7	4.6 ± 0.8*
Tumor diameter (cm)		
Unilateral breast (mean ± SD)	4.3 ± 1.3	2.9 ± 0.8*
Bilateral breast (mean ± SD)	4.0 ± 1.7	2.8 ± 1.0*

* $P < 0.05$ compared with modified double ring areola incision (MDRAI) group. OAI, ordinary areola incision; SD, standard deviation.

Table 2 Comparison of surgical and drainage duration, and blood loss (mean ± SD)

Item	MDRAI (n = 20)	OAI (n = 40)
Operation duration (min)		
Unilateral breast	25.1 ± 5.3	24.3 ± 3.6
Bilateral breast	45.6 ± 10.6	43.7 ± 9.5
Blood loss (mL)		
Unilateral breast	15.0 ± 4.8	19.6 ± 3.3*
Bilateral breast	29.4 ± 7.1	36.3 ± 5.9*
Drainage duration (days)		
Unilateral breast	1.8 ± 0.4	2.0 ± 0.3
Bilateral breast	1.9 ± 0.5	2.1 ± 0.6

* $P < 0.05$ compared with modified double ring areola incision (MDRAI) group. OAI, ordinary areola incision; SD, standard deviation.

surgery is necessary for patients with pain, anxiety, and altered appearance.⁸

Traditional surgery is performed by creating a radial or arc incision on the tumor surface. This obviously develops into a postoperative scar, and thus, this method is currently not recommended. In recent years, percutaneous rotary cutting and in situ ablation technology have been applied in breast fibroma resection. These techniques significantly ameliorated the cosmetic problem; however, as the tumor leaves residue, these two methods are not appropriate in cases of large tumors.⁹ Thus, a surgical resection procedure that can thoroughly resect the tumor, along with a small amount of normal tissue, is needed. To achieve aesthetic requirements, scars should be hidden as much as possible.¹⁰ In long-term practice, the design of the areolar incision can be adjusted to solve these problems. The anatomic location, deep color, and significant wrinkles of the areola can significantly cover a wound-healing scar. Hence, an areolar incision is performed on the quadrant in the direction of the corresponding mass by an auxiliary hook. In the process, a subcutaneous tunnel is constructed for tumor resection. However, this method does contain some limitations. Given that the areolar blood supply largely stems from the subcutaneous vascular network, the general extent of the areolar incision must be less than 180° to prevent ischemic injury to the areola. For large breasts, a tumor mass located on the edge of a dense gland, or an especially large tumor, this incision is difficult to accomplish because of the relatively limited exposure, ease of bleeding, long operation duration, and trauma.¹¹ In cases with concurrent inflammatory masses, such as plasma cell mastitis, when the cross-quadrant resection of lesions is required, poor exposure under the areolar incision causes inadequate excision, poor healing of postoperative incision, infection, or disease recurrence. On the basis of these conditions, this procedure has been improved through the use of a double ring incision. In this method, the epidermis is removed between two rings, whereas the

dermis is retained to preserve the subcutaneous vascular network and greatly avoid nipple ischemia. The corresponding second ring is cut on the outer areolar skin.

In our study sample, two patients presented with large breast masses located on the breast edge during surgery that were difficult to expose and remove by OAI. The MDRAI method was applied, and the mass was readily removed.

The following advantages of using the MDRAI were observed in our study: (i) the ring diameter was increased, providing sufficient exposure; (ii) all tumors in the four quadrants can be resected simultaneously at 360°; (iii) an excellent view for gland removal of more than one-fourth of the quadrant was achieved, and sufficient room was available to mold the gland flap to maximally protect the breast shape; and (iv) large breasts can be reduced and sagging breasts may be lifted.

No significant difference between the MDRAI and OAI methods was observed in either surgery or extubation duration in our study. Both procedures hid postoperative scars and showed similar cosmetic results. However, the MDRAI method provided the opportunity for simultaneous large-tumor resection from multiple quadrants and reduced average bleeding. In addition, because of good exposure, the postoperative recurrence risk in the MDRAI group was significantly decreased. Compared to OAI, MDRAI was more efficient and can be applied in clinical practice.

Acknowledgment

This study was supported by Bengbu Medical College in 2016 (No. GX2016039).

Disclosure

No authors report any conflict interest.

References

- 1 Houssami N, Cheung MN, Dixon JM. Fibroadenoma of the breast. *Med J Aust* 2001; **174**: 185–8.
- 2 Bendifallah S, Canlorbe G. [Common benign breast tumors including fibroadenoma, phyllodes tumors, and papillary lesions: Guidelines.]. *J Gynecol Obstet Biol Reprod (Paris)* 2015; **44**: 1017–29 (In French.)
- 3 El-Wakeel H, Umpleby HC. Systematic review of fibroadenoma as a risk factor for breast cancer. *Breast* 2003; **12**: 302–7.
- 4 Shrotria S. The peri-areolar incision--gateway to the breast. *Eur J Surg Oncol* 2001; **27**: 601–3.
- 5 Levi F, Randimbison L, Te VC, La Vecchia C. Incidence of breast cancer in women with fibroadenoma. *Int J Cancer* 1994; **57**: 681–3.
- 6 Ng WK, Mrad MA, Brown MH. Juvenile fibroadenoma of the breast: Treatment and literature review. *Can J Plast Surg* 2011; **19**: 105–7.
- 7 Larsen TK, Faurschou JP, Bak M, Ryttof NF. [Fibroadenoma of the breast--modern strategy of treatment.]. *Ugeskr Laeger* 2003; **165**: 1979–83 (In Danish.)
- 8 YJ O, Choi SH, Chung SY, Yang I, Woo JY, Lee MJ. Spontaneously infarcted fibroadenoma mimicking breast cancer. *J Ultrasound Med* 2009; **28**: 1421–3.
- 9 Achebe JU, Njeze GE, Okwesili OR. Treatment of unilateral giant fibroadenoma by breast reduction skin incision: The inverted "T" technique. *Niger J Clin Pract* 2014; **17**: 43–6.
- 10 Ugburo AO, Olajide TO, Fadeyibi IO, Mofikoya BO, Lawal AO, Osinowo AO. Differential diagnosis and management of giant fibroadenoma: Comparing excision with reduction mammoplasty incision and excision with inframammary incision. *J Plast Surg Hand Surg* 2012; **46**: 354–8.
- 11 Liu XF, Zhang JX, Zhou Q, Chen F, Shao ZM, Lu C. A clinical study on the resection of breast fibroadenoma using two types of incision. *Scand J Surg* 2011; **100**: 147–52.