

The Meniscomemoral Ligament Mimicking a Lateral Meniscus Tear

Bong Keun Park, MD, Hohyoung Lee, MD, Seong-Tae Kim, MD, and Min Geun Yoon, MD

Department of Orthopedic Surgery and Traumatology, Cheju Halla General Hospital, Jeju, Korea

A 58-year-old male patient who had developed left knee pain with a history of trauma was referred to our hospital. Physical examination and further examination by magnetic resonance imaging revealed results that closely resemble a horizontal tear of the lateral meniscus and a tear of the medial meniscus. Arthroscopically, we found a cord-like structure originating from the posterior 1/3 portion of the lateral meniscus and passing obliquely toward the medial femoral condyle in front of the posterior cruciate ligament without a tear of the lateral meniscus. In this report, we describe a rare case of anterior meniscomemoral ligament that was clearly seen on arthroscopy and mimicked a meniscal tear, which is also known as a pseudo-tear of the meniscus.

Keywords: Knee, Ligament, Meniscomemoral, Tear, Meniscus

As reported by Sanders et al.¹⁾, it is challenging for arthroscopic surgeons to differentiate a normal variant of the meniscomemoral ligament from a tear of the lateral meniscus or loose body formed by an intra-articular avulsed osteochondral or meniscal fragment²⁾. Because of its radiological appearance mimicking a pathologic tear of the meniscus or an osteochondral lesion, it is estimated that numerous patients with meniscomemoral ligaments have undergone arthroscopic procedures that was essentially unnecessary. We report a rare case of meniscomemoral ligament that was clearly seen on arthroscopy preoperatively and mimicked a lateral meniscal tear, which is also known as a pseudo-tear of the meniscus.

Case Report

A 58-year-old male patient presented with left knee lateral pain after a slip down injury a month ago. He had a history of ligamentous injury that occurred 20 years ago, for which no further diagnosis or treatment was done. He had been experiencing mild 'giving way' symptoms since then, but the symptom aggravated after the recent trauma. On the physical examination, we found that the range of motion of the patient's left knee was normal. Medial joint line tenderness was present. The result of the posterior drawer test was grade 2 positive, and McMurray test was also positive-knee pain in external rotation. Plain X-ray showed unremarkable findings.

On magnetic resonance imaging (MRI), a longitudinal tear of the medial meniscus (Fig. 1A) and a horizontal tear of the lateral meniscus (Fig. 1B) were shown with high-intensity signal on the proton density spectral presaturation inversion recovery coronal image. There was also a slightly high-intensity signal shown in the posterior cruciate ligament (PCL), indicating a probable acute partial tear of the ligament or evidence of an old injury.

For diagnostic arthroscopy, we made an anterolateral portal for visualization and an anteromedial portal for performing surgery. By examining the intercondylar notch and articular surfaces of the femur and tibia through these portals, we arthroscopically confirmed a longitudinal tear of the medial meniscus but the

Received June 23, 2016; Revised July 26, 2016;

Accepted August 16, 2016

Correspondence to: Hohyoung Lee, MD

Department of Orthopedic Surgery and Traumatology, Cheju Halla General Hospital, 65 Doryeong, Jeju 63127, Korea

Tel: +82-64-740-5140, Fax: +82-64-743-3110

E-mail: mdlee@hanmail.net

This is an Open Access article distributed under the terms of the Creative Commons Attribution Non-Commercial License (<http://creativecommons.org/licenses/by-nc/4.0/>) which permits unrestricted non-commercial use, distribution, and reproduction in any medium, provided the original work is properly cited.

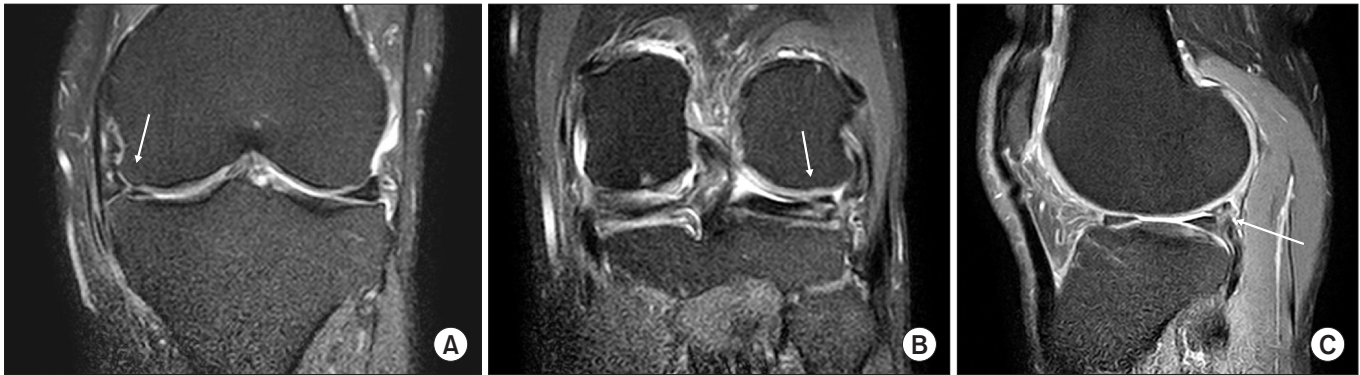

Fig. 1. Coronal proton density spectral presaturation inversion recovery magnetic resonance imaging scans showing high-intensity signal that resembles a tear of the medial (A) and lateral (B, C) menisci, respectively.

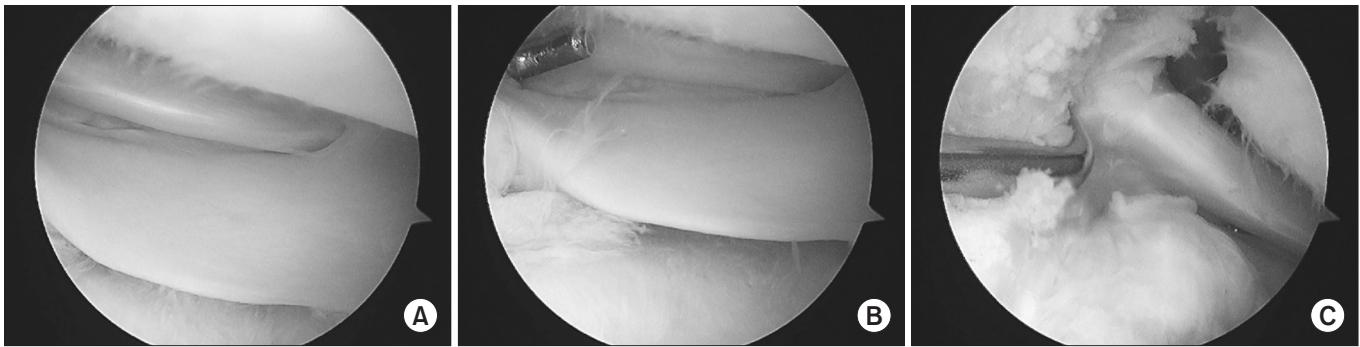


Fig. 2. Arthroscopic views of the left knee show a cord-like structure originating from the posterior horn of the lateral meniscus (A, B) and inserting into the lateral side of the medial femoral condyle. (C) Arthroscopic views from the anteromedial portal (A, B) and from the anterolateral portal (C).

lateral meniscus was intact without tear. Instead, we confirmed a cord-like structure, originating from the posterior 1/3 portion of the lateral meniscus and passing obliquely toward the medial femoral condyle in front of the PCL-anterior meniscomfemoral ligament (ligament of Humphrey) (Fig. 2). There was no sign of a tear of the anterior cruciate ligament and PCL structures. The main cause of the knee pain was finally proven to be due to the medial meniscus tear because there was neither a lateral meniscus tear nor a PCL injury in this patient.

Arthroscopic partial medial meniscectomy was performed, and at the 1-year follow-up, the patient could perform daily activities without any discomfort.

Discussion

We reported a rare case of meniscomfemoral ligament that was mimicking a tear of the lateral meniscus on preoperative arthroscopy. According to Watanabe et al.²⁾, 32.5% of the meniscomfemoral ligaments were present with Wrisberg ligament and 33% were present with Humphrey ligament and seen either as a discrete

low signal-intensity bulge or a lump along the concave surface of the PCL or as a small, ovoid, low signal intensity focus just anterior to the PCL. In a study performed by Bintoudi et al.³⁾, only 81 among 500 patients (37%) presented both meniscomfemoral ligaments and in other studies of Moran et al.⁴⁾ and Lee et al.⁵⁾, the percentage was 28% and 1%, respectively. Erbagci et al.⁶⁾ did not reveal the incidence. These studies show variations of the anatomy of meniscomfemoral ligaments and the low incidences of meniscomfemoral ligaments. In our institution, the meniscomfemoral ligament was observed in one individual, which was clearly confirmed by arthroscopy.

In our case, we initially thought the ligament of Humphrey (anterior meniscomfemoral ligament) was combined with a tear of the lateral meniscus showing high-intensity signals that extend along the ligament of Humphrey on both coronal and sagittal MRI images (Fig. 3). However, in diagnostic arthroscopy, there was no tear on the lateral meniscus and instead we could clearly confirm the presence of the anterior meniscomfemoral ligament originating from the posterior horn of the lateral meniscus and obliquely inserting into the medial femoral condyle.

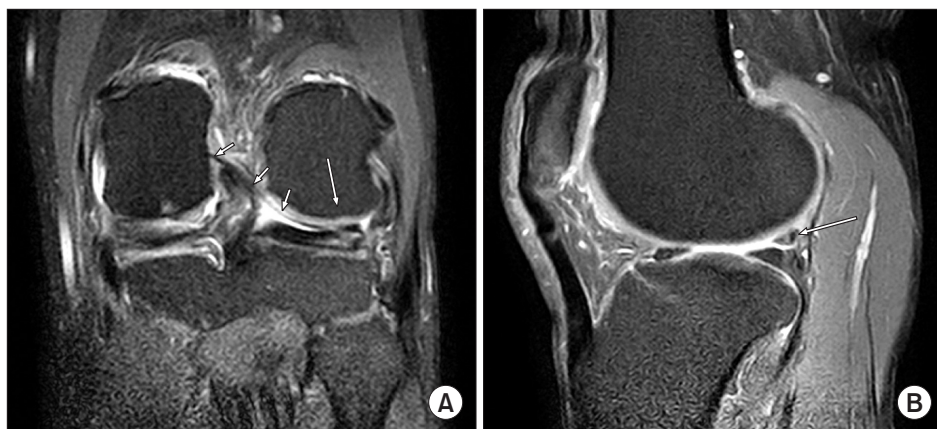

Fig. 3. (A) The ligament of Humphrey (anterior menisiofemoral ligament) was observed as a thin, linear band, with low-signal intensity on coronal magnetic resonance imaging (short arrows). (A, B) High-intensity signal extending to the ligament of Humphrey mimicking a tear of the lateral meniscus (long arrows).

So arthroscopy surgeons should take menisiofemoral ligaments into consideration and pay close attention to the confusing radiological features when encountering patients with meniscal tears. In addition, it is advised to inform the patients of the possibility of the presence of menisiofemoral ligaments before surgery.

Although menisiofemoral ligaments are not commonly or feasibly seen structures as shown in previous studies, the menisiofemoral ligament itself can be observed during a diagnostic arthroscopic procedure using methods developed by many orthopedic surgeons^{7,8)}.

In many biomechanical studies including the research performed by Amis et al.⁹⁾, it has been reported that the menisiofemoral ligament plays a great role after PCL injury. Therefore, it is important to distinguish actual hypertrophy after a PCL injury from congenital abnormality.

In our case, the patient had a history of knee trauma several decades ago but the PCL injury was undiagnosed at that time. On physical examination and preoperative MRI, there was a possibility of PCL injury; however, it was unclear whether the injury resulted from the recent trauma or the remnant of the old neglected injury. Ultimately, the PCL was confirmed to be intact in the patient. So we thought that the variant of the menisiofemoral ligament, which was clearly seen in our case, was more likely to be congenital abnormality rather than hypertrophy after a PCL injury.

The clinical relevance of this report is that normal variants of anatomical structures of the menisiofemoral ligaments may be mimicking tears of the lateral meniscus on MRI but they are actually intact on arthroscopy. Also, as we have seen in our case, the patient initially did not show signs of lateral meniscus tears in physical examination—no pain in the knee in internal rotation during McMurray test and no lateral joint line tenderness. The tear of the lateral meniscus was prediagnosed through MRI

before the arthroscopic procedure. So we would emphasize the importance of preoperative physical examination and comparison of the results with radiological findings to reduce the risk of misdiagnosis in meniscal tears.

Conflict of Interest

No potential conflict of interest relevant to this article was reported.

References

1. Sanders TG, Linares RC, Lawhorn KW, Tirman PF, Houser C. Oblique meniscomeniscal ligament: another potential pitfall for a meniscal tear: anatomic description and appearance at MR imaging in three cases. *Radiology*. 1999;213:213-6.
2. Watanabe AT, Carter BC, Teitelbaum GP, Bradley WG Jr. Common pitfalls in magnetic resonance imaging of the knee. *J Bone Joint Surg Am*. 1989;71:857-62.
3. Bintoudi A, Natsis K, Tsitouridis I. Anterior and posterior menisiofemoral ligaments: MRI evaluation. *Anat Res Int*. 2012;2012:839724.
4. Moran CJ, Poynton AR, Moran R, Brien MO. Analysis of menisiofemoral ligament tension during knee motion. *Arthroscopy*. 2006;22:362-6.
5. Lee BY, Jee WH, Kim JM, Kim BS, Choi KH. Incidence and significance of demonstrating the menisiofemoral ligament on MRI. *Br J Radiol*. 2000;73:271-4.
6. Erbagci H, Yildirim H, Kizilkan N, Gumusburun E. An MRI study of the menisiofemoral and transverse ligaments of the knee. *Surg Radiol Anat*. 2002;24:120-4.
7. Gupte CM, Bull AM, Atkinson HD, Thomas RD, Strachan RK, Amis AA. Arthroscopic appearances of the menisio-

- femoral ligaments: introducing the "meniscal tug test". *Knee Surg Sports Traumatol Arthrosc.* 2006;14:1259-65.
8. Lee BJ, Kyung HS, Yoon SD. Anterolateral meniscomemoral ligament with congenital aplasia of the anterior cruciate ligament: a case report. *Arthrosc Orthop Sports Med.* 2015;2:120-3.
 9. Amis AA, Bull AM, Gupte CM, Hijazi I, Race A, Robinson JR. Biomechanics of the PCL and related structures: posterolateral, posteromedial and meniscomemoral ligaments. *Knee Surg Sports Traumatol Arthrosc.* 2003;11:271-81.