

**LETTER TO THE EDITOR**

# Call Center Operator's Dystonia

**Dokyung Lee,<sup>1</sup> Jung A Kim<sup>2</sup>**<sup>1</sup>Department of Neurology, Neuroscience Center, Chung General Hospital, Seongnam, Korea<sup>2</sup>Department of Family Medicine, Seoul Medical Center, Seoul, Korea

Task-specific dystonia (TSD) presents as an insidious loss of dexterity triggered by performance of specific motor tasks. Repetitive, overpracticing of a motor task may contribute to developing TSD.<sup>1</sup> Many types of TSD can affect individuals with jobs that require the repetition of skilled tasks.<sup>2</sup> This report discusses a case of a movement disorder that affected a woman who works as a call center operator.

A 45-year-old right-handed woman visited our clinic for recurrent transient dysarthria and abnormal posturing of the fourth and fifth fingers of her left hand. She had been working as a customer service representative for 10 years at a financial company. She was responsible for receiving customer complaints via the telephone using a headset and typing on a keyboard. Three months previously, her fourth and fifth fingers of her left hand started to freeze, and her pronunciation became unclear while she was at her workplace using the headset and the keyboard. Her speech problem was manifested by stiffness her tongue and tightness in her bilateral temporal muscles when she speaks fast. She had to pronounce a voiceless consonant as a voiced consonant (e.g., [s] → [d] or [ð]). After a few hours of working, her pronunciation became unintelligible. Her dysarthria and finger movements did not always appear simultaneously. These symptoms did not occur during other daily routine activities. She reported that around the symptom onset, she was psychologically overstressed by her job.

A neurological examination showed no focal neurological deficits or extrapyramidal signs. There were no abnormalities in the lingual and facial movements examination. While she was typing on the keyboard, the fourth and fifth metacarpophalangeal joints of her left hand were slowly hyperextended, and then the

finger joints were flexed (Supplementary Video 1 in the online-only Data Supplement). Dysarthria could not be reproduced in the doctor's office because of the lack of a headset, and she reported that the dysarthria occurred only while she was wearing a headset. There were no possible maneuvers to alleviate the symptoms.

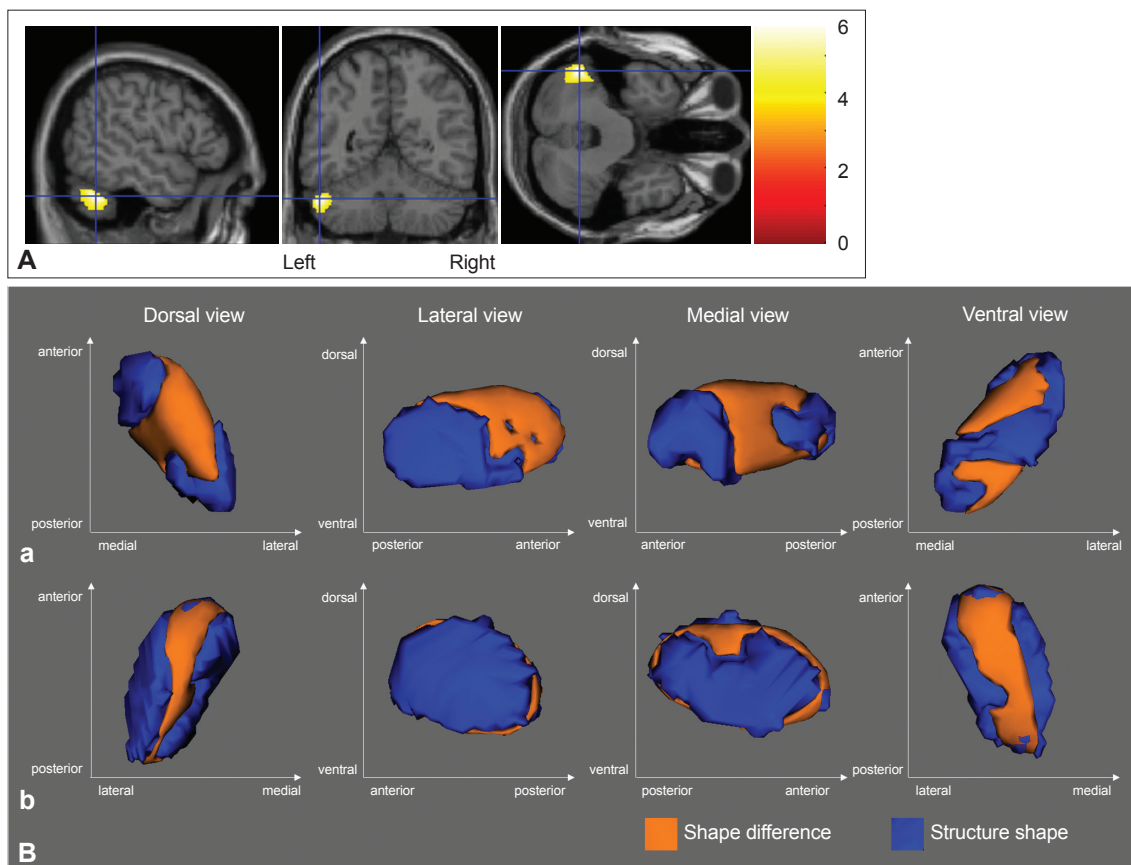
Her symptoms did not respond to clonazepam, baclofen and trihexyphenidyl. She finally quit her job.

Her brain MRI appeared overall to be normal. To quantitatively assess her brain, her brain MRI was statistically compared with the MRI scans of 21 age-matched women (mean age = 45.04, standard deviation = 8.04) using voxel-based morphometry (VBM) and vertex analysis. The controls were recruited from an MRI database at the author's institution. The institutional review board approved the retrospective use of MRI data.

VBM was performed using SPM12 (Wellcome Centre for Human Neuroimaging, London, UK, [www.fil.ion.ucl.ac.uk/spm/](http://www.fil.ion.ucl.ac.uk/spm/)) in MATLAB R2011a (Mathworks, Inc., Sherborn, MA, USA). The gray matter was segmented from the T1-weighted images of the recruited individuals. The segmented images were normalized into a standardized space. Then, a two-sample *t*-test was performed to compare the controls to the patient. The shape of the subcortical structures of the patient's brain was further studied using FMRIB's Integrated Registration and Segmentation Tool (FIRST), which is part of FMRIB's Software Library (FSL 5.0.8, <http://www.fmrib.ox.ac.uk/fsl>). The subcortical structures, including the putamen, caudate, thalamus, and globus pallidus (GP), were segmented from the brain MRI scans. Vertex analysis using the FIRST tool was performed between the controls and the patient to assess the shape differences in the segmented subcorti-

Received: August 1, 2018 Revised: October 9, 2018 Accepted: October 24, 2018

Corresponding author: Dokyung Lee, MD, PhD, <https://orcid.org/0000-0002-4957-9952>Department of Neurology, Neuroscience Center, Chung General Hospital, 76 Sujeong-ro, Sujeong-gu, Seongnam 13316, Korea / Tel: +82-31-750-6000 / Fax: +82-31-753-8546 / E-mail: [corpsedk@naver.com](mailto:corpsedk@naver.com)© This is an Open Access article distributed under the terms of the Creative Commons Attribution Non-Commercial License (<https://creativecommons.org/licenses/by-nc/4.0/>) which permits unrestricted non-commercial use, distribution, and reproduction in any medium, provided the original work is properly cited.



**Figure 1.** Neuroimaging analysis. A: Significant results of voxel-based morphometry are displayed on a normalized space. There is a cluster with significantly larger gray matter volume in the lateral portion of the left cerebellar hemisphere in the patient's brain (Height threshold was set at  $p < 0.001$ , uncorrected. Multiple comparison problems were corrected at the cluster level by a false discovery rate, corrected  $p < 0.05$ ). B: Significant group comparison results (controls versus the patient) of the vertex analysis are visualized (orange: shape deformation of the patient's brain). The patient's bilateral globus pallidum (GP) shows significant deformations [(a) right GP: dorsal, lateral, and medial aspects, (b) left GP: dorsal and ventral aspects;  $p < 0.05$  was considered statistically significant and corrected for multiple comparisons (family wise error) using the clusterwise approach].

cal gray matter structures.

VBM analysis revealed that the patient had a significantly larger volume in the lateral portion of the left cerebellar hemisphere (Figure 1A).

Vertex analysis of the subcortical gray matter revealed significant regional shape differences in the dorsal medial and the lateral aspect of the right GP as well as the dorsal and ventral aspects of the left GP. There were no significant regional shape deformations in the bilateral putamen, caudate, and thalamus (Figure 1B).

In this case, the patient's symptoms included dysarthria induced by headset use with abnormal posturing of the fingers of the left hand that was induced by typing. If wearing a headset is presumed to function as a sensory-stimuli like an alleviating maneuver, her dysarthria is a paradoxical phenomenon.<sup>3</sup> However, wearing a headset also could be a conditioning task similar to grabbing a violin or putting lips on a trumpet that has been observed for dystonia in musicians.<sup>1</sup> Because her dysarthria was associated with occupational stress and the symptom was not prop-

erly examined, there is still a possibility that the origin of the symptom was a functional disorder. However, the symptom consistency and specific action inducing the symptom favors the possibility that her dysarthria is not functional. A call center operator needs to overpractice motor tasks, such as keyboard typing and pronouncing the same words or sentences, which shares a common mechanism from developing TSD. TSD may be the most compatible phenomenon for explaining her symptoms.<sup>1</sup>

TSD typically occurs in the hand that performs the more demanding tasks, such as the right hand in pianists, the left hand in violinists and the dominant hand in writer's cramp.<sup>4</sup> In this case, her left hand could have been the more important hand for keyboard typing.

Her finger movements basically displayed the same phenomena observed in typist's cramps, except the dysarthria was an additional feature.<sup>5</sup> However, because being a call center operator is a common job, similar cases may be reported in the future. Defining the term Call Center Operator's Dystonia could

be meaningful.

TSD can be considered a network disorder.<sup>6</sup> The GP and the cerebellum are major functional nodes of the dystonia network. As functional nodes of the dystonia network, the GP and the cerebellum can be affected by abnormal neuronal plasticity.<sup>6</sup> Therefore, structural changes in the patient's bilateral GP and left cerebellum indicated that her symptoms may share the pathophysiology of TSD.

Although the precise dystonia network could not be identified in this case, previous neuroimaging studies of dystonia indicate that shape deformation of the bilateral GP may have played a major role in initiating dystonia network. Moreover, the connection between the left cerebellum and the basal ganglia may have contributed to the laterality of the dystonia in her left fingers.<sup>7</sup> However, methodological limitations due to having just a single case to study suggest that further studies with more cases are needed.

Several jobs require skilled individuals. Therefore, numerous types of TSD may occur.<sup>2</sup> Further studies on the functional node of dystonia networks are warranted to understand and manage TSD.

#### Supplementary Video Legends

Video 1. During her attempt at typing on the keyboard, her left fifth finger assumes a fixed posture (extended metacarpophalangeal joint and flexed

phalangeal joints). Then, her left fourth finger also gradually freezes in the same posture as the fifth finger.

#### Supplementary Materials

The online-only Data Supplement is available with this article at <https://doi.org/10.14802/jmd.18038>.

#### Conflicts of Interest

The authors have no financial conflicts of interest.

#### REFERENCES

1. Stahl CM, Frucht SJ. Focal task specific dystonia: a review and update. *J Neurol* 2017;264:1536-1541.
2. Lee D, Lee JS, Ahn TB. Moving foot dystonia in a seamstress. *Neurol Sci* 2015;36:1495-1496.
3. Albanese A, Bhatia K, Bressman SB, DeLong MR, Fahn S, Fung VS, et al. Phenomenology and classification of dystonia: a consensus update. *Mov Disord* 2013;28:863-873.
4. Altenmüller E, Jabusch HC. Focal dystonia in musicians: phenomenology, pathophysiology and triggering factors. *Eur J Neurol* 2010;17 Suppl 1:31-36.
5. Ham JH, Kim SJ, Song SK, Lyoo CH, Lee PH, Sohn YH, et al. A prognostic factor in focal hand dystonia: typist's cramp cases and literature review. *J Neurol Sci* 2016;371:85-87.
6. Lehericy S, Tijssen MA, Vidailhet M, Kaji R, Meunier S. The anatomical basis of dystonia: current view using neuroimaging. *Mov Disord* 2013;28:944-957.
7. Chen CH, Fremont R, Arteaga-Bracho EE, Khodakhah K. Short latency cerebellar modulation of the basal ganglia. *Nat Neurosci* 2014;17:1767-1775.