

This article is licensed under the Creative Commons Attribution-NonCommercial 4.0 International License (CC BY-NC) (<http://www.karger.com/Services/OpenAccessLicense>). Usage and distribution for commercial purposes requires written permission.

## Case Report

# Refractive Lens Exchange with Multifocal Intraocular Lens for Treatment of Chronic Intermittent Spasm of the Near Reflex

Guy Sallet

Ooginstituut Aalst, Aalst, Belgium

## Keywords

Spasm of the near reflex · Multifocal intraocular lens · Refractive lens exchange

## Abstract

We report the case of an emmetropic 32-year-old female with decreased uncorrected visual acuity and diplopia due to intermittent episodes of spasm of the near reflex. Neurologic, general, and ophthalmic examination could not find an organic cause. Attempts at spontaneous recovery, psychogenic therapy, and cycloplegic therapy were unsuccessful and the symptoms persisted for almost 5 years, leading to psychogenic distress. Final treatment with refractive lens exchange and implantation of a toric trifocal intraocular lens resolved the spasm of the near reflex, resulting in an uncorrected distance and near visual acuity of 20/20.

© 2017 The Author(s)  
Published by S. Karger AG, Basel

## Introduction

Accommodative spasm creating pseudomyopia was first described by von Graefe in 1856 [1]. It can be chronic or intermittent, lasting for years [2], and can induce convergence spasm and miosis with episodes of diplopia. The variable appearance of pseudomyopia, convergent strabismus, and miosis has been characterized as spasm of the near reflex. The characteristics may appear together or separately [3]. Possible organic causes are of neurologic

cerebral origin, attempts to overcome vertical gaze palsy, or endocrine metabolic dysfunctions [4, 5]. Treatment depends on the possible etiology, but often no organic cause can be found [6]. Symptomatic treatment exists in pharmacological cycloplegia [7], with possible persistence of the spasm after cessation of the therapy [8].

Here we describe a case of spasm of the near reflex of unknown etiology which lasted for more than 4 years despite psychogenic therapy and pharmacological cycloplegia for prolonged periods of time.

### Case Report

A 32-year-old female patient was first seen by an ophthalmologist in October 2010 with episodes of binocular diplopia and blurred vision during pregnancy of her second son. At that moment in time, she had a son 4 years of age and a history of 2 miscarriages. Spasm of accommodation due to hormonal changes during the pregnancy was presumed, which was expected to disappear with time. Several months after normal pregnancy and gestation, the symptoms persisted and the patient was seen by a neurologist. MRI of the brain was normal and the patient was referred for further neurological investigation to a university hospital. Thyroid disease and myasthenia gravis were excluded. It was concluded that the intermittent spasm of accommodation was psychogenic, since no organic disease was found.

A complete ophthalmologic examination at the university hospital showed normal results with emmetropia with the fogging method as well as after cycloplegia. Slight nuclear congenital lens opacities could be seen in both eyes with a 20/20 uncorrected visual acuity and normal ocular motility with orthophoria in all gaze directions and normal extraocular muscle function. In case of episodes of accommodative convergence spasm, miosis of the pupil and myopization up to  $-4$  D were noted with subjective refraction and the fogging method, as well as an esotropia, provoking diplopia, lasting seconds to several minutes and recurring several times per hour. Treatment with orthoptic exercises, prismatic glasses, and bifocals was unsatisfactory.

In May 2012, the patient had a third pregnancy, throughout which the symptoms of the spasm of the near reflex persisted. Psychiatric therapy for the debilitating disorder was initiated in August 2012. After her pregnancy, therapy with sertraline was conducted for 1 year (from January 2013 to January 2014), together with topical atropine and bifocals. Although the diplopia and esotropia persisted during the accommodative spasms, her visual comfort was better. Botox injection into both medial muscles was proposed, which, however, could induce reading problems due to convergence insufficiency. She was followed up by several orthoptists, strabismologists, and ophthalmologists from 2012 to 2015.

The patient consulted our practice in July 2015 with the same ophthalmic and clinical complaints, which had persisted for almost 5 years without any obvious improvement. During a spasm of the near reflex, the uncorrected visual acuity was 20/60, improving to 20/20 with  $-3$  D glasses and the fogging method. Cycloplegic refraction was near emmetropia in both eyes. This temporary myopia was diagnosed as an accommodative spasm. The topography showed corneal astigmatism of 1.53 D at the axis of  $83^\circ$ , which was compensated with lenticular astigmatism of 1 D at the axis of  $173^\circ$  (Fig. 1). The patient experienced psychogenic distress due to the discomfort that the spasm caused.

We thoroughly discussed possible therapeutic options with this patient. Injection of botulinum toxin into the medial rectus muscle of each eye is reversible, but it probably would not influence the accommodative spasm and could lead to convergence insufficiency.

Lens exchange might relieve the accommodative spasm, but it might not guarantee the disappearance of diplopia and miosis. Refractive lens exchange with monofocal toric lenses would necessitate the use of reading glasses. Multifocal intraocular lens implants could lead to better near vision without the use of reading glasses. Since there was no existing literature on intraocular lenses as a *treatment* for spasm of the near reflex, the patient was informed that this treatment was not evidence based and no guarantee of the disappearance of diplopia due to convergence could be given. As the spasm of the near reflex had already lasted for years despite long periods on different therapies, she agreed to lens exchange with a trifocal toric intraocular lens. If this would not improve the esotropia and diplopia, injection of botulinum toxin into the medial rectus muscles was still an option.

We expected better distance and near vision with the multifocal intraocular lens, due to the removal of accommodation of the crystalline lens. Bilateral lens exchange with implantation of a toric trifocal intraocular lens (FineVision; PhysiOL, Liège, Belgium) of 21.5 D and a cylinder power of 2.25 D at 87° in both eyes was performed in September 2015, 1 week apart. The surgery was uneventful. Removal of the first lens did improve the symptoms of spasm of the near reflex already, but still episodes of diplopia existed, although less frequent. After surgery on the second eye, the symptoms disappeared immediately, with an uncorrected visual acuity of 20/20 for near and distance vision. The toric multifocal intraocular lens neutralized the corneal astigmatism (Fig. 2). By January 2016, the patient had experienced no episodes of diplopia or blurred vision since the refractive lens exchange with the multifocal intraocular lens. Treatment also improved her quality of life, and led to complete recovery from her debilitating distress.

Unfortunately, 1 year later, convergence spasms resumed, causing episodes of diplopia without blurred vision and normal near and distance vision. Botulinum toxin injection into the medial rectus muscles was unsuccessful.

## Discussion

The etiology of chronic accommodative convergence spasm or spasm of the near reflex is not always understood. Neurologic disease as well as endocrine metabolic dysfunction has to be excluded [4, 5]. In our case, no organic cause was found for the spasm, which was intermittent for years. Psychogenic therapy [6, 9] and pharmacological treatment with cycloplegic eye drops [7] are noninvasive methods which led to successful resolution of accommodative spasm in isolated cases, but they are often temporary and not long lasting or curing the disease [3]. Sertraline is a selective serotonin reuptake inhibitor which is used as an anxiolytic and for emotional distress. A case report of resolution of convergence spasm with the addition of sertraline was presented by Hyun et al. [10]. Miotics, plus lenses, minus lenses, and pupil occluders do not provide an effective and consistent solution to the problem [3]. Our patient was treated for 8 months with cycloplegic eye drops without any obvious success.

Clear lens extraction with monofocal intraocular lens implantation for the treatment of persistent accommodative spasm after head trauma has been described by McMurray et al. [11]. In our case, no episode of head trauma was recognized, and MRI could not show any cerebral lesion. This case was thought to be of psychogenic origin with episodes of diplopia and miosis during accommodative spasm, representing spasm of the near reflex. As pharmacological or psychogenic therapy did not resolve the spasm in our case, we tried to stop the accommodative episodes with removal of the natural lens as described for accommodative

spasm after head trauma [11]. However, no literature was found on resolving episodes of diplopia and miosis by clear lens extraction. As our patient was emmetropic and had an uncorrected visual acuity of 20/20 for distance as well as for near vision, we opted for a multifocal intraocular lens in order to give her as much comfort for distance and near vision as possible. As expected, no episodes of accommodative spasm occurred postoperatively. Also, the convergence spasms, as well as the miosis, disappeared, with no diplopia since the refractive lens exchange. The use of monofocal or monofocal toric lenses could possibly have yielded the same result, but would have left this young patient with the need for reading glasses for near vision.

We presented a case of prolonged intermittent spasm of the near reflex which was resolved with trifocal intraocular lens implantation. This successful treatment allowed our patient to obtain good uncorrected visual acuity for distance and near vision. The diplopia temporarily disappeared, but episodes of convergence spasm resumed 1 year later.

### Statement of Ethics

All procedures were done according to the Helsinki Declaration of 1964, as revised in 2013.

### Disclosure Statement

Guy Sallet is a clinical investigator for Physiol (Belgium).

### References

- 1 Graefe AV: Case description of spasm of accommodation. *Arch Ophthalmol* 1856;2:304–306.
- 2 Bohlmann BJ, France TD: Persistent accommodative spasm nine years after head trauma. *J Clin Neuroophthalmol* 1987;7:129–131.
- 3 Goldstein JH, Schneekloth BB: Spasm of the near reflex: a spectrum of anomalies. *Surv Ophthalmol* 1996;40:269–278.
- 4 Savin LH: Functional spasm of accommodation. *Br J Ophthalmol* 1959;43:3–8.
- 5 Fekete R, Baizabal-Carvallo JF, Ha AD, Davidson A, Jankovic J: Convergence spasm in conversion disorders: prevalence in psychogenic and other movement disorders compared with controls. *J Neurol Neurosurg Psychiatry* 2012;83:202–204.
- 6 Abhishek G, Susanta KP, Gouray G, Manoj KG: Functional convergence spasm. *Indian J Psychol Med* 2014;36:332–334.
- 7 Hussaindeen JR, Mani R, Agarkar S, Ramani KK, Surendran TS: Acute adult onset comitant esotropia associated with accommodative spasm. *Optom Vis Sci* 2014;91(suppl 1):S46–S51.
- 8 Chan RVP, Trobe JD: Spams of accommodation associated with closed head trauma. *J Neuroophthalmol* 2002;22:15–17.
- 9 Schwartz GM, McHenry LC Jr, Proctor RC: Convergence spasm – treatment by Amytal interview. A case report. *J Clin Neuroophthalmol* 1983;3:123–125.
- 10 Hyun HJ, Chung US, Chun BY: Early resolution of convergence spasm following the addition of antipsychotic medications. *Korean J Ophthalmol* 2011;25:66–68.
- 11 McMurray CJ, Burley CD, Elder MJ: Clear lens extraction for the treatment of persistent accommodative spasm after head trauma. *J Cataract Refract Surg* 2004;30:2629–2631.

Sallet: Refractive Lens Exchange with Multifocal Intraocular Lens for Treatment of Chronic Intermittent Spasm of the Near Reflex

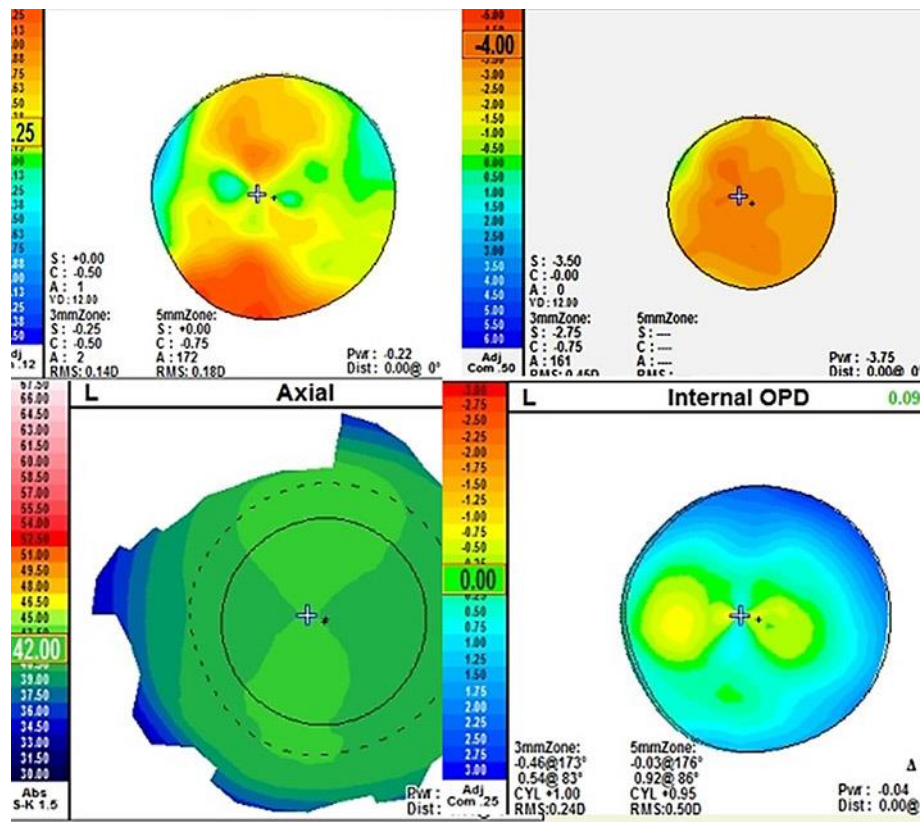
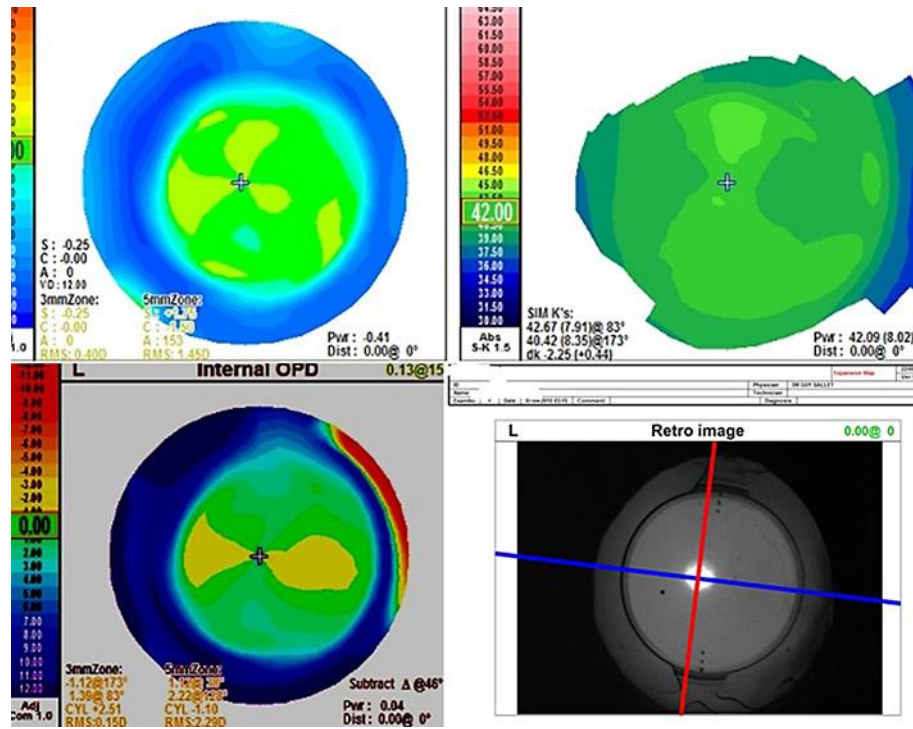


Fig. 1. Preoperative scans showing refraction with cycloplegia (top left) and with accommodative spasm and miosis (top right) as well as corneal with-the-rule astigmatism (bottom left) and lenticular against-the-rule astigmatism (bottom right).



**Fig. 2.** Postoperative scans showing refraction (top left), corneal astigmatism of 2.25 D at 83° (top right), lenticular astigmatism of 2.51 D at 173° (bottom left), and alignment of the intraocular lens at the steep corneal axis (bottom right).