

## Clinical Study

# Is Intra-gastric Botulinum Toxin A Injection Effective in Obesity Treatment?

Bulent Kaya <sup>1</sup>, Nuriye Esen Bulut,<sup>2</sup> and Mahir Fersahoglu<sup>2</sup>

<sup>1</sup>Hisar Intercontinental Hospital, Department of General Surgery, Istanbul, Turkey

<sup>2</sup>Fatih Sultan Mehmet Training and Research Hospital, Department of General Surgery, Istanbul, Turkey

Correspondence should be addressed to Bulent Kaya; drbkaya@yahoo.com

Received 24 June 2020; Revised 31 July 2020; Accepted 1 August 2020; Published 1 October 2020

Academic Editor: Noriyoshi Sawabata

Copyright © 2020 Bulent Kaya et al. This is an open access article distributed under the Creative Commons Attribution License, which permits unrestricted use, distribution, and reproduction in any medium, provided the original work is properly cited.

**Aims.** The objective of this prospective study was to evaluate the efficacy of intra-gastric botulinum toxin A (BTX-A) injection for the treatment of obesity. **Materials and Methods.** The study was performed between January and August 2019. This is a prospective study. After 6–12 hours of fasting, the patients were submitted to upper GI endoscopy under sedation for the injection of BTX-A. A total of 250 U of BTA-X was diluted with 10 ml of 0.9% saline. Injections were administered into the gastric antrum, each containing 1 ml of prepared solution (25 U BX-A + 1 ml saline). Continuous data were compared using a two-sample *t*-test. Statistical significance was determined as  $P \leq 0.05$ . All statistical analysis was performed using SPSS for Windows 22.1 software (SPSS, Chicago, IL, USA). **Results.** A total of 56 patients were studied. Mean weight before gastric Botox was  $85.25 \pm 14.02$ , and mean weight after gastric Botox was  $76.98 \pm 12.68$ . Mean weight loss was approximately 9 kg in studied patients. BMI decreased about 3 units. The mean time for maximum weight loss was  $60.39 \pm 37.43$  days. A total of 49 patients (87.5%) had reported decrease in appetite and early satiety. About 53.6% of patients were satisfied. No complications resulting from the endoscopic procedure were observed in this series. **Conclusions.** Intra-gastric BTX-A injection can be beneficial in weight loss. It is a minimally invasive, cost-effective procedure, without serious side effects.

## 1. Introduction

Obesity has become an epidemic disease in the past years. Genetic, social, psychological, and behavioural factors are important in obesity. It is well known that obesity increases the risk of some disorders including diabetes, arterial hypertension, hyperlipidemia, sleep apnea syndrome, and cerebral stroke [1]. There is no gold standard pharmacological treatment for obesity up to date.

Botulinum neurotoxin, produced by the Gram-positive, anaerobic bacterium *Clostridium botulinum*, has been used widely for many diseases. It was first injected into extra-ocular muscles for treatment of ocular strabismus [2]. It mainly inhibits the muscular contractions of smooth and striated muscles by decreasing acetylcholine release at the neuromuscular junction. It was also shown that botulinum toxin is effective in the treatment of some diseases with hyperactivity of the gastrointestinal smooth muscles such as achalasia and chronic anal fissure [3–5].

After the use of botulinum toxin A (BTX-A) in experimentally obese rat models, endoscopic intra-gastric BTX-A injection has been attempted for the treatment of morbid obesity [6, 7]. The mechanism of action is related to gastric emptying delay and early satiety, resulting in weight loss. There have been few conflicting results about intra-gastric Botox injection including body weight reduction, gastric emptying, induction of early satiety, and weight gain after the procedure. The objective of this prospective study was to evaluate the efficacy of intra-gastric BTX-A injection for the treatment of obesity.

## 2. Materials and Method

This study was performed between January and August 2019. All patients gave informed consent according to ethical committee principles. Inclusion criteria included age between 18 and 65 years and body mass index (BMI)  $\geq 25$  kg/m<sup>2</sup>. Patients who were pregnant and lactating and had

myopathy or neuromuscular disorder, hypersensitivity to BTX-A, cardiovascular disease, and peptic ulcer disease detected in endoscopy were excluded. Body weight and height were measured, and BMI was found out before the procedure (body weight (kg)/height (m<sup>2</sup>)). Body weight and BMI were measured monthly until the end of the study (5 months).

**2.1. Procedure.** After 6–12 hours of fasting, the patients were submitted to upper GI endoscopy under sedation for the injection of BTX-A. A total of 250 units of BTX-A was diluted with 10 ml of 0.9% saline. Injections were administered into the gastric antrum, each containing 1 ml of prepared solution (25 U BTX-A + 1 ml saline). Technically, the antral region of the stomach was punctured, and BTX-A was injected into the gastric wall slowly, using a standard 5 mm sclerotherapy needle in a circular direction. Usually, 8–10 injections were given with routine three punctures in the posterior gastric wall, three punctures in the anterior gastric wall, two punctures in the lesser curvature, and two punctures in the greater curvature.

There were no significant acute complications during the procedures except a minor bleeding that stopped without any intervention. All patients were observed for 4 h after the procedure. Only one patient complaining of abdominal pain and vomiting was observed for 12 h. All patients were suggested to visit a dietitian immediately after the endoscopic procedure.

**2.2. Diet and Follow-Up.** The patients were suggested to take the pure liquid diet within 72 hours after the procedure. All patients were consulted by the dietitian. At the end of 3 days, a 1200 kcal (protein 30%, carbohydrate 30%, and lipid 40%) was given. The patients were offered to follow the diet for 6–9 months and controlled by the dietitian every 3 weeks.

All patients were invited for control at the end of the first and fifth months.

**2.3. Statistical Analysis.** We performed descriptive analyses of all of the study variables. Quantitative variables are expressed as means, with minimum and maximum values, or as means with standard deviations as appropriate. Continuous data were compared using Student's *t*-test. Statistical significance was determined as  $P \leq 0.05$ . All statistical analysis was performed using SPSS for Windows 22.1 software (SPSS, Chicago, IL, USA).

### 3. Results

A total of 56 patients were studied. There were 50 (89.3%) females and 6 (10.7%) males. The mean age was  $38.97 \pm 9.90$  (22–61 years). The demographic findings of all patients are shown in Table 1. Mean weight before intragastric Botox was  $85.25 \pm 14.02$ , and mean weight after intragastric Botox was  $76.98 \pm 12.68$ . Mean weight loss was approximately 9 kg in studied patients. BMI decreased about 3 units. The mean time for maximum weight loss was  $60.39 \pm 37.43$  days

(Table 2). Appetite and early satiety were questioned. A total of 49 patients (87.5%) had reported a decrease in appetite and early satiety (Table 3). Dietary practices are shown in Figure 1. The patient satisfaction was measured with scoring (4: satisfied; 3: good; 2: fair; 1: poor). About 53.6% of patients were satisfied (Figure 2). No complications resulting from the endoscopic procedure were observed in this series.

### 4. Discussion

BTX-A has already been used for decades in both esthetic and therapeutic procedures [8–11]. The neuromuscular blockade caused by BTX-A provokes the thesis that this agent can be applied to the gastric wall, resulting in the feeling of bloating, delayed gastric emptying, early satiety, and weight loss. The main advantage of using the intragastric injection of BTX-A would be the absence of serious adverse events related to the procedure [12, 13].

Previous studies evaluating intragastric injection of BTX-A as a treatment for obesity have been associated with conflicting results. Rollnik et al. published the first report of the use of BTX-A for the treatment of obesity [14]. Total body weight loss was 8.9% (9 kg) of the initial body weight. In an experimental study, Gui et al. showed that the intraparietal administration of BTX-A into the gastric antrum causes a significant reduction of food intake and decrease of body weight [6]. Albani et al. applied 500 IU of BTX-A to 8 patients in a small series and found a total weight loss of approximately 4 kg at 1-month follow-up [15]. On the other hand, there are studies showing that intragastric Botox treatment is ineffective in weight loss. Bustamante et al. designed a meta-analysis with four randomized clinical trials [12]. They concluded that homogeneous randomized controlled studies did not find superiority of BTX-A versus placebo [6, 16, 17]. de Moura et al. also studied the effect of BTX-A in super-obese patients. They concluded that intragastric injection of BTX-A does not seem to be an effective method in achieving preoperative weight loss in these patients [18].

As far as we know, our study is one of the largest series published in the literature about the intragastric Botox injection. A total of 56 patients were studied prospectively. If we list the important results of the study, the weight loss after procedure was found to be approximately 9 kg. This finding is similar to the study results of Rollnik et al. This weight loss amount may suggest that intragastric Botox application will be more suitable especially for class 1 patients.

Diet is one of the important issues in the treatment of obesity. In our study, a low-calorie diet was recommended to all patients after the procedure. One of the interesting results of the study was that there was no statistical difference in terms of weight loss in patients who were on a diet or not ( $P > 0.05$ ).

One of the most curious topics in this study was the effect of Botox on appetite. After the intragastric Botox procedure, 47 of 56 patients stated that their appetite decreased. The importance of decreased appetite in weight loss is well known. After sleeve gastrectomy, which is an important bariatric surgery method, ghrelin hormone level and

TABLE 1: Demographic findings of patients.

Finding	Mean $\pm$ SD	Number
Age	38.97 $\pm$ 9.90	56
Gender		6 male/50 female (10.7%–89.3%)
Obesity in family		19 patients (33.9%)
Psychiatric problems		5 patients (8.9%)
Comorbidities		
Diabetes mellitus		6 patients (10.7%)
Hypertension		4 patients (7.1%)
Hypothyroid		2 patients (3.5%)
Polycystic ovary syndrome		1 patient (1.7%)

TABLE 2: Average weight and BMI loss.

	Mean $\pm$ SD	Min–max
Weight before gastric Botox	85.25 $\pm$ 14.02	61–123 kg
Weight after gastric Botox	76.98 $\pm$ 12.68	54–123 kg
Average time for weight loss	60.39 $\pm$ 37.43	7–150 days
BMI before gastric Botox	30.79 $\pm$ 4.25	25–43.6
BMI after gastric Botox	27.95 $\pm$ 3.76	38.3–20.6

TABLE 3: Effect of gastric Botox on appetite of patients.

	Number of patients	Appetite
Appetite before gastric Botox	33	High
	13	Normal
Appetite after gastric Botox	49	Decreased
	7	Not changed

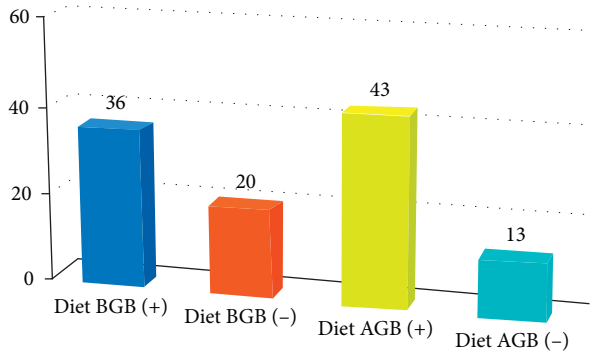


FIGURE 1: Dietary practice before gastric Botox (BGB) and after gastric Botox (AGB).

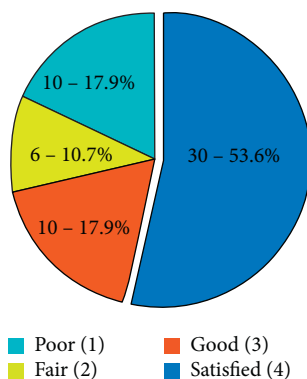


FIGURE 2: Patient satisfaction scores and percentages.

appetite decrease. Gastric antral contractility is an important component of normal gastric motility. Reduced antral motility appears to prolong gastric emptying. Intragastric BTX-A injection inhibits contractility of the gastric muscle. So we also injected BTX-A into the antral region of the stomach.

More than half of the patients reported a high satisfaction score after the intragastric Botox procedure. It is also important that no serious complications are seen during or after procedures.

In this study, it was observed that intragastric Botox administration with diet showed a clear effect on appetite and provided an average weight loss of 9 kg. But there have been patients in the series who had no weight loss and no decreased appetite. Diet can also be a confusing factor when investigating the effectiveness of Botox in weight loss. These results indicate that larger randomized prospective studies are needed to demonstrate the effectiveness of intragastric Botox.

In conclusion, it is shown that the intragastric BTX-A injection can be beneficial in weight loss. It is a minimally invasive, cost-effective procedure, without serious side effects. This study has some limitations.

## Data Availability

All prospective data used to support the findings of this study are included within the article and are available from the corresponding author upon request.

## Conflicts of Interest

The authors declare that they have no conflicts of interest.

## References

- [1] A. H. Mokdad, M. K. Serdula, W. H. Dietz, B. A. Bowman, and J. S. Marks, "The spread of the obesity epidemic in the United States, 1991–1998," *Journal of the American Medical Association*, vol. 282, no. 16, pp. 1519–1522, 1999.
- [2] A. B. Scott, "Botulinum toxin injection into extraocular muscles as an alternative to strabismus surgery," *Journal of Pediatric Ophthalmology and Strabismus*, vol. 17, no. 1, pp. 21–25, 1980.
- [3] P. J. Parischa, W. J. Ravich, T. R. Hendrix, S. Sostre, B. Jones, and A. N. Kalloo, "Intrasphincteric botulinum toxin for treatment of achalasia," *The New England Journal of Medicine*, vol. 332, no. 12, pp. 774–816, 1995.

- [4] M. Asim, N. Lowrie, J. Stewart, S. Lolohea, and R. Van Dalen, "Botulinum toxin versus botulinum toxin with low-dose glyceryl trinitrate for healing of chronic anal fissure: a prospective, randomised trial," *The New Zealand Medical Journal*, vol. 127, no. 1393, pp. 80–86, 2014.
- [5] B. E. Lacy, E. N. Zayat, M. D. Crowell, and M. M. Schuster, "Botulinum toxin for the treatment of gastroparesis: a preliminary report," *The American Journal of Gastroenterology*, vol. 97, no. 6, pp. 1548–1552, 2002.
- [6] D. Gui, A. De Gaetano, P. L. Spada, A. Viggiano, E. Cassetta, and A. Albanese, "Botulinum toxin injected in the gastric wall reduces body weight and food intake in rats," *Alimentary Pharmacology and Therapeutics*, vol. 14, no. 6, pp. 829–834, 2000.
- [7] H. Coskun, Y. Duran, E. Dilege, M. Mihmanli, H. Seymen, and M. O. Demirkol, "Effect on gastric emptying and weight reduction of botulinum toxin-A injection into the gastric antral layer: an experimental study in the obese rat model," *Obesity Surgery*, vol. 15, no. 8, pp. 1137–1143, 2005.
- [8] A. Priori, A. Berardelli, B. Mercuri, and M. Manfredi, "Physiological effects produced by botulinum toxin: changes in reciprocal inhibition between forearm muscles," *Brain*, vol. 118, no. 3, pp. 801–807, 1995.
- [9] J. O. Dolly, "Therapeutic and research exploitation of botulinum neurotoxins," *European Journal of Neurology*, vol. 4, pp. S5–S10, 1997.
- [10] O. Vergara-Fernández, N. Salgado-Nesme, A. Navarro-Navarro, and H. A. Rangel-Ríos, "Meta-analysis of botulinum toxin injection for chronic anal fissure: healing rates controversies," *Techniques in Coloproctology*, vol. 21, p. 169, 2017.
- [11] N. Pehlivanov and P. J. Pasricha, "Achalasia: botox, dilatation or laparoscopic surgery in 2006," *Neurogastroenterology and Motility*, vol. 18, no. 9, pp. 799–804, 2006.
- [12] F. Bustamante, V. O. Brunaldi, W. M. Bernardo et al., "Obesity treatment with botulinum toxin-A is not effective: a systematic review and meta-analysis," *Obesity Surgery*, vol. 27, no. 10, pp. 2716–2723, 2017.
- [13] H. Elshakh, K. El-Ejji, and S. Taheri, "The role of endoscopic intra-gastric botulinum toxin-A for obesity treatment," *Obesity Surgery*, vol. 27, no. 9, pp. 2471–2478, 2017.
- [14] J. D. Rollnik, P. N. Meier, M. P. Manns, and M. Göke, "Antral injections of botulinum A toxin for the treatment of obesity," *Annals of Internal Medicine*, vol. 138, no. 4, pp. 359–360, 2003.
- [15] G. Albani, M. L. Petroni, A. Mauro et al., "Safety and efficacy of therapy with botulinum toxin in obesity: a pilot study," *Journal of Gastroenterology*, vol. 40, no. 8, pp. 833–835, 2005.
- [16] M. Topazian, M. Camilleri, J. De La Mora-Levy et al., "Endoscopic ultrasound-guided gastric botulinum toxin injections in obese subjects: a pilot study," *Obesity Surgery*, vol. 18, no. 4, pp. 401–407, 2008.
- [17] R. Mittermair, C. Keller, and J. Geibel, "Intragastric injection of botulinum toxin A for the treatment of obesity," *Obesity Surgery*, vol. 17, no. 6, pp. 732–736, 2007.
- [18] E. G. H. De Moura, I. B. Ribeiro, M. S. V. Frazão et al., "EUS-Guided intragastric injection of botulinum toxin A in the preoperative treatment of super-obese patients: a randomized clinical trial," *Obesity Surgery*, vol. 29, no. 1, pp. 32–39, 2019.