



Since January 2020 Elsevier has created a COVID-19 resource centre with free information in English and Mandarin on the novel coronavirus COVID-19. The COVID-19 resource centre is hosted on Elsevier Connect, the company's public news and information website.

Elsevier hereby grants permission to make all its COVID-19-related research that is available on the COVID-19 resource centre - including this research content - immediately available in PubMed Central and other publicly funded repositories, such as the WHO COVID database with rights for unrestricted research re-use and analyses in any form or by any means with acknowledgement of the original source. These permissions are granted for free by Elsevier for as long as the COVID-19 resource centre remains active.



# Vaccine Breakthrough Severe COVID-19 in a Lung Recipient

Muhammet Ali Beyoglu<sup>a\*</sup>, Mehmet Furkan Sahin<sup>a</sup>, Sinan Turkkan<sup>a</sup>, Fatmanur Celik Basaran<sup>a</sup>, Alkin Yazicioglu<sup>a</sup>, Serife Gokbulut Bektas<sup>b</sup>, Yasemin Tezer Tekce<sup>c</sup>, and Erdal Yekeler<sup>a</sup>

<sup>a</sup>Department of General Thoracic Surgery and Lung Transplantation, Ankara City Hospital, University of Health Sciences, Ankara, Turkey; <sup>b</sup>Department of Intensive Care Unit, Ankara City Hospital, University of Health Sciences, Ankara, Turkey; and <sup>c</sup>Clinic of Infectious Disease, Ankara City Hospital, University of Health Sciences, Ankara, Turkey

## ABSTRACT

The vaccines developed against severe acute respiratory syndrome coronavirus 2 are seen as the most crucial weapon in controlling the epidemic. It has been reported in early-stage vaccine studies that vaccines provide up to 95% protection against severe disease and mortality, even in the absence of symptomatic infection. Reports on vaccine breakthrough infections that developed after widespread vaccination are available in the literature. In addition to the general population, the course of vaccine breakthrough infections in immunocompromised patients is a matter of concern. This case report aimed to define severe coronavirus disease 2019 developing in a lung recipient who received 3 doses of inactivated virus vaccine.

**A**LTHOUGH almost 2 years have passed since the first case was detected and despite ongoing social isolation measures and the widespread use of vaccines, the coronavirus disease 2019 (COVID-19) pandemic continues to cause morbidity and mortality worldwide. Re-infections and vaccine breakthrough infections are reported with a frequency that cannot be called sporadic. Immunocompromised patients are given priority in vaccination programs in our country, as in the rest of the world. The actual rate and prognosis of vaccine breakthrough infections in this patient group is a matter of curiosity. Lung recipients constitute a unique group among immunocompromised patients. Both the intensive use of immunosuppressants and the fact that the main target of the pandemic agent is allograft create concerns about the course of COVID-19 in lung recipients [1]. There are few reports in the literature on vaccine breakthrough infections in lung recipients. The present report aims to define a severe case of COVID-19 in a lung recipient vaccinated with 3 doses of Sinovac (Sinovac Life Sciences, Beijing, China), one of the vaccines approved for emergency use by the World Health Organization.

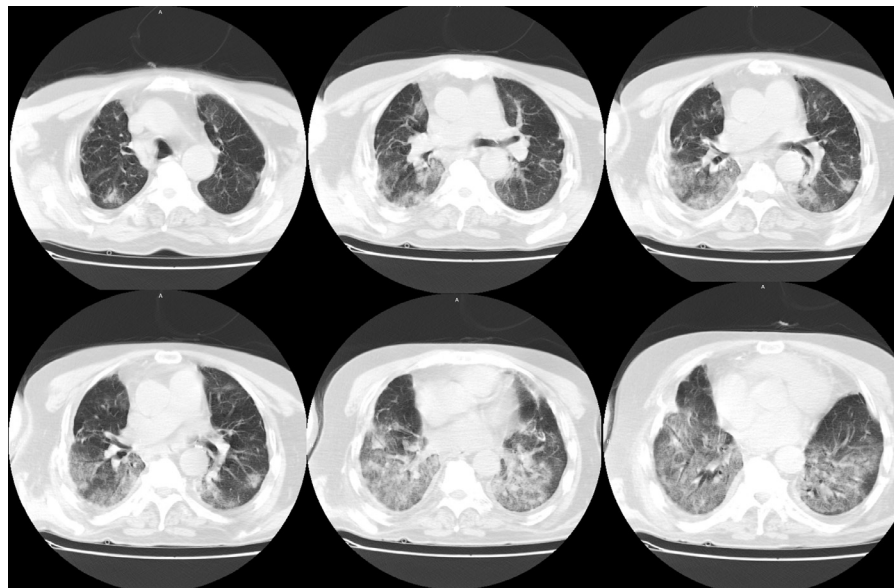
## CASE

A 62-year-old male patient who had a double lung transplant 42 months ago because of idiopathic pulmonary fibrosis was vaccinated with 2 doses of Sinovac in January 2021. In his routine tests 2 months later, severe acute respiratory syndrome coronavirus 2 (SARS-CoV-2) spike protein-specific immunoglobulin

(IgG and IgM) was found to be low positive in the serum. The patient was vaccinated with a third dose of Sinovac in July. Seven weeks after the third dose of Sinovac, the patient, who developed shivering and fever, went to the emergency department. The patient's oxygen saturation was measured as 96 in room air, with a temperature of 36.2°C, pulse rate of 80/min, and respiratory rate of 14/min. Chest x-ray was evaluated as normal, and a SARS-CoV-2 reverse transcription polymerase chain reaction test from a nasopharyngeal swab was positive. The patient had moderate symptoms and was followed up on an outpatient basis. Mycophenolate mofetil treatment was interrupted, and favipiravir (2 × 1600 mg loading on the first day, 2 × 600 mg on the next 4 days) and paracetamol were prescribed. The patient, who developed dyspnea on the third day after diagnosis, again went to the emergency department. Oxygen saturation was 92 in room air, heart rate was 96/min, and respiratory rate was 18/min. The patient was transferred to our center with the current findings. Respiratory examination revealed bilateral wheezing. Throat, tracheal aspirate, and blood and urine cultures were taken. Cytomegalovirus and *Aspergillus*

Informed consent was obtained from the relatives of the patients.

\*Address correspondence to Muhammet Ali Beyoglu, MD, Department of General Thoracic Surgery and Lung Transplantation, Ankara City Hospital, University of Health Sciences, MH2 binas., B1 kat., E2 bolumu, Universiteler Mahallesi 1604. Cadde No: 9 Çankaya, Ankara, Turkey. E-mail: [muhammetlibeyoglu@gmail.com](mailto:muhammetlibeyoglu@gmail.com)



**Fig 1.** Subsegmental atelectasis and bilateral multifocal ground-glass areas are seen on thorax computed tomography, which was examined 3 days after the severe acute respiratory syndrome coronavirus 2 diagnosis.

DNA polymerase chain reaction and galactomannan antigen tests from tracheal aspirate and serum samples were negative. Subsegmental atelectasis and bilateral multifocal ground-glass areas predominantly located peripherally were detected on thorax computed tomography (Fig 1). Nasal oxygen at 4 L/min, empirical antibiotics (meropenem  $2 \times 1000$  mg), ascorbic acid ( $2 \times 500$  mg), enoxaparin sodium ( $2 \times 40$  mg), and methylprednisolone (1 mg/kg-day) were started. The patient was hospitalized and followed up in the COVID-19 service. There was no growth in the throat, tracheal aspirate, or blood and urine cultures. High-flow oxygen therapy was started on the third day of hospitalization because the patient's respiratory failure gradually increased. Pulse steroid therapy ( $3 \times 1000$  mg/day methylprednisolone, gradually reduced to maintenance dose) was planned. Voriconazole ( $2 \times 200$  mg), amphotericin-B ( $3 \times 10$  mg with a nebulizer), and ganciclovir ( $2 \times 200$  mg) were started empirically. Because respiratory failure could not be managed despite high-flow oxygen therapy, invasive mechanical ventilation was applied. The patient died on the 19th day of hospitalization of multiorgan failure and septic shock. Delta variant was detected in the naso-oro-pharyngeal swab sample.

## DISCUSSION

Widespread use of effective and safe vaccines is a crucial factor in ending the COVID-19 pandemic. The World Health Organization has given emergency use approval to various SARS-CoV-2 vaccines [2]. Satisfactory results were reported in the first phase 3 studies of Sinovac, one of the vaccines approved for emergency use. The Sinovac vaccine was reported to be 51% to 65% protective against symptomatic SARS-CoV-2 infection and 90% to 100% protective against severe illness and hospitalization in the immunocompetent population [2,3]. Although early results show that vaccines protect against especially severe diseases, severe COVID-19 disease and deaths

have started to be seen despite vaccines. A phase 3 study conducted with the Sinovac vaccine in Chile reported that the vaccine was 85% protective against hospitalization due to COVID-19 and 80% protective against COVID-19-related death [2].

One of the important causes of vaccine breakthrough infections is the low neutralizing antibodies after vaccination. The vaccine response is expected to be low, especially in the elderly population and immunosuppressed patients [4]. However, the literature has also reported that vaccine breakthrough SARS-CoV-2 infection is seen despite high neutralizing antibodies [5]. Immune escape mutations in the spike protein of SARS-CoV-2 are highly likely to cause re-infection and vaccine breakthrough infections. Currently, the World Health Organization describes 4 variants as variants of concern, labeled alpha, beta, gamma, and delta [6]. Vaccine breakthrough infections seen in the community with SARS-CoV-2 variants that are more contagious, cause more severe disease, and have decreased neutralization with antibodies due to previous disease or vaccination are reported with a frequency that cannot be called sporadic. High mortality rates ranging from 14% to 34% have been reported in studies on COVID-19 in lung recipients, though there are few in the literature [7–9]. The success of promising treatments such as convalescent plasma, tocilizumab, and anakinra in the early stages of the pandemic has not been demonstrated in randomized controlled trials [10–13]. The lack of an effective treatment regimen raises concerns about vaccine efficacy and infections with mutant SARS-CoV-2 variants in lung recipients, as in other immunosuppressed patients [14]. Due to immunosuppressants, the antibody response may be low, and the risk of vaccine breakthrough infection is higher in these patients than in the general population.

In its consensus document published on August 13, 2021, International Society of Heart and Lung Transplantation recommended administering a third dose of COVID-19 vaccine to patients undergoing thoracic organ transplantation, regardless of neutralizing antibody level [15]. In our country, only inactivated

virus vaccine has been available since the last months of 2020. Therefore, 2 doses of inactivated virus vaccine were administered to lung recipients. Although mRNA vaccines were also provided and recommended to lung recipients, some preferred the inactivated virus vaccine for the third dose. This case is unique in that 3 doses of inactivated virus vaccine were administered. To the best of our knowledge, this is the first case reported in the English literature of a vaccine breakthrough infection in a lung recipient after 3 doses of inactive virus vaccine.

Thus, the efficacy of inactivated SARS-CoV-2 vaccines in lung recipients may be far below expectations. Although the SARS-CoV-2 infection that develops in these patients starts with mild symptoms, it can progress rapidly. Even if the inactivated SARS-CoV-2 vaccine is fully administered in lung recipients, isolation measures should not be compromised.

## REFERENCES

- [1] Turkkan S, Beyoglu MA, Sahin MF, et al. COVID-19 in a lung transplant patient: rapid progressive chronic lung allograft dysfunction [e-pub ahead of print] *Exp Clin Transplant* 2021 accessed April 29, 2021. doi: [10.6002/ect.2020.0563](https://doi.org/10.6002/ect.2020.0563).
- [2] <[https://www.who.int/publications/i/item/WHO-2019-nCoV-vaccinesSAGE\\_recommendation-Sinovac-CoronaVac-2021.1](https://www.who.int/publications/i/item/WHO-2019-nCoV-vaccinesSAGE_recommendation-Sinovac-CoronaVac-2021.1)>; [accessed 12.10.21].
- [3] Hitchings MDT, Ranzani OT, Torres MSS, de Oliveira SB, Almiron M, Said R, et al. Effectiveness of CoronaVac in the setting of high SARS-CoV-2 P.1 variant transmission in Brazil: a test-negative case-control study. *MedRxiv*. 2021 <<https://www.medrxiv.org/content/10.1101/2021.04.07.21255081v1>>; [accessed 26.04.21].
- [4] Goronzy JJ, Weyand CM. Understanding immunosenescence to improve responses to vaccines. *Nat Immunol* 2013;14:428–36.
- [5] Schulte B, Marx B, Korenack M, et al. Case report: infection with SARS-CoV-2 in the presence of high levels of vaccine-induced neutralizing antibody responses. *Front Med (Lausanne)* 2021;8:704719.
- [6] <<https://www.who.int/en/activities/tracking-SARS-CoV-2-variants/>>; [accessed 12.10.21].
- [7] Messika J, Eloy P, Roux A, et al. COVID-19 in lung transplant recipients. *Transplantation* 2021;105:177–86.
- [8] Kates OS, Haydel BM, Florman SS, et al. COVID-19 in solid organ transplant: a multi-center cohort study [e-pub ahead of print] *Clin Infect Dis* 2020 accessed August 7, 2020. doi: [10.1093/cid/ciaa1097](https://doi.org/10.1093/cid/ciaa1097).
- [9] Aversa M, Benvenuto L, Anderson M, et al. COVID-19 in lung transplant recipients: a single center case series from New York City. *Am J Transplant* 2020;20:3072–80.
- [10] Balcells ME, Rojas L, Le Corre N, et al. Early versus deferred anti-SARS-CoV-2 convalescent plasma in patients admitted for COVID-19: a randomized phase II clinical trial. *PLoS Med* 2021;18:e1003415.
- [11] Mehta M, Purpura LJ, McConville TH, et al. What about tocilizumab? A retrospective study from a NYC hospital during the COVID-19 outbreak. *PLoS One* 2021;16:e0249349.
- [12] Rosas IO, Bräu N, Waters M, et al. Tocilizumab in hospitalized patients with severe COVID-19 pneumonia. *N Engl J Med* 2021;384:1503–16.
- [13] CORIMUNO-19 Collaborative Group. Effect of anakinra versus usual care in adults in hospital with COVID-19 and mild-to-moderate pneumonia (CORIMUNO-ANA-1): a randomised controlled trial. *Lancet Respir Med* 2021;9:295–304.
- [14] Turkkan S, Beyoglu MA, Sahin MF, Yazicioglu A, Tezer Tekce Y, Yekeler E. COVID-19 in lung transplant recipients: a single-center experience [e-pub ahead of print] *Transpl Infect Dis* 2021: e13700. accessed July 29, 2021. doi: [10.1111/tid.13700](https://doi.org/10.1111/tid.13700).
- [15] <[https://ishlt.org/ishlt/media/documents/ISHLT-AST\\_SARS-CoV-2-Vaccination\\_8-13-21.pdf](https://ishlt.org/ishlt/media/documents/ISHLT-AST_SARS-CoV-2-Vaccination_8-13-21.pdf)>; [accessed 12.10.21].