

# Optical coherence tomography angiography in unilateral multifocal choroiditis and panuveitis

## A case report

Lung-Chi Lee, MD<sup>a</sup>, Ke-Hao Huang, MD<sup>a,b</sup>, Yi-Hao Chen, MD, PhD<sup>a</sup>, Hsin-Ting Lin, MD<sup>a</sup>, Chia-Chen Hsu, MD<sup>a</sup>, Ming-Cheng Tai, MD<sup>a</sup>, Chang-Min Liang, MD, PhD<sup>a</sup>, Jiann-Torng Chen, MD, PhD<sup>a</sup>, Ching-Long Chen, MD, PhD<sup>a,\*</sup>

### Abstract

**Rationale:** Optical coherence tomography angiography (OCT-A) has the advantage to visualize the microvascular structure of the retina in vivo and was utilized clinically in various neovascular retinal diseases. The OCT-A has also been used to examine the lesion in multifocal choroiditis and panuveitis (MCP). This study aimed to describe a case of MCP and present the disease process of a punched-out lesion in the chorioretina with neovascular activity using OCT-A.

**Patients concerns:** A 32-year-old female Caucasian patient presented with a 2-week history of progressive blurred vision in her right eye with photophobia and a diminished temporal visual field. On presentation, her best corrected visual acuity was 6/60 in the right eye with a prominent anterior uveitis seen under slit lamp examination.

**Diagnoses:** Dilated fundus examination of the right eye showed vitritis and multiple, punched-out yellowish-white lesions over the peripheral retina. Additional multimodal imaging (MMI) were done including fluorescein angiography (FA), indocyanine green angiography (ICGA) and fundus autofluorescence (FAF), which all revealed characteristic findings of MCP. In general, the diagnosis of unilateral MCP was made. Furthermore, one of the punched-out lesions in the right eye was particularly selected and examined under OCT and OCT-A, which revealed a subretinal elevated lesion with high flow signal under OCT-A.

**Interventions:** Treatment with oral prednisolone at 30 mg daily with topical prednisolone acetate 1% every 2 hours were prescribed, which were gradually tapered down within a 2-month course.

**Outcomes:** The patient's best corrected visual acuity of the right eye returned to 6/6 at 2 months after the diagnosis. The flow signal in the OCT-A study of the punched-out lesion had also resolved after steroid treatment.

**Lessons:** The MCP is an uncommon uveitis with multiple inflammatory chorioretinal lesions. Using multimodal imaging technique, physicians can better differentiate these lesions for diagnosis and for further monitoring. Our results demonstrated that these chorioretinal lesions in MCP may display neovascular activities that might not be seen easily using conventional FA or ICGA study. With OCT-A, ophthalmologists could identify and monitor subtle choroidal neovascularization (CNV) changes over these punched-out lesions.

**Abbreviations:** AMD = age-related macular degeneration, CME = cystoid macular edema, CNV = choroidal neovascularization, ERM = epiretinal membrane, FA = fluorescein angiography, FAF = autofluorescence, ICGA = indocyanine green angiography, IS/OS = inner segment/outer segment, MCP = multifocal choroiditis and panuveitis, MMI = multimodal imaging, OCT = optical coherence tomography, OCT-A = optical coherence tomography angiography, RPE = retinal pigment epithelium, SD-OCT = spectral domain optical coherent tomography.

**Keywords:** idiopathic multifocal choroiditis, multifocal choroiditis and panuveitis, optical coherence tomography angiography

Editor: N/A.

Source of funding: This research was supported in part by Grant ATSGH-C107-204 from the Tri-Service General Hospital, and Grant MOST- 106-2314-B-016 -022, MOST-107-2314-B-016 -031 -MY3, and MOST- 107-2314-B-016 -030 from Ministry of Science and Technology.

The authors have no conflicts of interest to disclose.

<sup>a</sup> Department of Ophthalmology, Tri-Service General Hospital, National Defense Medical Center, <sup>b</sup> Department of Ophthalmology, Songshan Branch of Tri-Service General Hospital, National Defense Medical Center, Taipei, Taiwan.

\* Correspondence: Ching-Long Chen, Department of Ophthalmology, Tri-Service General Hospital, National Defense Medical Center, Taipei 114, Taiwan (e-mail: doc30881@mail.ndmctsgh.edu.tw).

Copyright © 2019 the Author(s). Published by Wolters Kluwer Health, Inc.

This is an open access article distributed under the terms of the Creative Commons Attribution-Non Commercial-No Derivatives License 4.0 (CCBY-NC-ND), where it is permissible to download and share the work provided it is properly cited. The work cannot be changed in any way or used commercially without permission from the journal.

Medicine (2019) 98:4(e14259)

Received: 19 September 2018 / Received in final form: 26 December 2018 / Accepted: 1 January 2019

<http://dx.doi.org/10.1097/MD.00000000000014259>

## 1. Introduction

Multifocal choroiditis and panuveitis (MCP), a subset of white dot syndromes, is a disorder characterized by white-yellowish fundus lesion with intraocular inflammation, which is categorized under the disease spectrum of idiopathic multifocal choroiditis.<sup>[1,2]</sup> The MCP, usually presented with bilateral involvement of the posterior segment, predominantly affects healthy young myopic female between ages 20 to 60 years.<sup>[2]</sup> Patients usually have temporal scotoma, floaters, photopsia, and decreased vision. The affected eye shows various degree of anterior uveitis and vitritis. The characteristic fundus lesions are multiple white chorioretinal lesions in the posterior pole or peripheral retina with varied sizes. They eventually evolve into pigmentary punched-out lesions. In active disease, MCP is associated with hyperemic disc, vasculitis, epiretinal membrane (ERM), and cystoid macular edema (CME).<sup>[1–4]</sup> Occasionally, choroidal neovascularization (CNV) may develop, resulting in severe visual loss in over 33% of patients.<sup>[5]</sup> The MCP is typically treated with systemic corticosteroid therapy for inflammation control.<sup>[3]</sup> The differential diagnosis of MCP from other chorioretinopathies is made by 1st excluding any possible infectious entities. Clinical and morphological examinations are conducted using multi-modal imaging (MMI), including fluorescein angiography (FAG), indocyanine green angiography (ICGA), fundus autofluorescence (FAF), ultra-widefield retinal imaging, and optical coherence tomography (OCT).<sup>[4]</sup>

In the recent expansion of the MMI arsenal, OCT angiography (OCT-A) is a novel, non-invasive, non-dye imaging technique developed to detect angiographic view of the retina and choroid blood flow.<sup>[6]</sup> This high-resolution image of the capillary microstructure provides 3-dimensional flow information in a fixed time point. This OCT-A flow information offers additional structural detail compared to the traditional FA/ICGA images. Commercialized OCT-A has since been widely used in several studies to detect different retinal pathologies, such as age-related macular degeneration (AMD), diabetic retinopathy, central serous chorioretinopathy and retinal arterial or venous occlusions, especially with the presence of CNV in these disease.<sup>[7,8]</sup>

In this study, we examined a case of unilateral MCP and monitored the disease process using MMI, including OCT-A. This new modality has also been used in numerous studies to describe active lesion and to differentiate CNV changes in MCP.<sup>[9–12]</sup> Furthermore, we focused on a punched-out lesion and demonstrated changes in images obtained by OCT-A before and after steroid treatment.

## 2. Case report

A 32-year-old Caucasian woman presented to our department for progressive blurry vision in her right eye with photophobia and a diminished area in the temporal visual field for 2 weeks. There was no known history of systemic disease, major surgery or recent medication use also there was no noticeable flu-like symptoms during the previous 3 months. Her initial best corrected visual acuity was 6/60 in the right eye and 6/6 in the left eye with myopia. The intraocular pressure was normal. The anterior segment examination of the right eye revealed prominent cells and flares in the anterior chamber with mild congestion of the conjunctiva. Indirect ophthalmoscopy revealed multiple white-dot lesions in the mid-periphery retina, especially focused in the nasal quadrant with some scattered pigmented lesion (Fig. 1A). The macula was uninvolved, but the optic disc was hyperemic and swollen. Mild vitritis was also observed. The

fundus examination of the left eye was unremarkable. The patient was then admitted to our ward with a tentative clinical diagnosis of MCP for further survey and management.

A systemic survey was conducted to exclude infectious entities and possible specific inflammatory etiologies. Chest and sacroiliac X-ray imaging, to exclude pulmonary tuberculosis, sacrodermatitis, and ankylosing spondylitis, revealed normal results. Routine blood analysis, including a full blood count, C-reactive protein, electrolytes, liver, and renal profile were normal. Specific autoimmune markers for rheumatology screening were negative. Serologic tests for infectious entities were negative, exclude all possible systemic infections.

Fluorescein angiography (FA) revealed an early blockage with late staining in the area of the white and pigmented dot lesions shown in the fundus examination (Fig. 1B). The optic disc also showed late staining compatible with the swelling hyperemic fundus appearance. The ICGA showed numerous hypocyane-scent lesions larger in area and number compared to the fundus examination and FA (Fig. 1C). The FAF image, captured using ultra-widefield retinal imaging, showed speckled hyper-autofluorescent pattern in the macula area, and a clustered, hypo-autofluorescent lesion at the mid-periphery retina with hyper-autofluorescence surrounding few of these clustered lesions (Fig. 1D). One of these white-dot lesions with a hyper-autofluorescent ring (yellow circle in all figures) at the nasal retina was singled-out and examined using spectral domain optical coherence tomography (SD-OCT) and OCT-A for follow up purpose.

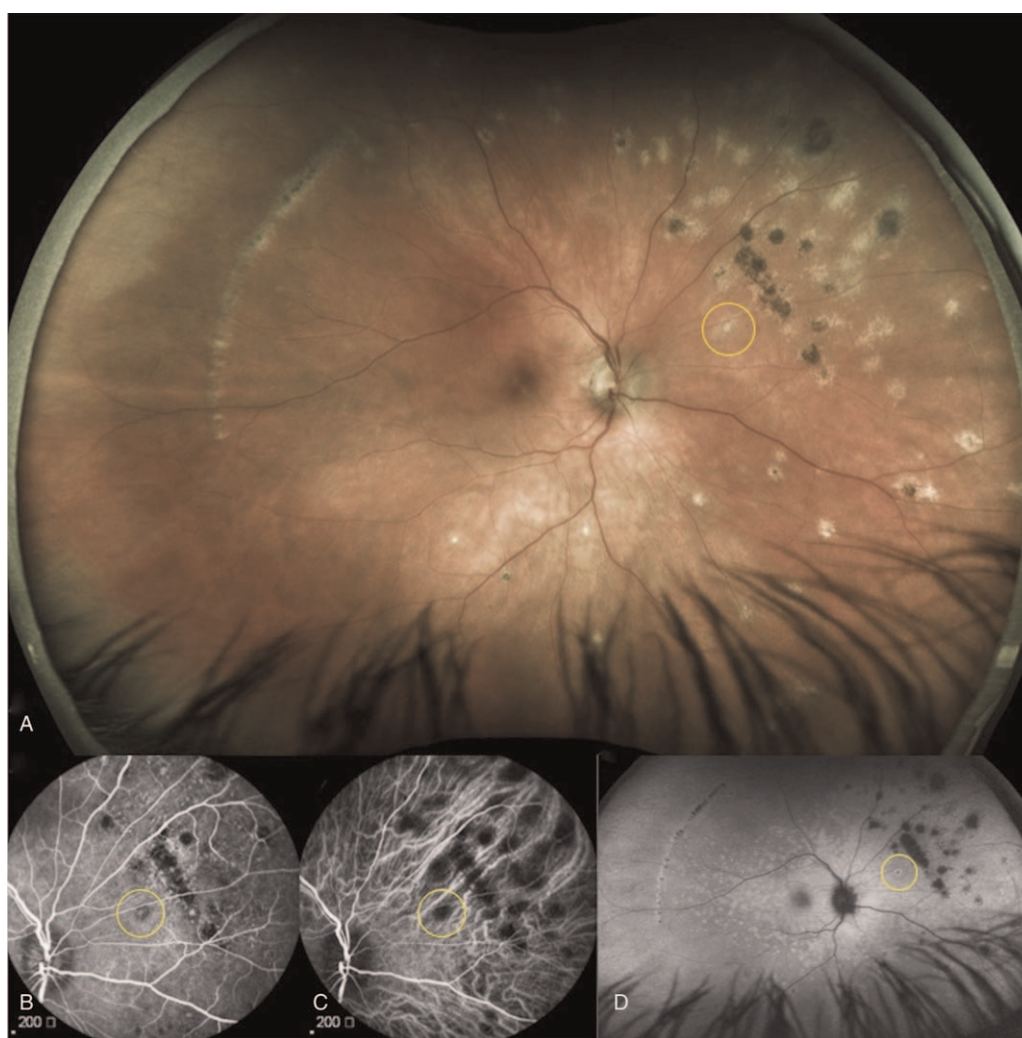
The OCT image, acquired at presentation of the singled-out white dot lesion, revealed vitreous cell aggregation above the lesion and disruption of the inner segment/outer segment (IS/OS) junction and retinal pigment epithelium (RPE) band with subretinal hyperreflectivity deposits (Fig. 2A). The OCT-A image showed a focal area of clustered circular flow in the outer retinal level, suggesting a possible CNV formation, (Fig. 2C) and a corresponding projection shadowing at the choriocapillary layer (Fig. 2D).

Under the impression of MCP, oral prednisolone at 30 mg daily with topical prednisolone acetate 1% every 2 hours were prescribed and gradually tapered down within a 2-month course. The patient was regularly followed up weekly in the outpatient clinic and had a smooth recovery. She reported significant vision improvements and recovery in the diminished temporal visual field. The singled out nasal lesion was examined again with OCT and OCT-A at week 3. The OCT showed a recovery of the retinal structure and reduced thickness, with resolved disrupted IS/OS and RPE band with fewer subretinal deposits compared to the previous examination (Fig. 3A). The focal area of suspicious neovascular flow previously seen on OCT-A (Fig. 2C) were not able to identify after treatment at week 3 (Fig. 3C and D). The best corrected visual acuity of her right eye has returned to 6/6 with total cessation of the anterior chamber and vitreous inflammation 2 months after treatment.

This case report was approved by the ethic committee (Institutional Review Board) of the Tri-service General Hospital in Taiwan (TSGH IRB No. 2-107-05-125). Informed written consent was obtained from the patient for publication of this case report and accompanying images.

## 3. Discussion

In this report, a young myopic woman presented with unilateral blurred vision of right eye for 2 weeks. Ophthalmic examination



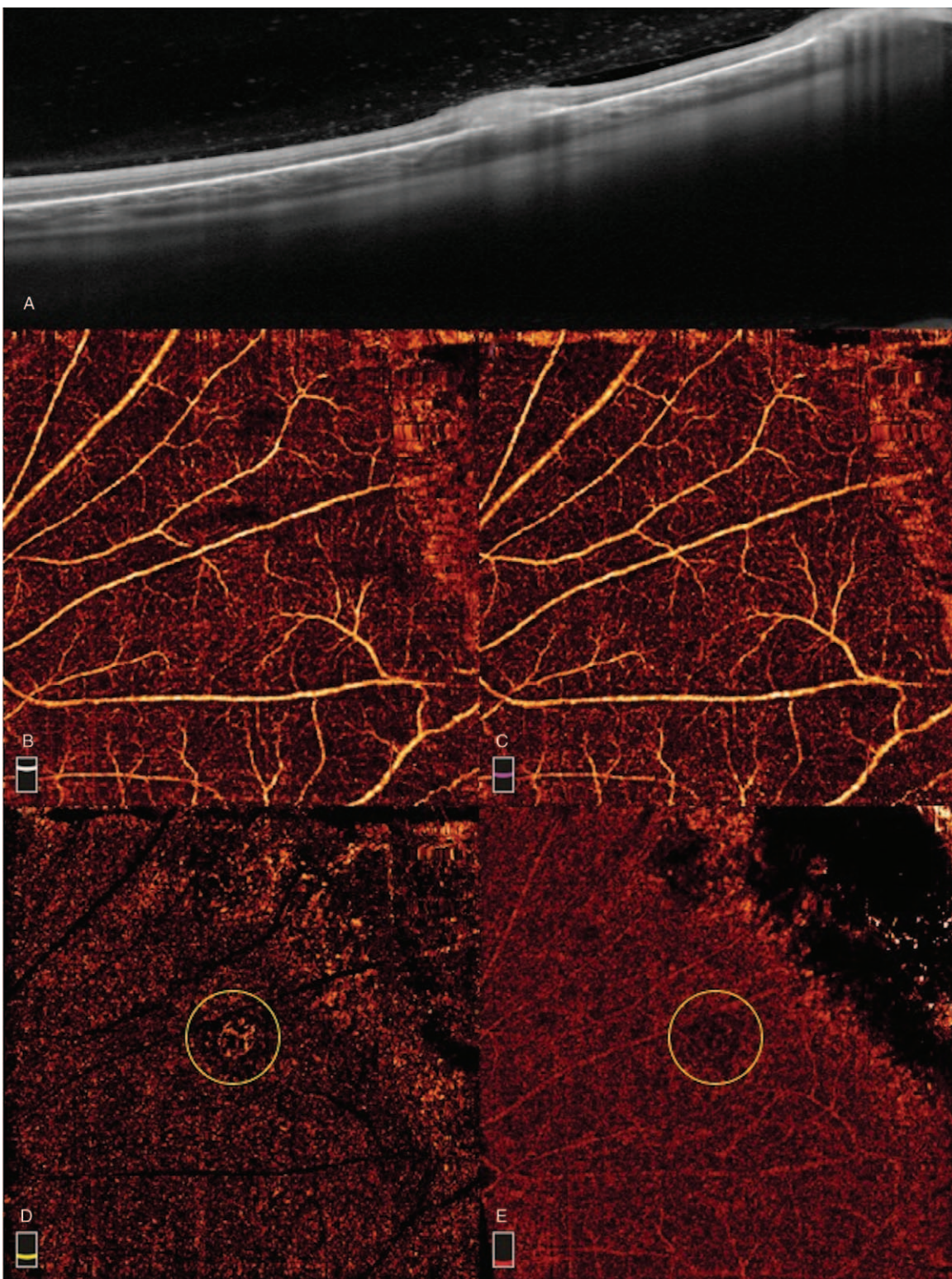
**Figure 1.** A pretreatment multimodal imaging study of a 32-year-old Caucasian woman who presented with multifocal choroiditis with panuveitis (MCP) in her right eye. (A) Ultra-wide field color fundus image. (B) Fluorescein angiography (FA). (C) Indocyanine green angiography (ICGA). (D) Fundus autofluorescence (FAF) ultra-wide field image. The yellow circles indicate the singled out active lesion being studied.

revealed anterior uveitis and vitritis with multiple chorioretinal lesions at the mid-periphery retina of the right eye. After excluding infectious etiologies, the clinical symptoms and signs were compatible with the diagnosis of MCP. As shown in the literature, these characteristic chorioretinal lesions in MCP generally have a yellow-white or grayish appearance in the outer retina and choroid at disease active stage, eventually progressing into punched-out pigmented scars or curvilinear chorioretinal streaks in a later stage.<sup>[1-3]</sup> Even though these lesions generally appear at mid-periphery retina, the documented poor visual prognosis in MCP was usually related to structural complications from ocular inflammation, such as cataracts, CME, ERM or CNV involving the macula.<sup>[13]</sup> Within these devastating complications, the development of CNV was the most common cause of vision loss.<sup>[13]</sup> Hence, numerous studies have utilized MMI method to assist the differential diagnosis and to monitor treatment effects of these fundoscopic lesions.

In this presented case, a punched-out lesion at the nasal quadrant was specifically selected for detailed MMI examination and follow up. The hypo-autofluorescent center and hyper-autofluorescent halo shown on FAF indicated an active inflammatory process involving the RPE and outer retina. This

finding was further confirmed by examine the OCT image, which revealed an IS/OS and RPE band disruption with subretinal deposits and overlaying vitreous cell aggregation. In 2013, Spaide et al<sup>[14]</sup> summarized their findings by examine MCP patient with MMI. They concluded that the principle site of acute lesions was located in the sub-RPE and outer retina level. Depositing homogenous or heterogenous material in these spaces would result in a wider involvement, extending to the ellipsoid zone beyond the RPE elevation. This is consistent to the reflectivity change found on SD-OCT examination in their study.<sup>[14]</sup> These conclusions revealed a similar assumptions while observing various FAF presentation in MCP lesions, such as hyper-autofluorescence ring in RPE elevation site or absent of autofluorescence in RPE dehiscence lesions, which logically explained the profoundly affected RPE pathologies.<sup>[15]</sup> Moreover, Spaide et al<sup>[14]</sup> categorized these MCP lesions as acute/inactive lesions and acute/late CNV lesions using MMI methods. Despite their efforts, the authors suggested that the differentiation between these lesions may not always be possible because the infiltrative nature of inflammatory process and CNV process, in which both break down the blood-retina barrier and sometimes co-existing in the same lesion.<sup>[14]</sup>



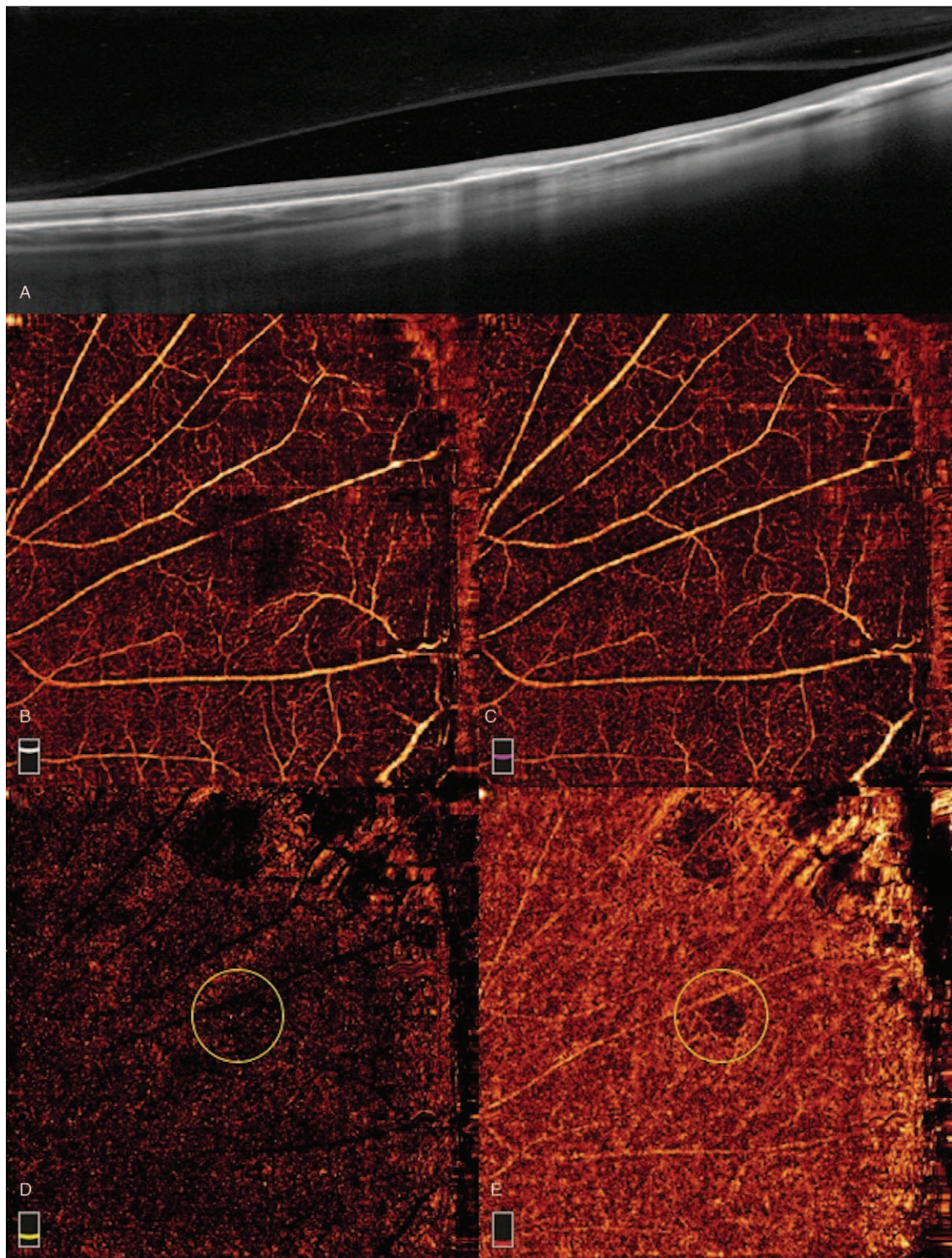


**Figure 2.** The singled out active lesion before treatment. (A) Cross-line optical coherence tomography (OCT) showed subretinal heterogenous deposit, disruption of RPE integrity and outer retina structure, and vitreous cell overlying the lesion. (B–E) Optical coherence tomography angiography (OCT-A) at different layers, (B) superficial capillary plexus, (C) deep capillary plexus, (D) outer retinal layer, and (E) choroidal capillary layer. Yellow circles indicate the singled-out lesion with flow signal in OCT-A. RPE = retinal pigment epithelium.

Conventionally, FA is considered the standard modality to differentiate between these 2 types of lesions, which show early hyper-fluorescence with late leakage in CNV lesions and hypo- to iso-fluorescence with late hyper-fluorescence in acute inflamma-

tory lesions. Owing to the advent of OCT-A, direct visualization of chorioretinal capillary vasculature is possible, with faster acquisition time and higher resolution than FA, without the risk of developing dye-injection-associated complications. Since then,





**Figure 3.** The singled-out lesion 3 weeks after treatment. (A) Cross-line optical coherence tomography (OCT) showed recovery of the previously disrupted RPE and outer retina structure with fewer subretinal hyperelective deposits, and near absence of vitreous cell. (B–E) Optical coherence tomography angiography (OCT-A) at different layers, (B) superficial capillary plexus, (C) deep capillary plexus, (D) outer retinal layer, and (E) choroidal capillary layer. Yellow circles indicate the singled-out lesion. RPE = retinal pigment epithelium.

OCT-A has been used to study inflammatory and CNV lesions in MCP. In a study conducted in 2016 by Chen et al,<sup>[9]</sup> active and inactive MCP lesions were presented with detailed statistical description using MMI methods, incorporating OCT-A results.

The authors indicated 5 advantages of the OCT-A over FA in active CNV identification: higher sensitivity and specificity, dynamic blood flow information without interference of dye leakage in FA, little influence from either subretinal fluid or

hemorrhage, quantitative analysis using flow area function, and excellent distinguishing ability of CNV from inflammatory lesions.<sup>[9]</sup> By comparing the differentiation ability of OCT-A to FA in acute inflammatory lesions, 94.1% did not showed flow signal in OCT-A and variable early-phase presentation with 100% late leakage in FA; whereas in active CNV lesions, 87% had blood flow signal in OCT-A and 100% showed early hyper-fluorescence with late leakage in FA.<sup>[9]</sup> In addition, 23.5% of the active inflammatory lesions had similar FA patterns (early hyper-fluorescence with late leakage) as in active CNV lesions, which proves the superior diagnostic power of OCT-A over FA imaging.<sup>[9]</sup>

In our study, the singled-out lesion was 1st observed under FA and showed early blockage with late staining. This result was better interpreted as an acute inflammatory process rather than a classical CNV appearance, which usually resulted in an early hyper-fluorescence and late leakage in FA. Second, this punched-out lesion was examined under OCT-A and revealed a circular high-flow area in the outer retinal layer indicative a CNV formation. In a recent retrospective study of MCP by Zahid et al,<sup>[11]</sup> active lesions that did not demonstrate obvious leakage in FA often presented with CNV under OCT-A image. These active MCP lesions were further categorized using SD-OCT into sub-RPE, subretinal, and mixed lesions, according to their anatomical level, and re-examined using OCT-A. Their results showed different probabilities of neovascular flow pattern in these anatomical levels: 0% in sub-RPE, 91% in subretinal level, and 100% in mixed lesions.<sup>[11]</sup> Furthermore, the development of CNV in patients with MCP is intrinsically related to RPE integrity. While a breach in the RPE barrier may provide a conduit for angiogenesis pathologically, the preservation of RPE integrity may be protective against neovascularization.<sup>[11]</sup> Recently, Astroz et al<sup>[12]</sup> established a correlation between FAF and OCT-A findings for both inflammatory and CNV lesions. The results showed statistically significance ( $P=.028$ ) and that hyper-autofluorescent halo or ring on FAF was strongly related with blood flow signal on OCT-A, whereas hypo-autofluorescent lesions showed no blood flow signal on OCT-A.<sup>[12]</sup> Hence, these lesions with hyper-autofluorescent halo on FAF prompt possible CNV detection of mixed or continuous inflammatory and neovascular component in these lesions.<sup>[12]</sup> Regarding the presented case, the singled-out lesion showed similar findings, including a disruption of RPE band and subretinal deposit under OCT, a hyper-autofluorescent halo under FAF, and a neovascular flow signal under OCT-A. Combining these results, the singled-out lesion of our study revealed a mixed component of a neovascularization event within an acute inflammation process. Nonetheless, this co-existing presentation may represent a similar example of a “quiescent CNV”, referred by Chen et al,<sup>[9]</sup> which is defined as inactive CNV lesions that show blood flow signal on OCT-A but no active leakage on FA.<sup>[9]</sup>

The CNVs observed in MCP or other posterior uveitis have been called “inflammatory CNV”, which presented differently compared to degenerative CNV, as in AMD. The inflammatory process is located at the RPE and inner choroid level, leading to rapid disruptions of the choriocapillaris–Bruch’s membrane–RPE complex and further aggravating neovascularization.<sup>[16]</sup> Hence, all inflammatory CNV cases were predominantly classic CNV or type 2 CNV in nature.<sup>[17]</sup> However, intra-retinal and subretinal fluids often observed in classic CNV on OCT rarely occur in these inflammatory CNVs.<sup>[9,10]</sup> In addition, chronic low-grade inflammation in this layer was believed to trigger angiogenesis,

sometimes in the area of an old chorioretinal scar, which frequently showed large hypofluorescent area in ICGA, suggesting ischemic non-perfusion in the choroidal vasculature.<sup>[18]</sup> These inflammatory CNVs usually started in non-subfoveal areas, progressively extending into subfoveal and significantly affecting vision.<sup>[16]</sup> Furthermore, in a pathology study of vitrectomized neovascular membrane of MCP eyes,<sup>[19]</sup> infiltration of B lymphocytes was observed in the vitrectomized CNV membrane, suggesting that the clinical presentation of inflammatory cells in the anterior chamber or vitreous body might indicate active inflammatory CNV. In other words, inflammation is the core pillar in MCP disease process which manifest in different presentation spectra, including inflammatory CNV. Hence, treating the upstream pathway may explain the effectiveness of steroid regimen in our case. To be more specific, the active inflammatory CNV lesion selected in our study had subsided with no detectable flow on OCT-A after 3 weeks of systemic steroid usage without anti-vascular endothelial growth factor intervention. Fortunately, the presented chorioretinal lesions in patient’s right eye did not involve macula or cause other commonly associated macula complications, such as CME or subfoveal CNV, so the patient’s visual acuity returned to its fullest after treatment.

Our results proved OCT-A’s superior visualization of microvascular details that might be lost in FA images, especially when mixed inflammatory and neovascular components occur in the same lesion. Further, without the nuisance of dye injection and associated systemic risk, OCT-A is more efficient and convenient than FA for MCP disease monitoring. However, given the limitation that this was only a single case report with a short follow-up period, the information obtained may not explain the whole picture of MCP disease process. Moreover, we also did not examine all the chorioretinal lesions with OCT-A, but focused on the relevant lesion, which showed specific active-stage FAF findings at presentation. Therefore, further study may be needed to include more cases and a more thorough examination of these chorioretinal lesions.

#### 4. Conclusion

The MCP is an uncommon, idiopathic, posterior uveitis with multiple inflammatory chorioretinal lesions and various degrees of ocular inflammation. In this case, we presented a patient with unilateral MCP and examined the characteristic punched-out lesions in the chorioretina using MMI technique. Our results demonstrated that OCT-A could be used to monitor the inflammatory CNV process in these lesions without dye injection. Moreover, these active inflammatory lesions may display subtle neovascularization process which is detectable by OCT-A but missed by conventional FA or ICGA image. Further studies should take explore these subtle changes to better understand the disease process of MCP.

#### Author contributions

**Conceptualization:** Lung-Chi Lee, Yi-Hao Chen, Jiann-Torng Chen.

**Data curation:** Ke-Hao Huang, Yi-Hao Chen, Chia-Chen Hsu.

**Formal analysis:** Lung-Chi Lee, Ke-Hao Huang, Yi-Hao Chen.

**Investigation:** Lung-Chi Lee, Ke-Hao Huang, Hsin-Ting Lin, Chia-Chen Hsu.

**Methodology:** Hsin-Ting Lin.

**Project administration:** Ching-Long Chen.



**Resources:** Ching-Long Chen.

**Software:** Chang-Min Liang.

**Supervision:** Hsin-Ting Lin, Ming-Cheng Tai, Chang-Min Liang, Ching-Long Chen.

**Visualization:** Jiann-Torng Chen.

**Writing – original draft:** Lung-Chi Lee.

**Writing – review & editing:** Ming-Cheng Tai, Jiann-Torng Chen, Ching-Long Chen.

## References

- [1] Quillen DA, Davis JB, Gottlieb JL, et al. The white dot syndromes. *Am J Ophthalmol* 2004;137:538–50. doi:10.1016/j.ajo.2004.01.053.
- [2] Crawford CM, Igboeli O. A review of the inflammatory chorioretinopathies: the white dot syndromes. *ISRN Inflamm* 2013;2013:783190doi:10.1155/2013/783190.
- [3] Tavallali A, Yannuzzi LA. Idiopathic multifocal choroiditis. *J Ophthalmic Vis Res* 2016;11:429–32. doi:10.4103/2008-322X.194141.
- [4] Raven ML, Ringeisen AL, Yonekawa Y, et al. Multi-modal imaging and anatomic classification of the white dot syndromes. *Int J Retin Vitre* 2017;3:12. doi:10.1186/s40942-017-0069-8.
- [5] Dreyer RF, Gass JDM. Multifocal choroiditis and panuveitis: a syndrome that mimics ocular histoplasmosis. *Arch Ophthalmol* 1984;102:1776–84. doi:10.1001/archoph.1984.01040031440019.
- [6] Ferrara D, Waheed NK, Duker JS. Investigating the choriocapillaris and choroidal vasculature with new optical coherence tomography technologies. *Prog Retin Eye Res* 2016;52:130–55. doi:10.1016/j.preteyeres.2015.10.002.
- [7] de Carlo TE, Romano A, Waheed NK, et al. A review of optical coherence tomography angiography (OCTA). *Int J Retin Vitre* 2015;1:5doi:10.1186/s40942-015-0005-8.
- [8] Kashani AH, Chen C-L, Gahm JK, et al. Optical coherence tomography angiography: a comprehensive review of current methods and clinical applications. *Prog Retin Eye Res* 2017;60:66–100. doi:10.1016/j.preteyeres.2017.07.002.
- [9] Cheng L, Chen X, Weng S, et al. Spectral-domain optical coherence tomography angiography findings in multifocal choroiditis with active lesions. *Am J Ophthalmol* 2016;169:145–61. doi:10.1016/j.ajo.2016.06.029.
- [10] Levison AL, Baynes KM, Lowder CY, et al. Choroidal neovascularisation on optical coherence tomography angiography in punctate inner choroidopathy and multifocal choroiditis. *Br J Ophthalmol* 2017;101:616–22. doi:10.1136/bjophthalmol-2016-308806.
- [11] Zahid S, Chen KC, Jung JJ, et al. Optical coherence tomography angiography of chorioretinal lesions due to idiopathic multifocal choroiditis. *Retina* 2017;37:1451–63. doi:10.1097/IAE.0000000000001381.
- [12] Astroz P, Miere A, Mrejen S, et al. Optical coherence tomography angiography to distinguish choroidal neovascularization from macular inflammatory lesions in multifocal choroiditis. *Retina* 2018;38:299–309. doi:10.1097/IAE.0000000000001617.
- [13] Thorne JE, Wittenberg S, Jabs DA, et al. Multifocal choroiditis with panuveitis. Incidence of ocular complications and of loss of visual acuity. *Ophthalmology* 2006;113:2310–6. doi:10.1016/j.ophtha.2006.05.067.
- [14] Spaide RF, Goldberg N, Freund KB. Redefining multifocal choroiditis and panuveitis and punctate inner choroidopathy through multimodal imaging. *Retina* 2013;33:1315–24. doi:10.1097/IAE.0b013e318286cc77.
- [15] Haen SP, Spaide RF. Fundus autofluorescence in multifocal choroiditis and panuveitis. *Am J Ophthalmol* 2008;145:847–53. doi:10.1016/j.ajo.2008.01.008.
- [16] Wu K, Zhang X, Su Y, et al. Clinical characteristics of inflammatory choroidal neovascularization in a Chinese population. *Ocul Immunol Inflamm* 2015;24:1–7. doi:10.3109/09273948.2015.1015741.
- [17] Neri P, Lettieri M, Fortuna C, et al. Inflammatory choroidal neovascularization. *Middle East Afr J Ophthalmol* 2009;16:245–51. doi:10.4103/0974-9233.58422.
- [18] Vadalà M, Lodato G, Cillino S. Multifocal choroiditis: indocyanine green angiographic features. *Ophthalmologica* 2001;215:16–21. doi:10.1159/000050820.
- [19] Shimada H, Yuzawa M, Hirose T, et al. Pathological findings of multifocal choroiditis with panuveitis and punctate inner choroidopathy. *Jpn J Ophthalmol* 2008;52:282–8. doi:10.1007/s10384-008-0566-2.