

Neth Heart J (2019) 27:108–109  
<https://doi.org/10.1007/s12471-018-1216-z>



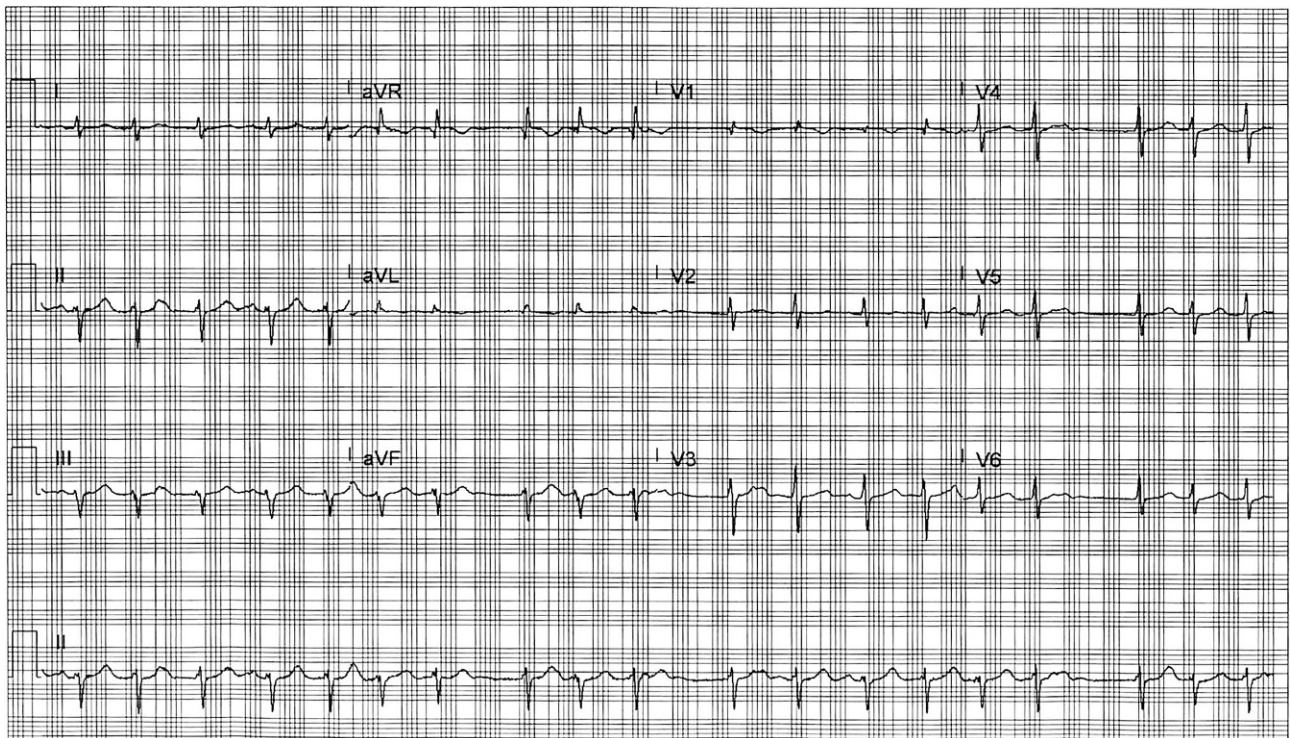
# An irregular narrow complex tachycardia: atrial fibrillation or something else?

M. J. Mulder · C. P. Allaart · H. A. Hauer · M. J. B. Kemme

Published online: 14 December 2018  
© The Author(s) 2018

A 44-year-old female patient was referred to our centre for pulmonary vein isolation. Her medical history was significant for hypothyroidism. She was tak-

ing levothyroxine and was clinically euthyroid with a free T4 of 19.9 pmol/l (12–22 pmol/l) and a thyroid-stimulating hormone level of 4.5 mU/l (0.3–4.5 mU/l).



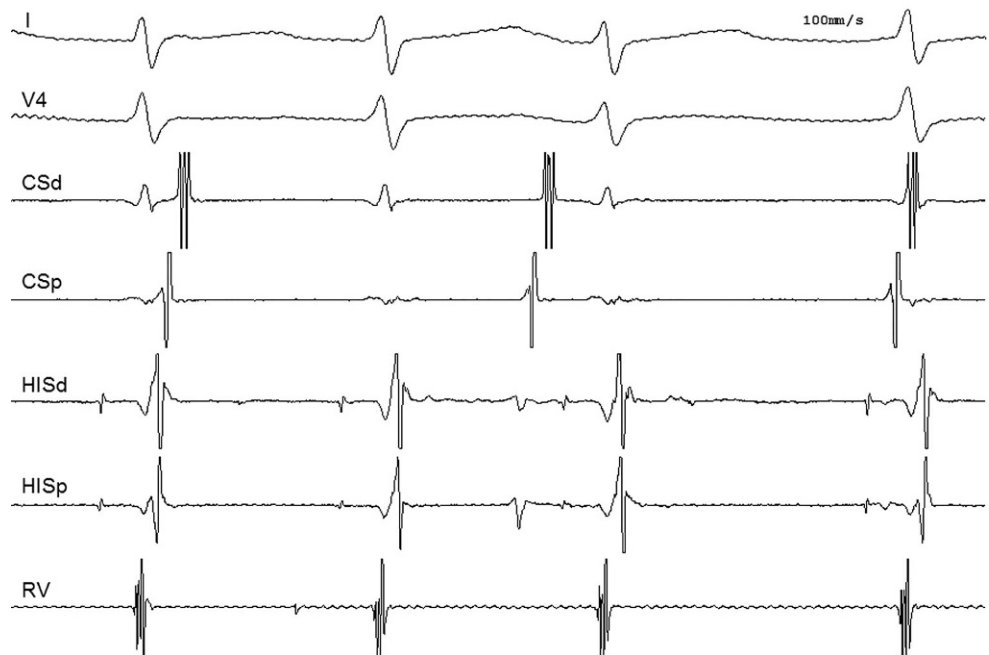
**Fig. 1** Electrocardiogram during palpitations

M. J. Mulder (✉) · C. P. Allaart · H. A. Hauer · M. J. B. Kemme  
Department of Cardiology, Amsterdam UMC, Amsterdam  
Cardiovascular Sciences, Vrije Universiteit Amsterdam,  
Amsterdam, The Netherlands  
m.mulder2@vumc.nl

H. A. Hauer  
Cardiology Centres of the Netherlands, Amsterdam, The  
Netherlands



**Fig. 2** Tachycardia during electrophysiology study (CSd distal coronary sinus, CSp proximal coronary sinus, HISd distal His bundle, HISp proximal His bundle, RV right ventricle)



She experienced daily episodes of palpitations, not responding to antiarrhythmic drug therapy (sotalol or flecainide). Episodes were self-terminating within an hour of onset, without performing vagal manoeuvres. A 12-lead electrocardiogram was acquired during palpitations, which revealed an irregular narrow complex tachycardia that was previously diagnosed as atrial fibrillation (Fig. 1). Structural heart disease was excluded by transthoracic echocardiography. Based on this ECG an electrophysiology study was scheduled. During placement of the catheters, spontaneous initiation of an irregular tachycardia occurred (Fig. 2). What is the mechanism of this tachycardia?

### Answer

You will find the answer elsewhere in this issue.

**Open Access** This article is distributed under the terms of the Creative Commons Attribution 4.0 International License (<http://creativecommons.org/licenses/by/4.0/>), which permits unrestricted use, distribution, and reproduction in any medium, provided you give appropriate credit to the original author(s) and the source, provide a link to the Creative Commons license, and indicate if changes were made.