

CASE REPORT

Use of microbubble contrast in the diagnosis of a left ventricular papillary fibroelastoma

Jenny Duke BSc MBBS¹, Kim Greaves BSc MBBS MD FACC FRACP² and Andrew Dettrick MBBS FRCPA³

¹Department of Medicine, University of Queensland, Brisbane, Queensland, Australia

²Department of Cardiology, Sunshine Coast Hospital and Health Services, Nambour, Queensland, Australia

³Department of Pathology, Sunshine Coast Hospital and Health Services, Nambour, Queensland, Australia

Correspondence
should be addressed
to J Duke

Email
jenny.marie.duke@gmail.com

Summary

A papillary fibroelastoma is a rare, avascular, cardiac tumour that is often found incidentally using transthoracic echocardiography (TTE). Peripheral i.v. injection of a microbubble contrast agent is often used to characterize abnormal masses within the heart allowing further delineation of physical features, the area of attachment, and vascularity of the mass in order to differentiate the growth from a tumour or a thrombus. This case highlights a potential pitfall when assessing a cardiac tumour's vascularity using contrast TTE. A cardiac mass was identified on a TTE of a 53-year-old man and was further investigated with microbubble contrast-enhanced TTE. Contrast TTE imaging suggested a vascularized structure in the left ventricle. However, after histological examination the tumour was found to be entirely avascular.

Learning points:

- Differentiation of cardiac tumour is usually best performed with contrast echocardiography.
- Contrast echocardiography may not be best tool to determine if cardiac mass is vascularized.
- A papillary fibroelastoma can appear vascularized with contrast echocardiography due to its frond-like structures.
- Physicians should be aware of this potential confusion when assessing a cardiac tumour in patients.

Background

Cardiac papillary fibroelastoma (PFE) is the second most common primary cardiac tumour and accounts for 5% of all heart tumours (1). PFE is benign, usually found incidentally on transthoracic echocardiography (TTE), and is surgically excised in order to reduce the risk of embolism. Patients whom do not have this type of tumour removed have increased rates of cerebrovascular accidents (up to 10%) and mortality (up to 13%) (2). In previous cases, TTE using microbubble contrast has been found to be particularly useful in the evaluation of cardiac masses and distinguishing malignant growths from myxomas and thrombi (3). The microbubbles produce a brighter signal due to their ability to vibrate strongly at high frequencies

resulting in improved definition between blood and tissue. The technique also permits selective destruction of microbubbles within the cardiac structure using a flash impulse of high amplitude ultrasound (4). Re-perfusion can then be readily assessed as the microbubbles diffuse back into and through the structure of interest. In this particular case a continuous peripheral infusion of microbubbles were destroyed and then observed to re-perfuse the cardiac mass (Video 2) giving the appearance that the tumour was vascular.

Case presentation

A 53-year-old man presented with fever, myalgia, and joint pain. He was admitted and his blood cultures grew Group B

streptococcus. The septicaemia was suspected to have resulted from a recent infection following an injection into the patient's left wrist for tenosynovitis 4 weeks prior.

Investigation

TTE was performed to investigate for potential infective endocarditis. The three-dimensional TTE revealed a 1.9 × 1.5 cm, pedunculated, independently mobile echodensity, with a heterogeneous appearance that arose from the apical left ventricular wall (Video 1). Further additional characterization of the mass was carried out with peripheral i.v. injection of microbubble contrast agent. Flash impulse imaging was used to destroy the microbubbles, which were then witnessed to re-perfuse the mass suggesting that the mass was indeed vascular (Video 2). Histological examination (Fig. 1) revealed a mass composed of multiple fronds of acellular collagen and elastin covered by endothelium – features which are highly characteristic of a PFE.

Video 1

3D TTE image of tumour. View Video 1 at <http://movie-usa.glencoesoftware.com/video/10.1530/ERP-15-0033/video-1>.

Video 2

Contrast TTE with flash impulse destruction. Pre-flash imaging shows contrast within the PFE. Immediately post flash there is an absence of microbubbles but microbubbles are seen to return into the PFE suggests structure is vascular. View Video 2 at <http://movie-usa.glencoesoftware.com/video/10.1530/ERP-15-0033/video-2>.

Treatment and outcome

Following a period of antibiotic therapy, the patient underwent cardiac surgery to remove the mass. Contrary to the features demonstrated on contrast TTE, the PFE was entirely non-vascular histologically (Fig. 1). Figure 2 shows the PFE removed and immersed in water. The appearance is typical and resembles a sea anemone attached to a stalk with frond-like appendages (5).

Discussion

Our explanation of the erroneous finding is the unusual structure of the PFE. Following contrast destruction, the microbubbles returned and dispersed between the appendages leading to an incorrect assumption that the mass

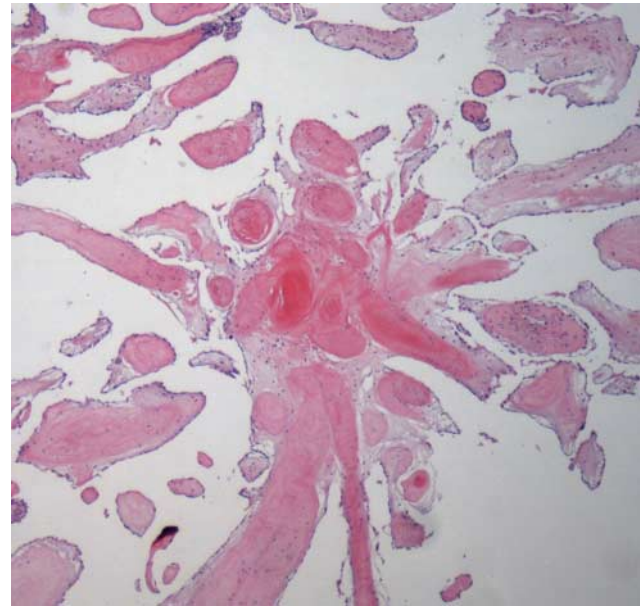


Figure 1

Histology of the PFE comprised of multiple fronds of acellular collagen and elastin covered by endothelium with a lack of vascular structures (H&E original magnification ×20).

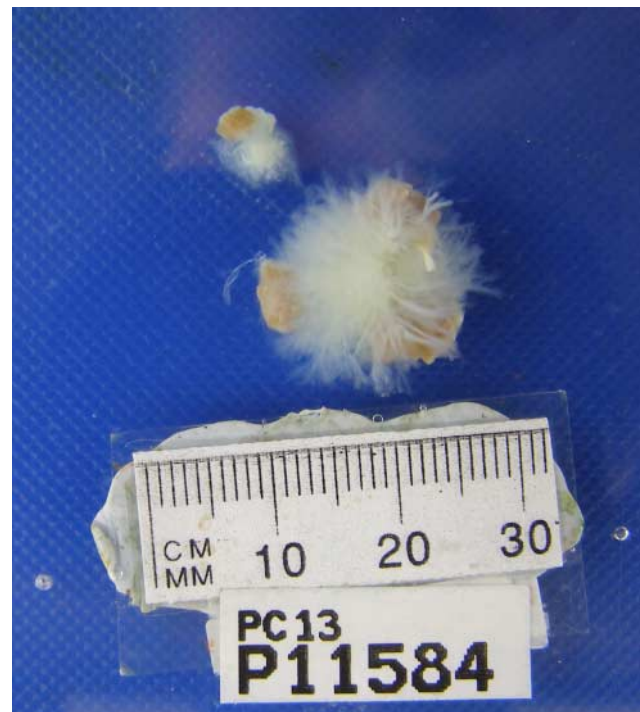

Figure 2

Macroscopic appearance of PFE demonstrating its frond-like structure.

was vascular. Another potential contributing factor is a 'bleeding' effect of surrounding LV cavity blood into the region of interest as the mass rapidly oscillates in and out of the imaging plane. A previous PFE case presented by Basoglu *et al.* (6) discussed the advantage of performing cardiac TTE in characterizing PFE but did not acknowledge the issue we have identified. We therefore suggest that when microbubble contrast agent is used to determine the vascularity of structures, operators need to be aware of these potential pitfalls.

Declaration of interest

There is no conflict of interest that could be perceived as prejudicing the impartiality of the research reported.

Funding

This research did not receive any specific grant from any funding agency in the public, commercial, or not-for-profit sector.

Patient consent

Written informed consent has been obtained from the patient for publication of the submitted article and accompanying images.

Author contribution statement

J Duke contributed to this case report as the primary author under the guidance of Dr K Greaves. K Greaves is the treating physician of the patient in the case. Dr A Dettrick was the original pathologist that reported the papillary fibroelastoma and provided the pathological images. Each co-author was involved in editing the case report.

References

- 1 Mariscalo G, Bruno VD, Borsani P, Dominici C & Sala A 2010 Papillary fibroelastoma: insight to a primary cardiac valve tumor. *Journal of Cardiac Surgery* **25** 198–205. (doi:10.1111/j.1540-8191.2009.00993.x)
- 2 Tamin S, Maleszewski J, Scott C, Khan S, William D, Bruce C, Jae K, Pellikka P & Klarich K 2015 Prognostic and bioepidemiologic implications of papillary fibroelastomas. *Journal of the American College of Cardiology* **65** 2420–2429. (doi:10.1016/j.jacc.2015.03.569)
- 3 Mansencal N, Revault-d'Allonnes L, Pelage JP, Farcot JC, Lacombe P & Dubourg O 2009 Usefulness of contrast echocardiography for assessment of intracardiac masses. *Archives of Cardiovascular Diseases* **102** 177–183. (doi:10.1016/j.acvd.2008.12.007)
- 4 Bomley MJ, Cooke JC, Unger EC, Monaghan MJ & Cogrove DO 2001 Microbubble contrast agents: a new era in ultrasound. *British Medical Journal* **322** 1222–1225. (doi:10.1136/bmj.322.7296.1222)
- 5 Law KB, Phillips KR, Cusimano RJ & Butany J 2009 Multifocal "tapete" papillary fibroelastoma. *Journal of Clinical Pathology* **62** 1066–1070. (doi:10.1136/jcp.2009.070243)
- 6 Basoglu A, De Wolf A, Dendale P, Vanbockrijck H & Vracnkx P 2006 Echocardiography remains the standard for the diagnostic evaluation of left ventricular tumors: a case report with anatomical correlation. *European Journal of Echocardiography* **8** 401–403. (doi:10.1016/j.euje.2006.06.009)

Received in final form 23 November 2015

Accepted 24 November 2015