

## EDITORIAL COMMENT

# Heterotopic Transcatheter Tricuspid Valve Implantation



## A Useful Bailout Strategy After Failed Transcatheter Tricuspid Valve Repair?\*

Alessandro Sticchi, MD,<sup>a</sup> Fabien Praz, MD<sup>b</sup>

In this issue of *JACC: Case Reports*, Costa et al<sup>1</sup> reported an interesting case of caval valve implantation (CAVI) using the TricValve system (P+F Products + Features) as a bailout strategy following unsuccessful tricuspid transcatheter edge-to-edge repair (T-TEER) because of partial detachment of a TriClip XT (Abbott).

The 71-year-old female patient had multivalvular rheumatic heart disease and underwent mitral valve replacement because of mitral stenosis. As a second step, symptomatic aortic stenosis was treated with the transfemoral implantation of a self-expanding transcatheter valve.

Following open heart surgery, worsening right ventricular (RV) dilatation and secondary tricuspid regurgitation (TR) have been observed in 31% of patients with rheumatic heart disease.<sup>2</sup> Redo surgical procedures to correct TR have been associated with excessive mortality, which is confirmed by a calculated TRI-SCORE of 7 of 12, predicting a risk of in-hospital mortality of 34% in the presented patient.<sup>3</sup> In this context, transcatheter treatment of the tricuspid valve represents an appropriate and safe approach.

During the initial T-TEER procedure, detachment of 1 of the 3 implanted clips occurred, leading to

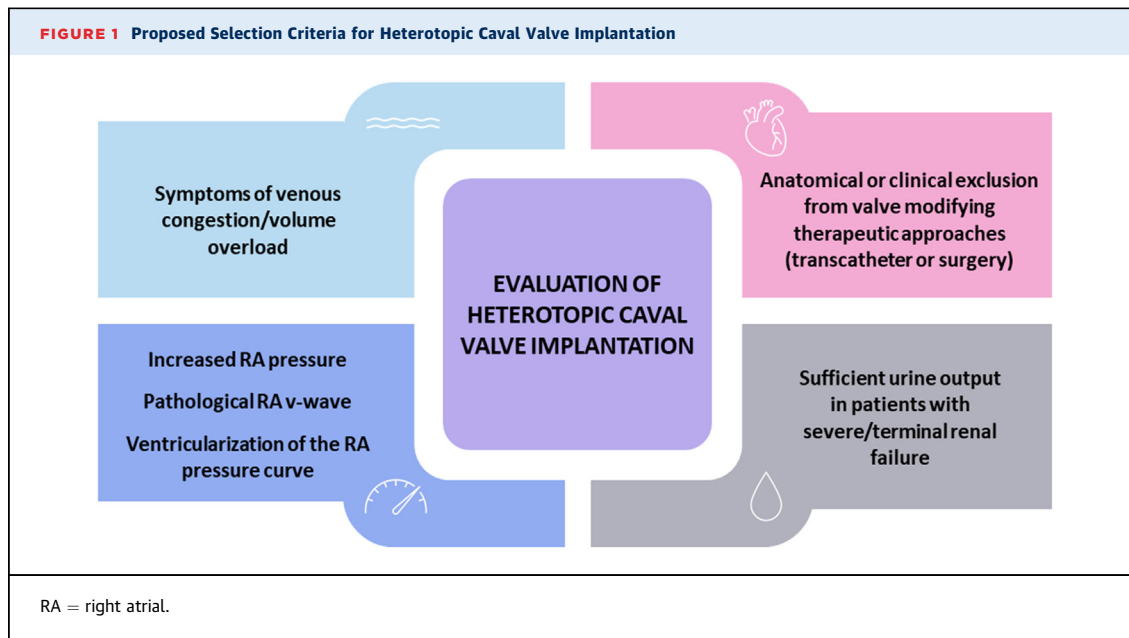
recurrent severe TR. With a prevalence ranging from 3% to 7% in published studies,<sup>4,5</sup> single-leaflet device attachment is a frequent complication during or early after T-TEER, in particular in patients with suboptimal imaging because of shadowing, as sometimes observed in the presence of a mechanical mitral valve prosthesis. Previously described management strategies include stabilization using additional implants, conversion to surgery, transcatheter valve replacement, or caval valve implantation.<sup>6-8</sup>

The device used in this patient, the TricValve system, consists of 2 self-expanding nitinol stents with bovine pericardial leaflets, each of them specifically designed to be implanted in the superior and the inferior vena cava with the aim of alleviating congestive symptoms. The 6-month results of the European approval single-arm study, the TRICUS EURO (Safety and Efficacy of the TricValve® Transcatheter Bicaval Valves System in the Superior and Inferior Vena Cava in Patients With Severe Tricuspid Regurgitation) registry (12 centers), have been published recently and described good technical and procedural success. Furthermore, the study reported functional improvement (Kansas City Cardiomyopathy Questionnaire [KCCQ-12] score from  $42.01 \pm 22.3$  points at baseline to  $59.7 \pm 23.6$  at 6 months [ $P = 0.004$ ]; patients in New York Heart Association functional class I or II from 0% at baseline to 79.4% at 6 months). Six-month all-cause mortality and heart failure hospitalization rates were 8.5% and 20%, respectively.<sup>9</sup>

Another dedicated caval valved stent, the Tricento system (New Valve Technology), is available in Europe and has shown comparable performance in a recently published multicenter retrospective study.<sup>10</sup> Using cardiovascular magnetic resonance

\*Editorials published in *JACC: Case Reports* reflect the views of the authors and do not necessarily represent the views of *JACC: Case Reports* or the American College of Cardiology.

From the <sup>a</sup>Humanitas Research Hospital IRCCS, Rozzano, Milano, Italy; and the <sup>b</sup>Bern University Hospital, University of Bern, Bern, Switzerland. The authors attest they are in compliance with human studies committees and animal welfare regulations of the authors' institutions and Food and Drug Administration guidelines, including patient consent where appropriate. For more information, visit the [Author Center](#).



imaging in a subgroup of patients, evidence of RV remodeling was observed at 6 months, while fractures of the custom-made stent have been detected by systematic 4-dimensional computed tomography and triggered changes in design and patient selection criteria. Compared to the off-label use of transcatheter aortic valves, dedicated caval systems appear safer and less prone to dislocation.<sup>11</sup>

Considering the technical complexity of transcatheter tricuspid valve interventions with still limited expertise and availability, as well as the high dependency on sufficient imaging conditions, CAVI may represent a simple palliative treatment alternative for patients with advanced right heart failure and no other therapeutic option. Because symptomatic response is not uniformly observed, careful patient selection, including invasive hemodynamic assessment, is required (Figure 1). Resolution of venous renal congestion (or “renal tamponade”) may represent one of the main pathophysiologic mechanisms conditioning clinical response, and therefore sufficient urine output may play a role in patients with severe or terminal renal failure.<sup>12</sup> Patients with failed T-TEER may be particularly suitable because the valve is generally no longer amenable to other treatment modalities due to additional still attached clips (as in the present case), interaction with the detached device,

or already increased transvalvular gradient.<sup>7,8</sup> Furthermore, the heterotopic position may allow for a second intervention through the valved stent, if required.<sup>8,13,14</sup>

As another interesting aspect, the presented case highlights the role of multimodality imaging during work-up but also the use of computed tomography fusion to identify the contours of the right atrium and the location of the hepatic veins, 2 key anatomic landmarks during caval valve implantation.<sup>15</sup>

Against the background of the modest clinical response and the risk of progression of RV dysfunction discussed in the present case, further studies are certainly needed to understand the exact role of CAVI in the emerging landscape of transcatheter tricuspid interventions.

#### FUNDING SUPPORT AND AUTHOR DISCLOSURES

Dr Sticchi has received travel expenses from Terumo. Dr Praz has received travel expenses from Abbott Vascular, Edwards Lifesciences, and Polares Medical.

**ADDRESS FOR CORRESPONDENCE:** Dr Alessandro Sticchi, Cardio Center, IRCCS Humanitas Research Hospital, Via Alessandro Manzoni 56, Rozzano, Milan 20098, Italy. E-mail: [sticchialessandro@gmail.com](mailto:sticchialessandro@gmail.com).

---

**REFERENCES**

1. Costa G, De Carlo M, Spontoni P, et al. Heterotopic transcatheter tricuspid valve replacement in severe tricuspid regurgitation and refractory right heart failure. *J Am Coll Cardiol Case Rep.* 2022;4:1005-1011.
2. Chen Y, Chan Y-H, Wu M-Z, et al. Prevalence and prognostic importance of massive tricuspid regurgitation in patients undergoing tricuspid annuloplasty with concomitant left-sided valve surgery: a study on rheumatic valvular heart disease. *Front Cardiovasc Med.* 2022;9:686208.
3. Dreyfus J, Audureau E, Bohbot Y, et al. TRI-SCORE: a new risk score for in-hospital mortality prediction after isolated tricuspid valve surgery. *Eur Heart J.* 2022;43(7):654-662.
4. Nickenig G, Weber M, Lurz P, et al. Transcatheter edge-to-edge repair for reduction of tricuspid regurgitation: 6-month outcomes of the TRILUMINATE single-arm study. *Lancet.* 2019;394(10213):2002-2011.
5. Kodali S, Hahn RT, Eleid MF, et al. Feasibility study of the transcatheter valve repair System for severe tricuspid regurgitation. *J Am Coll Cardiol.* 2021;77(4):345-356.
6. Wild MG, Zahr F, Nábauer M, Massberg S, Hausleiter J. Transfemoral transcatheter tricuspid valve replacement after failed leaflet repair. *EuroIntervention.* 2021;17(12):E1022-E1023.
7. Mattig I, Knebel F, Hewing B, et al. Impact of inferior caval valve implantation on severity of tricuspid regurgitation and right heart function. *Echocardiography.* 2020;37(7):999-1007.
8. Rroku A, Barbieri F, Landmesser U, Skurk C, Kasner M, Reinthaler M. Transcatheter caval valve implantation for tricuspid regurgitation after single leaflet device attachment. *J Am Coll Cardiol Case Rep.* 2022;4(8):481-485.
9. Estévez-Loureiro R, Sánchez-Recalde A, Amat-Santos IJ, et al. Six-month outcomes of the TricValve system in patients with tricuspid regurgitation: TRICUS EURO Study. *J Am Coll Cardiol Intv.* 2022;15(13):1366-1377.
10. Wild MG, Lubos E, Cruz-Gonzalez I, et al. Early clinical experience with the TRICENTO bicaval valved stent for treatment of symptomatic severe tricuspid regurgitation: a multicenter registry. *Circ Cardiovasc Interv.* 2022;15(3):E011302.
11. Dreger H, Mattig I, Hewing B, et al. Treatment of severe TRicuspid regurgitation in patients with advanced heart failure with caval vein implantation of the Edwards Sapien XT valve (TRICAVAL): a randomised controlled trial. *EuroIntervention.* 2020;15(17):1506-1513.
12. Boorsma EM, ter Maaten JM, Voors AA, van Veldhuisen DJ. Renal compression in heart failure: the renal tamponade hypothesis. *Heart Fail.* 2022;10(3):175-183.
13. Altisent OAJ, Benetis R, Rumbinaite E, et al. Caval valve implantation (CAVI): an emerging therapy for treating severe tricuspid regurgitation. *J Clin Med.* 2021;10(19):4601.
14. Bartkowiak J, Boscolo M, Sticchi A, Brugger N, Hunziker L, Praz F. Combined caval valved stent implantation and leaflet approximation for treatment of torrential tricuspid regurgitation. *J Am Coll Cardiol Intv.* 2022;15(13):1384-1385.
15. Praz F, Muraru D, Kreidel F, et al. Transcatheter treatment for tricuspid valve disease. *EuroIntervention.* 2021;17(10):791-808.

---

**KEY WORDS** computed tomography, imaging, tricuspid valve, valve replacement