

# A rare case of congenital red hair heterochromia of the scalp



Hua Yen Ling, MBBS, MRCP (UK),<sup>a</sup> Sharon Mun Yee Wong, MBBS, MRCPCH (UK),<sup>a</sup> Jinghui Yang, MBBS, MRCPCH (UK), MMED,<sup>b</sup> and Mark Jean Aan Koh, MBBS, MRCPCH (UK)<sup>a</sup>  
*Singapore*

**Key words:** heterochromia; scalp hair.

## INTRODUCTION

Heterochromia of hair describes hair with 2 distinct colors in the same person. It can present in several distributions, namely patchy, segmental, diffuse, or following lines of Blaschko. Isolated hair heterochromia, a variant of pigmentary mosaicism, results from somatic gene mosaicism affecting hair follicles on the scalp in a Blaschkoid distribution and usually presents at birth or in infancy. We report a rare case of congenital red hair heterochromia following a line of Blaschko in a well infant and discuss the literature on scalp hair heterochromia.

## CASE REPORT

A 1-year-old Chinese boy presented with a band of red hair in a spiral pattern over the left parieto-occipital region (Fig 1). Present since birth, it gradually became more obvious at 4 months. The rest of his scalp hair, eyebrows, and eyelashes were black. There was no prior scalp inflammation or trauma, and he had not undergone previous hair treatments. Parents were nonconsanguineous, and there was no significant family history. Systemic review was unremarkable, and he was not on any medications. His growth and development were normal. The underlying scalp was of uniform color and the rest of his skin, nails and mucosa were unremarkable. There were no ocular or audiological abnormalities. Light microscopy of the red hair showed homogeneously decreased pigmentation compared with the patient's normal hair (Fig 2). The parents were reassured, and no treatment was rendered. At review 1 year later, the band of red hair was still apparent but stable.

## DISCUSSION

Heterochromia of hair describes hair with 2 distinct colors in an individual. It can present as patchy, segmental, diffuse, or in a Blaschkoid pattern.

Patchy hair heterochromia describes demarcated areas of hair color distinctly different to the patient's normal scalp hair. This dyschromia can appear as white, brown, or blond. Examples include patients with piebaldism or Waardenburg syndrome with a white forelock, poliosis in depigmenting conditions like vitiligo, and thicker and darker hair over congenital melanocytic nevi.<sup>1</sup> Segmental hair heterochromia describes alternating light and dark sections in each hair shaft and may occur with iron deficiency.<sup>2</sup> Diffuse scalp heterochromia describes hair of different colors evenly distributed over the entire scalp and may be associated with systemic conditions such as kwashiorkor or phenylketonuria with lighter hair color or with medications such as minoxidil causing hair darkening, diazoxide causing red hair, or chloroquine causing depigmented hair.<sup>3</sup> Rarely, diffuse hair heterochromia has been described in families, unrelated to any underlying causes.<sup>4</sup>

Cutaneous somatic gene mosaicism, first described by Happle, results in skin abnormalities distributed in various cutaneous patterns such as the lines of Blaschko.<sup>5</sup> Similarly, hair heterochromia following lines of Blaschko is extremely rare and is thought to represent a form of pigmentary mosaicism affecting hair follicles in a Blaschkoid distribution.<sup>1</sup> The genetic alterations that have been described are heterogeneous. Affected patients usually present at birth or in infancy with a band of hair with a different

From the Dermatology Service<sup>a</sup> and General Paediatrics,<sup>b</sup> KK Women's and Children's Hospital.

Funding sources: None.

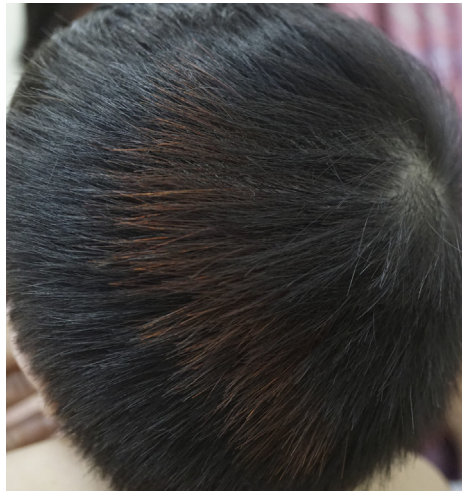Conflicts of interest: None disclosed.

Correspondence to: Mark Jean Aan Koh, MBBS, MRCPCH (UK), Dermatology Service, KK Women's & Children's Hospital, 100 Bukit Timah Road, Singapore 229899. E-mail: [Mark.koh.j.a@singhealth.com.sg](mailto:Mark.koh.j.a@singhealth.com.sg).


JAAD Case Reports 2020;6:700-1.  
2352-5126

© 2020 by the American Academy of Dermatology, Inc. Published by Elsevier, Inc. This is an open access article under the CC BY-NC-ND license (<http://creativecommons.org/licenses/by-nc-nd/4.0/>).

<https://doi.org/10.1016/j.jidcr.2020.05.028>



**Fig 1.** Photograph of left parieto-occipital scalp shows a patch of red hair following a line of Blaschko.



**Fig 2.** Light microscopy of the red-colored hair shows homogeneously decreased pigmentation (A) compared with the patient's normal hair (B). (Original magnification:  $\times 40$ .)

color compared to the patient's normal hair. The cases described by Restano et al<sup>1</sup> included a boy with 2 stable bands of darker hair on vertex and nuchal area, a boy with long narrow band of blond hair horizontally on left parietal and occipital area, and a girl with widespread pigmentary mosaicism and broad bands of scalp hair heterochromia, associated with other systemic abnormalities including scoliosis and speech delay.<sup>1</sup> The cases described by Iorizzo et al<sup>6</sup> included a boy with circular band of lighter hair along the crown of the scalp and a girl with multiple bands of brown hair from the vertex whorl.<sup>6</sup> Dumitrascu et al<sup>2</sup> described a girl with reddish streaks of scalp hair, heterochromia of eyelashes, and cutaneous pigmentary mosaicism. The condition remains stable as the child grows. Patients presenting with scalp heterochromia should, however, be assessed for associated cutaneous, neurologic or systemic conditions.

Here we present a rare case of heterochromia of scalp hair in a Blaschkoid distribution in

an infant. This form of hair heterochromia is thought to be a variant of pigmentary mosaicism. Extensive investigations is unnecessary in these patients apart from a thorough history and physical examination.

#### REFERENCES

1. Restano L, Barbareschi M, Cambiaghi S, Gelmetti C, Ghislanzoni M, Caputo R. Heterochromia of the scalp hair: a result of pigmentary mosaicism? *J Am Acad Dermatol* 2001; 45(1):136-139.
2. Dumitrascu CI, Hoss E, Hogeling M. Heterochromia of the hair and eyelashes with Blaschkoid dyspigmentation. *Pediatr Dermatol*. 2016;33(2):e121-e122.
3. Castelo-Soccio LA. Hair manifestations of systemic Disease. *Curr Probl Pediatr Adolesc Health Care*. 2012;42(8):198-203.
4. Lee WS, Lee W, Ahn SK. Diffuse heterochromia of scalp hair. *J Am Acad Dermatol*. 1996;35(5):823-825.
5. Happle R. Mosaicism in human skin. Understanding the patterns and mechanisms. *Arch Dermatol*. 1993;129(11): 1460-1470.
6. Iorizzo M, Piraccini BM, Tosti A. Heterochromia of the scalp hair following Blaschko lines. *Pediatr Dermatol*. 2007;24(1): 69-70.