



Case report

Two non-small cell lung cancer (NSCLC) patients with brain metastasis harboring epidermal growth factor receptor (EGFR) G719X and L861Q mutations benefited from aumolertinib: two cases report and review of the literature

Lin Li^{*}

Jiangxi Cancer Hospital, China

ARTICLE INFO

Keywords:

Aumolertinib
 Epidermal growth factor receptor (EGFR)
 G719X and L861Q mutation
 Non-small cell lung cancer (NSCLC)
 Case report
 Brain metastases (BMS)

ABSTRACT

The third-generation epidermal growth factor receptor (EGFR)-tyrosine kinase inhibitors (TKIs) established a new standard for EGFR mutation positive non-small cell lung cancer (NSCLC) treatment. Brain metastases (BMS) are common in NSCLCs with poor prognosis, and patients with BMS who carry uncommon mutations is lack of treatment options. Aumolertinib is the first third-generation EGFR TKI in China and the second in the global context. There are few reports of the efficacy of aumolertinib in treating NSCLC patients with BMS who harboring uncommon EGFR mutations, which is needs to be investigated. Here we reported two cases of aumolertinib in treating NSCLC patients with BMS harboring EGFR G719X/L861Q mutations. The first one was diagnosed with poorly differentiated stage IVB adenocarcinoma with brain metastases. Genetic tests showed mutations in exons of EGFR 18 (G719D) and 21 (L861Q) initially. The patient was administered with pemetrexed 0.8 g and lobaplatin 30 mg, and aumolertinib (110 mg QD) combined with one-month of WBRT(Whole Brain Radiation Therapy) (42 Gy in 7 fractions). In order to avoid the side effects of radiotherapy on brain, radiotherapy was discontinued on February 5, 2020. The regime was continued with pemetrexed 0.75 g, lobaplatin 30 mg, bevacizumab 400 mg, and aumolertinib 110 mg QD. The four-drug combination regimen lasted for 6 months until serum tumor markers were elevated slightly. Then lobaplatin was replaced with nedaplatin, and the new four-drug combination regimen (pemetrexed 0.75 g, nedaplatin 90mg, bevacizumab 400 mg, and aumolertinib 110mg QD) was used with a one-month cycle for 3 cycles. Aumolertinib was administered daily throughout the four-drug combination, with the rest administered on day 1 of this treatment cycle. Chest CT scan were performed each month, which showed no progressed of lung disease. The patient had a progression-free survival of 13 months and is still being treated with aumolertinib. The second patient was diagnosed as right lung adenocarcinoma (T3N2M1) IVB secondary bone and brain malignancy carrying EGFR 18 (G719A) and 21 (L861Q) exon mutation. Aumolertinib combined with local radiotherapy was used after failure of afatinib combined with radiotherapy. Follow-up chest CT and brain MRI revealed that the lung lesions were partially relieved. Furthermore, the multiple nodules in the brain were relieved and cerebral edema was reduced. The aumolertinib monotherapy was continued, and follow-up imaging showed no disease progression. PFS was 13 months during the treatment with aumolertinib. The two cases showed good efficacy of aumolertinib in treating patients with brain metastases (BMS) that harbored EGFR 18 (G719X) and 21 (L861Q) mutations.

1. Introduction

Morbidity and mortality of lung cancer are increasing in most countries [1], NSCLC accounts for 85% of the common subtypes of lung cancer [2]. The central nervous system (CNS) is a frequent site of metastases in

non-small cell lung cancer, with an incidence of about 50%, and higher incidence in patients with EGFR mutated NSCLC, which reduces the quality of life of patients, and related to poor prognosis [3]. As a driver oncogenes, EGFR mutations, the incidence went up to 51.4% in advanced NSCLC patients from unselected Asian patients with adenocarcinoma [4].

^{*} Corresponding author.

E-mail address: wxy_sky@163.com.

<https://doi.org/10.1016/j.heliyon.2022.e10407>

Received 23 May 2022; Received in revised form 29 July 2022; Accepted 19 August 2022

2405-8440/© 2022 The Author(s). Published by Elsevier Ltd. This is an open access article under the CC BY-NC-ND license (<http://creativecommons.org/licenses/by-nc-nd/4.0/>).

Aumolertinib, a novel third-generation EGFR-TKI which prolongs the PFS of EGFR-positive patients who previously untreated to 19.3 months [5], has been proved to have a good effect on patients with brain metastasis. In addition to common gene mutations such as L858R mutation and exon 19 deletion, uncommon EGFR mutation genes attract our attention as well, which accounts for 4%–13% in EGFR gene mutations including a heterogeneous group of molecular alterations within exons 18 to 21 (L861Q, 3%; T790M, 3%; G719X, 5%; exon 20 insertion, 3% and S768I, 1%) [6, 7]. However, the efficacy and safety of aumolertinib for treating patients with NSCLC induced BMS who carry uncommon EGFR mutations have not been determined. Here, we present the management of two patients with brain metastases that harbored L861Q and G719X. It is the first report providing clinical evidence of progression free survival benefit from aumolertinib 110 mg q.d.

2. Case presentation

A 48-year-old female patient was admitted to Jiangxi Cancer Hospital with persistent cough and bloody sputum. The patient had no prior tumor. Chest computed tomography (CT) scan revealed nodules in the anterior segment of the upper lobe of the left lung, considering the possibility of peripheral lung cancer with metastasis to both lungs (Figure 1). Ultrasound Doppler showed no obvious enlarged lymph nodes in the double neck or double clavicle, but a small amount of effusion in the left pleural cavity. The radionuclide bone scan reveals normal. Metastatic tumors in the left basal ganglia and cerebellar vermis was considered and metastases and cavernous hemangiomas in the right cerebellum showed by Magnetic resonance imaging (MRI) (Figure 2).

Puncture biopsy of the right lung lesion, Pathology and Immunohistochemistry (IHC) of tumor revealed poorly differentiated adenocarcinoma with CK(+), CK5/6 (-), P40 (-), CK7(+), P63 (-), TTF-1 (+), CD56 (-), CgA(-), Syn (-), Ki67(+), which indicated that the brain metastasis (BM) had originated from lung adenocarcinoma. Genetic tests showed EGFR 18 (G719D) and 21 (L861Q) exon mutations and EGFR amplification. Taking into account age, gene mutation form, and imaging findings, we believe that the patient is a refractory non-small cell lung cancer with poor prognosis, high malignancy, and strong aggressiveness. cT1bN2M1c.

Accordingly, the patient was administered with pemetrexed 0.8g and lobaplatin 30mg initially, and meantime aumolertinib (110 mg QD) combined with WBRT (42 Gy in 7 fractions) was administered on 4 August, 2020. Then, simultaneous administration of pemetrexed 0.75g, lobaplatin 30mg, bevacizumab 400mg, and aumolertinib 110mg QD on September 12, October 13, November 5, December 1, December 31 and January 30, 2021, during which led to the shrinkage of all brain lesions. In September, MRI plain scan of the brain indicated that multiple lesions in the brain were reduced (Figure 3) and Chest CT in October (Figure 4) and November (Figure 5) also showed that the nodules in the upper left lung had shrunk, partial response (PR) was achieved.

Follow-up CT in January 2021 showed no significant changes in the upper left lung compared to November 2020, and the lesion was in remission (Figure 6). MRI showed that the intracranial lesions continued to show remission (January 2021) (Figure 7), Follow-up positron emission tomography (PET)-CT showed no clear space-occupying lesions in the brain parenchyma, but there are still irregular nodules in the anterior segment of the left upper lobe (February 2021), and carcinoembryonic antigen (CEA) were elevated slightly. So a new combination of four drugs (pemetrexed 0.75g, nedaplatin 90mg, bevacizumab 400mg, and aumolertinib 110mg QD) replaced the previous regimen on March 1, March 31, and May 26, 2021.

Chest CT scan were performed in March (Figure 8), April (Figure 9), and June (Figure 10), and all showed that the lung disease had not progressed; In August, the chest (Figure 11) and brain lesions (Figure 12) showed no progress as before, at this point, the patient had a progression-free survival of 13 months and the patient is still receiving treatment.

This case demonstrates the effectiveness of combination of aumolertinib in NSCLC with brain metastases who harboring EGFR 18 (G719D) and 21 (L861Q) exon mutations. Similarly, we report another case of brain metastases with EGFR 18 (G719A) and 21 (L861Q) that has satisfactory therapeutic effect in the treatment of aumolertinib.

A 66-year-old female patient was admitted because of chest and back pain and impaired movement of the lower limbs, and then was diagnosed as poorly differentiated adenocarcinoma by pathological biopsy in Jiangxi Cancer Hospital (January 2020), chest CT showed lung cancer at the lower right with intrapulmonary metastases, bony metastases, liver and left renal cysts (Figure 13). MRI showed multiple brain lesions, which were considered to be multiple brain metastases (Figure 14). A biopsy from the primary lesion was performed and diagnosed as poorly differentiated lung adenocarcinoma. Based on imaging and genetic testing, the patient was diagnosed as a right lung adenocarcinoma (pT3N2M1)IVB secondary bone and brain malignancy carrying EGFR 18 (G719A) and 21 (L861Q) exon mutation. Pemetrexed 0.75g combined with afatinib 30mg qd was performed on January 22, 2020, followed by whole brain radiotherapy (DT30GY in 10 fractions) on February 4, 2020. The original protocol was continued without radiotherapy, and the curative effect was evaluated in March, and the lung lesions were PR which revealed by chest CT plain scan (Figure 15). However, multiple intracranial metastases had progressed showed by MRI (Figure 16). So local radiotherapy was performed on the patient, and the drug regimen replace by aumolertinib 110mg QD because of it's ability to enter brain tissue. Chest CT (Figure 17) and brain MRI (Figure 18) were performed in April and May, respectively. The lung lesions were partially relieved, meanwhile, the multiple nodules in the brain were relieved and cerebral edema was reduced, Therefore, aumolertinib monotherapy followed, follow-up chest CT scans were performed in June (Figure 19) and July (Figure 20) 2020 which showed a significant efficacy, brain MRI in July also showed remission (Figure 21), then aumolertinib monotherapy continued until April 2021, during which follow-up imaging showed no

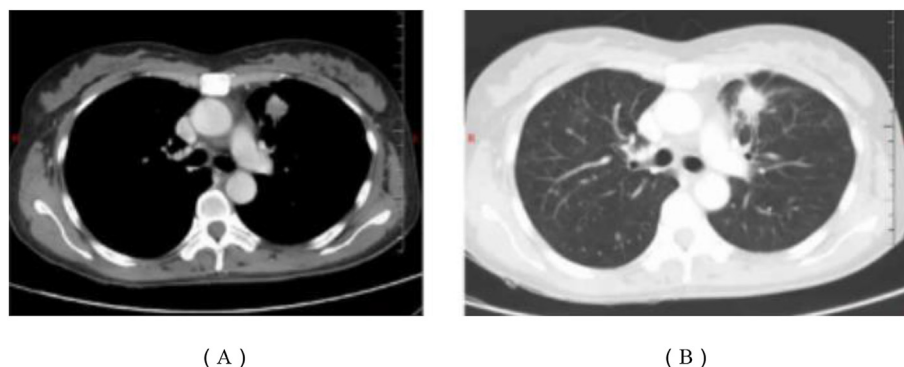


Figure 1. (A, B) Baseline CT scan at diagnosis in August 2020.

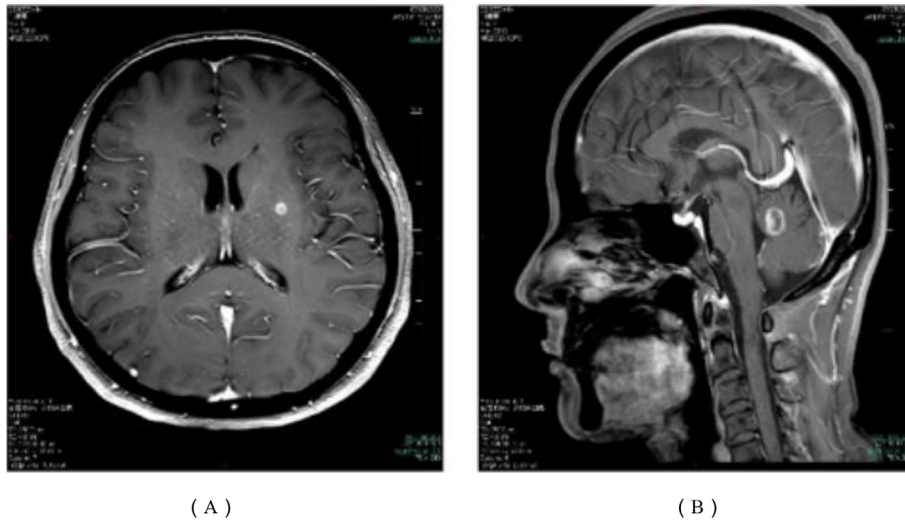


Figure 2. (A, B) MRI cranial plain scan and enhanced scan in September 2020.

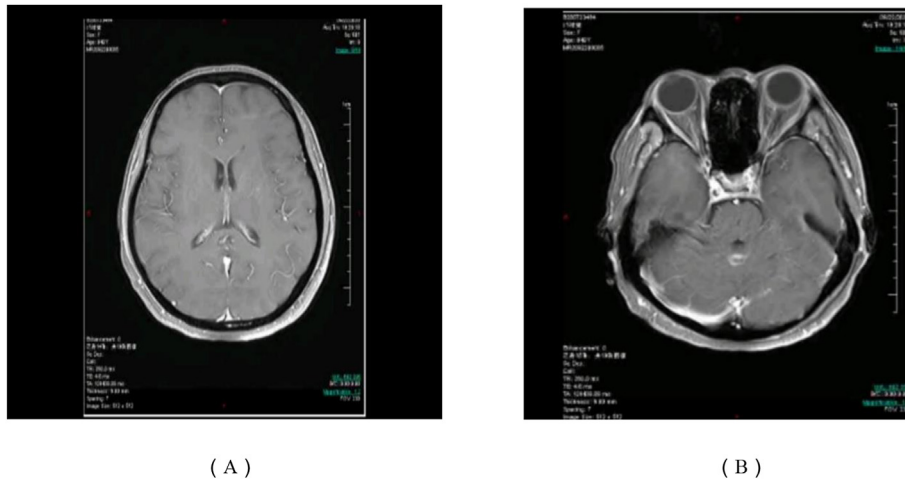


Figure 3. (A, B) MRI plain scan of the brain in October 2020 indicated that multiple lesions in the brain were reduced.

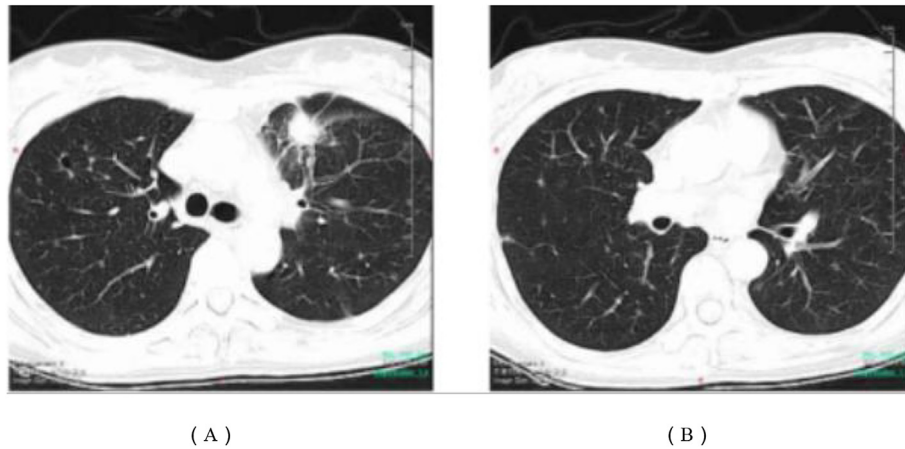


Figure 4. (A, B) PR in October 2020.

disease progression (Figure 22). PFS has been 13 months during the treatment with aumolertinib since March 2020. Informed consent has been obtained in this two cases.

3. Discussion

We have here shown the clinical efficacy of aumolertinib in two patients with NSCLC positive for G719X/L861Q mutations of EGFR as well

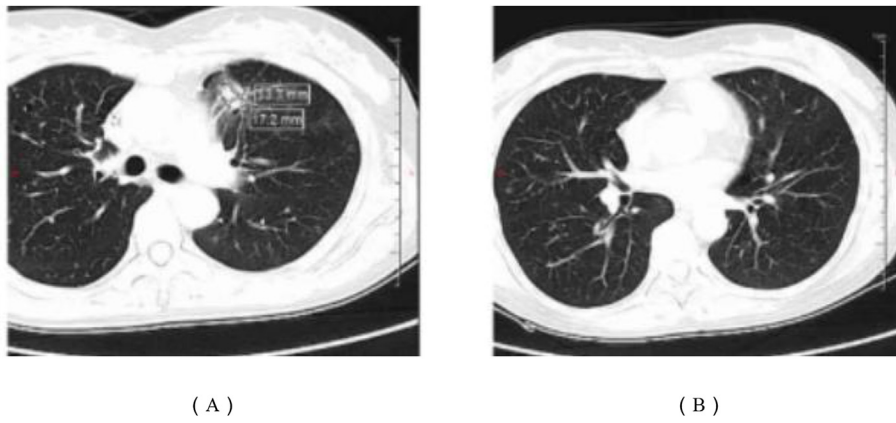


Figure 5. (A, B) PR in November, 2021.

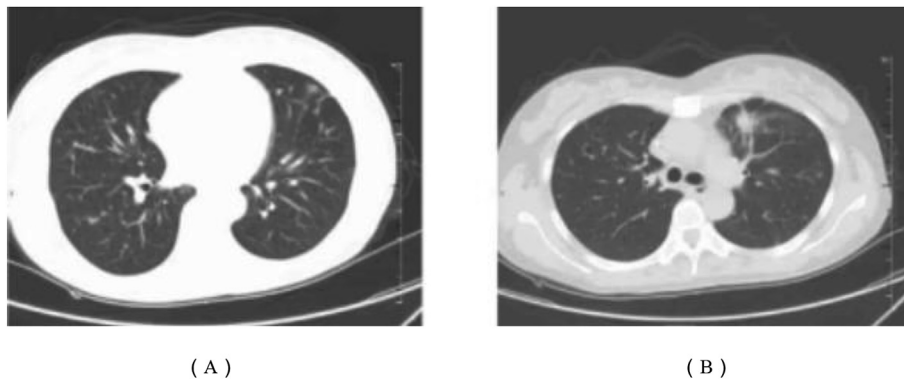


Figure 6. (A, B) PR in January, 2021.

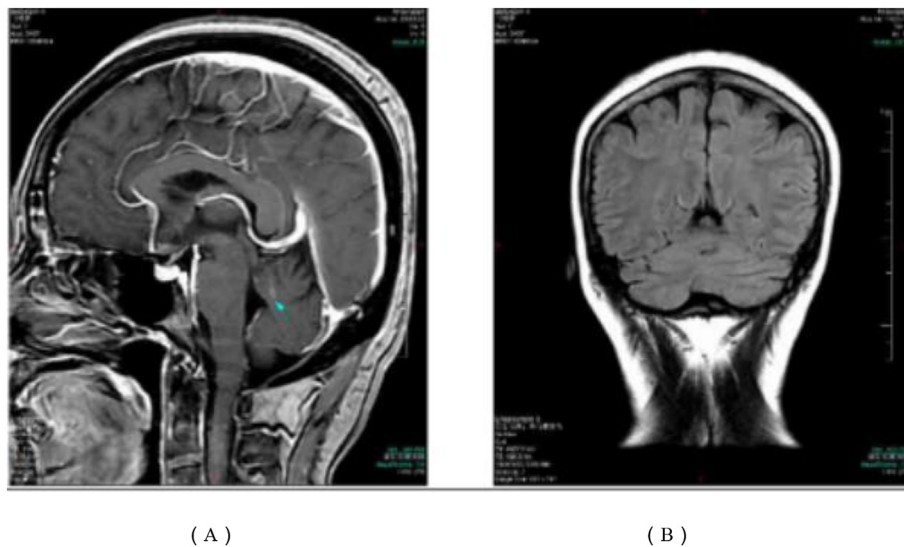


Figure 7. (A, B) MRI in January 2021 showed that the intracranial lesions continued to show remission.

as for brain metastases, three similarities between these two cases: (1) they're both NSCLC with brain metastases, and (2) the tumor harbored two uncommon EGFR mutations, (3) pulmonary lesions and brain metastases were in remission with aumolertinib monotherapy or combination therapy, and two patients also had PFS for 13 months.

Frequency of brain metastases is reported in 40–60% of cases of EGFR mutated non-small cell lung cancer [8, 9], once BMS develop in patients with NSCLC, the median overall survival (OS) is only approximately 6

months [10, 11], the treatment strategy for EGFR-mutant NSCLC with BMS has been revolutionized by EGFR-targeted therapy, and the different permeability of blood–brain barrier (BBB) of various TKIs may affects their individual efficacy in treating patients with BMS. Aumolertinib is an irreversible, novel third-generation small-molecule EGFR-TKI with high inhibitory activity against EGFR with common activating mutations as well as the T790M resistance mutation [12, 13]. Aumolertinib exhibited good control over central nervous system (CNS) metastases, from the

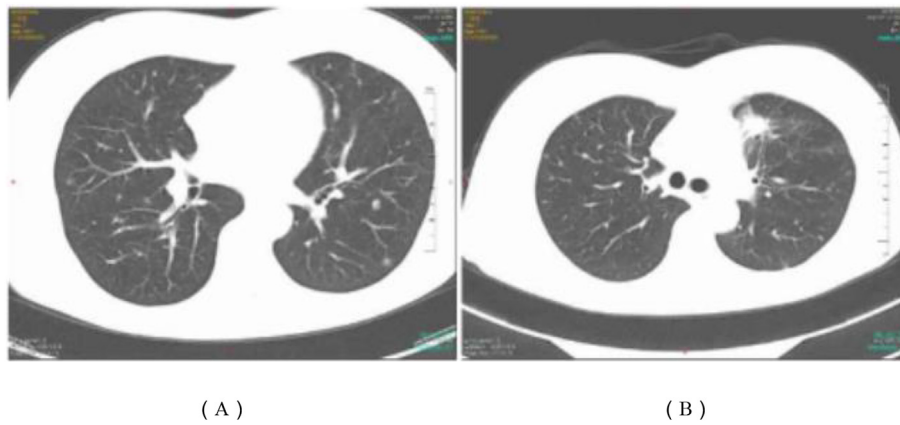


Figure 8. (A, B) Chest CT scan in March 2021 showed that the lung disease had not progressed.

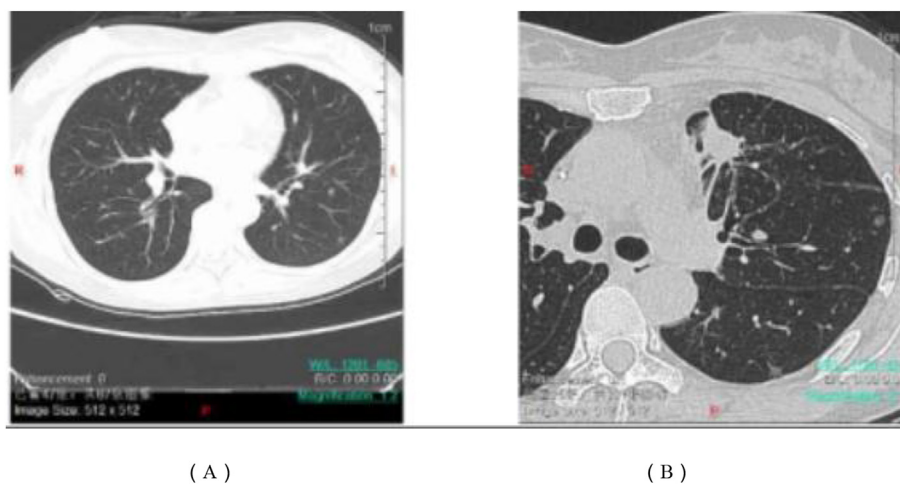


Figure 9. (A, B) Chest CT scan in April 2021 showed that the lung disease had not progressed.

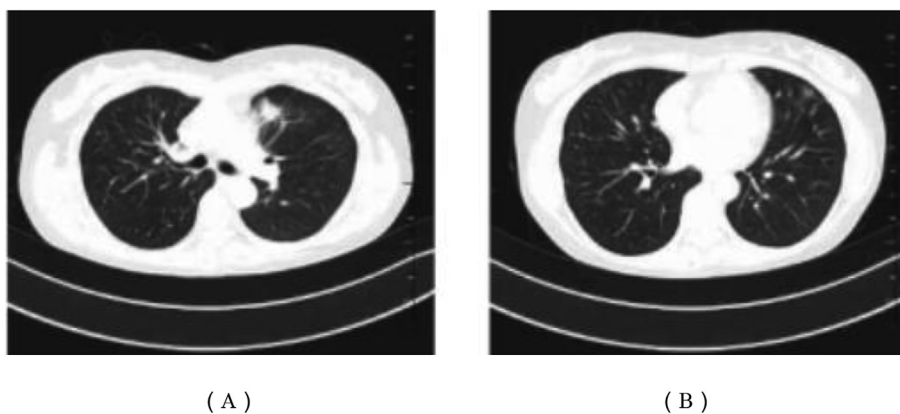


Figure 10. (A, B) Chest CT scan in June 2021 showed that the lung disease had not progressed.

data of single-arm, phase II APOLLO trial (NCT02981108), 23 of 91 patients with brain metastases had lesions that were evaluated by Independent Review Committee (ICR). the objective response rate (ORR) of intracranial tumours was 60.9% (95% CI, 38.5–80.3%). CNS disease control rate was 91.3%, and the median CNS PFS was 11.8 months [14]; The lipophilicity of the cyclopropyl group may prompt aumolertinib improve BBB permeability and thus enhance the curative effect for BMS of NSCLC. Aumolertinib's excellent efficacy in the treatment of brain metastases was revalidated in the Phase III (NCT03849768) first-line

treatment trial, compared to the control group (Gefitinib), the intracranial tumours PFS risk ratio observed between patients with brain metastases (HR, 0.38; 95% CI, 0.24–0.60) and non-brain metastases (HR, 0.51; 95% CI, 0.38–0.69) [5].

Missense mutations in exon 18 of EGFR gene 719 occur in approximately 3% of all known EGFR mutations [15, 16, 17], L861Q in exon 21 is a uncommon EGFR mutation, accounting for almost 2% of all EGFR mutations [18]. There is currently a lack of uniform standard therapy for uncommon EGFR mutations in NSCLC. Afatinib is used clinically in

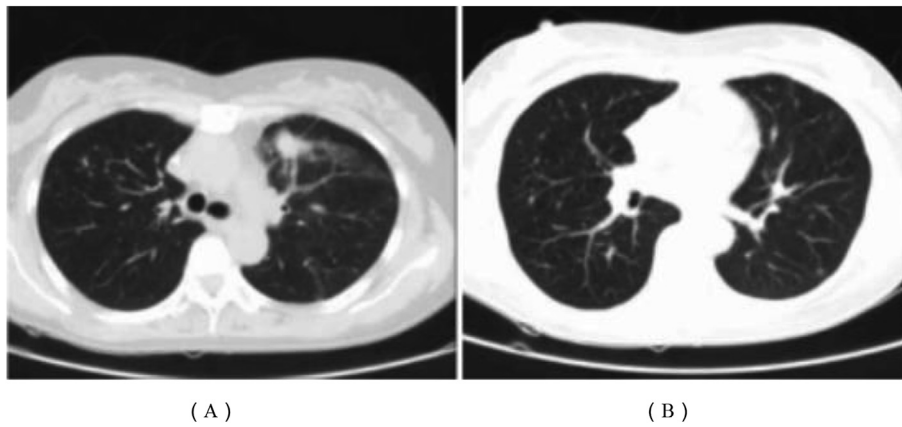


Figure 11. (A, B) Chest CT scan in August 2021 showed that the lung disease had not progressed.

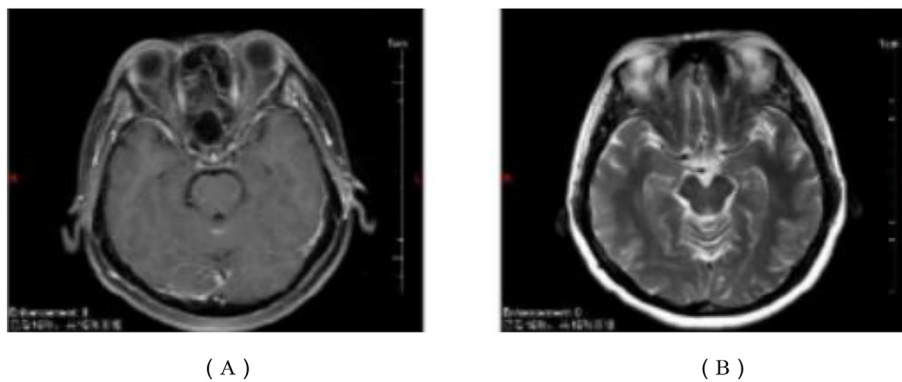


Figure 12. (A, B) MRI in August 2021 showed that the intracranial lesions continued to show remission.

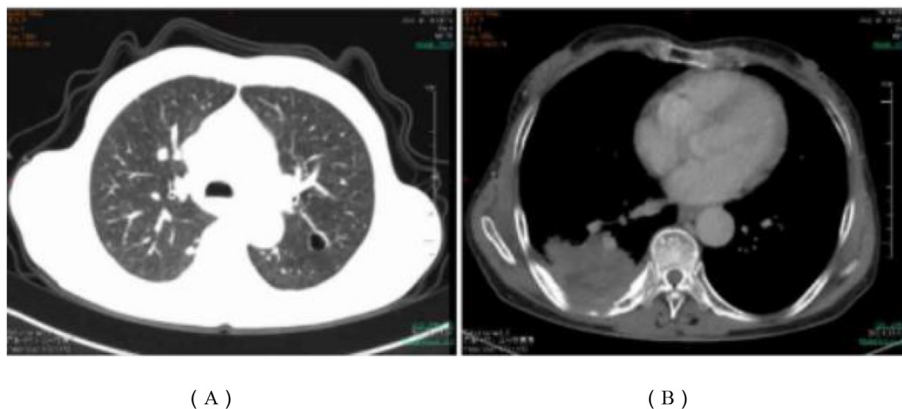


Figure 13. (A, B) Baseline CT scan at diagnosis in January 2020.

patients with uncommon mutations, in a pooled analysis of patients with uncommon mutations, afatinib showed efficacy in patients with NSCLC harboring the G719X, L861Q, median PFS was 13.8 months for patients with tumors harboring G719X and 8.2 months for L861Q [19]. In a combined analysis of the LUX-Lung 3 and 6 studies, patients with brain metastases at baseline who treated with afatinib compared to chemotherapy showed improved PFS 8.2 vs 5.4 months [20]; But fewer treatments are available when NSCLC patients with BMS who harbored EGFR G719X/L861Q mutations. The clinical activity of aumolertinib in NSCLC patients with uncommon EGFR mutations has never been reported before. Our two cases provides further clinical evidence for the

administration of aumolertinib at 110 mg QD for treating NSCLC patients with BMS harboring EGFR G719X/L861Q mutations.

Based on the structure of the third-generation EGFR-TKI aminopyridine core and Michael addition acceptor [21], aumolertinib introduces cyclopropyl for structural optimization. The introduction of cyclopropyl improved the metabolic stability and receptor subtype selectivity of aumolertinib, and increased the blood-brain barrier permeability of aumolertinib [21]. A Phase II registration study of aumolertinib included 88 asymptomatic patients with BMS, 23 of whom had measurable intracranial target lesions, with intracranial ORR and DCR of 60.9% and 91.3%, respectively, the median intracranial PFS was

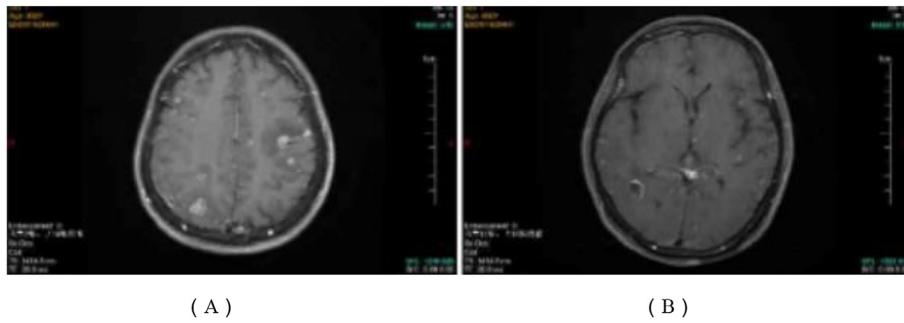


Figure 14. (A, B) MRI in January 2020 showed multiple brain lesions.

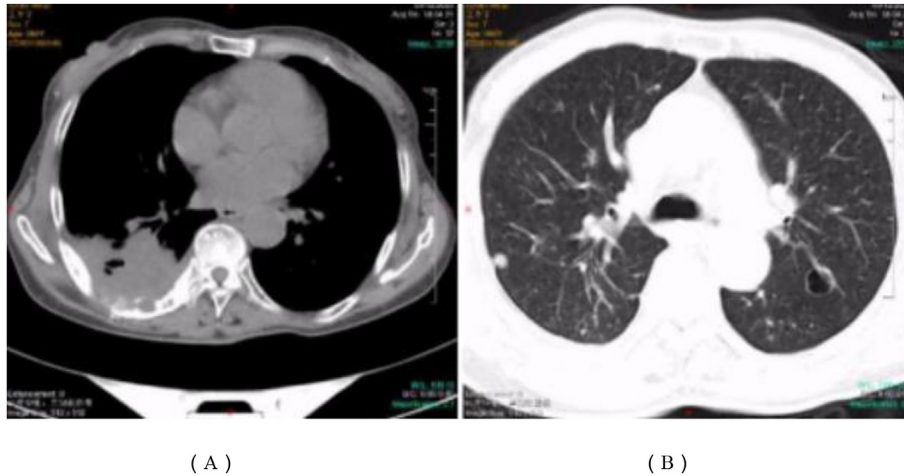


Figure 15. (A, B) Chest CT plain scan in March 2020.

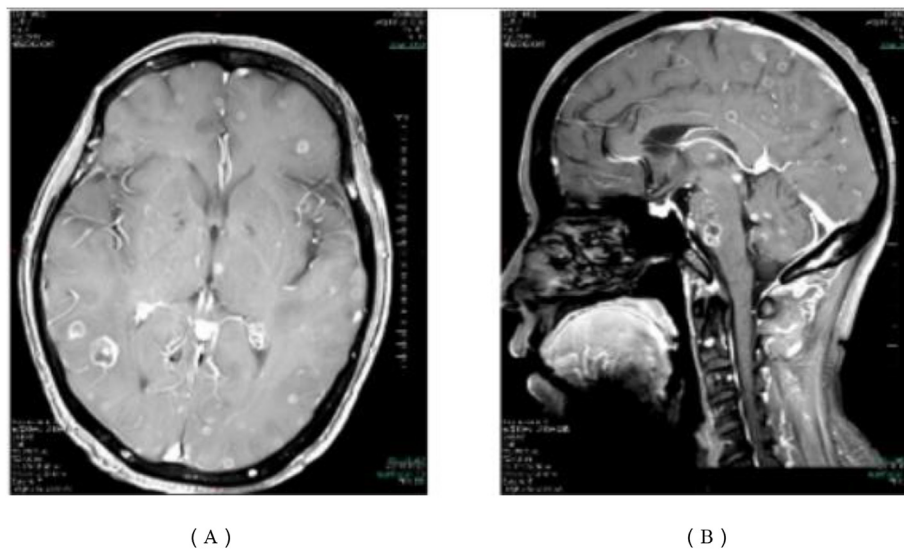


Figure 16. (A, B) multiple intracranial metastases had progressed showed by MRI in March 2020.

11.8 months and OS was 16.2 months [22]. The BMS antitumor activity of aumolertinib may be related to the fact that it is not a substrate for p-glycoprotein (P-gp) or breast cancer resistance protein (BCRP) [23] which prevent the entry of agents into the interstitial space of the brain [24]. Moreover, four patients with uncommon mutations were included in the study, and three of them had partial disease remissions (PR), which

suggests that aumolertinib has antitumor activity in both NSCLC with BMS and uncommon EGFR mutations [22].

In summary, we have reported two case of successful treatment of EGFR L861Q/G719X positive and brain metastases NSCLC with aumolertinib, which benefited our patient so that they both have a PFS of 13 months. This is the first reported cases of aumolertinib for NSCLC

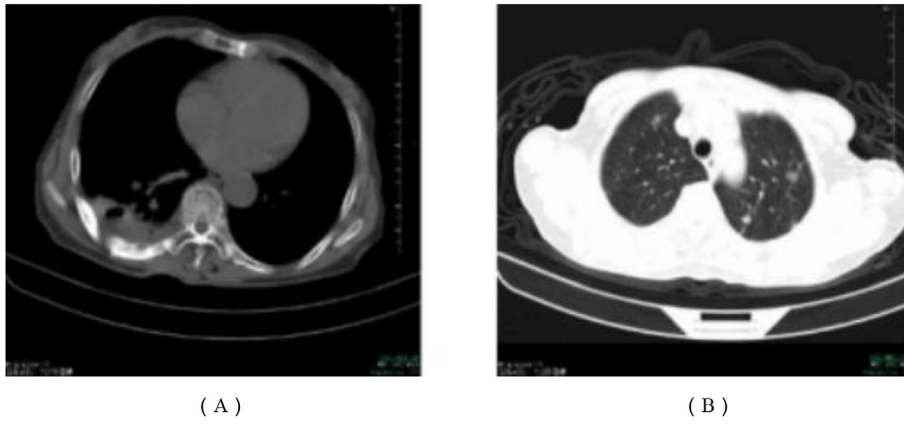


Figure 17. (A, B) Chest CT in April showed that the lung lesions were partially relieved.

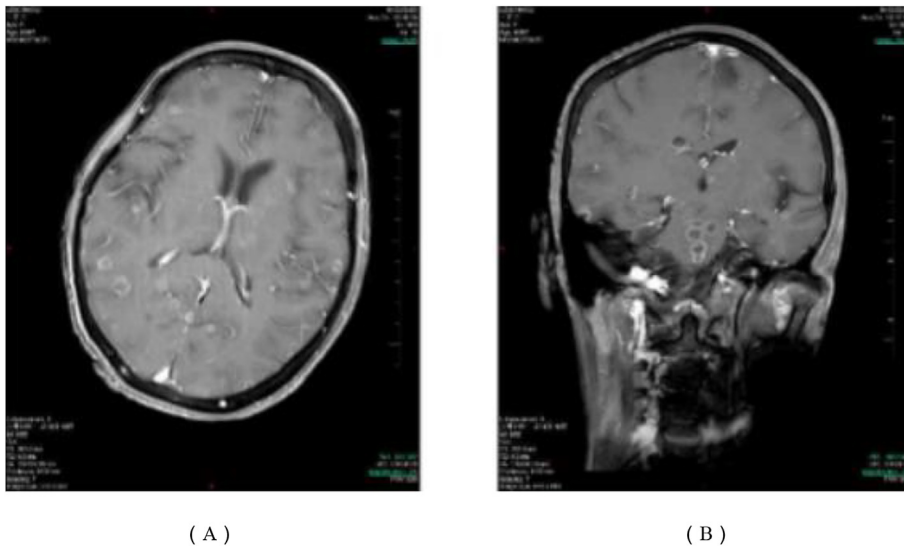


Figure 18. (A, B) Brain MRI in May showed that the lesions were partially relieved.

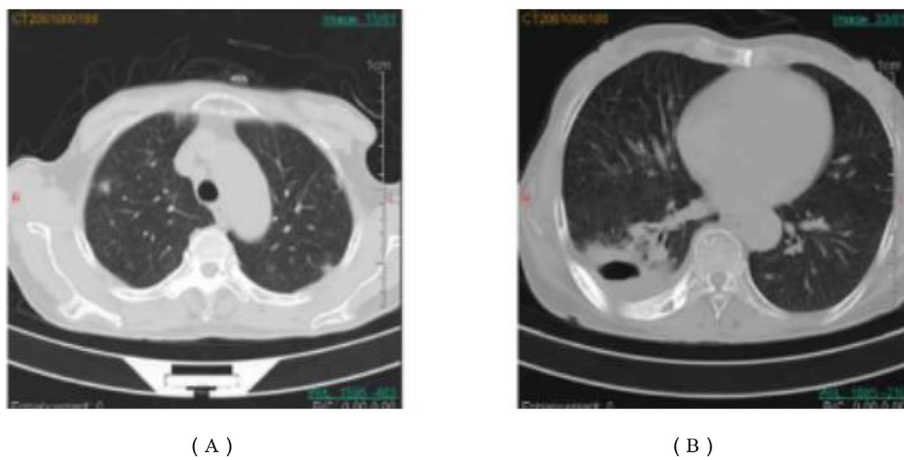
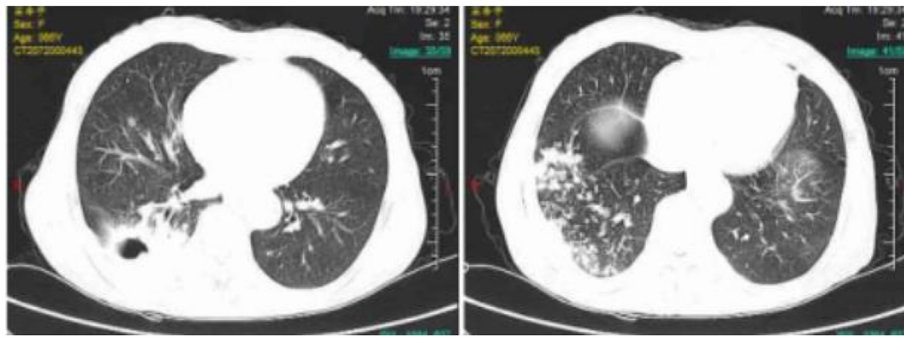


Figure 19. (A, B) Follow-up chest CT scans in June 2020 showed a significant efficacy.

patients with BMS harboring EGFR G719X/L861Q mutations, indicating a potential treatment option in the clinic. Aumolertinib in the treatment of NSCLC harboring uncommon mutations or brain metastases are both being studied, which may provide a better basis for the treatment of these patients.

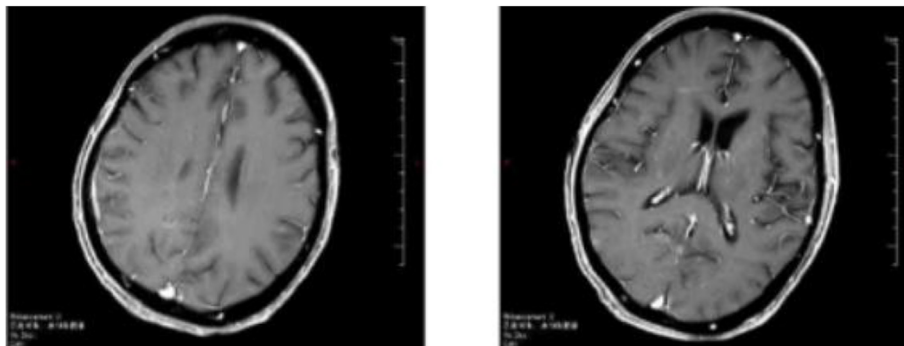
We are highly grateful to Mrs Fei Huang and Mr. Gang Xiao from the Medical Oncology Scientific Group of the Central Medical Department, Jiangsu Hansoh Pharmaceutical Group Co., Ltd. for their technical support in the accomplishment of this study.



(A)

(B)

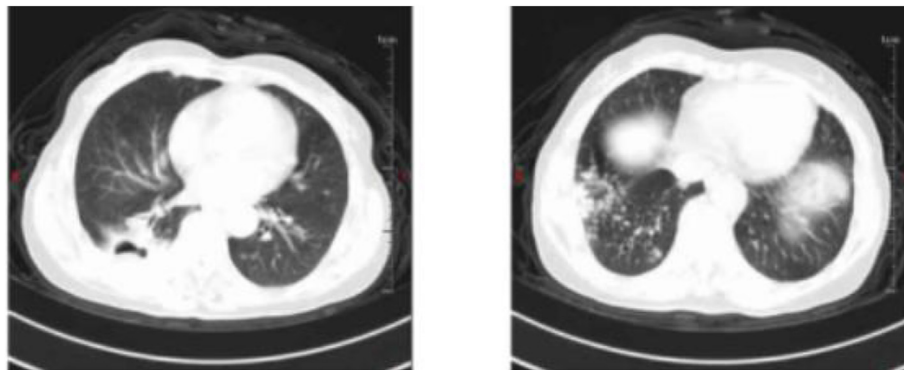
Figure 20. (A, B) Follow-up chest CT scans in July 2020 showed a significant efficacy.



(A)

(B)

Figure 21. (A, B) Brain MRI in July 2020 showed remission.



(A)

(B)

Figure 22. (A, B) Follow-up imaging showed no disease progression.

Declarations

Author contribution statement

All authors listed have significantly contributed to the investigation, development and writing of this article.

Funding statement

This research did not receive any specific grant from funding agencies in the public, commercial, or not-for-profit sectors.

Data availability statement

Data included in article/supp. material/referenced in article.

Declaration of interests statement

The authors declare no conflict of interest.

Additional information

No additional information is available for this paper.

References

- [1] Hyuna Sung, Jacques Ferlay, L. Rebecca, et al., Global cancer statistics 2020: GLOBOCAN estimates of incidence and mortality worldwide for 36 cancers in 185 countries, *CA CANCER J CLIN* 71 (3) (2021) 209–249.
- [2] R.L. Siegel, K.D. Miller, A. Jemal, et al., Cancer statistics, *CA Cancer J Clin* 68 (1) (2018) 7–30.
- [3] C.S. Tan, B.C. Cho, R.A. Soo, Treatment options for EGFR mutant NSCLC with CNS involvement-Can patients BLOOM with the use of next generation EGFR TKIs? *Lung Cancer* 108 (2017) 29–37.
- [4] Y. Shi, J.S. Au, S. Thongprasert, et al., A prospective, molecular epidemiology study of EGFR mutations in Asian patients with advanced non-small-cell lung cancer of adenocarcinoma histology (PIONEER), *J. Thorac. Oncol.* 9 (2014) 154–162.
- [5] S. Lu, X.R. Dong, H. Jian, et al., Randomized phase III trial of aumolertinib (HS-10296, Au) versus gefitinib (G) as first-line treatment of patients with locally advanced or metastatic non-small cell lung cancer (NSCLC) and EGFR exon 19 del or L858R mutations (EGFRm), *Journal of Clinical Oncology* 39 (15 suppl) (2021).
- [6] E. Massarelli, F.M. Johnson, H.S. Erickson, et al., Uncommon epidermal growth factor receptor mutations in non-small cell lung cancer and their mechanisms of EGFR tyrosine kinase inhibitors sensitivity and resistance, *Lung Cancer* 80 (2013) 235–241.
- [7] G.M. O'Kane, P.A. Bradbury, R. Feld, et al., Uncommon EGFR mutations in advanced non-small cell lung cancer, *Lung Cancer* 109 (2017) 137–144.
- [8] T. Iuchi, et al., Frequency of brain metastases in non-small-cell lung cancer, and their association with epidermal growth factor receptor mutations, *Int J Clin Oncol* 20 (4) (2015 Aug) 674–679.
- [9] M. Schuler, Y.L. Wu, et al., First-line afatinib versus chemotherapy in patients with non-small cell lung cancer and common epidermal growth factor receptor gene mutations and brain metastases, *J Thorac Oncol* 11 (3) (2016 Mar) 380–390.
- [10] J. Sanchez de Cos, M.A. Sojo Gonzalez, M.V. Montero, et al., Non-small cell lung cancer and silent brain metastasis. Survival and prognostic factors, *Lung Cancer* 63 (2009) 140–145.
- [11] P.W. Sperduto, S.T. Chao, P.K. Sneed, et al., Diagnosis-specific prognostic factors, indexes, and treatment outcomes for patients with newly diagnosed brain metastases: a multi-institutional analysis of 4,259 patients, *Int J Radiat Oncol Biol Phys* 77 (2010) 655–661.
- [12] Jiangsu Hansoh Pharmaceutical Group, Aumolertinib Mesylate: Chinese Prescribing Information, 2020. <http://www.hansoh.cn/product/15102.htm>. (Accessed 3 May 2020).
- [13] J.C.-H. Yang, D.R. Camidge, C.-T. Yang, et al., HS-10296 – a novel third generation EGFR tyrosine kinase inhibitor: results of the first-in-human phase 1 trial in patients with previously treated EGFR mutant advanced non-small-cell lung cancer, *Lancet Oncol* 15 (12) (2020) P1907–1918.
- [14] S. Lu, Q. Wang, G. Zhang, et al., A multicenter, open-label, single-arm, phase II study: the third generation EGFR tyrosine kinase inhibitor Aumolertinib for pretreated EGFR T790M-positive locally advanced or metastatic non-small cell lung cancer (APOLLO), *Cancer Research* 80 (16 suppl) (2020).
- [15] T. Mitsudomi, Y. Yatabe, Epidermal growth factor receptor in relation to tumor development: EGFR gene and cancer, *FEBS J* 277 (2010) 301–308.
- [16] T.J. Lynch, D.W. Bell, R. Sordella, et al., Activating mutations in the epidermal growth factor receptor underlying responsiveness of non-small-cell lung cancer to gefitinib, *N Engl J Med* 350 (2004) 2129–2139.
- [17] E.P. Brandão, M.G. Pantarotto, M. Cruz, A novel EGFR mutation in exon 18 with high sensitivity to EGFR TKI treatment with reduced dose, *J Thorac Oncol* 7 (2012) e32.
- [18] T. Zhang, B. Wan, Y. e a Zhao, Treatment of uncommon EGFR mutations in non-small cell lung cancer: new evidence and treatment, *Transl Lung Cancer Res* 8 (3) (2019) 302–316.
- [19] J.C. Yang, L.V. Sequist, S.L. Geater, et al., Clinical activity of afatinib in patients with advanced non-small-cell lung cancer harbouring uncommon EGFR mutations: a combined post-hoc analysis of LUX-Lung 2, LUXLung 3, and LUX-Lung 6, *Lancet Oncol* 16 (2015) 830–838.
- [20] M. Schuler, Y.L. Wu, V. Hirsh, et al., First-Line afatinib versus chemotherapy in patients with non-small cell lung cancer and common epidermal growth factor receptor gene mutations and brain metastases, *J Thorac Oncol* 11 (2016) 380–390.
- [21] D.A. Cross, S.E. Ashton, S. Ghiorghiu, et al., AZD9291, an irreversible EGFR TKI, overcomes T790M-mediated resistance to EGFR inhibitors in lung cancer, *Cancer Discov* 4 (9) (2014) 1046–1061, 21. Talele TT. The "Cyclopropyl Fragment" is a Versatile Player that Frequently Appears in Preclinical/Clinical Drug Molecules. *J Med Chem.* 2016;59(19):8712-8756.
- [22] Shun Lu, Qiming Wang, Guojun, et al., Efficacy of aumolertinib (HS-10296) in patients with advanced EGFR T790M+ NSCLC: updated post NMPA-approval results from the APOLLO registrational trial, *J Thorac Oncol* (2021 Nov 18). S1556-0864(21)03323-2.
- [23] Jiangsu Hansoh Pharmaceutical Group, Aumolertinib Mesylate: Chinese Prescribing Information, 2020. <http://www.hansoh.cn/product/15102.htm>. (Accessed 3 May 2020).
- [24] R. Soffietti, M. Ahluwalia, N. Lin, et al., Management of brain metastases according to molecular subtypes, *Nat Rev Neurol* 16 (10) (2020) 557–574.