

# Repeated cardiac arrest caused by an air embolism during hepatic resection

## A case report

Li-Hui Luo, MM, Zhi-You Peng, MM, Sheng-Mei Zhu, MD, Yong-Xing Yao, MD\*

### Abstract

**Rationale:** Although venous air embolism (VAE) during liver operation has been reported occasionally, fatal VAE in hepatic resection is uncommon. Prompt detection of VAE by transesophageal echocardiography (TEE) is crucial for effective therapy. We describe a case of fatal VAE that caused repeated cardiac arrest during hepatic resection and was confirmed by TEE.

**Patient concerns:** A 51-year-old woman with a body weight of 50 kg underwent partial liver resection due to intrahepatic duct calculus. She had a 1-year history of intrahepatic duct calculus without cardiopulmonary disease. The operation was performed under general anesthesia combined with epidural block. When the inferior vena cava was compressed, the  $P_{et}CO_2$  level decreased abruptly from 30 to 10 mmHg, followed by a decrease in  $SpO_2$  and the development of hypotension. Her heart rate increased with ST interval elevation on electrocardiography monitoring. Ephedrine and phenylephrine were administered immediately but had little effect. Cardiac arrest occurred.

**Diagnoses:** Air embolism was detected by TEE.

**Interventions:** Resuscitation was successful although cardiac arrest occurred repeatedly.

**Outcomes:** The patient returned to consciousness 6 hours postoperatively but died of multiorgan dysfunction 10 days later.

**Lessons:** Fatal air embolism may happen during hepatic resection. Prompt detection of VAE by TEE is crucial for effective therapy and should always be available during hepatic resection.

**Abbreviations:** TEE = transesophageal echocardiography, VAE = venous air embolism.

**Keywords:** air embolism, hepatic resection, transesophageal echocardiography

## 1. Introduction

Fatal venous air embolism (VAE) in hepatic resection is uncommon although VAE during liver operations has been reported.<sup>[1–3]</sup> VAE occurs in hepatic resection due to an opened hepatic vein or surgical compression of the inferior vena cava (IVC) at its junction with hepatic veins, whereby high-speed blood flow in the compressed vessel may cause air to enter the IVC via openings of small veins. Consequently, large air emboli form and enter the right atrium, causing cardiopulmonary compromise.<sup>[4,5]</sup> Symptoms range in severity from dyspnea to cardiac arrest, and mortality rate may be up to 50%.<sup>[6,7]</sup> Prompt detection of VAE by transesophageal echocardiography (TEE) is crucial for effective therapy.<sup>[8–10]</sup> We describe a case of fatal VAE

that caused repeated cardiac arrest during hepatic resection and was confirmed by TEE.

## 2. Case presentation

The case was reviewed by the Ethical Committee Board of First Affiliated Hospital, Zhejiang University School of Medicine and consent was obtained by an authorized relative of the patient. A 51-year-old woman (weight 50 kg; American Society of Anesthesiologists' status II) underwent partial liver resection due to intrahepatic duct calculus. She had a 1-year history of intrahepatic duct calculus without cardiopulmonary disease. She underwent cholecystectomy and endoscopic retrograde cholangiopancreatography 16 and 2 years ago, respectively. The operation was performed under general anesthesia combined with epidural block. Anesthesia and tracheal intubation were induced with propofol, fentanyl, and vecuronium, and maintained with intravenous propofol (6 mg/kg h) and intermittent epidural ropivacaine (0.5%). Cisatracurium was used to maintain proper muscle relaxation. Volume-controlled ventilation (I:E = 1:2) was adopted to obtain an end-tidal carbon dioxide ( $P_{et}CO_2$ ) level between 30 and 40 mm Hg. Blood pressure was measured invasively from the radial artery, and oxygen saturation ( $SpO_2$ ) was monitored with a pulse oximeter. Shortly after intubation, blood gas analysis showed that partial pressure of oxygen ( $PaO_2$ ) and partial pressure of carbon dioxide ( $PaCO_2$ ) levels were 277 mm Hg and 35 mm Hg, respectively (fraction of inspired oxygen [ $FiO_2$ ] = 0.5).

Hepatic dissection using electrocautery was started after clamping the branches of the portal vein. When the inferior vena cava was compressed, the  $P_{et}CO_2$  level decreased abruptly from 30 to 10 mm Hg, followed by a decrease in  $SpO_2$  (from

Editor: N/A.

The authors have no conflicts of interest to disclose.

Department of Anesthesia, First Affiliated Hospital, Zhejiang University School of Medicine, Hangzhou, PR China.

\* Correspondence: Yong-Xing Yao, Department of Anesthesia, First Affiliated Hospital, Zhejiang University School of Medicine, 79 Qingchun Road, Hangzhou, 310003, PR China (e-mail: yaoyongxing@zju.edu.cn).

Copyright © 2018 the Author(s). Published by Wolters Kluwer Health, Inc. This is an open access article distributed under the terms of the Creative Commons Attribution-Non Commercial-No Derivatives License 4.0 (CCBY-NC-ND), where it is permissible to download and share the work provided it is properly cited. The work cannot be changed in any way or used commercially without permission from the journal.

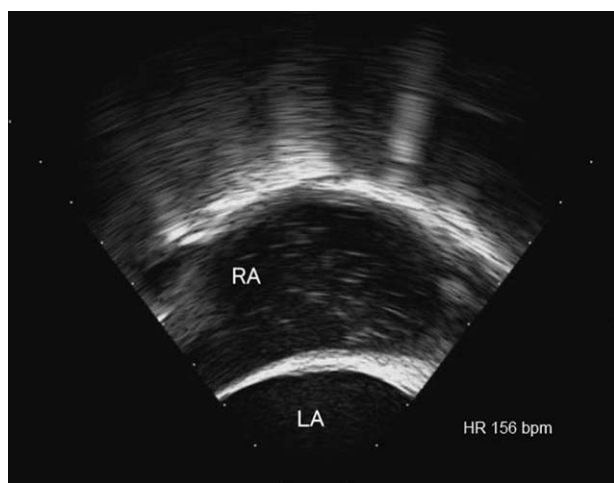
Medicine (2018) 97:39(e12639)

Received: 24 May 2018 / Accepted: 10 September 2018

<http://dx.doi.org/10.1097/MD.0000000000012639>

100% to 65%) and the development of hypotension (55–60 mm Hg). Her heart rate (HR) increased from 65 beats/min (bpm) to >100 bpm with ST interval elevation on electrocardiography monitoring. A bolus of ephedrine (15 mg) and phenylephrine (80 µg) was administered immediately but had little effect. Blood gas analysis showed severe hypercapnia (PaCO<sub>2</sub> level 75 mm Hg) and hypoxia (PaO<sub>2</sub> level 105 mm Hg [FiO<sub>2</sub> = 1.0]).

After fluid infusion and an epinephrine injection (100 µg), blood pressure increased. However, it quickly decreased again and remained unstable (50–70 mm Hg, systolic) even with a norepinephrine infusion (10 µg/min) and intermittent ephedrine and phenylephrine injections. Then, HR began to decrease, and cardiac arrest occurred. Surgical manipulation was suspended and resuscitation was initiated with an epinephrine injection (initially 100 µg, 3 mg in total) that was accompanied by chest compression to maintain a blood pressure of 80–110 mm Hg (systolic). Several minutes later, spontaneous circulation returned. Although the patient's blood pressure continued to fluctuate (70–100/52–72 mm Hg), the HR increased to 110 to 130 bpm when epinephrine (0.1–1 mg/min) was infused. An internal jugular vein catheter was placed, and central venous pressure was 31 mm Hg. Circulation tended to stabilize after blood transfusion (2 units of packed red blood cells) and administration of inotropic agents for 20 min. However, ventricular fibrillation occurred when the procedure resumed. After external cardiac compression and defibrillation were performed, sinus rhythm recovered, and blood pressure was maintained at 90–110/56–82 mm Hg under continued infusion of epinephrine (0.1–1 mg/min). VAE was suspected and TEE detected no significant findings, including air bubbles and obvious abnormalities in the heart cavity structure, except for overall low contractility. About 1 hour after the onset of clinical signs, the patient's condition seemed to improve. Arterial blood gas analysis showed the following values: PaO<sub>2</sub>, 329 mm Hg (FiO<sub>2</sub> = 1), and PaCO<sub>2</sub>, 69 mm Hg. After consultation, the operation was restarted. Suddenly, numerous air bubbles were seen floating through the right atrium when the surgeon moved the liver (Fig. 1), and cardiac arrest recurred. The patient was placed in the partial left lateral decubitus position and aspiration was unsuccessfully attempted via the central venous catheter.



**Figure 1.** Venous air embolism detected by transesophageal echocardiography. Air bubbles are seen floating through the right atrium. LA: left atrium, RA: right atrium.

Cardiac arrest was again treated with resuscitation. Extensive TEE examination excluded the presence of a cardiac shunt, suggesting that the air embolism may have developed when the hepatic veins were exposed to the air. Surgical exploration confirmed that the middle hepatic veins were cut and opened to the atmosphere. The opening was repaired with a suture, and the procedure was finished uneventfully. After re-establishing stable hemodynamic conditions, the patient was transferred to the intensive care unit without inotropic support. Blood gas analysis showed the following values: PH, 7.30; PCO<sub>2</sub>, 63 mm Hg; PO<sub>2</sub>, 283 mm Hg; and hemoglobin, 96 g/L. The patient returned to consciousness 6 hours postoperatively. Unfortunately, while hospitalized in the intensive care unit, the patient developed liver and renal dysfunction, as indicated by a total bilirubin level of 476 µmol/L, and atypical enzymology results (serum ALT: 5600 U/L; AST: 13010 U/L; lactate dehydrogenase: 24,060 U/L; hydroxybutyrate dehydrogenase: 10,200 U/L; phosphocreatine kinase: 11,310 U/L; troponin I: 8.89 ng/mL). Due to the deteriorating internal milieu, and no urine output, continuous renal replacement therapy was initiated 2 days later. Chest x-ray showed lung infection and required ventilation support (PEEP 15 cmH<sub>2</sub>O; FiO<sub>2</sub> = 0.7). Additionally, the patient's coagulation function was worsening (INR > 3.0, fibrinogen < 0.2 g/L, prothrombin time > 50 seconds), despite continuous plasma (3610 mL) and platelet (11 U) infusion. Norepinephrine (5–20 µg/min) was resumed to maintain hemodynamic stability (100–120 mm Hg in systolic). Ten days later, the patient died with sudden ventricular fibrillation despite emergent resuscitation.

### 3. Discussion

VAE is the entry of air from the operative field or other communication with the environment into the vein combined with systemic effects, which is a potential complication of surgery that requires the patient to maintain a sitting position. However, VAE has recently been reported in liver resection that was performed in a horizontal position.<sup>[5]</sup> Although VAE has been described and identified by using TEE, the specific incidence of VAE during hepatic resection remains unknown.<sup>[4]</sup> The most common factor accounting for VAE during hepatic resection may be hepatic vein rupture. During the operation, the diameter of vena cava at the junction with the hepatic veins may be narrowed by manipulation or compression. When blood passes through at a high flow rate, the venous pressure of the narrowed part may decrease, thus sucking air into the IVC.<sup>[5]</sup> When air embolism occurs, the prognosis depends on the volume and rate of air entry. The cumulative number of bubbles may block the right ventricle outflow tract and pulmonary artery, thereby resulting in pulmonary hypertension and heart failure. Serious VAE can cause cardiopulmonary collapse, as in the present case.

In order to minimize intraoperative bleeding from liver transected parenchyma, hepatic resection requires a low central venous pressure, which may lead to preload insufficiency and increase the incidence of air embolism. Although VAE was suspected from clinical clues of the symptoms, TEE remains the diagnostic gold standard for VAE.<sup>[8]</sup> In emergencies, any volume of air should alert the anesthesiologist to adopt prophylactic measures for reducing the risk of further deterioration. TEE is the most sensitive method and can detect 0.02 ml/kg of air; however, its cost limits its utility compared to the precordial Doppler ultrasonic device. Moreover, during operation, Doppler is not feasible because of sterilization of the body surface and use of clothing for draping during operation. Given its utility in the early, efficient, and accurate diagnosis of air

entering the right heart, TEE has advantages and should be considered in the anesthetic plan, in addition to routine monitoring, during surgery with a high VAE risk. Continuous monitoring is also essential since air passes through the heart quickly. If the examination is performed too early or too late, it will lead to a missed diagnosis.<sup>[10]</sup>

This case reminds surgeons of the possibility of fatal air embolism during hepatic resection, and highlights the need for anesthetists to be cautious of VAE. Particularly, the recurrence of cardiac arrest suggests the presence of air embolism when other obvious etiologies have been excluded. TEE should always be available during hepatic resection to detect fatal VAE. Cardiac arrest that results from VAE might complicate partially postoperative treatment in patients who have undergone partial hepatic resection. Vulnerable liver function often deteriorates the internal environment, which is often followed by renal and coagulation dysfunction, as in the present case.

#### 4. Conclusions

Fatal air embolism may occur during hepatic resection; the recurrence of cardiac arrest suggests the presence of air embolism when other obvious etiologies have been excluded. TEE should always be available during hepatic resection to detect fatal VAE.

#### Acknowledgments

We would like to thank Editage ([www.editage.com](http://www.editage.com)) for English language editing.

#### Author contributions

**Conceptualization:** Yong-Xing Yao.

**Writing – original draft:** Li-Hui Luo, Zhi-You Peng.

**Writing – review & editing:** Sheng-Mei Zhu.

#### References

- [1] Hatano Y, Murakawa M, Segawa H, et al. Venous air embolism during hepatic resection. *Anesthesiology* 1990;73:1282–5.
- [2] Nakayama R, Yano T, Mizutamari E, et al. Possible pulmonary gas embolism associated with localized thermal therapy of the liver. *Anesthesiology* 2003;99:227–8.
- [3] Adachi YU, Doi M, Sato S. Cardiac arrest by venous air embolism during hepatic resection using the Cavitron Ultrasonic Surgical Aspirator. *Anesth Analg* 2006;103:493–4.
- [4] Koo BN, Kil HK, Choi JS, et al. Hepatic resection by the Cavitron Ultrasonic Surgical Aspirator increases the incidence and severity of venous air embolism. *Anesth Analg* 2005;101:966–70.
- [5] Agnelli G, Becattini C. Acute pulmonary embolism. *N Engl J Med* 2010;363:266–74.
- [6] Hauser G, Milosevic M, Zelić M, et al. Sudden death after endoscopic retrograde cholangiopancreatography (ERCP)—case report and literature review. *Medicine (Baltimore)* 2014;93:e235.
- [7] Ebner FM, Paul A, Peters J, et al. Venous air embolism and intracardiac thrombus after pressurized fibrin glue during liver surgery. *Br J Anaesth* 2011;106:180–2.
- [8] Furuya H, Suzuki T, Okumura F, et al. Detection of air embolism by transesophageal echocardiography. *Anesthesiology* 1983;58:124–9.
- [9] Schmandra TC, Mierdl S, Bauer H, et al. Transoesophageal echocardiography shows high risk of gas embolism during laparoscopic hepatic resection under carbon dioxide pneumoperitoneum. *Br J Surg* 2002;89: 870–6.
- [10] Mirski MA, Lele AV, Fitzsimmons L, et al. Diagnosis and treatment of vascular air embolism. *Anesthesiology* 2007;106:164–77.