

# Myoclonus in older Cavalier King Charles Spaniels

Carina Rotter<sup>1</sup>  | Danielle Whittaker<sup>1</sup>  | Clare Rusbridge<sup>1,2</sup> 

<sup>1</sup>Orthopedics and Neurology, Fitzpatrick Referrals Ltd, Surrey, United Kingdom

<sup>2</sup>School of Veterinary Medicine, University of Surrey, Surrey, United Kingdom

## Correspondence

Carina Rotter, Orthopedics and Neurology, Fitzpatrick Referrals Ltd, Halfway Lane, Eashing, Surrey, GU7 2QQ, United Kingdom. Email: [crotter@fitzpatrickreferrals.co.uk](mailto:crotter@fitzpatrickreferrals.co.uk)

## Abstract

**Background:** Myoclonus is observed in older Cavalier King Charles Spaniels (CKCS) but a full description is lacking.

**Objectives:** The presence, age of onset, characteristics and treatment of myoclonic episodes were retrospectively evaluated in a cohort of CKCS which presented to 1 board-certified neurologist. Clinical data, imaging studies, presence of seizures and their management, as well as other comorbidities were noted.

**Animals:** Thirty-nine CKCS that were presented to 2 institutions between 2001 and 2018 with signs consistent with myoclonus. Clinical examination, blood sampling, advanced diagnostic imaging, cerebrospinal fluid analysis, and record keeping of other comorbidities was performed.

**Methods:** This is a retrospective case series, describing the presence of myoclonus in CKCS.

**Results:** Clinical signs reported were spontaneous in onset, lasted a few seconds and consisted of rapid blinking with head nodding and variable extension down the thoracic limbs. Myoclonus occasionally led to stumbling of the thoracic limbs or collapse. Mean age of onset was 8.38 years (SD  $\pm 1.96$ ). Thirteen of 39 dogs with myoclonus had paroxysmal events, such as generalized seizures (9/13).

**Conclusions and Clinical Importance:** Myoclonus occurs in middle-aged to older CKCS and seems to be another epiphenomena of this breed. A link to epilepsy might be present.

## KEYWORDS

involuntary movement, levetiracetam, myoclonic epilepsy, nonrhythmic muscle twitching, primary progressive myoclonus of aging

**Abbreviations:** AED, antiepileptic drug; CKCS, Cavalier King Charles Spaniel; CM, Chiari-like malformation; CM-P, Chiari-like malformation associated pain; CSF, cerebrospinal fluid; EEG, electroencephalogram; EMG, electromyogram; GABA, gamma-aminobutyric acid; MRI, magnetic resonance imaging; NSAIDs, nonsteroidal anti-inflammatory drugs; OME, otitis media with effusion; PMMA, primary progressive myoclonus of aging; SM, syringomyelia; SM-S, syringomyelia associated phantom scratching

## 1 | INTRODUCTION

Myoclonus is defined as a brief, shock-like, jerk-like movement due to involuntary contraction or relaxation of 1 or more muscles.<sup>1-6</sup> It can be positive (hyperkinetic) which manifests as a jerking muscle contraction; or negative (hypokinetic) where there is an interruption of

This is an open access article under the terms of the [Creative Commons Attribution-NonCommercial-NoDerivs](https://creativecommons.org/licenses/by-nc-nd/4.0/) License, which permits use and distribution in any medium, provided the original work is properly cited, the use is non-commercial and no modifications or adaptations are made.

© 2022 Fitzpatrick Referrals Limited. *Journal of Veterinary Internal Medicine* published by Wiley Periodicals LLC on behalf of American College of Veterinary Internal Medicine.

antigravity (isometric) muscle activity and tone resulting in postural instability or falling.<sup>1-6</sup> Myoclonus can be a consequence of many diseases and categorization is based on clinical presentation, physiology, and etiology. In humans, clinical presentation distinguishes physiological, essential, epileptic, and symptomatic myoclonus.<sup>2-4,6,7</sup> Physiological myoclonus is a common phenomenon, for example hypnic jerks (muscle twitch as falling asleep) or hiccups (a myoclonus of the diaphragm).<sup>1-6,8</sup> Essential myoclonus can be hereditary or sporadic. Myoclonus is the prominent feature, is not disabling and not associated with seizures, dementia, or neurodegeneration.<sup>2,4,7</sup> In contrast with epileptic myoclonus, seizures are the dominating clinical sign. Secondary myoclonus encompasses a myriad of etiologies including neurodegenerative disorders, inflammatory/metabolic conditions, intoxication and drug-induced.<sup>2,4,7</sup> The physiological categorization is based on electrodiagnostic tests, enabling differentiation between cortical, subcortical/nonsegmental, segmental, and peripheral myoclonus.<sup>3,4,7</sup> Myoclonus can originate in the cortex, subcortical structures (thalamus, brainstem), spinal cord, or peripherally.<sup>2-4,6</sup> Cortical myoclonus is due to discharges of the motor cortex.<sup>1-4</sup> However, a cerebellar component of myoclonus is suspected, with inhibitory output of the cerebellum being decreased.<sup>3,9</sup> It might be seen at rest, with action or sensory stimulation, with jerks being widespread.<sup>2,3,6</sup> In contrast, the excitatory discharge in cortico-subcortical myoclonus starts in subcortical structures and produces myoclonus when it spreads to the primary motor cortices, with often bilateral and synchronous appearance. It usually occurs at rest and might be isolated or a seizure with myoclonic features.<sup>4</sup> In veterinary medicine the etiology of myoclonus is under investigated. Grouping into epileptic and nonepileptic myoclonus has been described.<sup>5,8</sup> However, there is a lack of consistency between veterinary and human for the same disease. For example, Lafora's disease is categorized into epileptic category in veterinary<sup>5,8</sup> and as a secondary myoclonus in humans because seizures are not a predominant sign and because it is a neurodegenerative disorder.<sup>7</sup> The purpose of this paper is to describe the clinical characteristics and potential etiology of myoclonus in Cavalier King Charles Spaniels (CKCS) and diagnostic approach to myoclonus in the veterinary patient. Tendency for older CKCS presenting to develop myoclonus had been documented previously.<sup>10</sup> Further aims of this study is to explore if association between myoclonus and other neurological disorders exists and investigate potential treatment options.

## 2 | MATERIAL AND METHODS

For this retrospective study medical records of CKCS that presented to a board-certified specialist in veterinary neurology (C. Rusbridge) with myoclonus between 2001 and 2018 were reviewed by the first author. Dogs must have either had video footage provided of episodes showing myoclonus or the myoclonus itself had been present during 1 of the consultations. Medical data including possible triggers, position in which the myoclonus was observed, other neurological abnormalities, as well as

laboratory and imaging data were reviewed retrospectively. Dogs with coexisting epilepsy/generalized seizures were not excluded from the study.

Data were recorded by a board-certified neurologist (C. Rusbridge) and acquisition completed by a neurology resident in training. Data recorded from medical records included signalment, clinicopathologic data, age of onset of myoclonus, presence of epileptic seizures and if treated. Additionally, comorbidities, such as mitral valve disease and treatment trials for myoclonus were noted. Every owner was asked if they perceived the myoclonus to be interfering with the quality of life of their dog.

Imaging studies had to include at least T2-weighted sagittal and transverse, FLAIR transverse and T1-weighted dorsal and transverse sequences to rule out structural causes. Most MR images were obtained with a 1.5 T magnetic resonance imaging (MRI) machine (Siemens, Magnetom Symphony, Camberley, UK) or a 0.2 Tesla (Esaote Vet MRI, Genova, Italy), 2 scans were performed in external centers. Evaluation of existence of lateral ventriculomegaly, Chiari-like malformation (CM), syringomyelia (SM), or otitis media with effusion (OME) was performed by the last author.

Statistical analysis was performed using Microsoft Excel for Microsoft 365. Data were evaluated for normality using the Shapiro-Wilk test and normal data are stated as mean  $\pm$  SD. Nonnormal data are summarized as median and range.

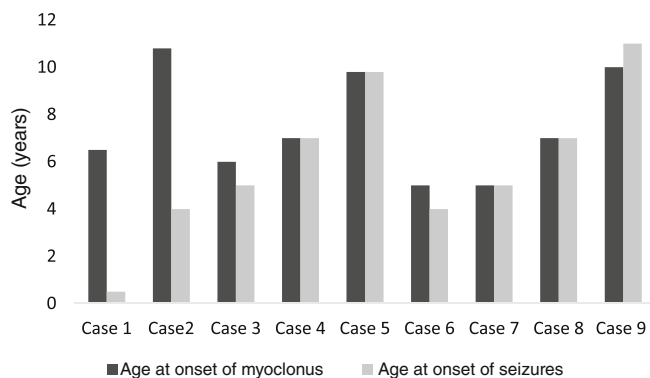
## 3 | RESULTS

### 3.1 | Signalment and clinical phenomenology

Thirty-nine dogs were identified, 24 female (14 neutered, 5 female entire, 5 unknown), 15 male (11 neutered, 2 entire, 2 unknown). Mean bodyweight was 9.44 kg ( $\pm$ 2.3). Most were referred originally for another disease. The myoclonic event was a mixture of positive and negative myoclonus and described as rapid eyelid blinking with head nodding/shuddering and variable extension down the thoracic limbs, that could result in falling or stumbling of the thoracic limbs. The movement lasted seconds had no obvious trigger and occurred mostly when stationary in a sternal or sitting position. It did not seem to be associated with loss of consciousness (see Videos S1 and S2). Multiple daily episodes were seen and increased in frequency and intensity over time. Owners whose dogs would frequently fall, often disrupting them while eating, reported the myoclonus to interfere with the dog's quality of life. The mean age of onset of myoclonus was 8.38 years (SD  $\pm$ 1.96).

### 3.2 | Neurological comorbidities

Thirteen of 39 cases had epileptic seizures or other paroxysmal events, with 9/13 having had at least 1 generalized tonic-clonic seizure. Mean age of onset of epileptic seizures was 5.9 years ( $\pm$ 3.19). Age of onset of epileptic seizures for 6 dogs with suspected idiopathic epilepsy was  $\pm$ 1 year from onset of myoclonus. Myoclonus occurred



**FIGURE 1** Correlation of age of onset of myoclonus (dark columns) and seizures (light columns). On the y-axis is the age in years, the x-axis shows each of the 9 cases with seizures

approximately at the same time (4/9), within 1 year of seizure onset (2/9), was present before the seizure onset (1/9) or occurred >6 years after seizure onset (2/9; see Figure 1).

Four dogs had paroxysmal events, described as sudden collapse, which occurred during exercise in 1 dog, which was tested homozygous normal for episodic falling syndrome. Two dogs were described as having a sudden drop, similar to a syncope, 1 of which had a normal Holter-ECG, the other was tested homozygous normal for episodic falling syndrome. One dog showed signs of paroxysmal dyskinesia with episodes lasting up to 30 minutes during which she struggled or was unable to move. These started on the left and spread to the right pelvic limb. Twenty cases showed signs of CM-associated pain (CM-P) and 9 dogs had SM specific signs in including phantom scratching (SM-S). Two dogs displayed signs of cognitive dysfunction, with 1 dog described as tending to stare blankly into space, showing less interaction with the owner, wandering aimlessly when left alone and signs suggesting anxiety. Both dogs had seizures which were managed with imepitoin. Four dogs had pelvic limb orthostatic tremor, 1/4 involved 1 of the thoracic limbs as well. The tremor was present while standing, disappeared when walking.

### 3.3 | Other comorbidities

Other comorbidities included degenerative mitral valve disease in 16 dogs. OME was diagnosed based on MRI and present in 13 dogs. Six dogs displayed signs of keratoconjunctivitis sicca.

### 3.4 | Advanced diagnostic imaging, laboratory findings, and histopathology

Magnetic resonance imaging was performed in 30/39 cases, all of which had CM, 23/30 had lateral ventriculomegaly, which was mild in 9/23 dogs, moderate in 11 and marked in 3 dogs. One dog had hydrocephalus which was managed with placement of a ventriculoperitoneal shunt. Twenty of 30 cases showed signs of SM, 3 a

presyrinx and 4 a central canal dilatation. OME was visible in 13 dogs. Median age of imaging was 5.5 years (range, 0-13), 28/30 dogs had repeated imaging between 1 and 13 years of age (median 7 years). Cerebrospinal fluid (CSF) was analyzed in 7 cases and was unremarkable in 3, with 1 cisternal and 1 lumbar sample having elevated protein content (cisternal sample: 160 mg/dL, reference <30; unknown value for lumbar sample), 2 being blood contaminated, and 1 result unavailable. Two dogs were tested for canine distemper virus infection via polymerase chain reaction on CSF, which was not detected. Testing for Toxoplasma and Neospora infection were performed and were negative in 3 dogs. Hematology was available in 20 and serum biochemistry including electrolytes in 22/39 cases. In 8 dogs, minor abnormalities were observed in hematology and clinical chemistry or hematology alone, but the abnormalities were judged as incidental and were not explanatory. Urinalysis was recorded in 4 (2 showing lower specific gravity and 1 sample tested positive for *Escherichia coli* and calcium oxalate stones). Organic uric acids were normal in 1 case. Acetylcholine-receptor antibodies, ammonia, bile acid stimulation tests and electrodiagnostic investigation was performed in 1 case respectively and was unremarkable. A postmortem of the brain and spinal cord was performed in 1 case. No structural abnormalities were detected and there were no signs of other diseases known to be associated with myoclonic epilepsy.

### 3.5 | Pharmacotherapy

Seizures were treated in 5/9 cases, with imepitoin (3/5) and 2 dogs with phenobarbital (2.5-3 mg/kg q12hours). Twenty-three dogs were on multimodal analgesia due to CM-P and SM-S. Pharmacotherapy was typically gabapentin (17/39; dose: 7-14 mg/kg q8 hours) or pregabalin (17/39; dose range, 3.8-10 mg/kg q12hours; 5-8 mg/kg q8hours) and various nonsteroidal anti-inflammatory drugs (NSAIDs). Twelve dogs were initially prescribed gabapentin but transitioned to pregabalin due to lack of positive response. Levetiracetam was used to manage myoclonus in 6 cases with doses ranging from 9.7 mg/kg q12hours to 26.3 mg/kg q8hours. Good response was noted in 3 dogs, with 1 showing marked improvement. In the latter daily episodes stopped for 8 months. In this case dose of levetiracetam was increased empirically, depending on effect. The dog was initially prescribed 13.1 mg/kg q8hours for 2 weeks, which was then increased to 20 mg/kg q8hours resulting in 5 days of improvement followed by worsening and subsequent dose adjustment to 26.3 mg/kg q8hours after which no myoclonus was observed for 8 months. After 8 months the episodes recurred, and the dog was diagnosed with a ruptured cruciate ligament at the same time. Treatment had to be discontinued in 1 case due to severe sedation and ataxia, despite trial of dose reduction (from 12.5 mg/kg q8hours to 6.25 mg/kg q8hours). Two dogs were lost for follow-up.

Seven dogs received methylprednisolone q24-48 hours, which resulted in apparent improvement of the myoclonus in 1 dog (dose 0.4 mg/kg q24hours). Six CKCS did receive it for reasons unrelated to the myoclonus. It was discontinued in 4 (1 due to suspected

contributor to anxiety). In 1 case it had been withdrawn before the myoclonus was noticed.

## 4 | DISCUSSION

Here we provide the first report of myoclonus syndrome in a cohort of CKCS with a higher prevalence after 8 years of age. Myoclonus is characterized by spontaneous onset, rapid eyelid blinking and head nodding, a jerking movement of the head sometimes extending down the thoracic limbs, occasionally involving the whole body and might cause the dog to stumble or fall. There was no apparent loss of consciousness. Myoclonus was not associated with a trigger or sleep but did occur when standing, sitting, or lying in a sternal position. Multiple episodes in a day were often reported. Clinical course was slowly progressive with the episodes becoming more frequent and more intense over time.

The myoclonus observed in our cohort was not action-related nor stimulus sensitive. Given the lack of electroencephalogram (EEG) and electromyogram (EMG) to explore the precise origin of the myoclonus within the nervous system it is not possible to provide a neuro-anatomical localization for myoclonus in CKCS. Based on the presenting features of myoclonus in our reported cohort a cortical or cortico-subcortical etiology is suspected.

### 4.1 | Neurological comorbidities with myoclonus in the CKCS

A genetic underlying cause leading to epilepsy or a movement disorder with myoclonus as a feature might have been present in 13/39 dogs. Dogs with idiopathic epilepsy (IE) tend to have an onset of seizures between 6 months and 6 years of age,<sup>11</sup> whereas our population had a later onset which might imply a different etiology to the typical breed associated IE. Two dogs showed signs of cognitive decline. These dogs were previously diagnosed with IE with a Tier 2 confidence according to the International Veterinary Epilepsy Task force.<sup>11</sup> It is impossible to eliminate the possibility of progressive myoclonic epilepsy; however, it could be argued that the cognitive impairment is more likely to be correlated to IE in these cases rather than part of a neurodegenerative disorder. Epilepsy in humans predisposes to dementia or Alzheimer's disease<sup>12</sup> and anxiety is more prevalent in epileptic patients.<sup>13</sup> Recent research indicates that dogs with IE are similar to humans, and more likely to show signs and an earlier onset of canine cognitive dysfunction, as well as an increase in anxious behavior.<sup>14-16</sup> Given the small case number and absence of repeated objective measurement, such as the canine cognitive dysfunction rating scale<sup>17</sup> we cannot rule out that an underlying neurodegenerative disorder was present and the myoclonus part of it.

Additionally, we investigated if common diseases affecting the CKCS were linked with the development of myoclonus. 100% of dogs that underwent MRI showed signs of CM and 66% SM, this resembles the overall reported breed prevalence in the general CKCS

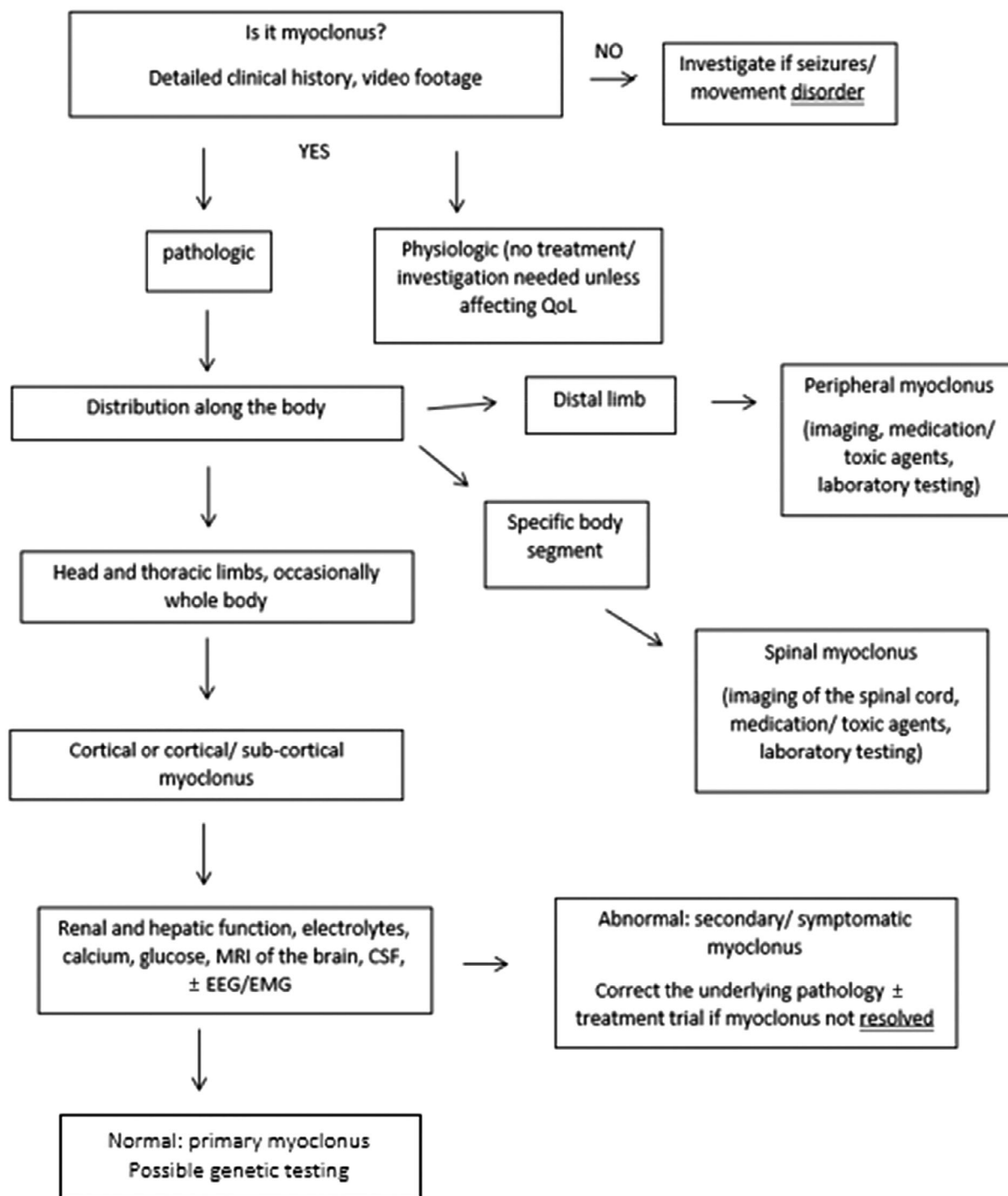
population.<sup>18</sup> In other words, a link between CM and SM was neither proven nor disproven. The frequency of CM and SM was that expected for the age of the population and dogs could have myoclonus without CM or SM.

### 4.2 | Other comorbidities

Sixteen of 39 dogs were diagnosed with degenerative mitral valve disease which is a common problem thought to affect nearly all CKCS >10 years of age.<sup>19</sup> Six dogs displayed signs of keratoconjunctivitis sicca, which could be associated with an immune-mediated disorder but based on this study it cannot be concluded if this is in relation to the myoclonus or not. The retrospective nature of this report is a limiting factor, which makes it difficult to determine if laboratory changes or neurodegenerative disease have contributed to the myoclonus.

Considering our findings in CKCS and human guidelines for a 3<sup>7</sup> or 8-step<sup>9</sup> diagnostic plan, we propose to approach the veterinary patient presenting with myoclonus with a 6-step plan ([Diagram 1](#)). In first instance it should be determined if the dog is displaying myoclonus. All our dogs were confirmed to have myoclonus based on observation of this by an experienced neurologist. It might be difficult for an inexperienced veterinarian and in these instances video footage provided can aid in identification by sending these to a neurologist for review. It is paramount to take a detailed history, including information about littermates, the dam and sire, history of seizure episodes, abnormal behavior and medication or possible drug or toxin exposure, as this gives information of potential primary and secondary myoclonus and will influence further investigation. Once established that the myoclonus is pathological, the distribution along the body should be taken into account to guide areas of interest for advanced diagnostic imaging. If medication or toxins are suspected, these should be withdrawn or eliminated and myoclonus resolving. In case the front part of the body is primarily affected intra- and extracranial causes should be excluded. Extracranial causes in humans to cause myoclonus are liver and renal failure.<sup>3,7,9</sup> Two of the dogs had slight to moderate increases in liver parameters, but a cutoff level where myoclonus could be triggered by renal, or liver disease has yet to be determined. Given the fact that increases in liver values has not led to hepatic encephalopathy signs on clinical examination this might be less likely. One dog was diagnosed with diabetes mellitus, and the myoclonic episodes worsened during times of hypoglycemia, but did not completely resolve during normoglycemia. Given the small case number of dogs with altered laboratory findings it is impossible to draw a concise relation.

Twenty-three of 39 dogs were prescribed gabapentin/pregabalin due to CM-P and/or SM-S. It is questionable if gabapentin or pregabalin worsened the myoclonus; however, no deterioration of myoclonus after start of gabapentinoids was documented. Two of the cases were prescribed gabapentin after the myoclonus occurred and the myoclonus did not worsen but the nature of this study does not help to draw a conclusion and it remains questionable if myoclonus was drug-induced in these cases. However, the inhibitory neurotransmitter gamma-aminobutyric acid (GABA) is thought to play a critical



**DIAGRAM 1** Flowchart giving a 6-step guide on how to approach and classify myoclonus in veterinary medicine

role in myoclonus. Interestingly, inhibition, as well as an increase in GABA-neurotransmission can cause myoclonus.<sup>20</sup>

Given the age of onset and a slowly progressive course of myoclonus in our cohort a primary geriatric/idiopathic myoclonus might be present within the CKCS population. A similar syndrome has been proposed in human medicine called “primary progressive myoclonus of aging (PPMA)” but description is limited to 11 people described in

2 publications.<sup>21,22</sup> PMMA is characterized by a cortical, asymmetrical action myoclonus in patients  $\geq 50$  years of age,<sup>22</sup> without an underlying cause or concomitant dementia or another neurodegenerative disease.<sup>21,22</sup> The course reported was static after an initial progressive phase.<sup>22</sup> The difference to our population of CKCS, is the stimulus-sensitive action-related asymmetric myoclonus affecting face/jaw, as well as arms to lower extremities,<sup>21</sup> whereas in CKCS we have found

a spontaneous, resting myoclonus that commonly involved unilateral thoracic limb, but head movements were symmetrical.

### 4.3 | Management of myoclonus

Cortical myoclonus might be responsive to medication decreasing cortical excitability, such as standard antiepileptic drugs (AEDs),<sup>2-4</sup> although phenobarbital has been shown to be rarely effective in humans.<sup>3</sup> Out of 9 dogs in this study that showed generalized seizure activity, 5 received a first-line antiepileptic medication (imepitoin or phenobarbitone), the remainder did not receive any. Both increase the inhibitory effect of GABA, resulting in decreased neuronal excitability. Yet, neither resulted in improvement of the myoclonus. One dog showed seizure control with a 12-month seizure free period during which the myoclonus progressed. Demonstrating that their pathogenesis suggests to be different.

For both cortical and subcortical myoclonus, which is suspected in the 39 CKCS in this study, if no inciting cause has been identified, levetiracetam has been proposed as a first-line treatment in humans.<sup>2-4,6,7</sup> Levetiracetam is unique compared to other AEDs, binding the synaptic protein SV2A<sup>4,23-25</sup> instead of having a direct effect on GABA receptors. It indirectly regulates inhibition of GABA and decreases cortical excitability,<sup>25</sup> being effective to decrease myoclonus of different anatomical origins, including cortical, subcortical, brainstem, but not spinal myoclonus.<sup>3,4</sup>

Six of our cases received levetiracetam (9.7 mg/kg q12hours to 26.3 mg/kg q8hours), which resulted in improvement in 3 cases, decreasing the episodes from 1 per day to a myoclonus free period of 8 months in 1 dog. Despite doses below the currently proposed guidelines of 20 mg/kg q8hours as a second-line AED in dogs with idiopathic epilepsy.<sup>23</sup> A similar effect has been noted in human studies, where probands experienced a reduction of myoclonus with only one third of the dose for cortical myoclonus epilepsy.<sup>24</sup>

Despite the low dose of levetiracetam used, 1 dog had to be discontinued due to severe ataxia and sedation, despite dose reduction. It might have been feasible in this case to reduce the pregabalin dose which was high at 5 mg/kg q8 hours. A future randomized, blinded study including a trial with levetiracetam would help to establish if this is a valuable treatment option. The rapid onset of action and possibility of sudden withdrawal make this medication a favorable pharmacokinetic for a therapeutic trial.<sup>23</sup> Further, the current human literature supports its benefit in managing cortical and cortical-subcortical myoclonus.<sup>2,4,6,9</sup>

A glucocorticoid was administered in 7 cases, albeit prescribed for reasons unrelated to the myoclonus in 6. 2/6 had discontinued steroid treatment by the time the myoclonus started. In 2 dogs, dose is unknown and 1 of them was discontinued due to suspicion of worsening of anxiety. One dog was prescribed methylprednisolone at 0.5 mg/kg q24hours due to SM-related signs, which was decreased to 0.25 mg/kg q24hours due to weakness, but the dog shortly after euthanized and no information about the effect on the myoclonus was available. In only 1 dog methylprednisolone was prescribed at

0.4 mg/kg q24hours for myoclonus specifically and it helped to decrease the myoclonus. In humans, myoclonus as part of progressive myoclonic epilepsies has been shown to be associated with neuroinflammation, which responded to anti-inflammatory drugs.<sup>26</sup> If an underlying inflammatory cause, such as encephalitis of unknown etiology was present in that dog, cannot be fully excluded given CSF sampling was not performed. However, the MRI findings did not suggest it.

Many of our cases did not receive treatment targeting the myoclonus, as owners generally did not perceive the episodes to interfere with daily activities or quality of life. However, in cases where myoclonic activity caused the dog to stumble or fall, treatment was attempted.

In order to choose directed treatment, it is important to categorize the myoclonus based on anatomical and physiological etiology.<sup>2,4,7</sup> Main importance should be to distinguish between primary and secondary myoclonus.<sup>4</sup> Based on this information treatment is selected, as certain medications have been proven to be effective in cortical myoclonus, but less in other forms.<sup>2,4,7-9</sup> It is of utmost importance to take a thorough clinical history to determine if a possible genetic link exists or the myoclonus is associated with medication or toxins.<sup>2,4,7,9</sup> Further, blood tests to exclude metabolic causes, MRI, EEG and multisurface EMG to determine the originating site within the nervous system,<sup>2,4,7,9</sup> but this has yet to be more advanced in veterinary medicine. We have performed widely available diagnostic steps in our study population (advanced diagnostic imaging, blood, and CSF sampling), to exclude an underlying pathology as much as possible and proposed a step-by-step approach for the veterinary patient with myoclonus.

## 5 | CONCLUSION

Myoclonic jerks are reported in middle-aged to older CKCS and should not be assumed to be a consequence of SM. There might be a link with generalized tonic-clonic seizures. It seems to be another epiphenomenon for this breed. Although the number of CKCS treated successfully with levetiracetam was low this could be a possible treatment for myoclonus in this breed. Further research to substantiate this is needed.

### ACKNOWLEDGMENT

No funding was received for this study.

### CONFLICT OF INTEREST DECLARATION

Authors declare no conflict of interest.

### OFF-LABEL ANTIMICROBIAL DECLARATION

Authors declare no off-label use of antimicrobials.

### INSTITUTIONAL ANIMAL CARE AND USE COMMITTEE (IACUC) OR OTHER APPROVAL DECLARATION

Authors declare no IACUC or other approval was needed.

**HUMAN ETHICS APPROVAL DECLARATION**

Authors declare human ethics approval was not needed for this study.

**ORCID**

Carina Rotter  <https://orcid.org/0000-0002-9032-3510>

Danielle Whittaker  <https://orcid.org/0000-0003-0240-8141>

Clare Rusbridge  <https://orcid.org/0000-0002-3366-2110>

**REFERENCES**

- Marsden CD, Hallett M, Fahn S. The nosology and pathophysiology of myoclonus. *Movement Disorders*. Netherlands: Elsevier; 1981:196-248. doi:10.1016/B978-0-407-02295-9.50018-7
- Stahl CM, Frucht SJ. An update on myoclonus management. *Expert Rev Neurother*. 2019;19(4):325-331. doi:10.1080/14737175.2019.1592676
- Levy A, Chen R. Myoclonus: pathophysiology and treatment options. *Curr Treat Options Neurol*. 2016;18(5):21. doi:10.1007/s11940-016-0404-7
- Pena AB, Caviness JN. Physiology-based treatment of myoclonus. *Neurotherapeutics*. 2020;17(4):1665-1680. doi:10.1007/s13311-020-00922-6
- Cerda-Gonzalez S, Packer RA, Garosi L, et al. International veterinary canine dyskinesia task force ECVN consensus statement: terminology and classification. *J Vet Intern Med*. 2021;35:1218-1230. doi:10.1111/jvim.16108
- Mills K, Mari, Z. An Update and review of the treatment of myoclonus. *Curr Neurol Neurosci Rep*. 2015;15(1):512. <https://doi.org/10.1007/s11910-014-0512-2>
- Caviness JN. Myoclonus. *Contin Minneap Minn*. 2019;25(4):1055-1080. doi:10.1212/CON.0000000000000750
- Lowrie M, Garosi L. Classification of involuntary movements in dogs: myoclonus and myotonia. *J Vet Intern Med*. 2017;31(4):979-987. doi:10.1111/jvim.14771
- Zutt R, van Egmond ME, Elting JW, et al. A novel diagnostic approach to patients with myoclonus. *Nat Rev Neurol*. 2015;11(12):687-697. doi:10.1038/nrneurol.2015.198
- Rusbridge C. Neurological diseases of the Cavalier King Charles Spaniel. *J Small Anim Pract*. 2005;46(6):265-272. doi:10.1111/j.1748-5827.2005.tb00319.x
- De Risio L, Bhatti S, Muñana K, et al. International veterinary epilepsy task force consensus proposal: diagnostic approach to epilepsy in dogs. *BMC Vet Res*. 2015;11(1):148. doi:10.1186/s12917-015-0462-1
- Dodrill CB. Progressive cognitive decline in adolescents and adults with epilepsy. *Progress in Brain Research*. Vol 135. Netherlands: Elsevier; 2002:399-407. doi:10.1016/S0079-6123(02)35037-4
- Hingray C, McGonigal A, Kotwas I, et al. The relationship between epilepsy and anxiety disorders. *Curr Psychiatry Rep*. 2019;21(6):40. doi:10.1007/s11920-019-1029-9
- Packer RMA, McGreevy PD, Salvin HE, et al. Cognitive dysfunction in naturally occurring canine idiopathic epilepsy. *PLoS One*. 2018;13(2):e0192182. doi:10.1371/journal.pone.0192182
- Watson F, Packer RMA, Rusbridge C, et al. Behavioural changes in dogs with idiopathic epilepsy. *Vet Rec*. 2020;186(3):93. doi:10.1136/vr.105222
- Watson F, Rusbridge C, Packer RMA, et al. A review of treatment options for behavioural manifestations of clinical anxiety as a comorbidity in dogs with idiopathic epilepsy. *Vet J*. 2018;238:1-9. doi:10.1016/j.tvjl.2018.06.001
- Salvin HE, McGreevy PD, Sachdev PS, et al. The canine cognitive dysfunction rating scale (CCDR): a data-driven and ecologically relevant assessment tool. *Vet J*. 2011;188(3):331-336. doi:10.1016/j.tvjl.2010.05.014
- Rusbridge C. New considerations about Chiari-like malformation, syringomyelia and their management. *In Pract*. 2020;42(5):252-267. doi:10.1136/inp.m1869
- Madsen MB, Olsen LH, Haggstrom J, et al. Identification of 2 loci associated with development of myxomatous mitral valve disease in Cavalier King Charles Spaniels. *J Hered*. 2011;102(Suppl 1):S62-S67. doi:10.1093/jhered/esr041
- Lalonde R, Strazielle C. Brain regions and genes affecting myoclonus in animals. *Neurosci Res*. 2012;74(2):69-79. doi:10.1016/j.neures.2012.07.004
- Alvarez M, Caviness JN. Primary progressive myoclonus of aging. *Mov Disord*. 2008;23(12):1658-1664. doi:10.1002/mds.22085
- Katschnig P, Massano J, Edwards MJ, et al. Late-onset asymmetric myoclonus: an emerging syndrome: brief report. *Mov Disord*. 2011;26(9):1744-1747. doi:10.1002/mds.23676
- Bhatti SFM, De Risio L, Muñana K, et al. International Veterinary Epilepsy Task Force consensus proposal: medical treatment of canine epilepsy in Europe. *BMC Vet Res*. 2015;11(1):176. doi:10.1186/s12917-015-0464-z
- Kovács T, Farsang M, Vitaszil E, et al. Levetiracetam reduces myoclonus in corticobasal degeneration: report of two cases. *J Neural Transm*. 2009;116(12):1631-1634. doi:10.1007/s00702-009-0301-2
- Solinas C, Lee YC, Reutens DC. Effect of levetiracetam on cortical excitability: a transcranial magnetic stimulation study. *Eur J Neurol*. 2008;15(5):501-505. doi:10.1111/j.1468-1331.2008.02110.x
- Sanz P, Serratos JM. Neuroinflammation and progressive myoclonus epilepsies: from basic science to therapeutic opportunities. *Expert Rev Mol Med*. 2020;22:e4. doi:10.1017/erm.2020.5

**SUPPORTING INFORMATION**

Additional supporting information may be found in the online version of the article at the publisher's website.

**How to cite this article:** Rotter C, Whittaker D, Rusbridge C. Myoclonus in older Cavalier King Charles Spaniels. *J Vet Intern Med*. 2022;36(3):1032-1038. doi:10.1111/jvim.16404