

# Rare Vascular Anomalies in the Femoral Triangle During Varicose Vein Surgery

Duk Sil Kim, M.D.<sup>1</sup>, Sung Wan Kim, M.D.<sup>1</sup>, Hyun Seok Lee, M.D.<sup>2</sup>,  
Kyung Hwan Byun, M.D.<sup>2</sup>, Michael SungPil Choe, M.D.<sup>3</sup>

Departments of <sup>1</sup>Thoracic and Cardiovascular Surgery, <sup>2</sup>Radiology, and <sup>3</sup>Emergency Medicine,  
CHA Gumi Medical Center, CHA University

**Background:** We observed several cases of rare vascular anomalies within the femoral triangle during varicose vein operations. **Methods:** From among 2,093 patients who underwent stripping operations of the great saphenous vein between January 2002 and June 2016, 14 cases of rare vascular anomalies were enrolled in this study. **Results:** Twelve cases of femoral artery and vein transposition (0.57%), 1 case of separate entrance of the great saphenous vein trunk and its tributaries (0.05%), and 1 case of separate entrance with femoral artery and vein transposition (0.05%) were observed. The preoperative diagnosis rate was 71% (10 of 14) using duplex ultrasound. In all cases of femoral artery and vein transposition, the saphenofemoral junction was located at the lateral or posterolateral side of the superficial femoral artery, corresponding to complete or incomplete transposition, respectively. Among the 12 cases of femoral artery and vein transposition, 5 cases were complete transposition and 7 cases were incomplete transposition. In 2 cases of separate entrance of the great saphenous vein trunk and its tributaries, the separated tributaries formed a common trunk before connecting to the femoral vein. **Conclusion:** The anatomy of the saphenofemoral junction may infrequently be altered in some individuals. Detailed preoperative sonographic examinations and meticulous groin dissection during the operation are necessary to prepare for unexpected anatomical variations.

*Key words:* 1. Saphenous vein  
2. Femoral artery  
3. Femoral vein

## Introduction

It is well known that during varicose vein surgery, the small saphenous veins may be found to variably enter into the popliteal vein, the superficial femoral vein, or the Giacomini vein. However, the great saphenous veins consistently enter into the common femoral vein within the femoral triangle. When the great saphenous vein has undergone stripping, the saphenofemoral junction is usually located at medial

side of the femoral artery [1].

Normal anatomical variations in the femoral triangle have been described, mainly dealing with the origin and course of the deep femoral artery, in addition to the great saphenous vein branches and external pudendal arteries at the saphenofemoral junction [1-5]. The authors, over the course of many varicose vein operations, have observed several cases of rare vascular anomalies within the femoral triangle that warrant additional discussion.

Received: July 27, 2016, Revised: October 17, 2016, Accepted: October 19, 2016, Published online: April 5, 2017

Corresponding author: Sung Wan Kim, Department of Thoracic and Cardiovascular Surgery, CHA Gumi Medical Center, CHA University, 12 Sinsi-ro 10-gil, Gumi 39295, Korea  
(Tel) 82-54-450-9586 (Fax) 82-54-452-5098 (E-mail) [doa1224@dreamwiz.com](mailto:doa1224@dreamwiz.com)

© The Korean Society for Thoracic and Cardiovascular Surgery. 2017. All right reserved.

© This is an open access article distributed under the terms of the Creative Commons Attribution Non-Commercial License (<http://creativecommons.org/licenses/by-nc/4.0>) which permits unrestricted non-commercial use, distribution, and reproduction in any medium, provided the original work is properly cited.

## Methods

We retrospectively reviewed the medical records of 2,775 patients who underwent surgical treatment of varicose veins from January 2002 to June 2016 at CHA Gumi hospital. All operations were performed by a single surgeon. Among the 2,093 patients who underwent stripping operations of the great saphenous vein, 14 patients with vascular anomalies were investigated and are reviewed here with a discussion of the relevant literature. In cases of femoral artery and vein transposition, we defined approximately 50% or greater superficial femoral artery positioning medial to the common femoral vein as complete transposition.

Duplex ultrasound was performed as a routine preoperative examination procedure. If reflux lasted more than half a second at the saphenofemoral junction, a stripping operation was routinely performed.






The groin was incised transversely, with an incision sized approximately 2–4 cm at the inguinal crease or lower area in proportion to the patient's obesity. During groin dissection, all branches around the saphenofemoral junction were divided and the great saphenous vein trunk was ligated flush with the common femoral vein. The great saphenous vein trunk was stripped out to the knee level or ankle level according to the results of duplex ultrasound or hand-held Doppler.

## Results

We observed 14 cases of rare vascular anomalies within the femoral triangle during varicose vein surgery. Among 2,093 patients undergoing great saphenous vein operations, 12 cases of femoral artery and vein transposition (0.57%), 1 case of separate entrance of the great saphenous vein trunk and its branches (0.05%), and 1 case of separate entrance with femoral artery and vein transposition (0.05%) were observed. All patients corresponded to clinical class 2 to 3 of the clinical-etiological-anatomical-pathological classification system.

Out of 12 cases of femoral artery and vein transposition, 8 cases were preoperatively diagnosed using routine examinations with duplex ultrasound, while the other 4 cases were encountered during the inguinal dissections. Two cases of separate entrance

Table 1. Types and locations of transposition of the femoral artery and vein

Types of transposition and location	Diagram of saphenofemoral junction	No. of cases
Complete transposition at right groin		3
Incomplete transposition with 100% overlap at right groin		1
Complete transposition at left groin		2
Incomplete transposition with 100% overlap at left groin		3
Incomplete transposition with 60% overlap at left groin		3

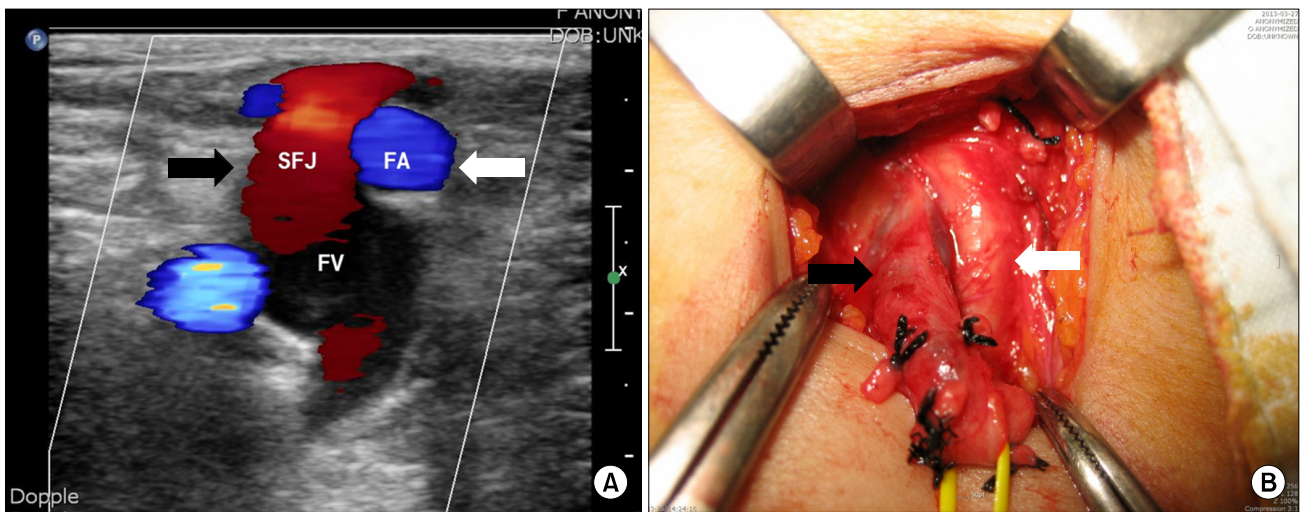
A, superficial femoral artery; a, deep femoral artery; SV, great saphenous vein.

and separate entrance with femoral vessel transposition were preoperatively detected with duplex ultrasound. The preoperative diagnosis rate was 71% (10 of 14).

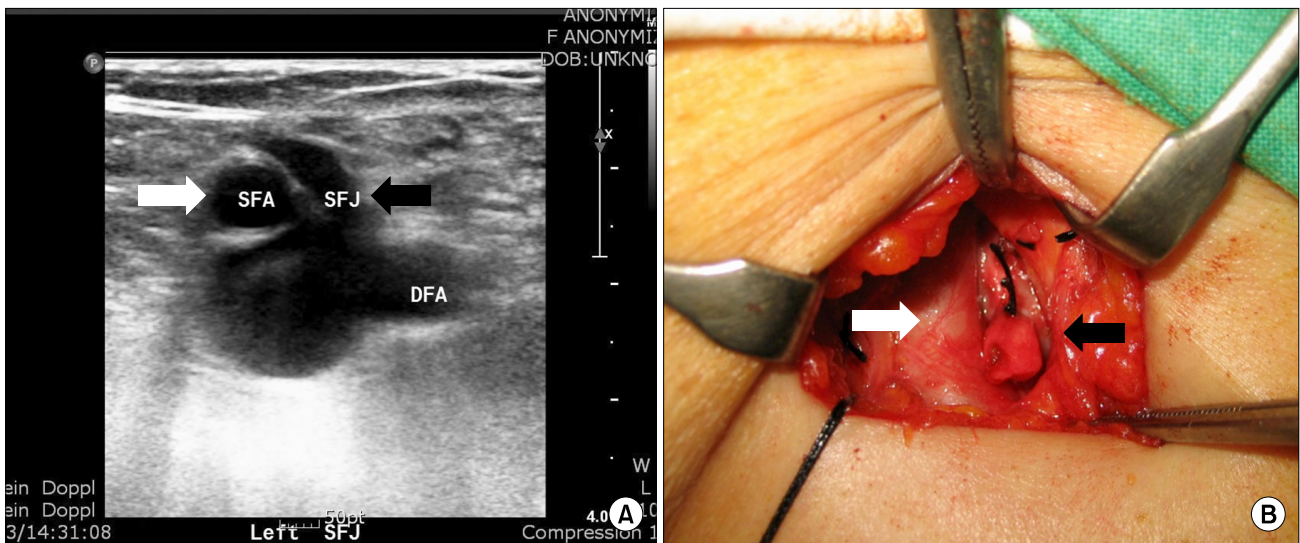
The 12 cases of femoral vessel transposition included 5 cases of complete transposition and 7 cases of incomplete transposition (Table 1). In cases of complete transposition, the superficial femoral artery was transposed and positioned to the medial side of the common femoral vein (Fig. 1). In cases of incomplete transposition, the superficial femoral artery was positioned directly above the common femoral vein and the 2 vessels overlapped by approximately 60% to 100% (Fig. 2).

In all cases of femoral artery and vein transposition, the saphenofemoral junctions were located at the lateral or posterolateral side of the superficial femoral artery, corresponding to complete or incomplete transpositions, respectively. The great saphenous vein crossed over the superficial femoral artery and entered into the common femoral vein. In cases of incomplete transposition, the great saphenous vein trunk was slightly compressed around the superficial femoral artery and traction of the femoral artery was required to perform flush ligation.

In 1 case of separate entrance, preoperative sonography revealed that the separated branches formed a common trunk before connecting to the common femoral vein, and the great saphenous vein trunk



**Fig. 1.** Femoral vessels complete transposition. (A, B) Preoperative sonography and intraoperative findings from the right groin show that the SFJ (black arrow) was positioned at the lateral side of the superficial FA (white arrow). SFJ, saphenofemoral junction; FA, femoral artery; FV, femoral vein.



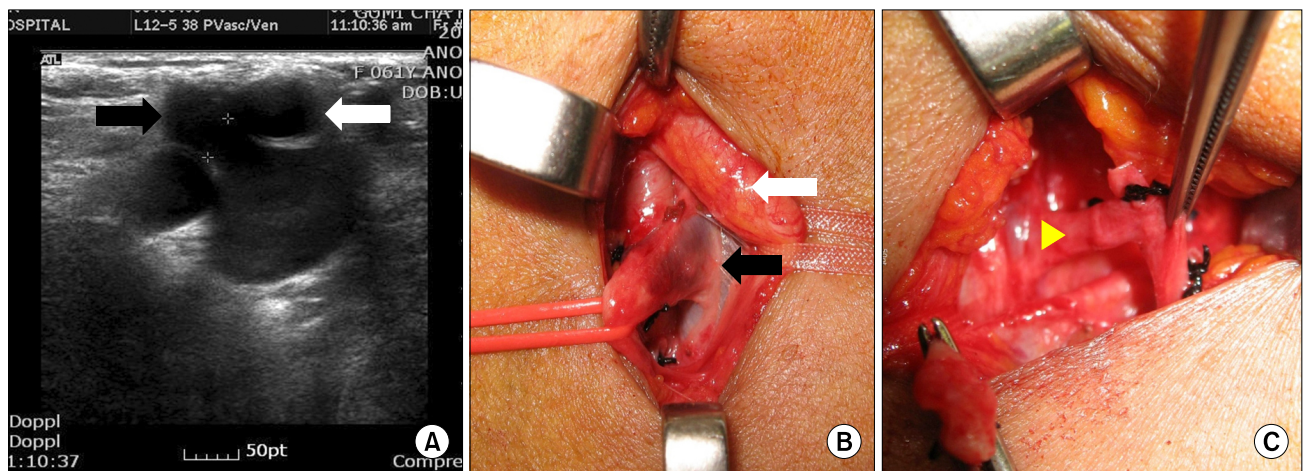
**Fig. 2.** Femoral vessels incomplete transposition. (A, B) Preoperative sonography and intraoperative findings from the left groin show that the SFJ (black arrow) was positioned at the posterolateral side of the SFA (white arrow). SFJ, saphenofemoral junction; SFA, superficial femoral artery; DFA, deep femoral artery.

was connected to the superficial femoral vein. Reflux appeared on the great saphenous vein trunk, but not on the common trunk of the branches. Only the great saphenous vein trunk was stripped out.

In the other case of separate entrance with incomplete transposition, the great saphenous vein trunk crossed over the superficial femoral artery and the saphenofemoral junction was positioned between

the superficial femoral artery and the deep femoral artery. The separated branches formed a common trunk before connecting to the common femoral vein. Operations to both the great saphenous vein trunk and its branches were performed within a small groin incision (Fig. 3).

Among the 12 cases of femoral artery and vein transposition, 8 presented at the left inguinal area



**Fig. 3.** Separate entrance with incomplete transposition. (A, B) Preoperative sonography and intraoperative findings from the right groin show that the saphenofemoral junction (black arrow) was positioned between the superficial femoral artery (white arrow) and the deep femoral artery. (C) The common trunk (yellow arrowhead) of separated branches was connected to the common femoral vein.

and 4 at the right inguinal area. One case of separate entrance and another case of separate entrance with incomplete transposition appeared at the right inguinal area.

## Discussion

Embryologically, the femoral artery begins its development from the external iliac artery during the 14-mm embryo stage. The proximal segment of the axial artery persists to form the inferior gluteal artery, while the middle segment disappears, leaving the femoral artery. Variations in the relationships among the femoral vessels may occur during this stage [6].

Normal variants in the origin and course of the deep femoral artery and variations at the saphenofemoral junction have been well described [2-5], but femoral vessel transposition and separate entrance of the great saphenous vein trunk and its branches have rarely been reported. Until now, 7 cases of femoral vessel transposition and 2 cases of separate entrance have been reported in the literature. Five cases of femoral vessel transposition were detected during varicose vein operations, 1 case was documented in a cadaveric dissection, and 1 other case was detected during a profundoplasty procedure. Two cases of separate entrance of the great saphenous vein trunk and its branches were found during varicose vein operations [7-13].

Marcucci et al. [7] reported 1 case of complete transposition of the femoral artery and vein during varicose vein surgery. The anomaly was not detected with duplex ultrasound, but rather found during the left groin dissection. The saphenofemoral junction and femoral vein were located laterally to the femoral artery. The great saphenous vein trunk crossed over the femoral artery and entered into the transposed femoral vein. The authors successfully performed a stripping operation without complications.

Smith and Dimitri [8] reported a case of femoral vessel transposition. It was not detected in preoperative examinations. During the right groin dissection, they found the superficial femoral artery running medial to the saphenofemoral junction and common femoral vein.

Leite et al. [9] reported 1 case of incomplete transposition. The anomaly was preoperatively detected using duplex ultrasound. Meticulous right groin dissections showed that the great saphenous vein crossed over the femoral artery from the medial to lateral position and was fit around the femoral artery. The saphenofemoral junction was positioned posterolaterally to the femoral artery. Retraction of the femoral artery was required to perform adequate ligation of the saphenofemoral junction.

Lekich et al. [10] described a case of femoral vessel transposition due to high bifurcation of the common femoral artery. Preoperative duplex ultrasound revealed that the saphenofemoral junction and com-

mon femoral vein were located between the superficial femoral artery and deep femoral artery. The authors performed endovenous laser ablation of the left great saphenous vein without any complications. A low energy setting was used to prevent arterial injuries.

Nabatoff [11] reported a case of transposition of the femoral artery and vein in the fossa ovalis encountered during varicose vein surgery. The great saphenous vein was compressed below the transposed femoral artery, so the patient had large varicosities even at her relatively young age, in her early twenties. The great saphenous vein was mobilized and brought out from underneath the femoral artery. The saphenofemoral junction was ligated flush with the femoral vein.

Bandyopadhyay et al. [12] described a case of incomplete transposition of the femoral vessels in the course of cadaveric dissection. The superficial femoral artery crossed medially to the common femoral vein and the saphenofemoral junction due to high bifurcation of the femoral artery just below the inguinal ligament.

Forty [13] reported a case of an anomalous relationship between the femoral artery and vein during right profundaplasty. It was found that the femoral artery was positioned medial to the vein in the region of the femoral triangle. The origin of the deep femoral artery was high and the saphenofemoral junction was located within the femoral bifurcation.

Baum et al. [14] investigated the anatomic relationship between the common femoral artery and vein with 100 computed tomographic scans. The femoral vessels partially overlapped in 65% of 200 pairs of vessels, but greater than 65% overlap or transposition was not found.

In our cases of femoral vessel transposition, the saphenofemoral junctions showed a lateral or posterolateral position in relation to the superficial femoral artery. There are no definitive criteria for complete or incomplete transposition. In this study, authors defined approximately 50% or greater superficial femoral artery positioning medial to the common femoral vein as complete transposition. In cases of incomplete transposition, the superficial femoral artery was positioned directly above the common femoral vein with approximately 60% to 100% overlap, so that traction of the superficial femoral artery

was required to perform flush ligations.

Nabatoff [11] described 2 cases of separate entrance of the great saphenous vein trunk and its branches into the femoral vein. In his cases, all of the branches formed a common trunk before connecting to the femoral vein, and the great saphenous vein trunk entered the femoral vein half an inch distal to the branches. These anomalies were found intraoperatively. He detected the anomalies via thorough exposure of the fossa ovalis and upward stripping passing from the ankle. In our study, 1 case of separate entrance and another case of separate entrance with incomplete transposition were diagnosed in preoperative sonographic examinations. During the operations, we were able to easily ligate and divide the great saphenous vein trunk and its branches separately within the small groin incision.

In conclusion, the authors documented that the consistent anatomy of the saphenofemoral junction within the femoral triangle can sometimes present in an altered form. Detailed preoperative sonographic examinations of the orientation of the femoral vessels are helpful in preventing unexpected complications during operations. Considering the possible anatomical variations, meticulous groin dissection and demarcation of the saphenofemoral junction are essential for successful varicose vein surgery.

### Conflict of interest

No potential conflict of interest relevant to this article was reported.

### References

1. Goldman MP, Bergan JJ. *Sclerotherapy: treatment of varicose and telangiectatic leg veins*. 3rd ed. St. Louis (MO): Mosby; 2001.
2. Donnelly M, Tierney S, Feeley TM. *Anatomical variation at the saphenofemoral junction*. Br J Surg 2005;92:322-5.
3. Chun MH, Han SH, Chung JW, et al. *Anatomical observation on draining patterns of saphenous tributaries in Korean adults*. J Korean Med Sci 1992;7:25-33.
4. Massoud TF, Fletcher EW. *Anatomical variants of the profunda femoris artery: an angiographic study*. Surg Radiol Anat 1997;19:99-103.
5. Bergman RA, Afifi AK, Miyauchi R. *Illustrated encyclopedia of human anatomic variation* [Internet]. [place unknown]: [publisher unknown]; 2015 [cited 2016 Jul 25]. Available

- from: <http://www.anatomyatlases.org/AnatomicVariants/AnatomyHP.shtml>.
6. Greebe J. *Congenital anomalies of the iliofemoral artery*. J Cardiovasc Surg (Torino) 1977;18:317-23.
  7. Marcucci G, Antonelli R, Accrocca F, Siani A. *A rare anomaly of the femoral vessels: complete transposition of the femoral artery and vein*. Interact Cardiovasc Thorac Surg 2010;11:838-9.
  8. Smith RA, Dimitri SK. *Case report: a rare orientation of femoral artery and vein*. EJVES Extra 2006;12:66-7.
  9. Leite JO, Carvalho Ventura I, Botelho FE, Costa Galvao W. *Incomplete transposition of the common femoral artery and vein*. Int Angiol 2010;29:80-2.
  10. Lekich C, Campbell W, Walton S, Hannah P. *Anomalous high bifurcation of the common femoral artery at the groin: management of GSV incompetence with endovenous laser ablation*. Phlebology 2013;28:264-7.
  11. Nabatoff RA. *Anomalies encountered during varicose vein surgery*. Arch Surg 1978;113:586-8.
  12. Bandyopadhyay M, Biswas S, Roy R. *Vessels in femoral triangle in a rare relationship*. Singapore Med J 2010;51:e3-5.
  13. Forty J. *Anomalous relationship between femoral artery and vein: a case report*. Clin Anat 1990;3:195-7.
  14. Baum PA, Matsumoto AH, Teitelbaum GP, Zuurbier RA, Barth KH. *Anatomic relationship between the common femoral artery and vein: CT evaluation and clinical significance*. Radiology 1989;173:775-7.