

ORIGINAL ARTICLE

Multicentre experience with the second-generation subcutaneous implantable cardioverter defibrillator and the intermuscular two-incision implantation technique

Federico Migliore MD, PhD¹  | Giulia Mattesi MD¹ | Pietro De Franceschi MD¹ | Giuseppe Allocca MD² | Martino Crosato MD³ | Vittorio Calzolari MD³ | Mauro Fantinel MD⁴ | Benedetta Ortis MD⁵ | Domenico Facchin MD⁶ | Elisabetta Daleffe MD⁶ | Tommaso Fabris MD¹ | Elena Marras MD⁷ | Manuel De Lazzari MD¹ | Francesco Zanon MD⁸  | Lina Marcantoni MD⁸ | Mariachiara Siciliano MD⁹ | Domenico Corrado MD, PhD¹ | Sabino Iliceto MD¹ | Emanuele Bertaglia MD, PhD¹ | Massimo Zecchin MD⁵

¹Department of Cardiac, Thoracic And Vascular Sciences, University of Padova, Padova, Italy

²Department of Cardiology, Hospital of Conegliano, Treviso, Italy

³Department of Cardiology, Ca' Foncello, Civil Hospital, Treviso, Italy

⁴Department of Cardiology, Civil Hospital, Feltre, Belluno, Italy

⁵Cardiovascular Department, University of Trieste, Trieste, Italy

⁶Cardiology Division, Azienda Sanitaria Universitaria Integrata di Udine and IRCAB Foundation, P.le Santa Maria della Misericordia, Udine, Italy

⁷Department of Cardiology, Dell'Angelo Hospital, Mestre, Italy

⁸Cardiology Department, Arrhythmia And Electrophysiology Unit, Santa Maria Della Misericordia Hospital, Rovigo, Italy

⁹Cardiology Division, Hospital of Cittadella, Padova, Italy

Correspondence

Federico Migliore, MD, PhD, FESC, FEHRA, Department of Cardiac, Thoracic and Vascular Sciences, University of Padova, Italy,

Abstract

Introduction: The recently developed second-generation subcutaneous implantable cardioverter defibrillator (S-ICD) and the intermuscular two-incision implantation technique demonstrate potential favorable features that reduce inappropriate shocks and complications. However, data concerning large patient populations are lacking. The aim of this multicentre prospective study was to evaluate the safety and outcome of second-generation S-ICD using the intermuscular two-incision technique in a large population study.

Methods and Results: The study population included 101 consecutive patients (75% male; mean age, 45 ± 13 years) who received second-generation S-ICD (EMBLEM; Boston Scientific, Marlborough, MA) implantation using the intermuscular two-incision technique as an alternative to the standard implantation technique. Twenty nine (29%) patients were implanted for secondary prevention. Twenty four (24%) patients had a previously implanted transvenous ICD. All patients were implanted without any procedure-related complications. Defibrillation testing was performed in 80 (79%) patients, and ventricular tachycardia was successfully converted at less than or equal to 65 J in 98.75% (79/80) of patients without pulse generator adjustments. During a median follow-up of 21 ± 10 months, no complications requiring surgical revision or local or systemic device-related infections were observed. Ten patients

Migliore and Mattesi have contributed equally as first authors.

This is an open access article under the terms of the Creative Commons Attribution-NonCommercial License, which permits use, distribution and reproduction in any medium, provided the original work is properly cited and is not used for commercial purposes.

© 2019 The Authors. *Journal of Cardiovascular Electrophysiology* Published by Wiley Periodicals, Inc.

Via N. Giustiniani 2, 35121 Padova, Italy.
Email: federico.migliore@libero.it

Disclosures: None.

(9.9%) received appropriate and successful shocks for ventricular arrhythmias. Three (2.9%) patients experienced inappropriate shocks due to oversensing the cardiac signal ($n = 1$), noncardiac signal ($n = 1$), and a combination of both cardiac and noncardiac signals ($n = 1$), with one patient requiring device explantation. No patients required device explantation due to antitachycardia pacing indications.

Conclusions: According to our multicentre study, second-generation S-ICD implanted with the intermuscular two-incision technique is an available safe combination and appears to be associated with a low risk of complications, such as inappropriate shocks.

KEYWORDS

implantable cardioverter defibrillator, intermuscular technique, subcutaneous implantable cardioverter defibrillator, two-incision technique

1 | INTRODUCTION

Current guidelines state that the subcutaneous implantable cardioverter defibrillator (S-ICD) represents a therapeutic option for patients at high-risk of sudden cardiac death, in whom pacing or cardiac resynchronization therapy is not required.¹ The recent development of an entirely S-ICD constitutes a major evolution of defibrillator technology, and there has been consistent clinical evidence regarding its safety.²⁻⁴ The standard S-ICD implantation technique requires three incisions and the placement of a midaxillary pulse generator under subcutaneous tissue. However, various alternative implantation techniques have been explored,³ including the intermuscular two-incision technique.⁴⁻⁶ New techniques may reduce complications such as erosion while improving the esthetic appeal of the pulse generator pocket.^{5,6} Beginning in March 2015, a new generation of the S-ICD device, the EMBLEM device, has been developed and commercially launched by Boston Scientific (Marlborough, MA). The second-generation S-ICD has several favorable features when compared with the first-generation S-ICD, including a smaller generator size, an increased battery life, and a software upgrade, which should further improve S-ICD performance while reducing inappropriate therapies and pocket complications.⁷ In fact, while continuous research in the field of S-ICD technology and implantation technique is ongoing, EMBLEM S-ICD and intermuscular two-incision technique represent the most recent advances. However, midterm data from a large population on the potential advantages of the combination of a second-generation S-ICD and intermuscular two-incision implantation technique are lacking. Thus, the aim of this retrospective multicentre study was to evaluate the safety and outcome of the second-generation S-ICD implanted with the alternative intermuscular two-incision technique.

2 | MATERIALS AND METHODS

The study population of this retrospective multicentre study consisted of patients with indications for ICD implantation according to the current guidelines⁸ who were implanted with a second-generation

S-ICD (EMBLEM A209 or EMBLEM A219; Boston Scientific) with the intermuscular two-incision implantation technique. The subjects were enrolled from nine Italian centers (Department Of Cardiac, Thoracic And Vascular Sciences, University Of Padova, Italy; Department Of Cardiology, Hospital Of Conegliano, Treviso, Italy; Department Of Cardiology, Ca' Foncello, Civil Hospital, Treviso, Italy; Department Of Cardiology Civil Hospital, Feltre, Belluno, Italy; Cardiovascular Department, University Of Trieste, Trieste, Italy; Ospedale S. Maria Della Misericordia, University Of Udine, Udine, Italy; Department Of Cardiology, Dell'Angelo Hospital, Mestre, Italy; Cardiology Department, Arrhythmia and Electrophysiology Unit, Santa Maria Della Misericordia Hospital, Rovigo, Italy; and Cardiology Division, Hospital Of Cittadella, Padova, Italy). Baseline clinical characteristics, electrocardiographic abnormalities, indication for implantation, electrocardiogram (ECG) screening, and technical device characteristics were collected. The local ethics committee approved the study protocol and all patients provided written consent to be enrolled in the registry.

2.1 | S-ICD implantation technique, defibrillation testing, and device programming

Before implantation, all patients were screened for eligibility for S-ICD using the Boston Scientific manual ECG screening tool or the automated screening tool based on the surface ECG limb lead recording over the left and/or right parasternal regions to simulate the three S-ICD sensing vectors. To be eligible for S-ICD implantation, at least one ECG lead (I, II, or III) must satisfy the template (at any gain) in both erect and supine postures. All ECGs screening were reviewed by two experienced electrophysiologists blinded to patients, clinical presentation, and outcome. When there was disagreement, the ECG for that patient was adjudicated by a third independent observer. The procedure was performed in an electrophysiology laboratory under standard sterile conditions and general local anesthesia with conscious sedation or ultrasound-guided serratus anterior plane block.⁹ Antibiotic prophylaxis was administered 1 hour before the procedure. The intermuscular two-incision technique was used for implantation, as previously reported in

detail.⁴ The intermuscular two-incision technique abandons the superior parasternal incision and consists of creating an intermuscular pocket (between the anterior surface of the serratus anterior muscle and the posterior surface of the latissimus dorsi muscle) for the pulse generator rather than a subcutaneous pocket using anatomical landmarks. The position of the lead and pulse generator relative to the heart silhouette is checked by fluoroscopy. An incision is made along the inframammary crease at the anterior edge of the latissimus dorsi. When the latissimus dorsi anterior edge is exposed, the pocket is created by blunt dissection between the superior surface of the serratus anterior muscle and the posterior surface of the latissimus dorsi muscle such that the pulse generator can be placed into the virtual anatomical space between the two muscles. When the serratus anterior is reached, it is important to recognize the change in the fiber pathway (horizontal vs vertical) to preserve the muscular fascia may and thereby minimize bleeding. A 2-cm horizontal incision at the level of the xiphoid process (xiphoid incision) is made in the direction of the pocket incision. The distal tip of the electrode insertion tool (EIT), which is used to create subcutaneous tunnels in which the electrode is placed, is inserted at the xiphoid incision and tunnelled laterally until the distal tip emerges at the device pocket. Conventional suture material is used to tie the anchoring hole of the electrode to the EIT. With the electrode attached, the EIT is pulled back through the tunnel to the xiphoid incision until the proximal sensing electrode emerges. A suture sleeve is placed over the electrode shaft 1 cm below the proximal sensing electrode. The preformed grooves are used to bind the suture sleeve to the electrode shaft using nonabsorbable suture material. The suture that connects the tip of the lead to the EIT is cut and removed. A peel-away sheath is placed over the shaft of the EIT, which is then tunnelled approximately 14 cm superior to the xiphoid incision and approximately 1 to 2 cm to the left or right of the sternal midline. The peel-away sheath is advanced over the EIT until it is fully inserted. The EIT is removed, and the peel-away sheath is left in its subcutaneous position. The electrode is inserted into the subcutaneous sheath until the suture sleeve reaches the opening of the sheath. The sheath is peeled away, leaving the electrode in place. Correct placement of the tip of the lead at the required sternomanubrial location is confirmed digitally. The suture sleeve is secured to the fascia. The proximal end of the lead is inserted into the connector port in the device header of the S-ICD and the screw set is tightened. Thus, the device is located in the intermuscular pocket and anchored to the fascia to prevent possible migration by using conventional nonabsorbable suture material. Particular attention is paid to ensure that the generator is placed posterior and inferior to the incision. Finally, the two muscles (serratus anterior and latissimus dorsi) are sutured using a conventional absorbable suture. Then, after device setup, the two incisions (xiphoid and pocket incisions) are closed using an intradermal suture.

After the procedure, defibrillation testing (DT) is performed after induction of ventricular fibrillation (VF) by 50 Hz stimulation. The DT is considered successful if the device detected and terminated VF using less than or equal to 65 J shock. In all patients, the device programming features included two tachyarrhythmia detection zones: (1) the shock-only zone, in which detection and therapy were based on rate only and (2) an additional "conditional zone," in which a

morphology analysis algorithm was applied in addition to rate. Rate cutoffs were individualized for each patient based on clinical indications. The sensing vector (primary, secondary, or alternate) was automatically selected by the device at the time of implantation and optimized during supine and upright positions before. A chest X-ray was obtained the day after the procedure to confirm stable lead and generator positions. All S-ICD implantations were performed by experienced operators. The decision to perform post-implant DT and the type of anesthesia used were at the discretion of the implanting physician.

2.2 | Follow-Up

All patients were followed up at 1 month and every 3 to 6 months thereafter. At these visits, patients' clinical conditions, S-ICD interrogations, and complications (including device-related complications and inappropriate shocks) were assessed. Perioperative complications were defined as complications that occurred during or within 24 hours of S-ICD implantation and were classified as the following: (1) procedure-related complications, including pneumothorax, pleural effusion, hematoma 2 cm, reduction in hemoglobin more than 2 g/dL, bleeding requiring wound exploration, or transfusion or generator/lead dislocation at the chest X-ray obtained 24 hours after the procedure and (2) technical complications, such as failure of the device to communicate with the programmer. Postoperative complications were defined as those occurring more than 24 hours after the procedure and included: pocket discomfort, pocket hematoma requiring surgical revision, incomplete wound healing, skin erosion of pulse generator or electrode, local and systemic device-related infections, migration of pulse generator or electrode, and technical complications such as failure of the device to communicate with the programmer or premature battery depletion. Captured S-ECG tracings from all shock episodes stored in the S-ICD were obtained and reviewed for details by two electrophysiologists. Interventions were considered inappropriate when triggered by anything other than ventricular tachycardia (VT) or VF above the programmed rate zone, including supraventricular arrhythmias (SVT), cardiac/noncardiac oversensing, or device or lead malfunction. Cardiac oversensing was defined as T-wave oversensing (TWOS), QRS oversensing, P-wave oversensing or oversensing due to a low-amplitude signal, and other/combined types of cardiac oversensing. Noncardiac oversensing was defined as any kind of oversensing due to noncardiac causes (eg, electromagnetic interference and myopotentials). Episodes of inappropriate therapy were reviewed and verified with the Boston Scientific Technical support team.

2.3 | Statistical analysis

Categorical variables are presented as actual numbers and frequencies. Continuous variables are expressed as the mean \pm standard deviation (SD) for normally distributed variables or median (25th–75th percentile) for skewed variables, respectively. All analyses were performed using the SPSS statistic software. Data were analysed with SPSS, version 23 (IBM Corp., Armonk, NY).

3 | RESULTS

3.1 | Study population

The study population of this retrospective multicentre investigation included 101 consecutive patients (76 male; median, 46 [36-52] years; range, 16-74 years) who received S-ICD implantation between April 2015 and September 2018 for SCD prevention. Baseline clinical characteristics are reported in Table 1. Twenty nine (29%) patients were implanted for secondary prevention. One (1%) patient was less than or equal to 18 years of age. At the time of ICD implantation, 78 (77%) patients were being treated with a β -blocker and 17 (17%) were receiving an antiarrhythmic agent. Left ventricular (LV) dysfunction (ejection fraction \leq 50%) was present in 45 (44%) patients. The reason for subcutaneous ICD placement was the presence of previous TV-ICD (patients underwent lead extraction for infection or lead failure) in 24 (24%) patients. In the remaining patients, the choice of implanting an S-ICD rather than a TV-ICD was at the discretion of the physician, which was based on clinical indications in accordance with current guidelines.¹

3.2 | ECG screening

The primary sensing vector was the most compatible (55%), followed by the secondary vector (38%) and the alternate vector (7%). There were no cases with adjudication disagreement.

3.3 | S-ICD implant characteristics

All patients were implanted with a second-generation S-ICD (EMBLEM A209 or Boston Scientific model EMBLEM A219; Boston Scientific). Baseline technical device characteristics are reported in Table 2. The procedure was performed under general anesthesia in 24 (24%) patients, local anesthesia with sedation in 75 (75%), and with ultrasound-guided serratus anterior plane block in two (2%) patients. The average procedure time ("skin to skin") was 68 ± 17 minutes. DT was performed in 80 (79%) patients. Twenty-one patients did not undergo DT because of the presence of intracardiac thrombi in the left atrial appendage ($n = 2$) or the LV apex due to prior myocardial infarction ($n = 1$), persistent atrial fibrillation with interruption of anticoagulation ($n = 3$), presence of advanced cardiomyopathy with severe LV systolic dysfunction, and borderline hemodynamic stability ($n = 5$), patient's rejection ($n = 2$), and physician's choice ($n = 8$). Ventricular tachycardia was successfully converted at less than or equal 65 J standard polarity in 98.75% (79/80) of patients without pulse generator adjustments. In 4/80 (5%) patients, DT was ineffective at standard polarity (at 65 J) but was successful after changing the polarity of the shock. One patient (body mass index [BMI], 23.55; affected by dilated cardiomyopathy) received three ineffective shocks at 65 and 80 J, both at standard and reversed polarity, and required external defibrillation at 200 J. Thus, the device was

TABLE 1 Baseline clinical characteristics of the study population

Characteristics	n = 101
Male sex	76 (75)
Age, y	46 (36-52)
Height, cm	175 (170-182)
Weight, kg	75 (62-82)
BMI mass index	24 (22-27)
LV ejection fraction	50 (33-60)
History of AF	7 (7)
Kidney disease	18 (18)
Hemodialysis for end-stage renal disease	3 (3)
ECG characteristics	
Sinus rhythm	98 (97)
Atrial fibrillation	3 (3)
QRS duration, ms	103 (96-110)
First AVB	4 (4)
LBBB	4 (4)
Previous transvenous ICD	24 (24)
Secondary prevention	29 (29)
Underlying disease	
Dilated cardiomyopathy	17 (17)
Ischemic heart disease	21 (21)
Hypertrophic cardiomyopathy	12 (12)
Arrhythmogenic right ventricular cardiomyopathy	15 (15)
Valvular disease	1 (15)
Brugada syndrome	8 (8)
Long QT syndrome	1 (1)
Idiopathic VF	10 (10)
Congenital heart disease	1 (1)
Others	15 (15)
Medications at implant	
β -Blockers	78 (77)
Antiarrhythmic agents	17 (17)
Diuretics	30 (30)
Ace-inhibitors	43 (43)
Antiplatelets	29 (29)
Anticoagulants	11 (11)

Abbreviations: AVB, atrioventricular block; BMI, body mass index; ECG, electrocardiogram; ICD, implantable cardioverter defibrillator; LBBB, left bundle branch block; LV, left ventricular; VF, ventricular fibrillation. Values are expressed as number/total (%) of patients or median (25th-75th percentile).

explanted at the time of the implant procedure. The mean time from VF induction to shock delivery was 16 ± 3 seconds. No early complications occurred. A postoperative chest radiography confirmed stable device and lead location in all patients. Dual-zone programming for tachyarrhythmia detection was selected in all patients.

TABLE 2 S-ICD implant characteristics

Characteristics	n = 101
Lead position	
Left parasternal	91 (90)
Right parasternal	10 (10)
Programmed sensing vector	
Primary	56 (55)
Secondary	38 (38)
Alternate	7 (7)
Defibrillator testing attempted	80 (79)
Acute VF conversion	79 (99)
Shock impedance, Ω	63 (56-72)
S-ICD programming	
Conditional zone, mean rate (beats/min)	210 (200-220)
Shock zone, mean rate (beats/min)	50 (250-250)

Abbreviations: S-ICD, subcutaneous implantable cardioverter defibrillator; VF, ventricular fibrillation. Values are expressed as number/total (%) of patients or median (25th-75th percentile).

3.4 | Follow-up

During a median follow-up of 21 months (13-29), two (2%) patients required device explantation because of inappropriate shocks ($n = 1$) or unsuccessful defibrillation ($n = 1$). Neither local or systemic device-related infection nor migration of pulse generator was observed. Ten patients (9.9%) received a total of 31 appropriate and successful shock for ventricular arrhythmias (VA; range, 1-11; Figure 1). Of the 10 patients who received appropriate shocks, two patients did not undergo DT postimplantation due to the physician's indication. Three (2.9%) patients experienced five inappropriate shocks (range, 1-3). One patient had dilated cardiomyopathy and experienced inappropriate shocks for oversensing of cardiac signal (SVT). The problem was solved with catheter ablation and increasing the threshold of conditioned intervention from 200 to 220 beats per minute (bpm; Figure 2). The second patient had hypertrophic cardiomyopathy (HCM) and experienced inappropriate shock for oversensing of noncardiac signal (artifacts) due to postural change (while bending the chest downward; Figure 3). The patient's history of shock led us to change the sensing vector from alternative to secondary. Finally, the third patient, who had a history of arrhythmogenic right ventricular cardiomyopathy (ARVC), had inappropriate shocks due to a combination of cardiac and noncardiac signals (noise and TWOS). At the follow-up the patient underwent device explantation and opted for transvenous ICD. No electromagnetic interferences were observed. No patient had the device removed because of a perceived need for antitachycardia pacing (ATP). Two (2%) patients experienced pocket hematoma that did not require surgical revision. Six patients (6%) died during follow-up (four patients died because of refractory heart failure, one patient died due to systemic infection, and one patient experienced sudden death), and two patients received a heart transplantation (one patient received a paracorporeal LV assistance device as bridge to the heart transplantation, see Figure 4).

4 | DISCUSSION

The purpose of our multicentre study was to report the clinical experience of S-ICD using a combination of the new generation S-ICD and the intermuscular two-incision implantation technique. The main objective of this study was to demonstrate the safety and performance of this advancement by evaluating complications, inappropriate shocks rates, and successful conversion rates of both induced and spontaneous VA. The main results were: (1) new generation S-ICD implanted with the two-incision technique is a safe clinical advancement that may prevent both acute and postoperative technical, pocket- and device-related complications, as well as infections during follow-up. In our study, (1) no patients experienced complications requiring surgical revision or device-related infections; (2) the rate of inappropriate shocks appears relatively low (2.9%); (3) this advancement is effective in terminating both induced and clinical VA; and (4) no patients had the device removed because of a perceived need for ATP or pacing.

4.1 | S-ICD implantation technique: Safety and complications

The standard implantation technique of the S-ICD involved three incisions and placement of the pulse generator under the subcutaneous tissue. While S-ICD prevents drawbacks of the transvenous lead, an early experience with traditional implantation technique was associated with sizable rates of complications due to the large-volume pulse generator, including skin erosion, infection, and discomfort, especially, in thin individuals.^{2,4,10-13} For these reasons, new implantation techniques were explored to offer both operative and cosmetic advantages, including the intermuscular two-incision technique and submuscular technique.⁵⁻⁸ The two-incision technique⁸ has been developed first to

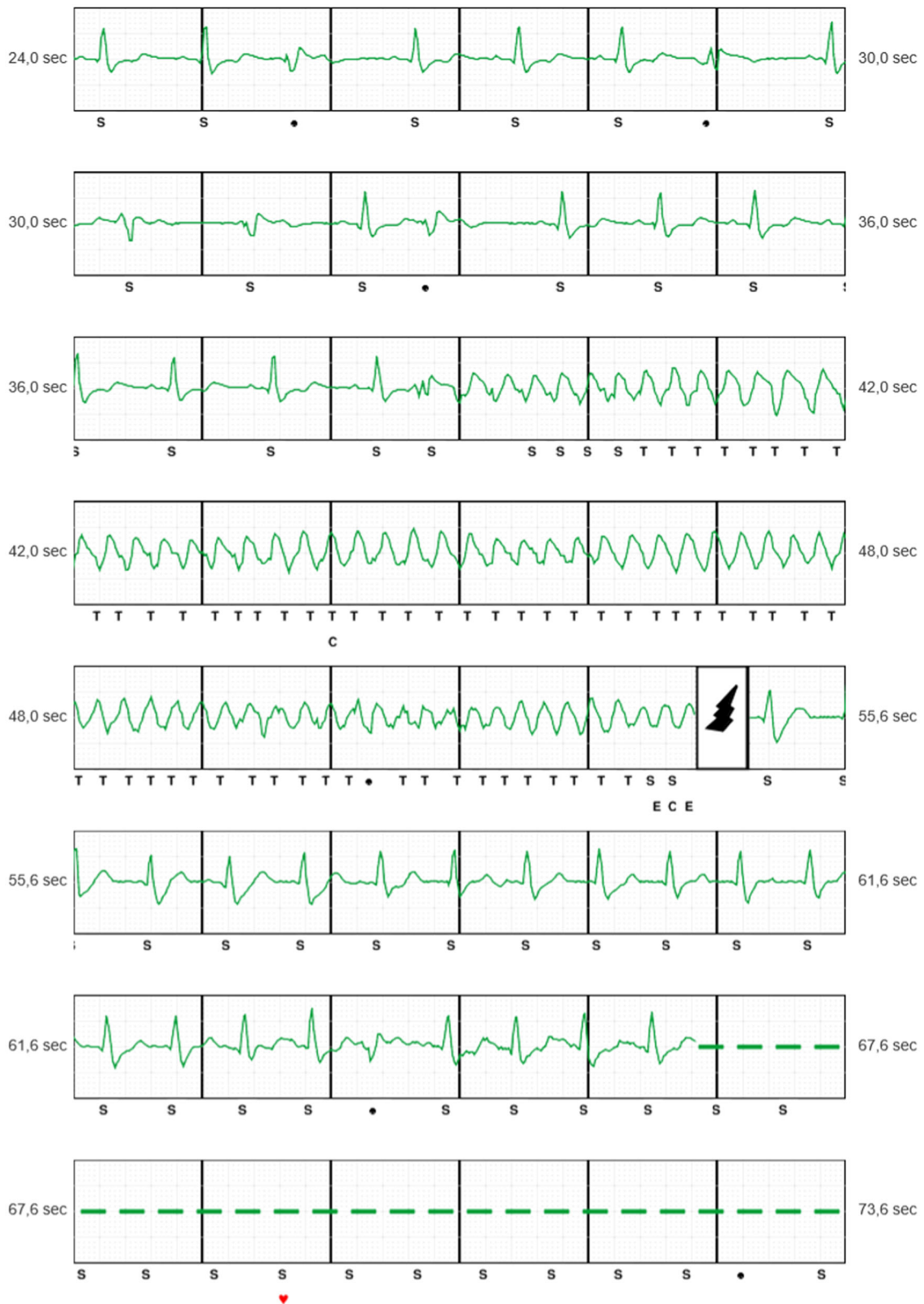

FIGURE 1 Subcutaneous implantable cardioverter defibrillator stored electrogram showing appropriately detected and treated polymorphic ventricular arrhythmia in a patient with hypertrophic cardiomyopathy [Color figure can be viewed at wileyonlinelibrary.com]

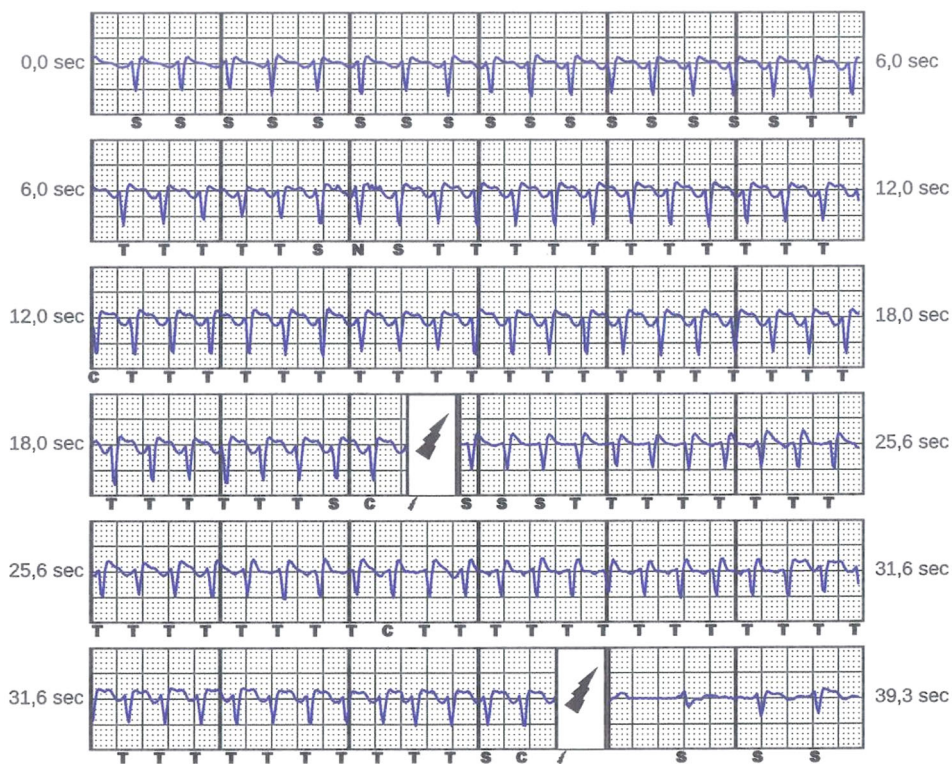


FIGURE 2 Subcutaneous implantable cardioverter defibrillator stored electrogram of inappropriate shock due to supraventricular tachycardia in a patient with dilated cardiomyopathy [Color figure can be viewed at wileyonlinelibrary.com]

prevent potential skin erosion and infection by omitting the superior parasternal incision and to improve the cosmetic result.^{4,8,14} The most commonly adopted technique is the intermuscular two-incision technique. This approach can offer better cosmetic results due to the deeper position of the pulse, and seems to prevent pocket complications and infections.^{6,7} Furthermore, anatomical landmarks ensure the right position of the pulse generator in obese patients.^{6,7} Moreover, using the intermuscular pocket approach, a more posterior placement (dorsally) of the device with less adipose tissue between the pulse generator and the chest (Figure 5) leads to lower defibrillator threshold test (DFT) compared with the traditional technique, and may help in troubleshooting patients with unacceptably high DFT while likely improving sensing performance.^{15–17} In the Investigational Device Exemption (IDE) and EFFORTLESS registry data,⁴ using the conventional approach, 40% of total complications related to the S-ICD system occurred within the first 30 days. Infection and suboptimal pulse generator or electrode position were the most common complications. In our study, no complications occurred during a relatively long follow-up period, which implies a favorable long-term outcome.

Winter et al⁵ conducted a single center study with the first-generation S-ICD, and described the intermuscular pocket technique while addressing its safety and outcome during follow-up. Alongside the displayed long-term safety of the intermuscular technique, patients demonstrated high levels of satisfaction

and outstanding cosmetic results. Recently, our study group in a multicentre registry, including 36 patients who underwent S-ICD using the intermuscular two-incision technique, observed no pocket complications requiring surgical revision or inappropriate therapies.⁶ The present multicentre prospective study, which has the largest study population and a longer, extended follow-up period, confirms these previous results.

In our study, intraoperative-induced arrhythmia conversion success at less than or equal to 65 J without pulse generator adjustments was considerably higher than that reported by previous studies (98.75% vs 90.2–91.2%).^{2,3} In light of the high conversion rate of inducible VT, the question of whether routine testing at implantation is needed, as currently recommended, is raised. The intermuscular approach may improve the ability to defibrillate, especially in patients with thick subcutaneous layers of fat. Gold et al³ demonstrated that body characteristics (height and BMI) were predictors of failed first shock conversion. The dorsal placement of the pulse generator captures more ventricular mass and avoids the subgenerator fat, which results in increased shock impedance and decreases the effective current traversing the heart.^{18–20} Although questionable, increased shock impedance is reported to be associated with failed conversion testing, and, therefore, one might wonder if impedance can be used as a predictor for shock efficacy.¹⁸ Currently, as a rule of thumb, a high impedance more than or equal to 100 Ω is generally considered a risk for lower shock efficacy,¹⁹ as insulation of the

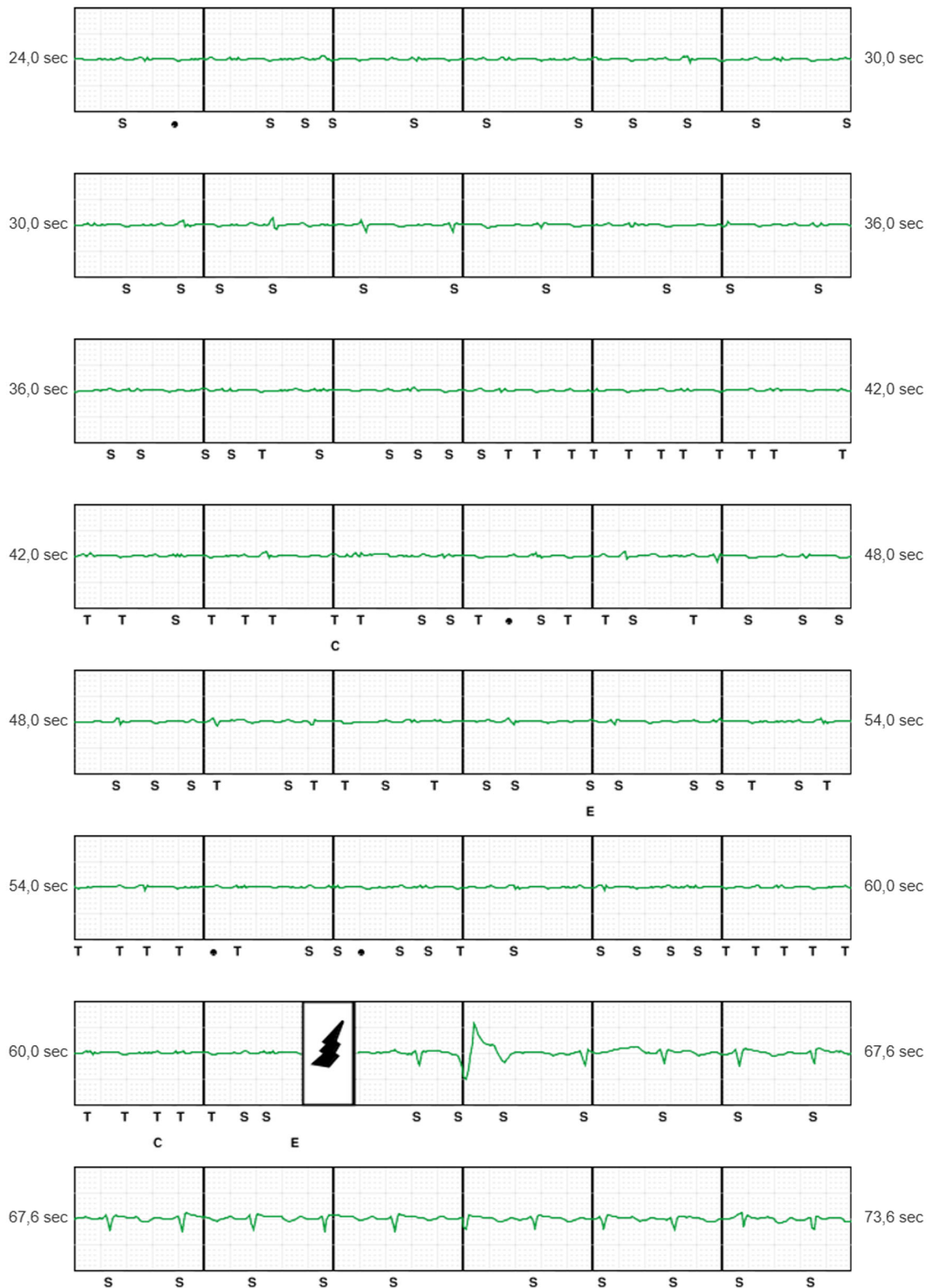


FIGURE 3 Subcutaneous implantable cardioverter defibrillator stored electrogram of inappropriate shock due to artifacts in a patient with hypertrophic cardiomyopathy. Note the low voltage signal in the alternative sensing vector [Color figure can be viewed at wileyonlinelibrary.com]

S-ICD system in adipose tissue increases resistance and creates a less efficient energy gradient. In our study, the mean value of impedance was $66 \pm 12 \Omega$ and no patients reported high impedance.

Recent studies showed that there is a learning curve involved in implanting and programming the S-ICD.²⁰ Thus, we recommend that physicians first become confident with the anatomical landmarks and technical issues of the traditional implantation technique.

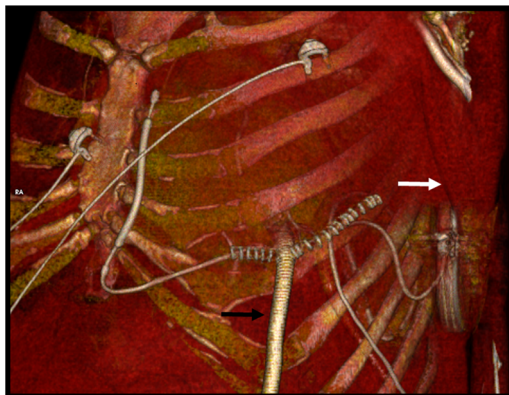


FIGURE 4 Computed tomography scan view obtained in a patient with an subcutaneous implantable cardioverter defibrillator who received a paracorporeal left ventricular assistance device (black arrow) as bridge to heart transplantation. Of note how the pulse generator is under the latissimus dorsi muscle (white arrow) with the intermuscular implantation technique [Color figure can be viewed at wileyonlinelibrary.com]

4.2 | S-ICD and inappropriate shocks

Although implantation of the S-ICDs reduces implant- and lead-related complications, a relatively high rate of inappropriate shocks with important impacts on quality of life was reported in previous studies.²⁻⁴ Events are triggered by cardiac (TWOS and SVT) and noncardiac (noise and myopotential) signals, which are likely to affect the correct detection of VA by S-ICD. In fact, in contrast to the ECG acquired with closely spaced endocardial electrodes, the S-ICD analysis recordings have a lower amplitude and frequency content and are, therefore, more susceptible to postural variations and other coexisting factors. Moreover, the characteristics of the population (young patients or patients affected by cardiomyopathies and channelopathies) that might benefit more from S-ICD will also be those characteristics that lead to markedly abnormal and frequently dynamic ECGs and thus, lead to greater exposure to inappropriate shocks.²¹ Therefore, careful preimplantation evaluation, accurate programming of the device, and storage of a template of aberrancy (ie, during exercise) should be performed.²² TWOS is

the main cause of inappropriate shocks. This problem has been recently overcome by a new double detection algorithm which leads to an 80% reduction of inappropriate shocks. The algorithm was available for a software update for the first-generation SQ-S-ICD device. In 2015, the new S-ICD and EMBLEM S-ICD, with this double detection algorithm as the standard, became available. A study by Larbig et al⁷ showed that an updated device and software update (including the “SMART Pass”) successfully reduced the incidence of TWOS in S-ICD patients, thus encouraging the efforts in the development of new devices and algorithms to reduce the incidence of inappropriate shocks. In contrast with previous studies, we observed a lower rate of inappropriate shocks (2.9%), and TWOS was reported in only one case. This difference can be explained by the different characteristics of the study populations and by technical reasons, such as device programming (single- vs dual-zone programming) and software upgrades. However, whether the new technique for S-ICD implantation may contribute to these excellent results remains to be demonstrated by studies comparing the two techniques (subcutaneous vs intermuscular). It is noteworthy that 27 (27%) patients in our study population presented underlying HCM or ARVC, which are potentially associated with a high risk of inappropriate shocks due to baseline depolarization and repolarization ECG changes,²³ thereby making S-ICD more challenging.

4.3 | Need of ATP and pacing

The European Heart Rhythm Association prospective snapshot survey showed that among factors favouring the use of a transvenous device, despite being a significant economic factor (18.5%), the three most important reasons included: the option of ATP (43.2%), and the current or expected need for CRT (40%) or permanent pacing (39.6%). Interestingly, the patient preference (2.9%), size of the device (1.8%), and aesthetical reasons (0.4%) all had negligible impact.²⁴ This study demonstrated that the potential need of ATP seemed to guide the clinician’s decision-making. In fact, only a few patients (1-2%/annum) will develop an indication for pacing therapy.²³ In the long-term follow-up of the entire EFFORTLESS and PAS registry cohorts,^{2,3} only 0.5%

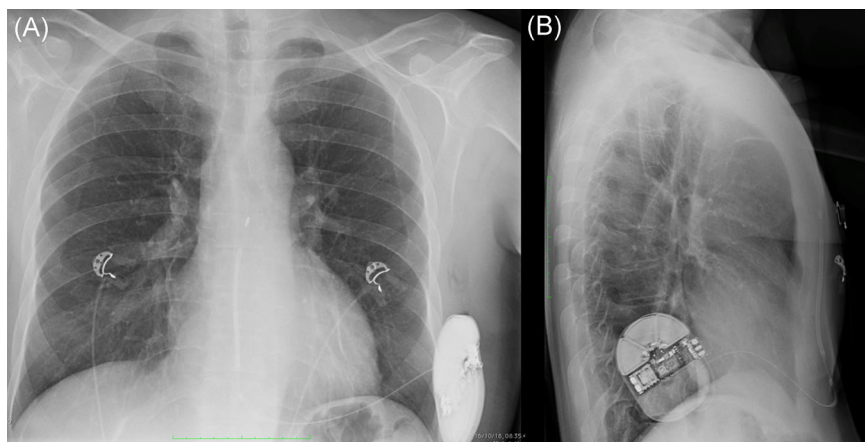


FIGURE 5 Chest X-ray anteroposterior view (A), and lateral view (B) after S-ICD implantation using the intermuscular two-incision technique. Note the virtual space between the pulse generator and the posterior placement (dorsal) of the device that may provide an improved vector toward the shocking coil capturing more left ventricular mass compared with the conventional subcutaneous approach

had the device removed for conceived need for ATP. In the PAS study, combination of the cohorts with recurrent MVT and exchange for ATP led to an annualized rate of 0.9% patients who might have benefitted from ATP.³ The MADIT-RIT study showed that the programming of ICD therapies for tachyarrhythmias of 200 bpm or higher, or with a prolonged delay in therapy at 170 bpm or higher compared with conventional programming, was associated with reductions in inappropriate therapy and all-cause mortality during long-term follow-up.²⁵ These findings bring into question the usefulness of ATP therapy and strongly argue that, in addition to patients with previous recurrent MVT, the lack of ATP in the S-ICD should not be a factor in selecting appropriate patients for this technology.

4.4 | Limitations

A potential limitation of the intermuscular two-incision technique could be a possible greater complexity for battery replacement. However, we believe that both the long battery life of the current EMBLEM S-ICD system as well as the reduction of acute and late complications may overcome this limitation. Another limitation is that our study sample mostly comprised young patients with ion channel diseases or cardiomyopathies with preserved or mildly reduced LV ejection fractions, and thus is not representative of the overall population receiving an ICD. Moreover, our study is biased because of its retrospective nature and because of the participation of selected centers. Although we reported a systematic implantation technique, the decision to perform postimplantation DT was left to physician discretions and center preference. However, DT was performed successfully in the majority of patients. Of note, two patients who did not undergo DT experienced appropriate and successful shocks for VA during follow-up. Moreover, all procedures were performed by experienced operators, and therefore, our results may not be widely applicable in less experienced centers. Finally, even if our data were collected from a multicentre registry with the largest study population observed to date, with the most recent advances of S-ICD (EMBLEM S-ICD and the intermuscular two-incision technique), larger-scale, randomized prospective studies should be conducted in the future to verify our findings and to compare the clinical success and safety of different techniques.

5 | CONCLUSIONS

According to our multicentre study, second-generation S-ICD implanted with the intermuscular two-incision technique is a safe combination and appears to be associated with a low risk of complications, such as inappropriate shocks.

AUTHOR CONTRIBUTIONS

FM: concept/design, data analysis/interpretation, drafting article, critical revision of article, approval of article, statistics, funding secured by, data collection. GM: data collection, data analysis/interpretation, critical revision of article. PD: data collection, data analysis/interpretation,

critical revision of article. GA, MC, VC, MF, BO, DF, ED, TF, EM, MD, FZ, LM, and MS: data collection, critical revision of article. DC and MZ: data collection, critical revision of article, data analysis/interpretation, drafting article. SI and EB: critical revision of article.

ORCID

Federico Migliore  <http://orcid.org/0000-0001-8574-9421>

Francesco Zanon  <http://orcid.org/0000-0003-2673-3918>

REFERENCES

- Al-Khatib SM, Stevenson WG, Ackerman MJ, et al. AHA/ACC/HRS guideline for management of patients with ventricular arrhythmias and the prevention of sudden cardiac death: executive summary: a report of the american college of cardiology/american heart association task force on clinical practice guidelines and the heart rhythm society. *Heart Rhythm*. 2017;2018(15):e190-e252.
- Boersma L, Barr C, Knops R, et al. EFFORTLESS Investigator Group. Implant and midterm outcomes of the subcutaneous implantable cardioverter-defibrillator registry the EFFORTLESS study. *J Am Coll Cardiol*. 2017;70:830-841.
- Gold MR, Aasbo JD, El-Chami MF, et al. Post-approval study: clinical characteristics and perioperative results. *Heart Rhythm*. 2017;14:1456-1463.
- Migliore F, Allocca G, Calzolari V, et al. Intermuscular two-incision technique for subcutaneous implantable cardioverter defibrillator implantation: results from a multicenter registry. *Pacing Clin Electrophysiol*. 2017;40:278-285.
- Winter J, Siekiera M, Shin DI, et al. Intermuscular technique for implantation of the subcutaneous implantable cardioverter defibrillator: long-term performance and complications. *Europace*. 2017;19:2036-2041.
- Knops RE, Olde Nordkamp LR, de Groot JR, Wilde AA. Two-incision technique for implantation of the subcutaneous implantable cardioverter defibrillator. *Heart Rhythm*. 2013;10:1240-1243.
- Larbig R, Motloch LJ, Bettin M, et al. Device updates successfully reduce T-wave oversensing and inappropriate shocks in subcutaneous ICD patients. *Neth Heart J*. 2018;26:606-611.
- Priori S, Blomström-Lundqvist C, Mazzanti A, et al. ESC Scientific Document Group. ESC guidelines for the management of patients with ventricular arrhythmias and the prevention of sudden cardiac death: the task force for the management of patients with ventricular arrhythmias and the prevention of sudden cardiac death of the European Society of Cardiology (ESC). *Eur Heart J*. 2015;2015(36):2793-2867.
- Droghetti A, Basso Ricci E, Scimia P, Harizai F, Marini M. Ultrasound-guided serratus anterior plane block combined with the two-incision technique for subcutaneous ICD implantation. *Pacing Clin Electrophysiol*. 2018;41:517-523.
- Jarman JWE, Todd DM. United Kingdom national experience of entirely subcutaneous implantable cardioverter-defibrillator technology: important lessons to learn. *Europace*. 2013;15:1158-1165.
- Jarman JWE, Lascelles K, Wong T, Markides V, Clague JR, Till J. Clinical experience of entirely subcutaneous implantable cardioverter-defibrillators in children and adults: cause of caution. *Eur Heart J*. 2012;33:1351-1359.
- Pettit SJ, McLean A, Colquhoun I, Connelly D, McLeod K. Clinical experience of subcutaneous and transvenous implantable cardioverter defibrillators in children and teenagers. *Pacing Clin Electrophysiol*. 2013;36:1532-1538.

13. Calvagna GM, Ceresa F, Patane S. Pocket infection as a complication of a subcutaneous implantable cardioverter-defibrillator. *Int J Cardiol.* 2014;177:616-618.
14. Boersma L, Burke MC, Neuzil P, et al. EFFORTLESS and IDE Study Investigators. Infection and mortality after implantation of a subcutaneous ICD after transvenous ICD extraction. *Heart Rhythm.* 2016;13:157-164.
15. Heist KE, Belalcazar A, Stahl W, Brouwer TF, Knops RE. Determinants of subcutaneous Implantable cardioverter-defibrillator efficacy: a computer modeling study. *JACC Clin Electrophysiol.* 2017;3:405-414.
16. Heist EK, Stahl W, Belalcazar A. Impact of generator location and sub-coil fat on 286 subcutaneous-ICD defibrillation thresholds. *Heart Rhythm.* 2017;14(5 Suppl 1):S102.
17. Quast A-FBE, Baalman SWE, Brouwer TF, et al. A novel tool to evaluate the implant position and predict defibrillation success of the subcutaneous implantable defibrillator: the PRAETORIAN score. *Heart Rhythm.* 2019;16(3):403-410.
18. Saltzman HE, Angel B, Overcash J, Kutalek S. Increased shock impedance is associated with failed subcutaneous implantable cardioverter defibrillator defibrillation threshold testing. *J Am Coll Cardiol.* 2017;69(11 suppl):351.
19. Di Girolamo E, Furia N, Faustino M, et al. Is shock impedance value alone to be considered a good predictor for shock efficacy in subcutaneous implantable cardioverter defibrillator? *Clin Case Rep.* 2018;6(4):574-577.
20. Knops RE, Brouwer TF, Barr CS, et al. IDE and EFFORTLESS investigators. The learning curve associated with the introduction of the subcutaneous implantable defibrillator. *Europace.* 2016;18:1010-1015.
21. Migliore F, Pelliccia F, Autore C, et al. Subcutaneous implantable cardioverter defibrillator in cardiomyopathies and channelopathies. *J Cardiovasc Med.* 2018;19:633-642.
22. Migliore F, Bertaglia E, Zorzi A, Corrado D. Subcutaneous implantable cardioverter-defibrillator and arrhythmogenic right ventricular cardiomyopathy: the importance of repeat ECG screening during exercise test. *JACC Clin Electrophysiol.* 2017;3:785-786.
23. de Bie MK, Thijssen J, van Rees JB, et al. Suitability for subcutaneous defibrillator implantation: results based on data from routine clinical practice. *Heart.* 2013;99:1018-1023.
24. Boveda S, Lenarczyk R, Fumagalli S, et al. Factors influencing the use of subcutaneous or transvenous implantable cardioverter-defibrillators: results of the European Heart Rhythm Association prospective survey. *Europace.* 2018;20:887-892.
25. Sedláček K, Ruwald AC, Kutylifa V, et al. MADIT-RIT Investigators. The effect of ICD programming on inappropriate and appropriate ICD Therapies in ischemic and nonischemic cardiomyopathy: the MADIT-RIT trial. *J Cardiovasc Electrophysiol.* 2015;26:424-433.

How to cite this article: Migliore F, Mattesi G, Franceschi PD, et al. Multicentre experience with the second-generation subcutaneous implantable cardioverter defibrillator and the intermuscular two-incision implantation technique. *J Cardiovasc Electrophysiol.* 2019;30:854-864.
<https://doi.org/10.1111/jce.13894>