

Bilateral agenesis of maxillary permanent canines: Review of the literature

Ali Borzabadi-Farahani

ABSTRACT

Oligodontia, or agenesis of six or more teeth, excluding third molars, which involves canine agenesis is rare, and restorative management can be challenging. Bilateral agenesis of a permanent canine in the general population often indicates a several missing adult teeth. The most common sign of it is the primary canine retention beyond its exfoliation age. The multistage restorative management includes the early diagnosis, excluding associated medical problems as well as assessment of patient's malocclusion and facial skeletal pattern, life span of deciduous teeth, possibility of premolar substitution, minimum required number of prosthetic units, patient's preferences, and the cost of treatment. A 10-year-old boy with bilateral agenesis of maxillary permanent canines is described. Some thoughts on the multidisciplinary restorative management of this case are discussed.

Key words: Maxillary permanent canine agenesis, oligodontia, premolar substitution

INTRODUCTION

The present case report describes a rare form hypodontia, bilateral agenesis of maxillary permanent canines.^[1-3] A severe form of hypodontia or oligodontia refers to the absence of more than six teeth, excluding third molars, affecting about 1% of the population (0.08–1.1%) and 0.25% of the European population.^[4,5] Oligodontia is often associated with the positional and morphological changes of remaining teeth^[3] as well as growth disturbances of the maxillofacial skeleton.^[3,6-8] The absence of permanent canines, first molars, and second molars are extremely rare, often seen in association with oligodontia, in particular syndromic oligodontia.^[9,10]

The agenesis of a permanent canine^[11] and particularly a missing maxillary canine in a non-syndromic subject are extremely rare.^[12-17] Early diagnosis of ectopic or missing maxillary canines is important. The late detection of ectopic or missing maxillary canines may lead to serious complications.^[18-20] Similarly, with syndromic canine agenesis^[8] early detection and identifying the associated medical conditions is of the essence. Here, a 10-year-old boy with bilateral maxillary canine agenesis is presented.

Warwick Dentistry, Warwick Medical School, University of Warwick, Coventry, United Kingdom

Address for correspondence: Dr. Ali Farahani,
Warwick Dentistry, Warwick Medical School, University of Warwick,
Coventry, United Kingdom.
E-mail: faraortho@yahoo.com

CASE REPORT

A 10-year-old boy was referred for an orthodontic examination with a chief complaint of deep bite. Medical history was not contributory. Patient presented with a Class II division 2 malocclusion on a Class II skeletal base. Clinical examination revealed normal temporo-mandibular joint and mandibular movements. Examination revealed no significant facial asymmetry with a convex and a slightly retrognathic profile and reduced lower facial height [Figure 1]. The gingival exposure was normal on smiling. The intraoral examination revealed an early permanent dentition with a deep overbite, overlapping of upper central incisors, and retained deciduous maxillary lateral incisors and canines, as well as retained deciduous molars [Figure 2a-c]. Oral hygiene was fair, and caries was absent.

Radiographic examination revealed the absence of permanent maxillary lateral incisors, canines, and the right second premolar [Figure 3a]. In the mandibular arch, both second premolars and lower left lateral incisor were absent [Figure 3a]. The decision was made to review the patient and to assess the prognosis of retained deciduous teeth. Meanwhile, it was decided to liaise with various experts to develop a definitive treatment plan. The patient was reviewed for approximately

Access this article online

Quick Response Code:



Website:

www.jorthodsci.org

DOI:

10.4103/2278-0203.149614

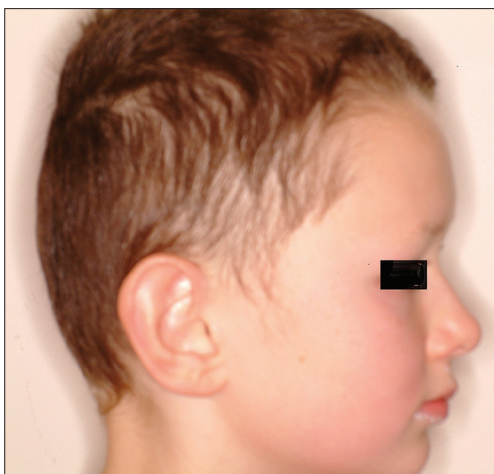


Figure 1: Profile view of the patient

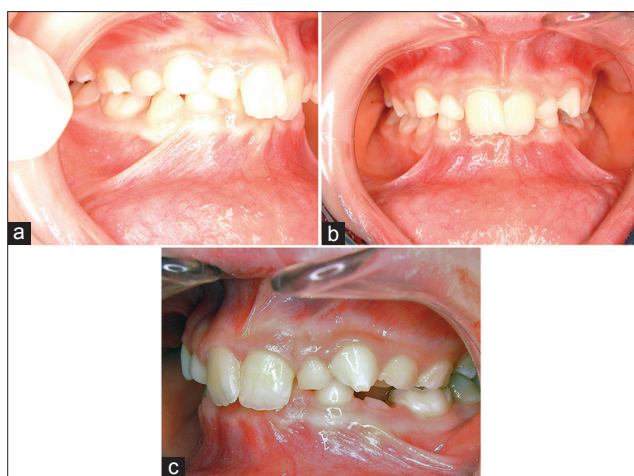


Figure 2: (a-c) Intra-oral photos show retained right maxillary and mandibular deciduous second molars, retained maxillary deciduous lateral incisors and canines, and retained left mandibular deciduous second molar. The lower left lateral incisor is absent, but it is not seen in the anterior occlusal view

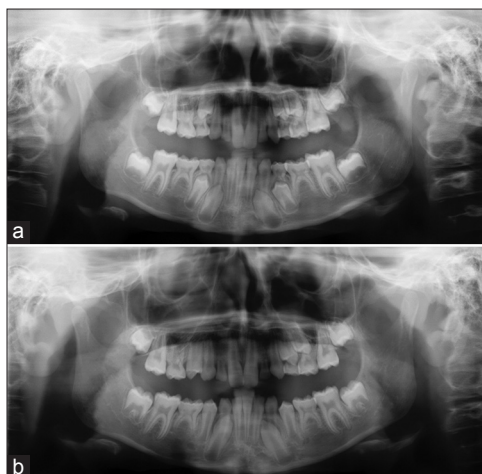


Figure 3: (a and b) Panoramic radiograph at the initial examination, above teeth were missing: The consecutive panoramic radiograph was taken 18 months later (below). Retained deciduous maxillary lateral incisors and mandibular second molars showed some degree of root resorption

18 months, and consecutive panoramic view showed some degree of progressive root resorption in deciduous mandibular molars and maxillary lateral incisors [Figure 3b]. The maxillary deciduous canines displayed no root resorption in the initial and consecutive radiographic examinations [Figure 3a and b]. It was also noted the subject's siblings suffered from a mild form of hypodontia.

DISCUSSION

The deciduous maxillary canines are the most commonly reported retained deciduous tooth; they are more likely to become impacted.^[21] The incidence of maxillary canine impaction is approximately 2% and is twice more common in females than males.^[22,23] The average ages of exfoliation for deciduous maxillary canines are 11.6 and 10.75 years for males and females, respectively.^[21] The absence of labial bulges in a 10-year-old patient often indicates an eruption disturbance of a permanent canine,^[24] and, therefore, radiographic examination is advisable at this age.^[25,26] Compared to retained deciduous molars, deciduous canines are more likely to show little or no sign of root resorption.^[27]

Hypodontia often characterized by retention of deciduous teeth beyond their shedding age. Approximately, 80% of individuals with hypodontia lack only one or two teeth.^[28] Third molars are the most common missing teeth, that is, 25% of the population,^[1] followed by permanent second premolars and upper lateral incisors.^[9] The number and pattern of missing teeth in this patient were unusual; he presented with a rare form of oligodontia, that is, severe hypodontia of 7 teeth involving both maxillary permanent canines.^[12-17]

Hypodontia is seen with many syndromes, but most frequently with X-linked ectodermal dysplasia.^[6,8] Oligodontia may be associated with other ectodermal abnormalities and syndromes, and consequently, treatment of these patients needs a multidisciplinary approach.^[6,8] Nearly 15% of patients missing eight or more permanent teeth were affected with a syndrome such as ectodermal dysplasia;^[29] the isolated form of oligodontia has been associated with mutations in EDARADD, AXIN2, MSX1, and PAX9 genes.^[30] The isolated agenesis of maxillary permanent canines has been associated with mutations of WNT10A gene.^[31] There are indications that the incidence of permanent canines agenesis is higher in females, and it commonly affects the maxilla, in particular the left side.^[11,16,32] Considering the rare and unusual pattern of hypodontia, there was some suspicion this child may have some associated medical conditions (i.e. variant of ectodermal dysplasia). Therefore, a medical geneticist was asked to evaluate the patient. The result of medical examination; however excluded this.

The treatment objective for this patient would be to minimize or consolidate the edentulous space, reduce the number of dental units (implants) required for restoration of the dentition,

that is, without compromising facial profile, dental aesthetics, or function.^[33,34] The clinician should evaluate each dental arch and assess if extraction of selected deciduous teeth results in guided eruption, reduction in edentulous space size and the need for artificial replacement of teeth. For instance, with guided eruption and orthodontic treatment, premolar substitution for missing maxillary canines can be considered.^[33] With premolar substitution, a clinician would eventually only need to replace lateral incisors and right second premolar. It is sensible to avoid placing implants in maxillary canine regions, considering the functional trauma in that area,^[33,34] however, replacing the deciduous canines with implants has been reported.^[35]

In the mandibular arch, deciding whether the occlusion sets up properly with three mandibular incisors is important, which is determined by assessing the tooth size relationships between maxillary and mandibular incisors.^[36] At the end of treatment, some increased overjet would be unavoidable due to the present tooth size discrepancy. In the mandibular arch, establishing whether extraction of the mandibular second deciduous molars results in permanent molars shifting forward to take up space for missing second premolars is critical. This is determined to a great degree by the patient's overall skeletal pattern. With a steep mandibular plane, teeth will drift forward more easily;^[37] analyzing the patient's radiographic cephalogram determines that. It is advisable to keep in mind the overall goal of trying to reduce the number of teeth that eventually needs to be replaced. Within this context, the uses of mini-implants^[38] help in mesialization of maxillary and mandibular dentition, space closure, and premolar substitution.

A treatment plan to extract the maxillary deciduous lateral incisors, maxillary left deciduous second molar and deciduous mandibular second molars as well as orthodontic space redistribution was formulated. It was suggested to provide 3 implant-supported restorations in maxillary lateral incisors and maxillary right first premolar areas, after completion of facial growth. Deciduous canines showed a good survival rate; however, the life span of deciduous molars was not promising.^[27] Considering the age and remaining growth potential for this patient, it was decided to keep deciduous canines and eventually replaced them with implants.

In summary, agenesis of permanent canines is often part of a bigger picture, including severe hypodontia and associated medical problems. The ability to predict the long-term prognosis of retained deciduous teeth without permanent successors would be of considerable value. In a multi-stage restorative therapy many factors should be considered such as the early diagnosis of agenesis, associated medical problems, patient's malocclusion and facial skeletal pattern, life span of deciduous teeth, minimum number of required prosthetic units, patient's preferences, and the treatment cost.

REFERENCES

1. Matalova E, Fleischmannova J, Sharpe PT, Tucker AS. Tooth agenesis: From molecular genetics to molecular dentistry. *J Dent Res* 2008;87:617-23.
2. Schalk-van der Weide Y, Steen WH, Bosman F. Distribution of missing teeth and tooth morphology in patients with oligodontia. *ASDC J Dent Child* 1992;59:133-40.
3. Vahid-Dastjerdi E, Borzabadi-Farahani A, Mahdian M, Amini N. Non-syndromic hypodontia in an Iranian orthodontic population. *J Oral Sci* 2010;52:455-61.
4. Sarnäs KV, Rune B. The facial profile in advanced hypodontia: A mixed longitudinal study of 141 children. *Eur J Orthod* 1983;5:133-43.
5. Schalk-van der Weide Y, Beemer FA, Faber JA, Bosman F. Symptomatology of patients with oligodontia. *J Oral Rehabil* 1994;21:247-61.
6. Bergendal B, Bergendal T, Hallonsten AL, Koch G, Kuro J, Kvint S. A multidisciplinary approach to oral rehabilitation with osseointegrated implants in children and adolescents with multiple aplasia. *Eur J Orthod* 1996;18:119-29.
7. Nodal M, Kjaer I, Solow B. Craniofacial morphology in patients with multiple congenitally missing permanent teeth. *Eur J Orthod* 1994;16:104-9.
8. Cobourne MT. Familial human hypodontia – is it all in the genes? *Br Dent J* 2007;203:203-8.
9. Symons AL, Stritzel F, Stamation J. Anomalies associated with hypodontia of the permanent lateral incisor and second premolar. *J Clin Pediatr Dent* 1993;17:109-11.
10. Brook AH, Elcock C, al-Sharood MH, McKeown HF, Khalaf K, Smith RN. Further studies of a model for the etiology of anomalies of tooth number and size in humans. *Connect Tissue Res* 2002;43:289-95.
11. Rózsa N, Nagy K, Vajó Z, Gábris K, Soós A, Alberth M, *et al.* Prevalence and distribution of permanent canine agenesis in dental paediatric and orthodontic patients in Hungary. *Eur J Orthod* 2009;31:374-9.
12. Keniry AJ. Congenital absence of permanent maxillary canines. A case report. *Dent Pract Dent Rec* 1965;16:133-4.
13. Hillam DG. Congenital absence of permanent maxillary canines. *Dent Pract Dent Rec* 1970;20:268-70.
14. Lum YM, Lim ST. Four cases of congenitally missing permanent cuspids. *Singapore Dent J* 1976;2:49-51.
15. Leong P, Calache H. Bilateral congenitally missing maxillary canines. A case report. *Aust Dent J* 1999;44:279-82.
16. Cho SY, Lee CK, Chan JC. Congenitally missing maxillary permanent canines: Report of 32 cases from an ethnic Chinese population. *Int J Paediatr Dent* 2004;14:446-50.
17. Lombardo C, Barbato E, Leonardi R. Bilateral maxillary canines agenesis: A case report and a literature review. *Eur J Paediatr Dent* 2007;8:38-41.
18. Ericson S, Kuro J. Incisor resorption caused by maxillary cuspids. A radiographic study. *Angle Orthod* 1987;57:332-46.
19. Power SM, Short MB. An investigation into the response of palatally displaced canines to the removal of deciduous canines and an assessment of factors contributing to favourable eruption. *Br J Orthod* 1993;20:215-23.
20. Rimes RJ, Mitchell CN, Willmot DR. Maxillary incisor root resorption in relation to the ectopic canine: A review of 26 patients. *Eur J Orthod* 1997;19:79-84.
21. Stanley HR, Collett WK, Hazard JA. Retention of a maxillary primary canine: Fifty years above and beyond the call of duty. *ASDC J Dent Child* 1996;63:123-30.
22. Proffit WR, Fields HW, Sarver DM. *Contemporary Orthodontics*. 4th ed. St. Louis: Mosby; 2007. p. 234-67.
23. Cooke J, Wang HL. Canine impactions: Incidence and management. *Int J Periodontics Restorative Dent* 2006;26:483-91.
24. Bishara SE. Impacted maxillary canines: A review. *Am J Orthod Dentofacial Orthop* 1992;101:159-71.
25. Fox NA, Fletcher GA, Horner K. Localising maxillary canines using dental panoramic tomography. *Br Dent J* 1995;179:416-20.

26. Ferguson JW. Management of the unerupted maxillary canine. *Br Dent J* 1990;169:11-7.
27. Haselden K, Hobkirk JA, Goodman JR, Jones SP, Hemmings KW. Root resorption in retained deciduous canine and molar teeth without permanent successors in patients with severe hypodontia. *Int J Paediatr Dent* 2001;11:171-8.
28. Lidral AC, Reising BC. The role of MSX1 in human tooth agenesis. *J Dent Res* 2002;81:274-8.
29. Worsaae N, Jensen BN, Holm B, Holsko J. Treatment of severe hypodontia-oligodontia – an interdisciplinary concept. *Int J Oral Maxillofac Surg* 2007;36:473-80.
30. Bergendal B, Klar J, Stecksén-Blicks C, Norderyd J, Dahl N. Isolated oligodontia associated with mutations in EDARADD, AXIN2, MSX1, and PAX9 genes. *Am J Med Genet A* 2011;155A: 1616-22.
31. Kantaputra P, Kaewgahya M, Kantaputra W. WNT10A mutations also associated with agenesis of the maxillary permanent canines, a separate entity. *Am J Med Genet A* 2014;164A: 360-3.
32. Fukuta Y, Totsuka M, Takeda Y, Yamamoto H. Congenital absence of the permanent canines: A clinico-statistical study. *J Oral Sci* 2004;46:247-52.
33. Borzabadi-Farahani A. Orthodontic considerations in restorative management of hypodontia patients with endosseous implants. *J Oral Implantol* 2012;38:779-91.
34. Borzabadi-Farahani A, Zadeh HH. Adjunctive orthodontic applications in dental implantology. *J Oral Implantol* 2013, doi: 10.1563/AAID-JOI-D-13-00235.
35. Mazor Z, Peleg M, Redlich M. Immediate placement of implants in extraction sites of maxillary impacted canines. *J Am Dent Assoc* 1999;130:1767-70.
36. Bolton WA. The clinical application of a tooth-size analysis. *Am J Orthod* 1962;48:504-29.
37. Houston WJ. Mandibular growth rotations – their mechanisms and importance. *Eur J Orthod* 1988;10:369-73.
38. Kanomi R. Mini-implant for orthodontic anchorage. *J Clin Orthod* 1997;31:763-7.

How to cite this article: Borzabadi-Farahani A. Bilateral agenesis of maxillary permanent canines: Review of the literature. *J Orthodont Sci* 2015;4:26-9.

Source of Support: Nil, **Conflict of Interest:** None declared.

Author Help: Online submission of the manuscripts

Articles can be submitted online from <http://www.journalonweb.com>. For online submission, the articles should be prepared in two files (first page file and article file). Images should be submitted separately.

1) **First Page File:**

Prepare the title page, covering letter, acknowledgement etc. using a word processor program. All information related to your identity should be included here. Use text/rtf/doc/pdf files. Do not zip the files.

2) **Article File:**

The main text of the article, beginning with the Abstract to References (including tables) should be in this file. Do not include any information (such as acknowledgement, your names in page headers etc.) in this file. Use text/rtf/doc/pdf files. Do not zip the files. Limit the file size to 1 MB. Do not incorporate images in the file. If file size is large, graphs can be submitted separately as images, without their being incorporated in the article file. This will reduce the size of the file.

3) **Images:**

Submit good quality color images. Each image should be less than 4096 kb (4 MB) in size. The size of the image can be reduced by decreasing the actual height and width of the images (keep up to about 6 inches and up to about 1800 x 1200 pixels). JPEG is the most suitable file format. The image quality should be good enough to judge the scientific value of the image. For the purpose of printing, always retain a good quality, high resolution image. This high resolution image should be sent to the editorial office at the time of sending a revised article.

4) **Legends:**

Legends for the figures/images should be included at the end of the article file.