

# Internuclear ophthalmoplegia as a presenting feature in a COVID-19-positive patient

Varshitha Hemanth Vasanthpuram,<sup>1</sup> Akshay Badakere <sup>2</sup>

<sup>1</sup>Ophthalmic Plastic Surgery Services, LV Prasad Eye Institute, Hyderabad, India

<sup>2</sup>Child Sight Institute, Jasti V Ramanamma Children's Eye Care Centre, LV Prasad Eye Institute, Hyderabad, India

## Correspondence to

Dr Akshay Badakere; akshaybadakere@gmail.com

Accepted 26 March 2021

## SUMMARY

A 58-year-old man presented with vertical diplopia for 10 days which was sudden in onset. Extraocular movement examination revealed findings suggestive of internuclear ophthalmoplegia. Investigations were suggestive of diabetes mellitus, and reverse transcription-PCR for SARS-CoV-2 was positive. At 3 weeks of follow-up, his diplopia had resolved. Neuro-ophthalmic manifestations in COVID-19 are increasingly being recognised around the world. Ophthalmoplegia due to cranial nerve palsy and cerebrovascular accident in COVID-19 has been reported. We report a case of internuclear ophthalmoplegia in a patient with COVID-19.

## BACKGROUND

The novel coronavirus has engulfed the globe in a pandemic. One year after it was first detected,<sup>1</sup> SARS-CoV-2 continues to surprise clinicians with newer manifestations. Ophthalmic manifestations were initially reported to be limited to conjunctivitis.<sup>2-3</sup> Now there are increasing instances of other ophthalmic manifestations of COVID-19, such as uveitis<sup>4</sup> and occlusive vascular diseases.<sup>5</sup> The possibility of SARS-CoV-2 being a neurotropic virus is increasingly being reported, and neuro-ophthalmological manifestations are being reported. Neuro-ophthalmological manifestations range from isolated cranial nerve palsy<sup>6-8</sup> to supranuclear gaze palsy,<sup>9</sup> optic neuritis,<sup>10</sup> vision loss<sup>11</sup> and Miller Fisher syndrome.<sup>12</sup>

We present a case of COVID-19 presenting with internuclear ophthalmoplegia (INO).

## CASE PRESENTATION

A 58-year-old man presented to a rural eye care centre with complaints of binocular diplopia for 10 days which was sudden in onset. He had no known comorbidities of diabetes, hypertension or thyroid disorder and gave no history of trauma. There was no headache or diurnal variation. Examination revealed a vertical diplopia, enhanced in down-gaze and leversion. There were left eye exotropia and hypotropia of 15°. There was a -1 limitation of adduction in the right eye ([figure 1](#)) and his vertical saccades were partially impaired. He had a left-beating nystagmus in the left eye noted only on abduction. Pupillary reaction was normal. Best corrected visual acuity was 6/6p and 6/12 in the right and left eye, respectively. Colour vision was normal. Anterior segment evaluation revealed bilateral nasal pterygium and posterior polar cataract in the left eye, while posterior segment examination

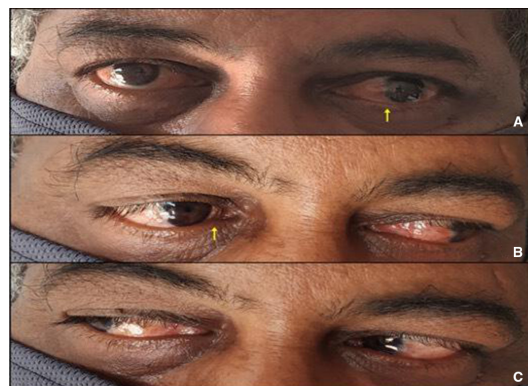was unremarkable. His vitals at the time of screening were 94% saturation of peripheral oxygen (SpO<sub>2</sub>), temperature of 35.8°C and pulse rate of 91 per minute. His overall systemic status was stable, with no respiratory symptoms noted.

## INVESTIGATIONS

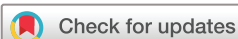Extraocular motility examination, the abducting nystagmus in the left eye and the saccades were indicative of INO. Fatigue and ice pack test were negative. Initial blood investigations of complete blood count, lipid profile and 24-hour urine protein were within normal range. Fasting and postprandial blood sugar levels were 121 mg/dL and 205 mg/dL, respectively, and haemoglobin A1c (HbA1c) was 7.5%, suggestive of diabetes mellitus. At the same time, he also underwent SARS-CoV-2 reverse transcription-PCR as part of the community screening at his village which was positive. The sample submitted for this test was a nasopharyngeal swab. He later revealed positive contact history with his brother and family who stayed close to his house.

## DIFFERENTIAL DIAGNOSIS

Ischaemic nerve palsy secondary to impaired blood glucose, myasthenia gravis, thyroid eye disease and INO were considered. The absence of clinical features suggesting an isolated nerve palsy on clinical examination ruled out ischaemic nerve palsy secondary to diabetes mellitus, although HbA1c was 7.5 gm%. The rapid resolution of diplopia over a period of 2–3 weeks is unlikely in diabetes mellitus.

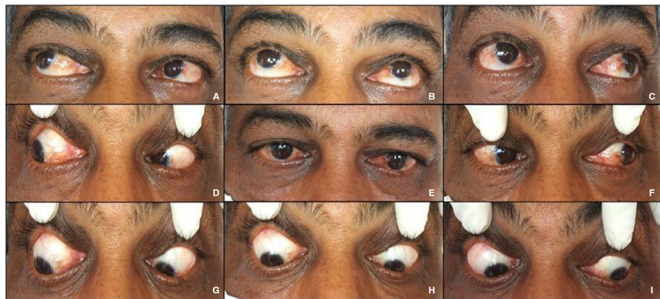


**Figure 1** Extraocular movements at presentation: primary gaze image showing left eye exotropia (A, arrow); adduction limitation in the right eye in leversion (B, arrow); and no limitation in horizontal movements in dextroversion (C).



© BMJ Publishing Group Limited 2021. No commercial re-use. See rights and permissions. Published by BMJ.

**To cite:** Vasanthpuram VH, Badakere A. *BMJ Case Rep* 2021;**14**:e241873. doi:10.1136/bcr-2021-241873



**Figure 2** Nine-gaze image at 3-week follow-up, that is, 1 week after being tested negative for SARS-CoV-2.

The absence of eyelid signs and the normal thyroid function test ruled out the possibility of thyroid eye disease. The absence of diurnal variation, negative ice pack test and absent Cogan twitch clinically ruled out ocular myasthenia. The patient was diagnosed with right-sided INO based on adduction limitation in the right eye and the abducting nystagmus in the left eye.

### TREATMENT

Prior to sending the patient for investigations, we started him on vitamin B<sub>12</sub> supplements once daily. The local physician treated the patient with oral doxycycline two times per day, ivermectin once daily and vitamin C supplementation for 10 days; this was an off-label treatment started by his general physician. He was also started on tablet metformin 500 mg once daily.

### OUTCOME AND FOLLOW-UP

The patient presented to our eye clinic after 3 weeks of first presentation and 1 week of a repeat nasopharyngeal swab for SARS-CoV-2 PCR test which was negative. He was relieved of his diplopia. However, the adduction limitation of  $-1$  persisted in the right eye (figure 2). His general demeanour was better. On retrospective probing, he had no anosmia, headache or any other COVID-19 symptoms apart from diplopia. At 1-month follow-up, his vertical saccades were normal and he was free of diplopia.

### DISCUSSION

Neurological symptoms in COVID-19 are well established, ranging from headache, dizziness, anosmia or hyposmia, and hypogeusia, to Guillain-Barre syndrome, ischaemic and haemorrhagic strokes, and so on.<sup>12</sup> Reports of neuro-ophthalmic findings such as cranial nerve paresis, optic neuritis, gaze palsy, vision loss and so on are being increasingly described in the literature.<sup>6–16</sup>

Multiple mechanisms in the aetiopathogenesis of neuro-ophthalmic manifestations in COVID-19 have been proposed, and these include postviral inflammatory syndrome, sequelae of a proinflammatory state and as a consequence of systemic conditions, such as cardiovascular disease or uncontrolled hypertension.<sup>14</sup> Haematological spread and direct viral invasion have also been suggested.<sup>12</sup>

Cases of oculomotor nerve palsy,<sup>13</sup> Miller Fisher syndrome,<sup>6</sup> abducens nerve palsy<sup>7,8</sup> and tonic pupil<sup>15</sup> have been reported earlier, which resolved with treatment.

There are increasing reports of cerebrovascular accidents (CVA) with neuro-ophthalmological manifestations ranging from gaze palsy<sup>8</sup> to devastating vision loss<sup>11</sup> in COVID-19. Vision loss has been reported due to occipital infarcts and central retinal artery occlusion as well.<sup>9,11</sup> Along with severe

COVID-19, all patients reported had additional cardiovascular and other systemic comorbidities, increasing their susceptibility to thrombotic events.<sup>9,11</sup>

Apart from being newly diagnosed with diabetes mellitus, our patient had no other predisposition to thrombotic events and no other signs or symptoms indicative of CVA.

Clinical signs seen in INO can be caused by ocular myasthenia and hence it needs to be ruled out. Clinical tests in ocular myasthenia include fatigue test, a positive ice pack test, peak sign, saccadic fatigue and Cogan twitch sign.<sup>17</sup> Cogan twitch sign has a sensitivity of up to 75% and a specificity approaching 99%.<sup>18</sup> Ice pack test has sensitivity and specificity of 80% and 100%, respectively.<sup>17</sup> Ocular myasthenia was clinically ruled out in our patient based on normal pupillary reaction, negative ice pack test and absent Cogan twitch sign.

Our patient presented with ophthalmoplegia not conforming to any pattern of cranial palsy. He was free from diplopia within 4 weeks of onset. In the absence of neuroimaging and with the patient being recently diagnosed with diabetes, it is difficult to be absolutely certain about INO being caused by COVID-19. A review by Brouwer<sup>19</sup> and associates reported the possible aetiology of stroke in COVID-19. They suggest that there is coagulation system activation and an inflammatory response that

### Patient's perspective

I was suffering with double vision since a few days and was facing difficulty with walking. I was hitting into the furniture at my house and had a fall breaking my phone. I decided to visit the eye hospital close to my village where the Doctor checked by eye sight. I was told that there is something wrong with my eye movements and needed some blood tests. My doctor gave me a capsule saying it is a vitamin capsule which I needed to take till my blood reports come. During the same time, the government COVID testing van came to my village and took samples from my family members. Around 2 weeks back, my brother and his family had tested positive for the virus. After giving my swab, I got blood tests done from a laboratory near my house. The health authorities informed me that I have COVID. I called my eye hospital and I was advised to visit the Physician. The Physician started my treatment and gave me some tablets for COVID. He also told me that I have Diabetes. I am taking tablets for Diabetes since then. I was at home for about 2 weeks. The government van came again to my village and repeated my COVID test which was negative now. I then visited my eye doctor after another 1 week. After checking the doctor said that there is still some problem with my eye movements but I had no double vision. I was able to comfortably walk now and go about my daily chores. I have visited my eye doctor twice now since recovering from COVID. I have been told that the cataract in my left eye will be operated later.

### Learning points

- ▶ Neuro-ophthalmic symptoms can be the only manifestation of COVID-19.
- ▶ SARS-CoV-2 can cause internuclear ophthalmoplegia possibly by demyelination or stroke.
- ▶ A meticulous clinical examination can help arrive at the diagnosis.
- ▶ A thorough systemic work-up aids in the diagnosis.

can lead to embolism and cerebral infarction. Our patient being diabetic possibly put him at an additional risk of stroke due to COVID-19.<sup>19</sup>

Damage in the medial longitudinal fasciculus causes INO.<sup>20</sup> The aetiology includes demyelinating disorders, infarcts, infections, vasculitis, trauma and iatrogenic injury.<sup>20</sup> In a series of 410 patients, Keane<sup>21</sup> reported infarction in 38% of INO, followed by multiple sclerosis in 34%. Unusual causes were reported in a quarter (28%) of the patients in the series, out of which only 17 cases had an infectious aetiology. Six cases had AIDS, four cysticercosis, two had each of syphilis, meningitis and sepsis, and one had brucellosis.

INO secondary to infection is rare.<sup>21</sup> Few reports of herpes zoster infection propose demyelination and vasculopathy in the aetiopathogenesis of INO.<sup>22–24</sup> The possible pathophysiology in our case may have been demyelination or related to stroke.<sup>19</sup>

Lack of neuroimaging for this patient due to the rural set-up and lack of serological investigations to rule out ocular myasthenia due to the patient's financial constraints are limitations.

With the community spread of SARS-CoV-2 in villages and areas with fewer healthcare facilities, a thorough clinical examination by an ophthalmologist can play an important role in the identification and ensuring adequate referral. This report highlights a case of mild COVID-19 with no respiratory symptoms and having primarily neuro-ophthalmic manifestations.

**Correction notice** This article has been corrected since it was published Online First. The spelling of author's name is corrected to "Varshitha Hemanth Vasanthpuram".

**Contributors** VHV was involved in the care of the patient, along with expert advice from AB. VHV wrote the first draft and collected the images. AB helped refine the draft and was involved in responding to reviewer comments.

**Funding** The case report was funded by Hyderabad Eye Research Foundation.

**Competing interests** None declared.

**Patient consent for publication** Obtained.

**Provenance and peer review** Not commissioned; externally peer reviewed.

This article is made freely available for use in accordance with BMJ's website terms and conditions for the duration of the covid-19 pandemic or until otherwise determined by BMJ. You may use, download and print the article for any lawful, non-commercial purpose (including text and data mining) provided that all copyright notices and trade marks are retained.

#### ORCID iD

Akshay Badakere <http://orcid.org/0000-0003-0747-6653>

#### REFERENCES

- Phelan AL, Katz R, Gostin LO. The novel coronavirus originating in Wuhan, China: challenges for global health governance. *JAMA* 2020;323:709–10.
- Douglas KAA, Douglas VP, Moschos MM. Ocular manifestations of COVID-19 (SARS-CoV-2): a critical review of current literature. *In Vivo* 2020;34:1619–28.
- Wu P, Duan F, Luo C, *et al.* Characteristics of ocular findings of patients with coronavirus disease 2019 (COVID-19) in Hubei Province, China. *JAMA Ophthalmol* 2020;138:575–8.
- Bettach E, Zadok D, Weill Y, *et al.* Bilateral anterior uveitis as a part of a multisystem inflammatory syndrome secondary to COVID-19 infection. *J Med Virol* 2021;93:139–40.
- Gaba WH, Ahmed D, Al Nuaimi RK, *et al.* Bilateral central retinal vein occlusion in a 40-year-old man with severe coronavirus disease 2019 (COVID-19) pneumonia. *Am J Case Rep* 2020;21:e927691.
- Dinkin M, Gao V, Kahan J, *et al.* COVID-19 presenting with ophthalmoparesis from cranial nerve palsy. *Neurology* 2020;95:221–3.
- Falcone MM, Rong AJ, Salazar H, *et al.* Acute abducens nerve palsy in a patient with the novel coronavirus disease (COVID-19). *J Aapos* 2020;24:216–7.
- Greer CE, Bhatt JM, Oliveira CA, *et al.* Isolated cranial nerve 6 palsy in 6 patients with COVID-19 infection. *J Neuroophthalmol* 2020;40:520–2.
- Yang Y, Qidwai U, Burton BJL, *et al.* Bilateral, vertical supranuclear gaze palsy following unilateral midbrain infarct. *BMJ Case Rep* 2020;13:e238422.
- Zhou S, Jones-Lopez EC, Soneji DJ, *et al.* Myelin oligodendrocyte glycoprotein antibody-associated optic neuritis and myelitis in COVID-19. *J Neuroophthalmol* 2020;40:398–402.
- Cyr DG, Vicidomini CM, Siu NY, *et al.* Severe bilateral vision loss in 2 patients with coronavirus disease 2019. *J Neuroophthalmol* 2020;40:403–5.
- Tisdale AK, Chwalisz BK. Neuro-Ophthalmic manifestations of coronavirus disease 19. *Curr Opin Ophthalmol* 2020;31:489–94.
- Faucher A, Rey P-A, Agudisch E, *et al.* Isolated post SARS-CoV-2 diplopia. *J Neurol* 2020;267:3128–9.
- Gold DM, Galetta SL. Neuro-Ophthalmologic complications of coronavirus disease 2019 (COVID-19). *Neurosci Lett* 2021;742:135531.
- Ordás CM, Villaceros-Álvarez J, Pastor-Vivas A-I, *et al.* Concurrent tonic pupil and trochlear nerve palsy in COVID-19. *J Neurovirol* 2020;26:970–2.
- Luis ME, Hipólito-Fernandes D, Mota C, *et al.* A review of Neuro-Ophthalmological manifestations of human coronavirus infection. *Eye Brain* 2020;12:129–37.
- Al-Haidar M, Benatar M, Kaminski HJ. Ocular myasthenia. *Neurol Clin* 2018;36:241–51.
- Singman EL, Matta NS, Silbert DI. Use of the Cogan lid twitch to identify myasthenia gravis. *J Neuroophthalmol* 2011;31:239–40.
- Brouwer MC, Ascione T, Pagliano P. Neurologic aspects of covid-19: a Concise review. *Infez Med* 2020;28:42–5.
- Feroze KB, Wang J. Internuclear Ophthalmoplegia. In: *StatPearls*. Treasure Island (FL): StatPearls Publishing, 2020.
- Keane JR. Internuclear ophthalmoplegia: unusual causes in 114 of 410 patients. *Arch Neurol* 2005;62:714–7.
- Paramanandam V, Perumal S, Jeyaraj M, *et al.* Herpes zoster internuclear ophthalmoplegia. *NN* 2016;3:102–3.
- Carroll WM, Mastaglia FL. Optic neuropathy and ophthalmoplegia in herpes zoster oticus. *Neurology* 1979;29:726–9.
- Al-Abdulla NA, Rismondo V, Minkowski JS, *et al.* Herpes zoster vasculitis presenting as giant cell arteritis with bilateral internuclear ophthalmoplegia. *Am J Ophthalmol* 2002;134:912–4.

Copyright 2021 BMJ Publishing Group. All rights reserved. For permission to reuse any of this content visit <https://www.bmj.com/company/products-services/rights-and-licensing/permissions/>  
BMJ Case Report Fellows may re-use this article for personal use and teaching without any further permission.

Become a Fellow of BMJ Case Reports today and you can:

- ▶ Submit as many cases as you like
- ▶ Enjoy fast sympathetic peer review and rapid publication of accepted articles
- ▶ Access all the published articles
- ▶ Re-use any of the published material for personal use and teaching without further permission

#### Customer Service

If you have any further queries about your subscription, please contact our customer services team on +44 (0) 207111 1105 or via email at [support@bmj.com](mailto:support@bmj.com).

Visit [casereports.bmj.com](http://casereports.bmj.com) for more articles like this and to become a Fellow