



## Standards and Guidelines

# SCAI/HRS Expert Consensus Statement on Transcatheter Left Atrial Appendage Closure



Jacqueline Saw, MD, FSCAI, Chair<sup>a,\*</sup>, David R. Holmes, MD, FSCAI, (Vice-Chair)<sup>b</sup>, João L. Cavalcante, MD<sup>c</sup>, James V. Freeman, MD, MPH, MS<sup>d</sup>, Andrew M. Goldsweig, MD, MS, FSCAI<sup>e</sup>, Clifford J. Kavinsky, MD, PhD, MSCAI<sup>f</sup>, Issam D. Moussa, MD, MBA, FSCAI<sup>g</sup>, Thomas M. Munger, MD<sup>b</sup>, Matthew J. Price, MD, FSCAI<sup>h</sup>, Mark Reisman, MD, FSCAI<sup>i</sup>, Matthew William Sherwood, MD, MHS, FSCAI<sup>j</sup>, Zoltan G. Turi, MD, MSCAI<sup>k</sup>, Dee Dee Wang, MD, FSCAI<sup>l</sup>, Brian K. Whisenant, MD, FSCAI<sup>m</sup>

<sup>a</sup> Division of Cardiology, Vancouver General Hospital, University of British Columbia, Canada; <sup>b</sup> Department of Cardiovascular Medicine, Mayo Clinic Health System Rochester, Rochester, Minnesota; <sup>c</sup> Department of Cardiology, Minneapolis Heart Institute, Minneapolis, Minnesota; <sup>d</sup> Section of Cardiovascular Medicine, Yale University, New Haven, Connecticut; <sup>e</sup> Division of Cardiovascular Medicine, The University of Nebraska Medical Center, Omaha, Nebraska; <sup>f</sup> Division of Cardiovascular Medicine, Rush University, Chicago, Illinois; <sup>g</sup> Carle Heart and Vascular Institute, Carle Illinois College of Medicine, Urbana, Illinois; <sup>h</sup> Division of Cardiovascular Diseases, Scripps Green Hospital, La Jolla, California; <sup>i</sup> Division of Cardiology, Weill Cornell Medical Center, New York, New York; <sup>j</sup> Division of Cardiology, Inova Heart and Vascular Institute, Fairfax, Virginia; <sup>k</sup> Center for Structural and Congenital Heart Disease, Hackensack University Medical Center, Hackensack, New Jersey; <sup>l</sup> Center for Structural Heart Disease, Henry Ford Health System, Detroit, Michigan; <sup>m</sup> Division of Cardiology, Intermountain Medical Center, Murray, Utah

**Endorsement:** This statement was endorsed by the American College of Cardiology and the Society of Cardiovascular Computed Tomography.

## ABSTRACT

Exclusion of the left atrial appendage to reduce thromboembolic risk related to atrial fibrillation was first performed surgically in 1949. Over the past 2 decades, the field of transcatheter endovascular left atrial appendage closure (LAAC) has rapidly expanded, with a myriad of devices approved or in clinical development. The number of LAAC procedures performed in the United States and worldwide has increased exponentially since the Food and Drug Administration approval of the WATCHMAN (Boston Scientific) device in 2015. The Society for Cardiovascular Angiography & Interventions (SCAI) has previously published statements in 2015 and 2016 providing societal overview of the technology and institutional and operator requirements for LAAC. Since then, results from several important clinical trials and registries have been published, technical expertise and clinical practice have matured over time, and the device and imaging technologies have evolved. Therefore, SCAI prioritized the development of an updated consensus statement to provide recommendations on contemporary, evidence-based best practices for transcatheter LAAC focusing on endovascular devices.

**Abbreviations:** DOAC, direct oral anticoagulation; DRT, device-related thrombosis; LA, left atrium; LAA, left atrial appendage; LAAC, left atrial appendage closure; NCDR, National Cardiovascular Data Registry; OAC, oral anticoagulation; PVI, pulmonary vein isolation; TEE, transesophageal echocardiography; TSP, transseptal puncture.

**Keywords:** CHA<sub>2</sub>DS<sub>2</sub>-VASc; device-related thrombus; embolic stroke prevention; left atrial appendage closure; non-valvular atrial fibrillation; peridevice leak.

J.L.C. is a Society of Cardiovascular Computed Tomography representative.

J.V.F. and T.M. are Heart Rhythm Society representatives.

M.W.S. is an American College of Cardiology representative.

This article has been published in *JACC: Cardiovascular Interventions and Heart Rhythm*.

\* Corresponding author: [jsaw@mail.ubc.ca](mailto:jsaw@mail.ubc.ca) (J. Saw).

<https://doi.org/10.1016/j.jscai.2022.100577>

Available online 27 March 2023

2772-9303/© 2023 Society for Cardiovascular Angiography and Interventions Foundation, Heart Rhythm Society and American College of Cardiology, published by Elsevier Inc. This is an open access article under the CC BY-NC-ND license (<http://creativecommons.org/licenses/by-nc-nd/4.0/>) which permits use and distribution in any medium, provided the original work is properly cited, the use is non-commercial and no modifications or adaptations are made.

## Table of Contents

Summary of recommendations . . . . .	2
Methodology . . . . .	2
Introduction . . . . .	3
Patient Selection for LAAC . . . . .	4
Transcatheter LAAC is appropriate for patients with nonvalvular AF with high thromboembolic risk who are not suited for long-term OAC and who have adequate life expectancy (minimum >1 year) and quality of life to benefit from LAAC. There should be patient-provider discussion for shared decision making. . . . .	4
Physician and institutional requirements . . . . .	4
Physician initial requirements: . . . . .	4
Skill maintenance: . . . . .	4
Institutional requirements: . . . . .	4
Preprocedural imaging . . . . .	5
Baseline preprocedural imaging with TEE or cardiac computed tomography angiography is recommended before LAAC . . . . .	5
Intraprocedural imaging . . . . .	5
Intraprocedural imaging guidance with TEE or ICE and contrast angiography is strongly recommended . . . . .	5
Technical aspects for safe and effective procedure performance. . . . .	6
Procedural venous access, anticoagulation, transseptal puncture, delivery sheath selection and placement, LA pressure measurement, and device deployment should be performed in accordance with the testing and labeling of each specific LAAC device. . . . .	6
Avoidance, recognition, and treatment of intraprocedural complications . . . . .	8

Operators need to be familiar with avoidance, recognition, and management of complications associated with LAAC. . . . .	8
PredischARGE imaging should be performed with 2D transthoracic echocardiography to rule out pericardial effusion and device embolization. Same-day discharge may be appropriate after several hours of observation, demonstrating no complications or pericardial effusion after LAAC . . . . .	9
Recognition and management of late adverse events . . . . .	9
Device-related thrombus should be treated with anticoagulation. Repeat imaging at 45- to 90-day intervals can be performed to assess for resolution with eventual cessation of anticoagulation . . . . .	9
Routine closure of iatrogenic atrial septal defects associated with LAAC should not be performed . . . . .	9
The clinical impact and management of PDLs are not fully understood and all efforts should be made to minimize such leaks at the time of implantation. . . . .	9
Patients should be prescribed antithrombotic therapy with warfarin, direct oral anticoagulants, or DAPT after LAAC according to the studied regimen and instructions for use for each specific device and tailored to bleeding risks of each patient . . . . .	10
TEE or cardiac CT is recommended at 45 to 90 days after LAAC for device surveillance to assess for PDL and DRT . . . . .	10
Combined procedures with LAAC (eg, structural interventions, PVI) are not routinely recommended pending data from ongoing RCTs . . . . .	11
Future directions and landscape of LAAC . . . . .	11
Funding sources . . . . .	11
Supplementary material . . . . .	11
References . . . . .	11

## Summary of recommendations

- Transcatheter left atrial appendage closure (LAAC) is appropriate for patients with nonvalvular atrial fibrillation with high thromboembolic risk who are not suited for long-term oral anticoagulation and who have adequate life expectancy (minimum >1 year) and quality of life to benefit from LAAC. There should be patient-provider discussion for shared decision making.
- Physicians performing LAAC should have a prior experience, including  $\geq 50$  prior left-sided ablations or structural procedures and  $\geq 25$  transseptal punctures (TSPs). Interventional imaging physicians should have experience in guiding  $\geq 25$  TSPs before supporting any LAAC procedures independently.
- For maintenance of skills, implanting physicians should perform  $\geq 25$  TSPs and  $>12$  LAACs over each 2-year period.
- New programs and implanting physicians early in their LAAC experience should have on-site cardiovascular surgery backup.
- Baseline imaging with transesophageal echocardiography (TEE) or cardiac computed tomography is recommended before LAAC.
- Intraprocedural imaging guidance with TEE or intracardiac echocardiography is recommended.
- Technical aspects of the procedure, including venous access, anticoagulation, transseptal puncture, delivery sheath selection and placement, left atrial pressure measurement, and device deployment, should be performed in accordance with the labeling of each specific LAAC device.
- Operators need to be familiar with avoidance, recognition, and management of procedural complications associated with LAAC.
- PredischARGE imaging should be performed with 2-dimensional transthoracic echocardiography to rule out pericardial effusion and device embolization. Same-day discharge may be

appropriate after several hours of observation demonstrating no complications or pericardial effusion after LAAC.

- Device-related thrombus should be treated with anticoagulation. Repeat imaging at 45- to 90-day intervals can be performed to assess for resolution with eventual cessation of anticoagulation.
- Routine closure of iatrogenic atrial septal defects associated with LAAC should not be performed.
- The clinical impact and management of peridevice leaks are not fully understood, and all efforts should be made to minimize such leaks at the time of implantation.
- Patients should be prescribed antithrombotic therapy with warfarin, direct oral anticoagulants, or dual antiplatelet therapy after LAAC according to the studied regimen and instructions for use for each specific device and tailored to the bleeding risks of each patient.
- TEE or cardiac computed tomography is recommended at 45 to 90 days after LAAC for device surveillance to assess for peridevice leak and device-related thrombus.
- Combined procedures with LAAC (eg, structural interventions, pulmonary vein isolation) are not routinely recommended, as data are pending from ongoing randomized controlled trials.

## Methodology

This statement has been developed according to the Society for Cardiovascular Angiography & Interventions (SCAI) Publications Committee policies for writing group composition, disclosure and management of relationships with industry, internal and external review, and organizational approval.<sup>1</sup>

The writing group has been organized to ensure diversity of perspectives and demographic characteristics, multistakeholder representation, and appropriate balance of relationships with industry. Relevant

author disclosures are included in [Supplementary Table S1](#). Before appointment, members of the writing group were asked to disclose financial and intellectual relationships from the 12 months before their nomination. A majority of the writing group disclosed no relevant, significant financial relationships. Disclosures were periodically reviewed during document development and updated as needed. SCAI policy requires that writing group members with a current, relevant financial interest are recused from participating in related discussions or voting on related recommendations. The work of the writing committee was supported exclusively by SCAI, a nonprofit medical specialty society, without commercial support. Writing group members contributed to this effort on a volunteer basis and did not receive payment from SCAI.

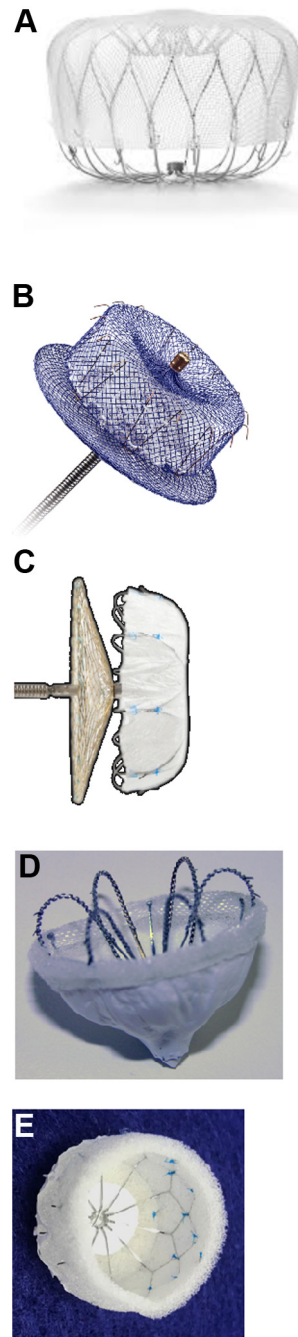
Literature searches were performed by group members designated to lead each section, and initial section drafts were authored primarily by the section leads in collaboration with other members of the writing group. The recommendations and supporting text for each section were discussed and agreed upon by the full writing group. All recommendations are supported by a short summary of the evidence or specific rationale. The draft manuscript was peer reviewed in August 2022, and the document was revised to address pertinent comments. The writing group unanimously approved the final version of the document. The SCAI Publications Committee and Executive Committee endorsed the document as official society guidance in December 2022.

The SCAI statements are primarily intended to help clinicians make decisions about treatment alternatives. Clinicians also must consider the clinical presentation, setting, and preferences of individual patients to make judgments about the optimal approach.

## Introduction

Atrial fibrillation (AF) is associated with a 4- to 5-fold increased risk of ischemic stroke and accounts for 25% of the 700,000 cerebrovascular accidents that occur in the United States annually.<sup>2</sup> Historically, the standard of care for stroke prevention in AF has been oral anticoagulation (OAC); however, there are many patient, prescriber, and health care resource issues that limit OAC use in this setting. Warfarin, the traditional oral anticoagulant, is limited by dietary restrictions, and the need for routine blood testing to maintain a narrow therapeutic window can lead to patient nonadherence. The newer direct OAC (DOAC) carries high costs, which are not uniformly absorbed by third party payors. Despite ease of administration, 30% of patients taking DOAC are nonadherent at 2 years.<sup>3</sup> Other patients cannot tolerate long-term OAC because of bleeding complications, cognitive impairment, fall risk, and other factors (eg, drug allergy, drug interactions, renal dysfunction). Older patients often have unfavorable bleeding risk profiles for OAC, leading physicians not to offer or to discontinue OAC. This treatment gap has created an unmet clinical need for an effective and safe nonpharmacologic therapy for stroke prevention in patients with nonvalvular AF and has fueled the field of LAAC.

In patients with nonvalvular AF, >90% of thrombi observed on transesophageal echocardiography (TEE) or on autopsy series come from the left atrial appendage (LAA).<sup>4,5</sup> This finding has stimulated development of procedures to exclude the LAA, including endovascular occlusion, surgical suturing, stapling, and amputation, as a nonpharmacologic means to reduce stroke risk. The LAAOS III trial showed that surgical LAA closure (LAAC) using multiple techniques was associated with reduction of ischemic stroke and systemic embolism in patients who continued to receive chronic OAC.<sup>6</sup> Whether LAA surgical excision is effective in preventing ischemic stroke in patients not receiving OAC remains unproven. Transcatheter endocardial devices have been and are actively being evaluated in clinical trials, and the WATCHMAN (Boston Scientific) and Amulet (Abbott) devices have received Food and Drug Administration (FDA) approval for stroke prevention without long-term OAC. There are several other devices at various stages of development that can be anticipated to add to the procedural armamentarium in the future (Figure 1).



**Figure 1.**

**Examples of transcatheter LAAC devices. (A) WATCHMAN FLX, (B) Amulet, (C) LAmbre, (D) Wavecrest, and (E) Conformal. LAAC, left atrial appendage closure.**

Left atrial appendage closure has been compared with OAC for stroke prevention in nonvalvular AF in 3 prospective randomized controlled trials (RCTs) showing noninferiority in reduction of stroke and systemic embolism: (1) PROTECT AF (707 patients) (NCT00129545<sup>7</sup>) and (2) PREVAIL (407 patients) (NCT01182441<sup>8</sup>) in which the WATCHMAN device was compared with warfarin; and (3) PRAGUE-17 (402 patients) (NCT02426944<sup>9</sup>) in which Amulet and WATCHMAN devices were compared to DOAC, primarily apixaban.<sup>10-12</sup> Several important DOAC vs LAAC RCTs for patients eligible for OAC are ongoing, including CHAMPION-AF (NCT04394546<sup>13</sup>), CATALYST (NCT04226547<sup>14</sup>), and OPTION (NCT03795298<sup>15</sup>) (Table 1). The ASAP-TOO study (NCT02928497<sup>16</sup>) (stopped prematurely due to slow enrollment after ~500 patients), STROKE-CLOSE (NCT02830152<sup>17</sup>), and CLOSURE-AF

**Table 1.** Ongoing endovascular LAAC randomized controlled trials and postprocedural antithrombotic strategies.

Trial	OAC-eligible patients			OAC-contraindicated patients		
	OPTION trial: WATCHMAN FLX vs OAC after PV ablation	CHAMPION-AF trial: WATCHMAN FLX vs DOAC	CATALYST trial: Amulet vs DOAC	ASAP-TOO trial: WATCHMAN vs control	STROKE-CLOSE trial: Amulet vs control	CLOSURE-AF trial: LAAC vs OAC
N	1600	3000	2650	888 <sup>a</sup>	750	1512
Postprocedural antithrombotic strategies	DOAC or warfarin and aspirin for 3 mo after LAAC	DOAC and aspirin or DAPT for 3 mo after LAAC	DAPT for 3 mo after LAAC	DAPT for 3 mo after LAAC	Aspirin ± clopidogrel for 45 d after LAAC	DAPT after LAAC
Control	OAC	DOAC	DOAC	Aspirin or none	OAC, antiplatelet, or none	DOAC or warfarin

DAPT, dual antiplatelet therapy; DOAC, direct oral anticoagulation; LAAC, left atrial appendage closure; OAC, oral anticoagulation; PV, pulmonary vein.

<sup>a</sup> Study stopped prematurely (~500 patients enrolled).

(NCT03463317<sup>18</sup>) studies randomize OAC-ineligible patients, but enrollment has been challenged by competition from “off-label” use of LAAC in the OAC-contraindicated population.

### Patient Selection for LAAC

1. *Transcatheter LAAC is appropriate for patients with nonvalvular AF with high thromboembolic risk who are not suited for long-term OAC and who have adequate life expectancy (minimum >1 year) and quality of life to benefit from LAAC. There should be patient-provider discussion for shared decision making*

Recent guidelines issued by the United States and European professional societies<sup>19,20</sup> have both made a IIb recommendation for LAAC in those with AF and contraindication to long-term OAC (Tables 2 and 3).<sup>11,20-23</sup> Because the RCTs were designed to demonstrate non-inferiority of LAAC to long-term OAC, they enrolled only patients eligible for long-term OAC.<sup>11,21</sup> The mandate by the Centers for Medicare and Medicaid Services (CMS) to perform LAAC for patients for whom long-term OAC is not appropriate had a limited evidence base at the time of the coverage decision. However, the practice in both the United States and worldwide is to treat patients with LAAC who are suboptimal candidates for long-term OAC. CMS also added requirements applied across a range of new technologies, including obligatory registry enrollment and documentation of evidence-based shared decision making with a nonimplanting physician. The National Cardiovascular Data Registry (NCDR) LAA Occlusion (LAAO) Registry reports prior clinical bleeding in almost 70% of patients undergoing LAAC, intracranial bleeding in nearly 12% (vs none in RCTs), and

significant rates of discharge without OAC (7.9%) in the United States.<sup>24,25</sup> In Europe, LAAC without the use of OAC after procedure is more widespread: in the EWOLUTION Registry (N = 1021), 61.8% were ineligible for OAC.<sup>26</sup> In the Amulet Post-Marketing Registry, 82.8% of 1088 patients were contraindicated to OAC.<sup>27</sup>

Patients suitable for LAAC should fit the definition of nonvalvular AF and should be at increased risk of stroke with CHA<sub>2</sub>DS<sub>2</sub>-VASc of ≥2 (men) or ≥3 (women) as per the ESC 2020 and American College of Cardiology (ACC)/American Heart Association (AHA) 2019 updated AF guidelines for class I indication for OAC for stroke prevention.<sup>19,20</sup> Patients should have increased bleeding risks (eg, high HAS-BLED score ≥3) or OAC intolerance, including prior bleeding, fall risk, uncontrolled hypertension, renal or liver failure, alcohol use, concomitant antiplatelet or nonsteroidal agents, high-risk occupations, noncompliance, labile international normalized ratio, OAC intolerance/allergy, and drug interactions. Patients should have an adequate life expectancy (minimum >1 year) and quality of life to benefit from LAAC. In questionable cases, frailty markers may help guide decision making. There should be patient-provider discussion for shared decision making. LAAC is generally contraindicated in patients with known LAA thrombus; implantation in such patients using embolic protection devices is reported but is inconsistent with published indications.<sup>28</sup>

### Physician and institutional requirements

2.1. *Physician initial requirements: ≥50 prior left-sided ablations or structural procedures and ≥25 transseptal punctures*

2.2. *Skill maintenance: ≥25 transseptal punctures and >12 LAACs over 2 years*

2.3. *Institutional requirements: on-site cardiovascular surgery (CVS) program backup during implanter's early learning curve*

The SCAI/ACC/Heart Rhythm Society (HRS) LAAC institutional and operator requirements were published in 2015,<sup>29,30</sup> which

**Table 2.** 2019 AHA/ACC/HRS focused update of the 2014 AHA/ACC/HRS guideline for the management of patients with atrial fibrillation.

Recommendations	Class of recommendation	Level of evidence
After surgical occlusion or exclusion of the LAA, it is recommended to continue anticoagulation in at-risk patients with AF for stroke prevention.	<b>I</b>	<b>B</b>
LAA occlusion may be considered for stroke prevention in patients with AF and contraindications for long-term anticoagulant treatment (eg, those with a previous life-threatening bleed without reversible cause).	<b>IIb</b>	<b>B</b>
Surgical occlusion or exclusion of the LAA may be considered for stroke prevention in patients with AF undergoing cardiac surgery.	<b>IIb</b>	<b>B</b>
Surgical occlusion or exclusion of the LAA may be considered for stroke prevention in patients undergoing thoracoscopic AF surgery.	<b>IIb</b>	<b>B</b>

ACC, American College of Cardiology; AF, atrial fibrillation; AHA, American Heart Association; HRS, Heart Rhythm Society; LAA, left atrial appendage. Adapted from January et al.<sup>19</sup>

**Table 3.** 2020 European Society of Cardiology Guidelines for the management of atrial fibrillation.

Recommendations for occlusion or exclusion of the LAA	Class of recommendation	Level of evidence
LAA occlusion may be considered for stroke prevention in patients with AF and contraindications for long-term anticoagulant treatment (eg, intracranial bleeding without a reversible cause)	<b>IIb</b>	<b>B</b>
Surgical occlusion or exclusion of the LAA may be considered for stroke prevention in patients with AF undergoing cardiac surgery	<b>IIb</b>	<b>C</b>

AF, atrial fibrillation; LAA, left atrial appendage. Adapted from Hindricks et al.<sup>20</sup>



outlined standards for the operator knowledge base and procedural skill sets, as well as institutional requirements required for LAAC. Physicians' educational requirements should include the following: knowledge of AF, its clinical course and medical therapies, comprehension of the CHA<sub>2</sub>DS<sub>2</sub>-VASc and HAS-BLED scoring systems for risk stratification of patients with AF using OAC, indications and management of OAC agents, indications and risks of various invasive surgical and catheter techniques for LAAC, and awareness of patient shared decision making.

For procedural skills, physicians should have knowledge of transseptal puncture (TSP), LA/interatrial fossa/LAA anatomy and associated intraprocedural imaging requirements, and prior experience with other percutaneous endovascular procedures such as, but not limited to, transcatheter mitral valve interventions, atrial septal defect (ASD)/patent foramen ovale closure, or pulmonary vein isolation (PVI) ablation. This should include 50 prior left-sided ablations or structural procedures and at least 25 TSPs. Industry-sponsored device-specific training (including proctoring) is an expectation as a mechanism for introducing new technologies at the operator's institution. For maintenance,  $\geq 25$  TSPs and  $> 12$  LAAOs over 2 years were suggested. Knowledge and management experience of complications such as tamponade and device retrieval is required. Educational and procedural skill sets have also been reviewed in the 2015 electrophysiology advanced training statement.<sup>31</sup>

Institutional requirements include availability of TEE or intracardiac echocardiography (ICE) operators, a multidisciplinary team, and an on-site CVS program, although a recent 2020 European Heart Rhythm Association/European Association of Percutaneous Cardiovascular Interventions document suggested on-site CVS as optional if transfer within an hour is feasible.<sup>32</sup> It is recommended that physicians in their early learning curve and starting a program should have on-site CVS. A hemodynamic recording system is necessary for pressure assessment. An active institutional quality registry program in the United States is mandatory. It is recommended that interventional imaging physicians have experience in guiding  $\geq 25$  TSPs before supporting any LAAC procedures independently.<sup>33</sup>

## Preprocedural imaging

### 3. Baseline preprocedural imaging with TEE or cardiac computed tomography (CT) angiography (cardiac CT) is recommended before LAAC

Baseline preprocedural imaging with TEE or cardiac computed tomography (CT) angiography (cardiac CT) is recommended before embarking on the LAAC procedure. The most commonly employed preprocedural LAA imaging is TEE. Some experienced centers have evolved to performing the baseline TEE at the beginning of the LAAC procedure. This practice may be acceptable but should be discouraged with new programs and inexperienced operators. Furthermore, this approach will necessitate periodically cancelling a case with the patient on the table secondary to technical issues such as a lipomatous or aneurysmal septum, LAA thrombus, or unanticipated technical challenges secondary to LAA size/morphology. Two-dimensional (2D) images of the LAA are recommended to be obtained at 0°, 45°, 90°, and 135° along the axis of the circumflex artery to identify the maximal width of the LAA landing zone.<sup>34</sup> Depth dimensions are obtained from the centroid of the landing zone as a straight line to the main body of the LAA (Figure 2). To ensure that maximal dimensions are obtained, measurements should be taken during maximal filling of the LAA (left ventricular systole), typically at a mean LA pressure  $> 12$  mm Hg.<sup>35,36</sup> Three-dimensional (3D) TEE imaging of the LAA evaluated using double-oblique multiplanar reformatting can provide improved accuracy for sizing measurements.

Cardiac CT is increasingly recognized as an excellent 3D primary imaging tool for LAAC procedural planning and is a superior alternative

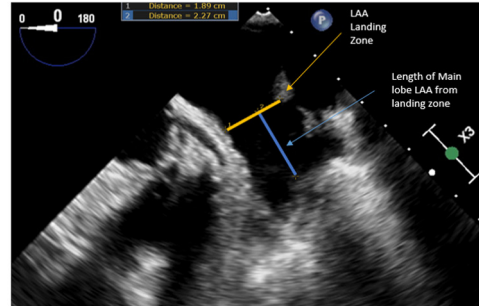
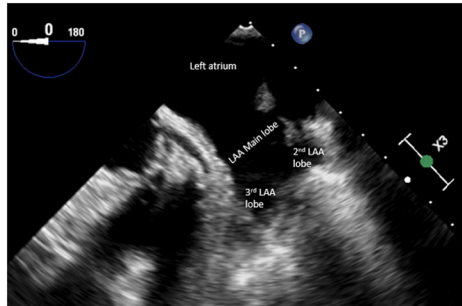
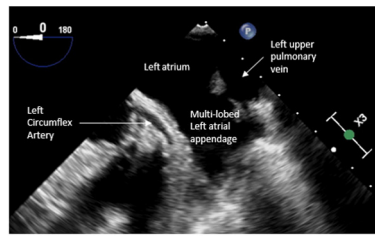
to TEE for spatial resolution. Cardiac CT-gated scans should be obtained utilizing previously described methodologies to ensure maximal contrast opacification of the LAA and landing zone while minimizing motion artifacts.<sup>36,37</sup> A late-pass delayed scan is recommended to allow adequate contrast mixing to avoid overinterpretation of the thrombus in the LAA. Reconstructive segmentation and analysis for device size should be performed at scan increments ideally between 0.5- to 1.5-mm slice thickness with delayed imaging to ensure the absence of LAA thrombus.<sup>36</sup> Cardiac CT measurements of the LAA's landing zone should be performed utilizing 3D multiplanar reformat images of the LAA at the level of the circumflex artery in the mid-to-late systolic phase of the cardiac cycle to ensure maximal LAA contrast opacification.<sup>38,39</sup> Device sizing should take into account that LAA measurements on cardiac CT tend to be 2- to 3-mm larger than TEE measurements,<sup>37,40</sup> given that CT measurements are performed in 3D and patients are not fasting (and often administered fluid) before scanning. The addition of 3D printing and computer simulation to gauge how different device sizes can fit in individual patient anatomies may be helpful, especially with challenging anatomies.

## Intraprocedural imaging

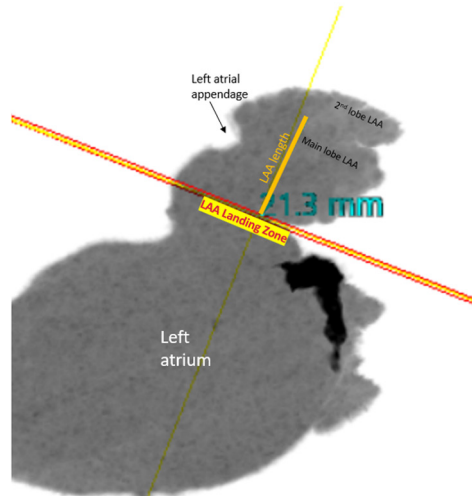
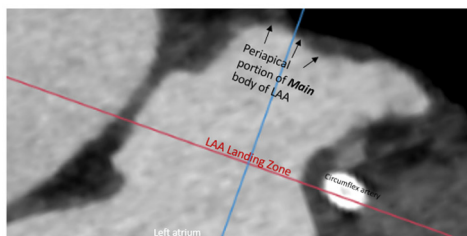
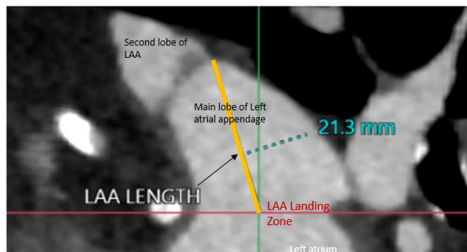
### 4. Intraprocedural imaging guidance with TEE or ICE and contrast angiography is strongly recommended

It is strongly recommended that intraprocedural imaging guidance be utilized for all LAAC procedures. Intraprocedural imaging is essential for ruling out LAA thrombus; monitoring for pericardial effusion; guidance of TSP; visualization of device implantation, stability, compression, and PDL; and assessment of iatrogenic ASD.<sup>41,42</sup> Fluoroscopy alone without TEE/ICE is not recommended. TEE guidance by a dedicated experienced interventional imaging physician with standardized views as described above has been the traditional intraprocedural imaging modality for LAAC. It is recommended that new programs and proceduralists early in their LAAC experience utilize 2D and 3D TEE to become comfortable with imaging for LAAC. Intracardiac echocardiography is evolving as an additive imaging modality to guide LAAC. The 2D and emerging 3D ICE technology with availability of preprocedural cardiac CT case planning is an emerging acceptable alternative to TEE for intraprocedural guidance for LAAC. There is the increased expense of the ICE probe that needs to be considered, as well as the increased complexity of the procedure associated with ICE probe placement in the left atrium (LA). ICE imaging of the LAA can be performed from the right atrium but is usually suboptimal for procedural guidance. Ideally, the ICE probe needs to be placed in the LA. This can be performed through a separate transseptal puncture or through the same puncture used for LAAC device delivery sheath. ICE views (with probe in the LA in the retroflex, supramitral, and left upper pulmonary vein positions) that simulate standard TEE views may be achievable (Figure 3); however, in most cases, TEE still provides superior imaging and operator reproducibility than ICE for the LAA. The RCTs leading to approval of the commercially available LAAC devices both required intraprocedural TEE guidance. Although small studies suggest that an ICE-guided approach may be safe and effective, further data in larger cohorts are needed to confirm these early findings. Therefore, ICE guidance for LAAC, currently, should be reserved for experienced programs/implanters/interventional imaging physicians. In addition, when beginning ICE guidance for LAAC, a period of utilizing combined TEE and ICE is recommended until comfort with the ICE catheter and image acquisition workflow by the interventional imaging and implanting team is achieved. Furthermore, when using ICE, baseline preprocedural day imaging with cardiac CT or TEE is recommended to provide detailed information regarding LAA morphology.<sup>41,42</sup> Fluoroscopy alone without TEE/ICE is not recommended.

A



B



**Figure 2.** Transesophageal echocardiogram (TEE) and computed tomography angiography (CTA) images of the left atrial appendage (LAA) landing zone and definition of optimal LAA length measurements. (A)

TEE images demonstrate the multilobed LAA that emanates from a larger body of the main lobe of the LAA. The landing zone is depicted by an orange line measured at the level of the circumflex artery. The length of the main lobe of the LAA is depicted by the blue line measured from the centroid of the LAA landing zone (orange line) to the center of the periapical region of the main body of the LAA. Care is taken to avoid measuring lengths to accessory LAA lobes as this may not accurately mimic the ability of current generation LAA occlusion (LAAO) devices to fully expand within very narrow portions of the distal lobes of the LAA. (B) CTA images demonstrate the multilobed LAA that emanates from a larger body of the main lobe of the LAA. The landing zone is depicted by a red line measured from the centroid of the LAA landing zone (demarcated by solid orange line), to the center of the periapical region of the main body of the LAA. Care is taken to avoid measuring lengths to accessory LAA lobes as this may not accurately mimic the ability of current generation LAAO devices to fully expand within very narrow portions of the distal lobes of the LAA.

### Technical aspects for safe and effective procedure performance

5. Procedural venous access, anticoagulation, transseptal puncture, delivery sheath selection and placement, LA pressure measurement, and device deployment should be performed in accordance with the testing and labeling of each specific LAAC device

**LAAC implantation step-by-step.** A detailed description of procedural steps for LAAC is beyond the scope of this article. Rather, certain points requiring clarification will be highlighted.

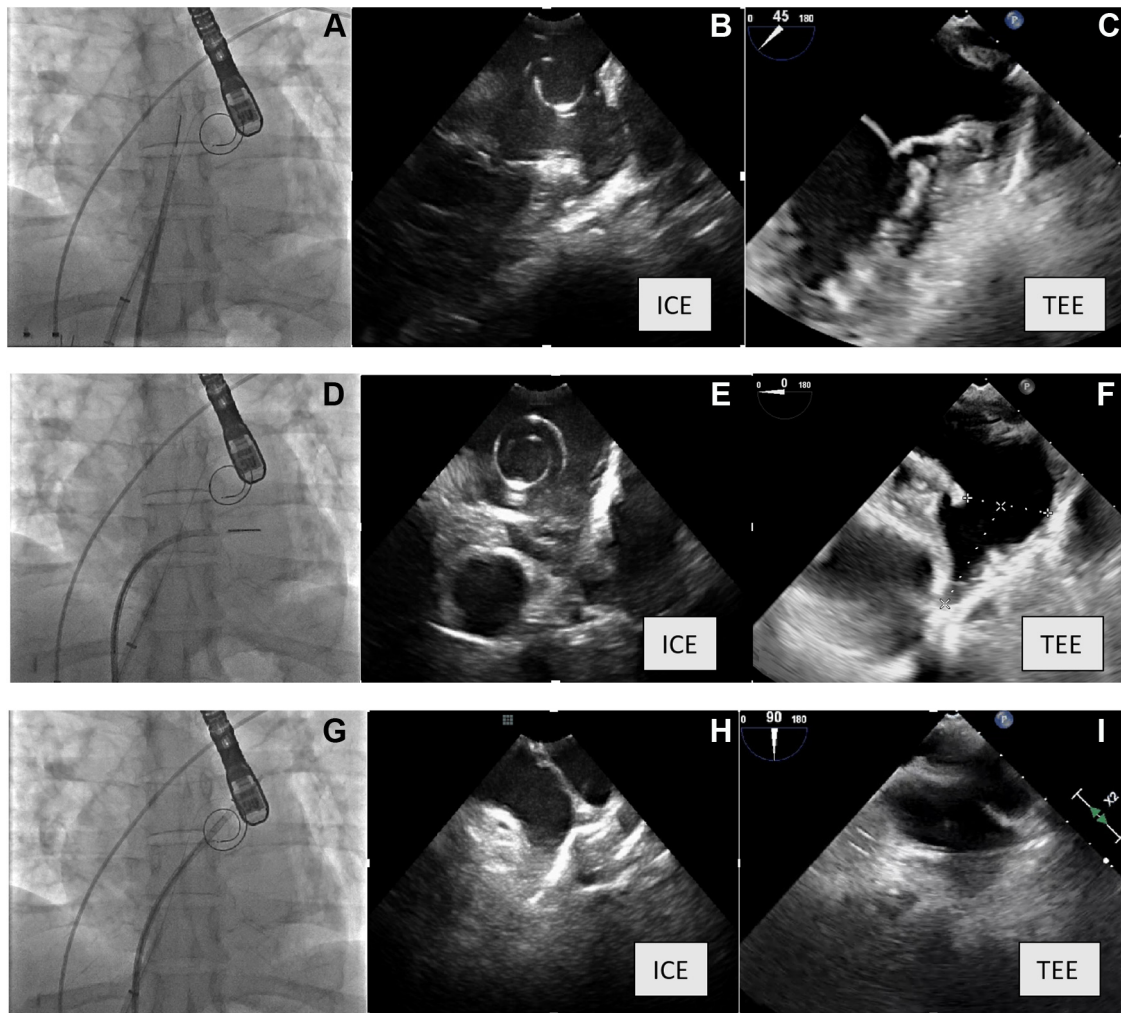
**Venous access.** The LAAC procedure should generally be performed through the right femoral vein whenever possible. Micropuncture technique and ultrasound guidance can be helpful and should be strongly considered. The left femoral vein may be utilized; however, transseptal puncture and subsequent sheath manipulation can be more challenging. After completion of the procedure, hemostasis can be achieved through any number of techniques including manual compression, suture-mediated closure, or figure-of-8 suture with equal efficacy in accordance with operator comfort. Administration of protamine may be considered if hemostasis is not achieved by standard techniques.

**Anticoagulation.** Unfractionated heparin (UFH) is used to achieve therapeutic anticoagulation during the procedure, with a goal activated

clotting time (ACT) of at least 250 to 300 seconds. UFH may be administered before or after TSP, at the discretion of the operator. ACT should be monitored frequently to ensure appropriate anticoagulation for the duration of the procedure.

**TSP location.** For the commercially available LAAC devices, the TSP site should be located inferiorly and posteriorly. This approach typically orients the access sheath coaxially with the LAA. The location of the LAA can be confirmed on TEE or preprocedural cardiac CT. For a superiorly directed LAA, an inferior puncture is desired. In mid-to-inferiorly directed LAA, a less inferior TSP can be performed. Most appendages are directed anteriorly; therefore, a posterior puncture is desired in most cases. On TEE, the 90° view of the LAA helps gauge the direction of the LAA.

**Delivery sheath selection.** Each commercially available device comes with manufacturer's recommendations for specific delivery sheaths. For example, the WATCHMAN device can be delivered through 2 different 14F sheaths: single-curve or double-curve. The double-curve sheath is sufficient to provide coaxial orientation with the LAA in most cases where the LAA is directed both superiorly and anteriorly. The single-curve sheath is advantageous when there is an inferiorly directed appendage. The Amulet device can be delivered through an inner diameter 12F (for devices  $\leq 25$  mm) or 14F (for devices  $\geq 28$  mm)



**Figure 3.**

**Corresponding images on fluoroscopy (showing intracardiac echocardiography [ICE] probe position), ICE views, and corresponding transesophageal echocardiography (TEE) views in the same patient. (A)** Fluoroscopy showing ICE probe in the retroflex position in the LA (also showing the VersaCross wire in the left atrium [LA]), **(B)** image from the ICE probe in the retroflex LA position, **(C)** image from TEE at 45° view. **(D)** Fluoroscopy showing ICE probe in the supramitral position in the LA, **(E)** image from the ICE probe in the supramitral LA position, **(F)** image from TEE at 0° view. **(G)** Fluoroscopy showing ICE probe in the left upper pulmonary vein, **(H)** image from the ICE probe in the left upper pulmonary vein, **(I)** image from TEE at 90° view.

TorqueVue 45 × 45 degree sheath or the 14F steerable sheath (outer diameter 19F).

**Advancement of delivery sheath into the LAA.** Once TSP is completed, the delivery sheath is introduced into the LA either by anchoring a stiff support wire in the pulmonary vein or over a “pigtail” type wire positioned in the LA. Each technique has advantages and disadvantages. A stiff support wire anchored in the left upper pulmonary vein provides an excellent support platform for introducing the device delivery sheath into the LA but runs a greater risk of wire perforation of the pulmonary vein. The stiff wire should be placed in the pulmonary vein through a previously placed exchange catheter positioned in the pulmonary vein using a soft tipped guide wire. A “pigtail” type wire is technically easy and safe to place in the LA through the transseptal assembly but does not provide as much support for introduction of the device delivery sheath through the TSP. If difficulty is encountered introducing the device delivery sheath into the LA, one can predilate the atrial septum using a 14F Inoue dilator or by performing atrial septostomy using a 5.0-mm or larger balloon. Once in the LA, the delivery sheath should be carefully deaired and flushed with saline. The device delivery sheath is advanced into the LAA over a 5F to 6F straight pigtail catheter

positioned deep in the LAA. Commercially available “tight curve” pigtail catheters allow for deeper placement in the LAA, a right anterior oblique/caudal projection can be helpful in profiling the LAA for sheath advancement.

**LA pressure measurement.** Measuring LA pressure can be helpful in confirming position in the LA during TSP and ensuring that the LA pressure is high enough to properly measure LAA dimension during the procedure to ensure proper device size selection and to avoid choosing a device too small and risking embolization. A mean LA pressure of  $\geq 12$  mm Hg is recommended for proper LAA measurements and device size selection.<sup>43</sup> Intravenous fluid should be administered when patients arrive for the procedure unless contraindicated, and hydration should be administered until the goal LA pressure is achieved.

**Deployment of LAAC device.** Operators should refer to the manufacturer’s instructions for use for proper device deployment for each commercially available device and should adhere to established criteria to ensure proper positioning before device release. Care should be taken to ensure proper device sizing, anchoring, positioning within the LAA, and absence of significant PDLs.



## Avoidance, recognition, and treatment of intraprocedural complications

### 6. Operators need to be familiar with avoidance, recognition, and management of complications associated with LAAC

WATCHMAN, the first LAAC device approved for general use, underwent a lengthy, multistep approval consisting of 2 randomized clinical trials, 2 continued access registries, and an unprecedented 3 FDA panel hearings spanning 2 decades before approval for commercialization was obtained. This was largely due to safety concerns surrounding the LAAC procedure. In the PROTECT AF RCT, there was an 8.7% complication rate driven largely by a 4.8% serious pericardial effusion, as well as 0.6% device embolization, 0.6% air embolism, 0.9% procedure-related stroke, and 0.6% access-site bleeding.<sup>21</sup> Following procedure refinements and increasing operator experience, the complication rates have dropped significantly. Contemporary clinical data suggest that serious complication rates and pericardial effusions/tamponade are well <2%. Despite this, it is essential that all implanters be skilled in the recognition and treatment of procedural complications and be attentive to the details necessary to prevent such events (Table 4).

**Pericardial effusion.** Imaging of the pericardial space should be performed at the beginning and end of every LAAC procedure to assess for pericardial effusion. Systemic blood pressure should be monitored throughout the procedure with a manual cuff or arterial line to aid prompt diagnosis of tamponade. Pericardial effusion is typically caused by perforation of the LAA and can result in tamponade, requiring urgent pericardiocentesis and, rarely, urgent surgery. Pericardial effusion may also be related to the TSP or damage to other cardiac structures. Increasing experience with LAAC, preprocedural imaging and planning, the use of intraprocedural echocardiographic guidance, and utilization of less traumatic guide wires and pigtail catheters have resulted in a marked decrease in pericardial effusion. In particular, the mandated use of a pigtail catheter for entry into the LAA allowed advancement of the large sheath more safely, preventing damage to the thin LAA wall. LAAC has seen a stepwise decrease in serious pericardial effusion from 5.0% to the current level of <1.5%. In the NCDR LAO Registry of 38,158 patients treated with the commercial WATCHMAN device from 2016 to 2018, pericardial effusion requiring intervention was documented in 528 (1.39%) patients, of

which 437 (83%) were treated with percutaneous drainage, primarily for tamponade. There were 91 (17%) patients who required open cardiac surgery.<sup>24</sup>

Operators and other members of the procedure team should be adept in recognition and prompt pericardiocentesis for effusions associated with any signs of hemodynamic compromise. Pericardiocentesis trays should be in the room, and surgical teams should be immediately available, should surgical intervention become necessary. If bleeding is still brisk into the pericardium after pericardiocentesis pigtail insertion and draining, protamine may be considered. Autotransfusion and surgical intervention are the immediate next management steps. Occasionally, pericarditis may result from pericardial drainage, which is conventionally managed with a short course of colchicine and/or anti-inflammatory agents.

**Periprocedural stroke.** The second major complication identified in the PROTECT AF trial was periprocedural stroke, which has decreased substantially with experience. In the NCDR LAO Registry, an ischemic stroke was documented in 0.12%, whereas hemorrhagic stroke was identified in 0.01%.<sup>24</sup> Several potential causes of stroke have been identified: (1) preprocedural presence of thrombus or sludge; (2) air embolization, typically the result of inadequate purging and flushing of equipment; and (3) development of thrombus on equipment during the procedure. Rigorous screening to rule out LAA thrombus before procedure and meticulous flushing to avoid air embolization are essential. The incidence of air embolism is extremely rare in contemporary practice with careful preparation of equipment. In the presence of spontaneous echo contrast, operators should proceed with caution after ruling out the presence of thrombus. Administering intravenous UFH during the procedure aiming for ACT 250 to 300 seconds is necessary to reduce the risk of thrombus formation on catheters, wires, devices, and so forth. Inadequate procedural anticoagulation, prolonged procedure duration, or excessive recaptures of the device (resulting in tissue trauma) may promote thrombus formation. Once thrombus is identified, additional heparin should be administered, and a prompt decision should be made whether to continue the procedure after documenting successful resolution of the thrombus or to abort and remove the equipment with adherent thrombus.

**Device embolization.** This complication is uncommon. In the NCDR LAO Registry, 30 (0.07%) embolizations were reported.<sup>24</sup> A systematic review of cases reported with both the WATCHMAN device and Amplatzer Cardiac Plug identified 31 cases.<sup>44</sup> Two-thirds occurred during the implant, whereas the others occurred later, sometimes detected at follow-up TEE or cardiac CT angiography as incidental findings in patients who were asymptomatic. Embolized devices may be lodged in the aorta, LA, or left ventricle. In 21 of the cases for which information was available, percutaneous removal was attempted in 17 and a surgical approach attempted in 10 to retrieve the embolized devices. The retrieval approach was in large part dependent on the location of the embolized device; surgery was typically the first choice if the device had embolized to the left ventricle and was entangled in the mitral apparatus and associated with hemodynamic deterioration. LAAC devices that had embolized to the descending aorta or LA were often successfully retrieved percutaneously. Although the case numbers were small, potential mechanisms for embolization included device undersizing or oversizing. Implanters should be skilled in the use of large sheaths and snares for retrieving devices from the LA or aorta.

**Other complications.** The NCDR LAO Registry documented other important procedural complications, namely in-hospital major bleeding that occurred in 1.25% and major vascular complications in 0.15%.<sup>24</sup> In this regard, 70% of the patients had a history of prior bleeding,

**Table 4.** Procedural and late postprocedural complications of left atrial appendage occlusion.

Periprocedural complications	Postprocedural complications
Death (<0.2%)	Late pericardial effusion & tamponade (~1%)
Stroke (<0.2%): Ischemic: air or thromboembolism Hemorrhagic	Peridevice leak: >5 mm on TEE: 1%-3% >3 mm on TEE: 10%-25%
Systemic embolism (rare)	Device-related thrombus (3%-5%)
Pericardial tamponade (~1%)	Late device migration/ embolization (infrequent)
Device embolization (~0.2%)	Device erosion (rare)
Vascular complications: retroperitoneal bleed, arteriovenous fistula, pseudoaneurysm	Iatrogenic atrial septal defects (rare to require intervention)
Other: major bleeding, renal failure, respiratory failure, sepsis, MI, endotracheal/esophageal damage, interfering surrounding structures, device/contrast allergy, pericarditis	

MI, myocardial infarction; TEE, transesophageal echocardiography.



including 42% with prior gastrointestinal bleeding. Venous bleeding with the large sheath size may occur. Access-site bleeding can be avoided by practicing good technique for gaining access and achieving hemostasis. Using ultrasound-guided venous puncture with micro-puncture needle/catheter may enhance safety. Using suture-mediated preclosure or figure-of-8 suture or combining the 2 ensures complete hemostasis and minimizes the possibility of late access-site bleeding. Avoidance of excessive anticoagulation and adherence to standard hemostasis techniques can help prevent bleeding.

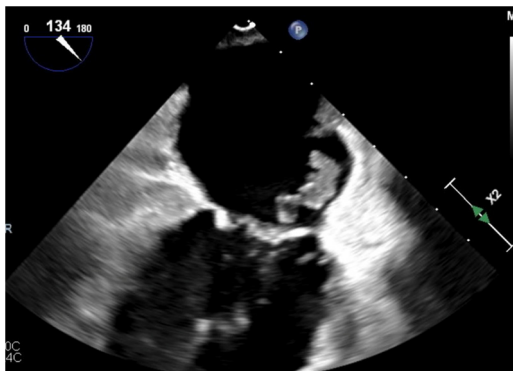
7. *Predischarge imaging should be performed with 2D transthoracic echocardiography to rule out pericardial effusion and device embolization. Same-day discharge may be appropriate after several hours of observation, demonstrating no complications or pericardial effusion after LAAC*

Imaging with 2D transthoracic echocardiogram is recommended before hospital discharge to evaluate for new pericardial effusion and rule out device embolization. After LAAC, patients were observed overnight in-hospital in the US pivotal trials of the WATCHMAN device, and this is currently common practice after LAAC. "Inpatient status" is mandated by CMS for reimbursement.<sup>23</sup> Several small case series have evaluated the feasibility of same-day discharge after endocardial LAAC and found that in selected patients without procedural complications, same-day discharge can be done without an associated increase in adverse events.<sup>45,46</sup> More data should be collected before same-day discharge can be routinely advocated, although that practice is increasing in frequency and may be appropriate after several hours of observation, demonstrating no complications or pericardial effusion.

### Recognition and management of late adverse events

8. *Device-related thrombus should be treated with anticoagulation. Repeat imaging at 45- to 90-day intervals can be performed to assess for resolution with eventual cessation of anticoagulation*

**Device-related thrombosis.** Device-related thrombosis (DRT) (Figure 4) has been reported after 3% to 5% of LAAC procedures in large clinical trial and registry experiences.<sup>10,11,24</sup> DRT has been shown to be more likely in patients with prior stroke, large LAA dimensions, those with permanent AF, and those with previous LA thrombus.<sup>11,47-49</sup> The relationship between DRT and long-term adverse cardiovascular events is unclear, but registry-based analyses have found an association between DRT and stroke/transient ischemic attack (TIA) during short-term follow-up.<sup>10,47</sup> However, most strokes after LAAC occur in patients without



**Figure 4.** Device-related thrombus (TEE). TEE, transesophageal echocardiography.

DRT; thus, the clinical importance of DRT is not well understood.<sup>11,46</sup> If DRT is diagnosed on post-LAAC imaging, anticoagulation should be continued. For patients on dual antiplatelet therapy (DAPT), OAC should be started and DAPT should be discontinued.<sup>50</sup> Repeat imaging at 45- to 90-day intervals can be performed to assess for resolution with eventual cessation of anticoagulation. Both cardiac CT and TEE have comparable accuracy for DRT detection<sup>51,52</sup> and should be chosen according to site experience and patient's preference and clinical profile.

9. *Routine closure of iatrogenic atrial septal defects associated with LAAC should not be performed*

**Residual iatrogenic ASD.** Endovascular LAAC requires traversal of the interatrial septum with a large sheath; subsequent removal of the sheath may result in left-to-right or even bidirectional shunting, which typically resolves by 6 months in most cases.<sup>53</sup> There has been very little study of the clinical significance of iatrogenic ASD from the LAAC procedure. Small randomized trials have not shown any clinical benefit in closure of the iatrogenic ASD after transcatheter edge-to-edge repair of the mitral valve or transcatheter mitral valve replacement, which require >20F sheaths/devices.<sup>54</sup> At present, there is no clear indication for closure of the iatrogenic ASD associated with LAAC unless there is significant right ventricular dilation and/or dysfunction.

10. *The clinical impact and management of PDLs are not fully understood and all efforts should be made to minimize such leaks at the time of implantation*

**Peridevice leak.** Peridevice leaks (PDLs) are common and are reported in 11% to 57% of transcatheter LAAC procedures depending on the implanted device and imaging modality used.<sup>55-58</sup> A relatively small secondary analysis of the PROTECT AF trial showed no difference in adverse event rates between leak sizes of <1, 1 to 3, and >3 mm but did not evaluate larger leaks with the WATCHMAN device. Subsequent studies have corroborated these results, although these were small and may have been underpowered to detect differences in outcomes.<sup>58,59</sup> An analysis of 51,333 patients in the NCDR LAAO Registry found that a small leak (<5 mm) was associated with a slightly higher rate of stroke, TIA, and systemic embolism over 1 year (adjusted hazard ratio, 1.152; 95% CI, 1.025-1.294).<sup>60</sup>

There are limited data and no consensus on the management of PDL. PDLs of >5 mm are believed to be significant, and current practice is generally to continue OAC. Case reports and small case series have demonstrated the feasibility of closing leaks using interventional approaches including placement of occlusion or plug devices or coiling, but data are lacking on the long-term impact of these approaches including adverse event rates and the safety of discontinuing OAC.<sup>61-64</sup>

**Late pericardial effusion.** Late pericardial effusion has been reported infrequently via case reports and in 1% of patients in the PRAGUE-17 trial.<sup>12,65</sup> These may be related to the hooks of the devices penetrating through the LAA wall. Management is similar to periprocedural pericardial effusion.

**Rare complications (device erosion, infection, nickel allergy).** Left atrial appendage closure may be associated with device erosion in rare cases. Erosion can result in damage to the pulmonary artery or late pericardial effusion.<sup>15,66</sup> Infection is exceedingly rare with LAAC<sup>67</sup>; nevertheless, the instructions for use for both the WATCHMAN and Amulet devices recommend appropriate endocarditis prophylaxis for 6 months after device implantation.

Treatment for device infection may require antibiotics and surgical removal of the device.<sup>13</sup> Devices available for LAAC in the United States are predominantly made of nitinol, an alloy of roughly equal parts nickel and titanium. Allergic reactions to nickel have been reported in patients undergoing patent foramen ovale/ASD closure and usually present as dermatitis, although reports of uncomplicated implantation in patients with documented nickel allergies have also been published.<sup>14,68</sup> In general, manufacturer indications for use recommend against implantation of nitinol devices in patients with a documented significant nickel allergy.

11. Patients should be prescribed antithrombotic therapy with warfarin, direct oral anticoagulants, or DAPT after LAAC according to the studied regimen and instructions for use for each specific device and tailored to bleeding risks of each patient

The FDA approved the WATCHMAN device based on the PROTECT AF and PREVAIL trials, in which warfarin and aspirin were administered for 45 days, and if no DRT or PDL of >5 mm was observed on TEE, patients transitioned to DAPT with aspirin and clopidogrel until 6 months after implant and to aspirin alone afterward.<sup>12,24,69,70</sup> However, following FDA approval, the NCDR LAAO Registry showed utilization of varied antithrombotic regimens after LAAC in the United States. In this Registry, discharge after LAAC with WATCHMAN device on DOAC and aspirin was associated with similar outcomes compared with warfarin and aspirin at 45 days and 6 months. Furthermore, discharge on either warfarin or DOAC alone without aspirin was associated with a lower risk of adverse events, largely due to lower rates of bleeding.<sup>24</sup> In the PINNACLE FLX study, patients were discharged on DOAC and aspirin for 45 days and then transitioned to DAPT; there are similar or favorable outcomes in other studies compared with the older pivotal trials.<sup>71</sup> The WATCHMAN FLX FDA label initially allowed for either warfarin or DOAC in addition to aspirin for the initial 45 days after device implantation before transitioning to DAPT. The revised FDA labeling now allows the use of DAPT for 45 days after WATCHMAN FLX implantation, following a recent propensity-matched study comparing DAPT versus either a DOAC or warfarin plus aspirin after WATCHMAN FLX in the NCDR LAAO Registry, which showed no difference in the rate of composite death, stroke, or major bleeding, and device-related thrombus.<sup>72</sup>

The use of postprocedural DAPT (without OAC) after LAAC is common practice in Europe and other parts of the world, as most patients treated with LAAC have contraindications to OAC.<sup>68</sup> In the Amulet IDE study, 75.7% of patients were discharged on DAPT after Amulet implantation, and the rate of DRT was not different from the WATCHMAN arm, in which 95.8% were on OAC at discharge.<sup>73</sup> Other small trials and single/multicenter prospective observational registries using the WATCHMAN and Amplatzer/Amulet devices have shown similar results.<sup>26,49,55,74</sup> The EWOLUTION registry of WATCHMAN procedures performed in Europe reported that 60% of patients were discharged on DAPT, with an adverse events rate comparable with that published in the pivotal WATCHMAN trials.<sup>26,49</sup> The NCDR LAAO Registry showed that discharge on DAPT after WATCHMAN implant was relatively uncommon (5% of implants) but was associated with a similar risk of adverse events compared with warfarin and aspirin at 45 days and 6 months.<sup>24</sup> A large meta-analysis of 83 studies including 12,326 LAAC patients (7900 on antiplatelet, and 4151 on OAC) showed no difference in stroke, DRT, bleeding, or overall mortality with antiplatelet versus OAC after LAAC.<sup>75</sup> Currently enrolling randomized trials will continue to evaluate optimal postprocedural antithrombotic strategies (Table 1).

In summary, the studies till date are insufficient to define an optimal postprocedural antithrombotic regimen following LAAC. Discharge on anticoagulation with anticoagulant plus aspirin is well established for WATCHMAN based on the PROTECT AF, PREVAIL, and PINNACLE FLX studies. Discharge on DAPT appears well

established for the Amulet device based on the Amulet IDE study and real-world registries. There is also an increasing body of registry evidence supporting DAPT with WATCHMAN. At this juncture, the choice and duration of antithrombotic regimen after LAAC should be made according to the studied regimen for each specific device, potentially individualized based on the patient's bleeding/thrombotic risk, and potentially modified if PDL or DRT is seen on post-LAAC imaging surveillance.

12. TEE or cardiac CT is recommended at 45 to 90 days after LAAC for device surveillance to assess for PDL and DRT

There is variability in clinical practice on postprocedural imaging modality and timing. Typically, imaging surveillance after LAAC device implantation is recommended at 3 time points:

1. Immediately after LAAC implant to evaluate for pericardial effusion, device stability, and PDL (with TEE or ICE)
2. Prehospital discharge to evaluate for new pericardial effusion and device embolization (with 2D transthoracic echocardiography)
3. At 45 days after LAAO device implant to evaluate for sealing of the LAAC device or continued presence of PDL.

Common imaging modalities utilized at these specific time points are depicted in Table 5.

Of note, some centers delay the 45-day imaging to 90 days, and some centers routinely perform a second TEE/cardiac CT at 1 year as per the PROTECT AF trial protocol. The instructions for use for WATCHMAN recommends both 45-day and 1-year device surveillance. During the COVID-19 pandemic, some physicians migrated away from TEE, which generates aerosolization, to less invasive surveillance imaging with the use of cardiac CT.<sup>76</sup> There appears to be greater sensitivity and reproducibility of cardiac CT for the evaluation of LAAC PDL and similar rate of detection of DRT compared with TEE.<sup>51,52</sup> These reasons together with the noninvasiveness led to many preferring cardiac CT over TEE for device surveillance (Table 5). However, imaging surveillance after LAAC is an evolving topic and more comparative and prospective data are required.<sup>51</sup> We recommend device surveillance with TEE/CT angiography at 45 to 90 days after LAAC, and a second imaging at 1 year should be considered if a PDL is there at prior imaging or if there are concerns for DRT risk.

**Table 5.** Imaging surveillance modality and optimal imaging at different postdevice implantation time points.

Imaging timing	Immediate postdevice implant	Prehospital discharge	45-d follow-up	1-y follow-up (optional)
Transthoracic echocardiogram	–	+++	–	–
Transesophageal echocardiogram	+++	–	++	++
CCTA	–	–	+++	+++
Complication surveillance	Pericardial effusion	Device embolization	Peridevice leak	Device-related thrombus
Transthoracic echocardiogram	+++	+	–	–
Transesophageal echocardiogram	+++	+++	++	+++
CCTA	+++	+++	+++	+++

+++ , strongly recommended; ++ , less strongly recommended; + , recommended; – , not required.

CCTA, cardiac computed tomography angiography.

13. Combined procedures with LAAC (eg, structural interventions, PVI) are not routinely recommended pending data from ongoing RCTs

Left atrial appendage closure is increasingly performed simultaneously with PVI ablation and other structural heart procedures. In a report of 139 patients from 10 European centers who underwent AF ablation (chiefly PVI) followed by WATCHMAN LAAC in the same setting,<sup>77</sup> a high degree of LAAC success (100%) with excellent periprocedural safety and an early (28 days) 98% freedom from PDL of >5 mm was shown. There were, however, leaks of <5 mm, potentially the result of small device migration with resolution of tissue edema from PVI. Good results were confirmed at the 2-year follow-up, with 92% off OAC and a relative 84% cerebrovascular accident/TIA reduction compared with predicted in patients with similar risk scores not treated with OAC.<sup>78</sup> The OPTION trial randomized ~1600 patients 1:1 to either OAC or WATCHMAN FLX following AF ablation, with approximately one-third of the WATCHMAN devices being placed concomitantly immediately after ablation. Results are anticipated in 2023. The aMAZE study (NCT02513797<sup>79</sup>) prospectively randomized patients 2:1 to percutaneous suture closure of the LAA (LARIAT, SentreHEART) as an adjunct to PVI ablation in patients with symptomatic or longstanding persistent AF. This study showed that although performing LAA ligation together with PVI was safe, there was no reduction in recurrent AF compared with PVI alone.<sup>80</sup>

The WATCH-TAVR trial (NCT03173534<sup>81</sup>) randomized 350 patients with aortic stenosis and AF to transcatheter aortic valve replacement and medical therapy vs transcatheter aortic valve replacement with concomitant WATCHMAN LAAC with a primary end point of all-cause mortality, stroke, or major bleeding. Results are anticipated in 2023. Until these RCT results are available, combined procedures with LAAC should not be routinely performed.

### Future directions and landscape of LAAC

The field of transcatheter LAAC has evolved tremendously in its first 2 decades, with marked improvements in safety, efficacy, and device iterations. Ongoing trials and evolving practices indicate significant future advancements to come. The FDA approval of WATCHMAN FLX and Amulet devices, in-progress RCTs evaluating new devices, and an array of other technologies in the development and approval queue will mean a larger toolbox for LAAC. Several RCTs comparing LAAC to controls in OAC-ineligible patients and RCTs comparing DOAC to LAAC in OAC-eligible patients are ongoing and are anticipated to broaden the clinical indications and strengthen societal recommendations for this device therapy. Advancements in periprocedural imaging have also improved the safety and efficiency of the procedure, and novel imaging technologies are continuing to be explored. This document provides the current evidence-based best practices of endovascular LAAC by consensus of the established expert panel with multisocietal support. Given the rapid developments in this field, this consensus document acknowledges important areas where further evidence is needed to be developed including but not restricted to the type and duration of post-LAAC antithrombotic therapy, standardization of post-LAAC imaging surveillance and time points; duration of OAC after DRT detection and follow-up imaging; management of PDL; and head-to-head comparison of LAAC vs DOAC in OAC-eligible patients.

### Declaration of competing interest

João Cavalcante received consulting fees from Boston Scientific and Abbott. Matthew Price serves on the advisory board and has received consulting, honoraria, and speakers bureau fees from Abbott. Brian

Whisenant received consulting fees from Boston Scientific and Abbott. Dee Dee Wang is a principal investigator for investigator-initiated research for Boston Scientific and has received consulting fees from Abbott. Jacqueline Saw, David Holmes, Andrew Goldsweig, James Freeman, Thomas Munger, Issam Moussa, Clifford Kavinsky, Matthew Sherwood, Zoltan Turi, and Mark Reisman reported no financial interests.

### Funding sources

This research did not receive any specific grant from funding agencies in the public, commercial, or not-for-profit sectors.

### Supplementary material

To access the supplementary material accompanying this article, visit the online version of the *Journal of the Society for Cardiovascular Angiography & Interventions* at [10.1016/j.jscai.2022.100577](https://doi.org/10.1016/j.jscai.2022.100577).

### References

- Szerlip M, Feldman DN, Aronow HD, et al. SCAI publications committee manual of standard operating procedures. *Catheter Cardiovasc Interv.* 2020;96(1):145–155.
- Benjamin EJ, Muntner P, Alonso A, et al. Heart disease and stroke statistics-2019 update: a report from the American Heart Association. *Circulation.* 2019;139(10):e56–e528.
- Martinez C, Katholing A, Wallenhorst C, Freedman SB. Therapy persistence in newly diagnosed non-valvular atrial fibrillation treated with warfarin or NOAC. A cohort study. *Thromb Haemost.* 2016;115(1):31–39.
- Blackshear JL, Odell JA. Appendage obliteration to reduce stroke in cardiac surgical patients with atrial fibrillation. *Ann Thorac Surg.* 1996;61(2):755–759.
- Johnson WD, Ganjoo AK, Stone CD, Srivayas RC, Howard M. The left atrial appendage: our most lethal human attachment! Surgical implications. *Eur J Cardiothorac Surg.* 2000;17(6):718–722.
- Whitlock RP, Belley-Cote EP, Paparella D, et al. Left atrial appendage occlusion during cardiac surgery to prevent stroke. *N Engl J Med.* 2021;384(22):2081–2091.
- WATCHMAN Left Atrial Appendage System for Embolic PROTECTioN in Patients With Atrial Fibrillation. ClinicalTrials.gov identifier: NCT00129545. Accessed July 20, 2021. <https://clinicaltrials.gov/ct2/show/NCT00129545>
- Evaluation of the WATCHMAN Left Atrial Appendage (LAA) Closure Device in Patients With Atrial Fibrillation Versus Long Term Warfarin Therapy (PREVAIL). ClinicalTrials.gov identifier: NCT01182441. Accessed July 20, 2021. <https://clinicaltrials.gov/ct2/show/NCT01182441>
- Left Atrial Appendage Closure vs. Novel Anticoagulation Agents in Atrial Fibrillation (PRAGUE-17). ClinicalTrials.gov identifier: NCT02426944. Accessed July 20, 2021. <https://clinicaltrials.gov/ct2/show/NCT02426944>
- Holmes DR, Reddy VY, Turi ZG, et al. Percutaneous closure of the left atrial appendage versus warfarin therapy for prevention of stroke in patients with atrial fibrillation: a randomised non-inferiority trial. *Lancet.* 2009;374(9689):534–542.
- Holmes DR, Kar S, Price MJ, et al. Prospective randomized evaluation of the Watchman Left Atrial Appendage Closure device in patients with atrial fibrillation versus long-term warfarin therapy: the PREVAIL trial. *J Am Coll Cardiol.* 2014;64(1):1–12.
- Osmancik P, Herman D, Neuzil P, et al. Left atrial appendage closure versus direct oral anticoagulants in high-risk patients with atrial fibrillation. *J Am Coll Cardiol.* 2020;75(25):3122–3135.
- WATCHMAN FLX versus NOAC for embolic protection in the management of patients with non-valvular atrial fibrillation. ClinicalTrials.gov identifier: NCT04394546. Accessed July 20, 2021. <https://clinicaltrials.gov/ct2/show/NCT04394546>
- Amplatzer Amulet LAAC vs. NOAC (CATALYST). ClinicalTrials.gov identifier: NCT04226547. Accessed July 20, 2021. <https://clinicaltrials.gov/ct2/show/NCT04226547>
- Comparison of anticoagulation with left atrial appendage closure after AF ablation (OPTION). ClinicalTrials.gov identifier: NCT03795298. Accessed July 20, 2021. <https://clinicaltrials.gov/ct2/show/NCT03795298>
- Assessment of the WATCHMAN Device in Patients Unsuitable for Oral Anticoagulation (ASAP-TOO). ClinicalTrials.gov identifier: NCT02928497. Accessed July 21, 2021. <https://clinicaltrials.gov/ct2/show/NCT02928497>
- Prevention of Stroke by Left Atrial Appendage Closure in Atrial Fibrillation Patients After Intracerebral Hemorrhage. ClinicalTrials.gov identifier: NCT02830152. <https://clinicaltrials.gov/ct2/show/NCT02830152>
- Left Atrial Appendage CLOSURE in Patients With Atrial Fibrillation Compared to Medical Therapy (CLOSURE-AF). ClinicalTrials.gov identifier: NCT03463317. Accessed July 20, 2021. <https://clinicaltrials.gov/ct2/show/NCT03463317>



19. January CT, Wann LS, Calkins H, et al. 2019 AHA/ACC/HRS focused update of the 2014 AHA/ACC/HRS guideline for the management of patients with atrial fibrillation: a report of the American College of Cardiology/American Heart Association task force on clinical practice guidelines and the Heart Rhythm Society in collaboration with the Society of Thoracic Surgeons. *Circulation*. 2019; 140(2):e125–e151. Published correction appears in *Circulation*. 2019;140(6):e285.
20. Hindricks G, Potpara T, Dagres N, et al. 2020 ESC guidelines for the diagnosis and management of atrial fibrillation developed in collaboration with the European Association for Cardio-Thoracic Surgery (EACTS): the task force for the diagnosis and management of atrial fibrillation of the European Society of Cardiology (ESC) developed with the special contribution of the European Heart Rhythm Association (EHRA) of the ESC. *Eur Heart J*. 2021;42(5):373–498. Published correction appears in *Eur Heart J*. 2021;42(5):546–547. Published correction appears in *Eur Heart J*. 2021;42(40):4194.
21. Reddy VY, Sievert H, Halperin J, et al. Percutaneous left atrial appendage closure vs warfarin for atrial fibrillation: a randomized clinical trial. *JAMA*. 2014;312(19):1988–1998.
22. Approval order for the Watchman LAA closure technology (P130013). United States Department of Health & Human Services. Accessed July 21, 2021. [https://www.accessdata.fda.gov/cdrh\\_docs/pdf13/P130013A.pdf](https://www.accessdata.fda.gov/cdrh_docs/pdf13/P130013A.pdf)
23. Decision memo for percutaneous left atrial appendage (LAA) closure therapy (CAG-00445N). Centers for Medicare & Medicaid Services. Accessed July 21, 2021. <https://www.cms.gov/medicare-coverage-database/details/nca-decision-memo.aspx?NCAId=281>
24. Freeman JV, Varosy P, Price MJ, et al. The NCDR left atrial appendage occlusion registry. *J Am Coll Cardiol*. 2020;75(13):1503–1518.
25. Lip GYH, Nieuwlaat R, Pisters R, Lane DA, Crijns HJGM. Refining clinical risk stratification for predicting stroke and thromboembolism in atrial fibrillation using a novel risk factor-based approach: the euro heart survey on atrial fibrillation. *Chest*. 2010;137(2):263–272.
26. Boersma LV, Ince H, Kische S, et al. Efficacy and safety of left atrial appendage closure with WATCHMAN in patients with or without contraindication to oral anticoagulation: 1-year follow-up outcome data of the EWOLUTION trial. *Heart Rhythm*. 2017;14(9):1302–1308.
27. Landmesser U, Schmidt B, Nielsen-Kudsk JE, et al. Left atrial appendage occlusion with the AMPLATZER Amulet device: periprocedural and early clinical/echocardiographic data from a global prospective observational study. *EuroIntervention*. 2017;13(7):867–876.
28. Marroquin L, Tirado-Conte G, Pracoñ R, et al. Management and outcomes of patients with left atrial appendage thrombus prior to percutaneous closure. *Heart*. 2022;108(14):1098–1106.
29. Masoudi FA, Calkins H, Kavinsky CJ, et al. 2015 ACC/HRS/SCAI Left Atrial Appendage Occlusion Device Societal Overview: A professional societal overview from the American College of Cardiology, Heart Rhythm Society, and Society for Cardiovascular Angiography and Interventions. *Catheter Cardiovasc Interv*. 2015; 86(5):791–807.
30. Kavinsky CJ, Kusumoto FM, Bavry AA, et al. SCAI/ACC/HRS institutional and operator requirements for left atrial appendage occlusion. *Catheter Cardiovasc Interv*. 2016;87(3):351–362.
31. Zipes DP, Calkins H, Daubert JP, et al. 2015 ACC/AHA/HRS advanced training statement on clinical cardiac electrophysiology (a revision of the ACC/AHA 2006 update of the clinical competence statement on invasive electrophysiology studies, catheter ablation, and cardioversion). *Heart Rhythm*. 2016;13(1):e3–e37.
32. Glikson M, Wolff R, Hindricks G, et al. EHRA/EAPCI expert consensus statement on catheter-based left atrial appendage occlusion - an update. *EuroIntervention*. 2020; 15(13):1133–1180.
33. Wang DD, Geske JB, Choi AD, et al. Interventional imaging for structural heart disease: challenges and new frontiers of an emerging multi-disciplinary field. *Struct Heart*. 2019;3(3):187–200.
34. Wang DD, Forbes TJ, Lee JC, Eng MH. Echocardiographic imaging for left atrial appendage occlusion: transesophageal echocardiography and intracardiac echocardiographic imaging. *Interv Cardiol Clin*. 2018;7(2):219–228.
35. Eng MH, Wang DD, Greenbaum AB, et al. Prospective, randomized comparison of 3-dimensional computed tomography guidance versus TEE data for left atrial appendage occlusion (PRO3DLAAO). *Catheter Cardiovasc Interv*. 2018;92(2):401–407.
36. Korsholm K, Berti S, Iriart X, et al. Expert recommendations on cardiac computed tomography for planning transcatheter left atrial appendage occlusion. *J Am Coll Cardiol Interv*. 2020;13(3):277–292.
37. Wang DD, Eng M, Kupsky D, et al. Application of 3-dimensional computed tomographic image guidance to WATCHMAN implantation and impact on early operator learning curve: single-center experience. *J Am Coll Cardiol Interv*. 2016; 9(22):2329–2340.
38. Leipsic J, Nørgaard BL, Khalique O, et al. Core competencies in cardiac CT for imaging structural heart disease interventions: an expert consensus statement. *J Am Coll Cardiol Img*. 2019;12(12):2555–2559.
39. Kaafarani M, Saw J, Daniels M, et al. Role of CT imaging in left atrial appendage occlusion for the WATCHMAN™ device. *Cardiovasc Diagn Ther*. 2020;10(1):45–58.
40. Saw J, Fahmy P, Spencer R, et al. Comparing measurements of CT angiography, TEE, and fluoroscopy of the left atrial appendage for percutaneous closure. *J Cardiovasc Electrophysiol*. 2016;27(4):414–422.
41. Alkhouli M, Chaker Z, Alqahtani F, Raslan S, Raybuck B. Outcomes of routine intracardiac echocardiography to guide left atrial appendage occlusion. *J Am Coll Cardiol EP*. 2020;6(4):393–400.
42. Berti S, Pastormerlo LE, Santoro G, et al. Intracardiac versus transesophageal echocardiographic guidance for left atrial appendage occlusion: the LAAO Italian multicenter registry. *J Am Coll Cardiol Interv*. 2018;11(11):1086–1092.
43. Spencer RJ, DeJong P, Fahmy P, et al. Changes in left atrial appendage dimensions following volume loading during percutaneous left atrial appendage closure. *J Am Coll Cardiol Interv*. 2015;8(15):1935–1941.
44. Aminian A, Lalmand J, Tzikas A, Budts W, Benit E, Kefer J. Embolization of left atrial appendage closure devices: a systematic review of cases reported with the watchman device and the amplatzer cardiac plug. *Catheter Cardiovasc Interv*. 2015;86(1):128–135.
45. Gilhofer TS, Inohara T, Parsa A, et al. Safety and feasibility of same-day discharge after left atrial appendage closure. *Can J Cardiol*. 2020;36(6):945–947.
46. Tan BE-X, Boppana LKT, Abdullah AS, et al. Safety and feasibility of same-day discharge after left atrial appendage closure with the WATCHMAN device. *Circ Cardiovasc Interv*. 2021;14(1), e009669.
47. Main ML, Fan D, Reddy VY, et al. Assessment of device-related thrombus and associated clinical outcomes with the WATCHMAN left atrial appendage closure device for embolic protection in patients with atrial fibrillation (from the PROTECT-AF trial). *Am J Cardiol*. 2016;117(7):1127–1134.
48. Sherwood M, Bliden KP, Ilkhanoff L, et al. Detailed thrombogenicity phenotyping and 1 year outcomes in patients undergoing WATCHMAN implantation: (TARGET-WATCHMAN) a case-control study. *J Thromb Thrombolysis*. 2020;50(3):484–498.
49. Vuddanda VLK, Turagam MK, Umale NA, et al. Incidence and causes of in-hospital outcomes and 30-day readmissions after percutaneous left atrial appendage closure: a US nationwide retrospective cohort study using claims data. *Heart Rhythm*. 2020;17(3):374–382.
50. Saw J, Nielsen-Kudsk JE, Bergmann M, et al. Antithrombotic therapy and device-related thrombosis following endovascular left atrial appendage closure. *J Am Coll Cardiol Interv*. 2019;12(11):1067–1076.
51. Qamar SR, Jalal S, Nicolaou S, Tsang M, Gilhofer T, Saw J. Comparison of cardiac computed tomography angiography and transoesophageal echocardiography for device surveillance after left atrial appendage closure. *EuroIntervention*. 2019; 15(8):663–670.
52. Korsholm K, Jensen JM, Nørgaard BL, Nielsen-Kudsk JE. Detection of device-related thrombosis following left atrial appendage occlusion: a comparison between cardiac computed tomography and transesophageal echocardiography. *Circ Cardiovasc Interv*. 2019;12(9), e008112.
53. Al-Kassou B, Neikes F, Stock F, Buellesfeld L, Omran H. P6101 Incidence and persistence rates of iatrogenic atrial septal defects following left atrial appendage closure. *Eur Heart J*. 2017;38(suppl\_1), ehx493.P6101.
54. Shah P, deFilippi CR, Mullins KE. Late-breaking science abstracts and featured science abstracts from the American Heart Association's scientific sessions 2020 and late-breaking abstracts in resuscitation science from the Resuscitation Science Symposium 2020. *Circulation*. 2020;142(24):2293–2295.
55. Tzikas A, Gafoor S, Meerkin D, et al. Left atrial appendage occlusion with the AMPLATZER Amulet device: an expert consensus step-by-step approach. *EuroIntervention*. 2016;11(13):1512–1521.
56. Saw J, Tzikas A, Shakir S, et al. Incidence and clinical impact of device-associated thrombus and peri-device leak following left atrial appendage closure with the amplatzer cardiac plug. *J Am Coll Cardiol Interv*. 2017;10(4):391–399.
57. Pillarisetti J, Reddy YM, Gundu S, et al. Endocardial (Lariat) left atrial appendage exclusion devices: understanding the differences in the location and type of leaks and their clinical implications. *Heart Rhythm*. 2015; 12(7):1501–1507.
58. Nguyen A, Gallet R, Riant E, et al. Peridevice leak after left atrial appendage closure: incidence, risk factors, and clinical impact. *Can J Cardiol*. 2019;35(4):405–412.
59. Viles-Gonzalez JF, Kar S, Douglas P, et al. The clinical impact of incomplete left atrial appendage closure with the Watchman Device in patients with atrial fibrillation: a PROTECT AF (Percutaneous Closure of the Left Atrial Appendage Versus Warfarin Therapy for Prevention of Stroke in Patients With Atrial Fibrillation) substudy. *J Am Coll Cardiol*. 2012;59(10):923–929.
60. Alkhouli M, Du C, Killu A, et al. Clinical impact of residual leaks following left atrial appendage occlusion: insights from the NCDR LAAO registry. *J Am Coll Cardiol EP*. 2022;8(6):766–778.
61. Della Rocca DG, Horton RP, Di Biase L, et al. First experience of transcatheter leak occlusion with detachable coils following left atrial appendage closure. *J Am Coll Cardiol Interv*. 2020;13(3):306–319.
62. Alkhouli M, Alqahtani F, Kazienko B, Olgers K, SenGupta PP. Percutaneous closure of peridevice leak after left atrial appendage occlusion. *J Am Coll Cardiol Interv*. 2018;11(11):e83–e85.
63. Transcatheter leak closure with detachable coils following incomplete left atrial appendage closure procedures (TREASURE). ClinicalTrials.gov identifier: NCT03503253. Accessed July 20, 2021. <https://clinicaltrials.gov/ct2/show/NCT03503253>
64. Sleiman JR, Lewis AJ, Perez EJ, et al. Management of peri-device leak following left atrial appendage closure: a systematic review. *Catheter Cardiovasc Interv*. 2021; 98(2):382–390.
65. Reddy VY, Doshi SK, Kar S, et al. 5-year outcomes after left atrial appendage closure: from the PREVAIL and PROTECT AF trials. *J Am Coll Cardiol*. 2017; 70(24):2964–2975.



66. AMPLATZER Amulet left atrial appendage occluder trial (Amulet IDE). ClinicalTrials.gov identifier: NCT02879448. Accessed July 20, 2021. <https://clinicaltrials.gov/ct2/show/NCT02879448>
67. Williams T, Alsanjari O, Parker J, et al. Day-case percutaneous left atrial appendage occlusion-safety and efficacy. *Catheter Cardiovasc Interv.* 2018;92(7):1439–1443.
68. Kirchhof P, Benussi S, Kotecha D, et al. 2016 ESC guidelines for the management of atrial fibrillation developed in collaboration with EACTS. *Eur Heart J.* 2016;37(38):2893–2962.
69. Fauchier L, Cinaud A, Brigadeau F, et al. Device-related thrombosis after percutaneous left atrial appendage occlusion for atrial fibrillation. *J Am Coll Cardiol.* 2018;71(14):1528–1536.
70. Dukkipati SR, Kar S, Holmes DR, et al. Device-related thrombus after left atrial appendage closure: incidence, predictors, and outcomes. *Circulation.* 2018;138(9):874–885.
71. Kar S, Doshi SK, Sadhu A, et al. Primary outcome evaluation of a next-generation left atrial appendage closure device: results from the PINNACLE FLX trial. *Circulation.* 2021;143(18):1754–1762.
72. Coylewright M, et al. Comparative effectiveness of post-procedure medications following left atrial appendage occlusion: a DAPT analysis with WATCHMAN FLX. Presented at TVT. June 9, 2022. Chicago, USA.
73. Lakkireddy D, Thaler D, Ellis CR, et al. Amplatzer Amulet left atrial appendage occluder versus Watchman device for stroke prophylaxis (Amulet IDE): a randomized, controlled trial. *Circulation.* 2021;144(19):1543–1552.
74. Reddy VY, Möbius-Winkler S, Miller MA, et al. Left atrial appendage closure with the Watchman device in patients with a contraindication for oral anticoagulation: the ASAP study (ASA Plavix feasibility study with Watchman left atrial appendage closure technology). *J Am Coll Cardiol.* 2013;61(25):2551–2556.
75. Osman M, Busu T, Osman K, et al. Short-term antiplatelet versus anticoagulant therapy after left atrial appendage occlusion: a systematic review and meta-analysis. *J Am Coll Cardiol EP.* 2020;6(5):494–506.
76. Shah PB, FGP Welt, Mahmud E, et al. Triage considerations for patients referred for structural heart disease intervention during the COVID-19 pandemic: an ACC/SCAI position statement. *J Am Coll Cardiol Interv.* 2020;13(12):1484–1488.
77. Phillips KP, Pokushalov E, Romanov A, et al. Combining Watchman left atrial appendage closure and catheter ablation for atrial fibrillation: multicentre registry results of feasibility and safety during implant and 30 days follow-up. *Europace.* 2018;20(6):949–955.
78. Phillips KP, Romanov A, Artemenko S, et al. Combining left atrial appendage closure and catheter ablation for atrial fibrillation: 2-year outcomes from a multinational registry. *Europace.* 2020;22(2):225–231.
79. aMAZE Study: LAA Ligation Adjunctive to PVI for Persistent or Longstanding Persistent Atrial Fibrillation (aMAZE). ClinicalTrials.gov identifier: NCT02513797. Accessed July 20, 2021. <https://clinicaltrials.gov/ct2/show/NCT02513797>
80. Lee RJ, Lakkireddy D, Mittal S, et al. Percutaneous alternative to the Maze procedure for the treatment of persistent or long-standing persistent atrial fibrillation (aMAZE trial): rationale and design. *Am Heart J.* 2015;170(6):1184–1194.
81. WATCH-TAVR, WATCHMAN for Patients With Atrial Fibrillation Undergoing Transcatheter Aortic Valve Replacement. ClinicalTrials.gov identifier: NCT03173534. Accessed July 20, 2021. <https://clinicaltrials.gov/ct2/show/NCT03173534>