

Available online at [www.sciencedirect.com](http://www.sciencedirect.com)

ScienceDirect

journal homepage: [www.elsevier.com/locate/radcr](http://www.elsevier.com/locate/radcr)

## Case Report

# Canal of Nuck incarcerated ovarian hernia with strangulation, a case report<sup>☆</sup>

Jamshid Sadiqi, MD, MS<sup>a,\*</sup>, Mustafa Ezmarai, MD, PhD<sup>b</sup>, Jawid Niazi, MD, MS<sup>b</sup>

<sup>a</sup> Radiology department, Mellat Medical Complex, Taimani square, Kabul, Afghanistan

<sup>b</sup> Pediatric Surgery Department, Alashraf Clinic

## ARTICLE INFO

## Article history:

Received 15 August 2021

Revised 3 February 2022

Accepted 5 February 2022

## Key words:

Canal of Nuck

Labia majus

Ovarian hernia

Incarceration

Strangulation

Ultrasonography

## ABSTRACT

Canal of Nuck ovarian hernia is a rare medical entity which presents as labia majora swelling in female babies. The serious complications of strangulation and torsion may happen which requires urgent surgical intervention. Here an incarcerated labium majus ovarian hernia with strangulation is presented in a six-month-old female baby. The diagnosis was made by ultrasonography and then urgent surgery was performed.

© 2022 The Authors. Published by Elsevier Inc. on behalf of University of Washington.

This is an open access article under the CC BY-NC-ND license

(<http://creativecommons.org/licenses/by-nc-nd/4.0/>)

## Introduction

The incidence of inguinal hernia in pediatric population is between 0.8 to 4.4% which is about 6 to 10 times higher in male children compared to females. The inguinal hernia in girls is rare and is called canal of Nuck hernia [1–2]. It is non-obiterated processus vaginalis during early childhood which may encounter indirect inguinal hernia or hydrocele at the level of labia majora. The hernia content can be bowel loop and its mesentery, fluid, uterus, ovary and fallopian tubes [3]. Incarcerated canal of Nuck hernia can be seen in cases of ovary with or without its fallopian tube and may result in strangulation and torsion that needs urgent surgery. Ultra-

sound is the most suitable imaging modality for diagnosis of the canal of Nuck pathologies [3].

Here we present a case of canal of Nuck hernia with content of right ovary and part of its fallopian tube associated with incarceration and strangulation.

## Case presentation

A 6-month old female baby with a palpable mass in her right labium majus was referred from pediatric surgery department to ultrasound department. The patient's parents mentioned that the swelling is from 1 month ago. They explained that

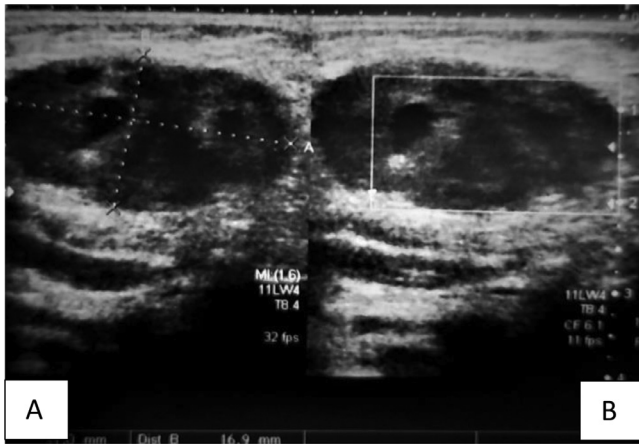
<sup>☆</sup> Competing Interest: The authors declare no conflict of interest in this case report.

\* Corresponding author.

E-mail address: [jamshidsadiqi79@gmail.com](mailto:jamshidsadiqi79@gmail.com) (J. Sadiqi).

<https://doi.org/10.1016/j.radcr.2022.02.025>

1930-0433/© 2022 The Authors. Published by Elsevier Inc. on behalf of University of Washington. This is an open access article under the CC BY-NC-ND license (<http://creativecommons.org/licenses/by-nc-nd/4.0/>)

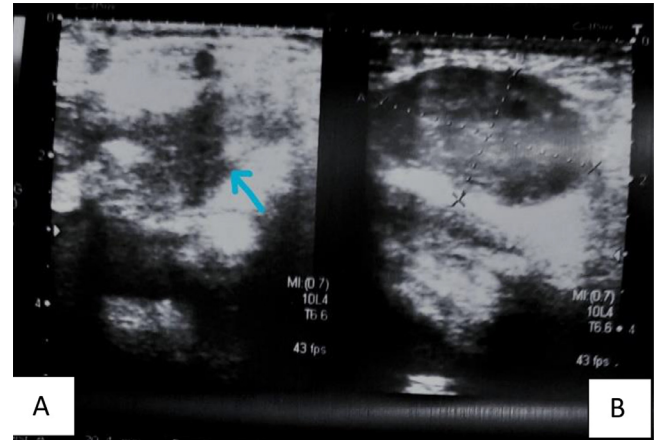


**Fig. 1 – (A)** Sonography of the right labium majus by linear probe demonstrates an ovoid shaped hypoechoic lesion containing few cysts inside suggest ovary which is measured 30 mm x 17 mm. **(B)** Color Doppler ultrasound shows no blood flow within the herniated ovary representing strangulation.

in the beginning the bulging was not always visible except for the moments that the baby was restless. They mentioned that the swelling became tender and did not disappear since last 3 days and the baby became very irritable. Except this problem, the baby did not have any other health issue.

In physical examination a persistent asymmetrical bulging was detected in right labium majus without any color changes in overlying skin. By palpation a firm solid mass was found.

Ultrasound examination was done by a high frequency linear probe that demonstrated an ovoid shaped hypoechoic lesion containing few rounded cysts inside. A soft tissue band was extended from the lesion noted in the inferior aspect of the lesion coming from a defect area representing hernia. The herniated content was irreducible during scanning and showed no blood flow by color Doppler ultrasound. These find-



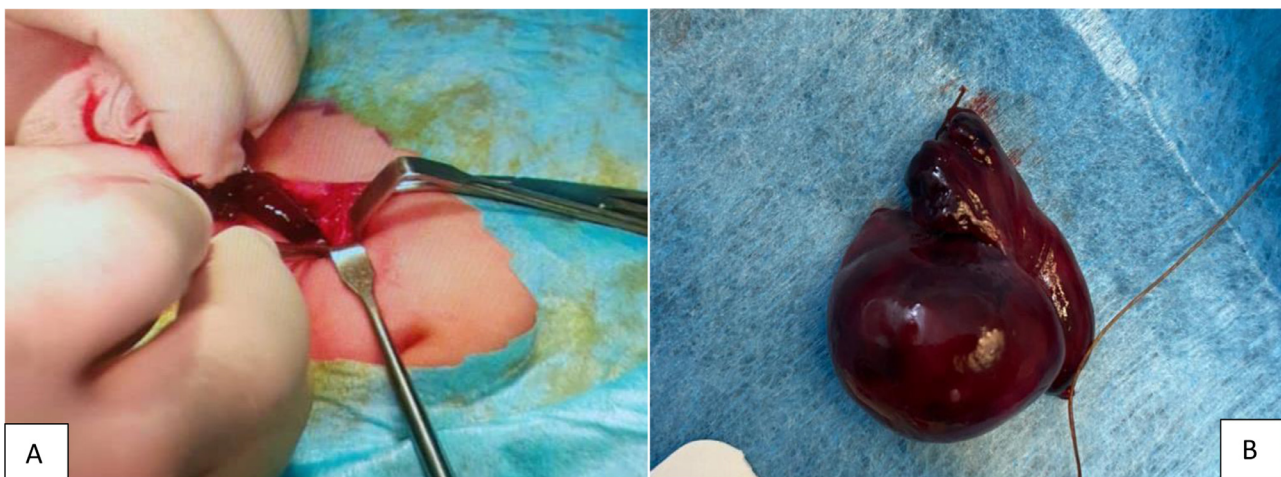
**Fig. 2 – (A)** Ultrasound of right labium majus shows site of the defect with herniation (blue arrow). **(B)** represents the herniated ovary. (Color version of figure is available online.)

ings suggested incarcerated right ovarian hernia with strangulation (Figs. 1 & 2).

The patient was referred to the pediatric surgery department which immediate surgery was performed. The sonography findings were confirmed during herniotomy surgery and the gangrenous right ovary with part of its fallopian tube were removed (Fig. 3).

## Discussion

Pediatric inguinal hernia mostly occurs in early childhood. The hernia is almost always of indirect type which is due to failure in closure of embryonic processus vaginalis. This defect may let the abdominal contents protrude from deep inguinal ring lateral to the inferior epigastric vessels into the patent inguinal canal [4–5]. In contrary the direct inguinal



**Fig. 3 – (A)** The herniotomy procedure showing gangrenous fallopian tube. **(B)** The gangrenous ovary with part of its fallopian tube.

canal often occurs in adulthood. The hernia is due to a weak point in lower abdominal wall posterior to the inguinal canal and medial to the inferior epigastric vessels [6].

The 2 fetal anatomic organs that form inguinal canal are processus vaginalis and gubernaculum testis. The gubernaculum testis is attached to the lower pole of gonad connecting it to the groin skin. In males it helps descending testis from abdomen to scrotal cavity through inguinal canal while in females the midpoint of gubernaculum testis is attached to the uterus and prevents descending of ovary into inguinal canal. The ovarian ligament and round ligament are homologues for gubernaculum testis in postnatal life in female babies [6].

The processus vaginalis invaginates into the inguinal canal as a peritoneal fold and usually obliterates in about 8 months of prenatal life in females. In any circumstances that this closure doesn't occur, it is called canal of Nuck. The occurrence of inguinal hernia is high in premature babies which is about 30% and is 6 times more in boys than girls. The canal of Nuck is a potential place for herniation of abdominal contents like bowel, mesenteric fat, fluid, ovary, uterus and fallopian tubes into the labia majora through inguinal canal [7]. In 15% to 20 % of cases the content is ovary with or without fallopian tubes. Sometimes the ovarian hernia is with strangulation which comprise 43 % of all ovarian hernia case. This condition occurs when there is incarceration of ovary with blockage of its blood supply [8]. Ultrasound is the modality of choice for rule out of canal of Nuck abnormalities and in many cases can establish the definitive diagnosis [9].

## Conclusion

Canal of Nuck hernias rarely occurs in female babies with different abdomen and pelvis contents. The prior knowledge of canal of Nuck abnormalities are vital for medical professionals in order to prevent the complications like incarceration and strangulation in cases of ovarian hernia. Ultrasonography is

the best imaging modality for fast detection and diagnosis of canal of Nuck disorders.

## Patient consent

Written informed consent was obtained for the publication of this case report.

## REFERENCES

- [1] Kapur P, Caty MG, Glick PL. Pediatric hernias and hydroceles. *Pediatr Clin North Am* 1998;45:773–89.
- [2] Lao OB, Fitzgibbons RJ, Cusick RA. Pediatric inguinal hernias hydroceles, and undescended testicles. *Surg Clin N Am* 2012;92:487–504.
- [3] Yang DM, Kim HC, Kim SW, et al. Ultrasonographic diagnosis of ovary-containing hernias of the canal of Nuck. *Ultrasonography* 2014;33:178–83.
- [4] George EK, Oudesluys-Murphy AM, Madern GC, Cleyndert P, Blomjous JGAM. Inguinal hernias containing the uterus, fallopian tubes and ovary in premature female infants. *J Pediatr* 1999;136:696–7.
- [5] Deinkuyu BE, Affrancheh MR, Sonmez D, Kologlu MB, Fitoz S. Canal of Nuck in a female infant containing uterus, bilateral adnexa and bowel. *Balkan Med J* 2016;33:566–8.
- [6] Shadbolt CL, Heinze SB, Dietrich RB. Imaging of groin masses: inguinal anatomy and pathologic conditions revisited. *Radiographics* 2001;21:261–71.
- [7] Hamidi H, Rahimi M. Infantile presentation of the canal of Nuck hernia containing uterus and ovary: a case report. *Radiology Case Reports* 2020;15(12):2557–9.
- [8] Choi KH, Baek HJ. Incarcerated ovarian herniation of the canal of Nuck in a female infant: ultrasonographic findings and review of literature. *Ann Med Surg* 2016;9:38–40.
- [9] Yang D, Kim H, Kim S, Lim S, Park S, Lim J. Ultrasonographic diagnosis of ovary-containing hernias of the canal of Nuck. *Ultrasonography* 2014;33(3):178–83.