



Since January 2020 Elsevier has created a COVID-19 resource centre with free information in English and Mandarin on the novel coronavirus COVID-19. The COVID-19 resource centre is hosted on Elsevier Connect, the company's public news and information website.

Elsevier hereby grants permission to make all its COVID-19-related research that is available on the COVID-19 resource centre - including this research content - immediately available in PubMed Central and other publicly funded repositories, such as the WHO COVID database with rights for unrestricted research re-use and analyses in any form or by any means with acknowledgement of the original source. These permissions are granted for free by Elsevier for as long as the COVID-19 resource centre remains active.

Lipschutz Ulcers in an Adolescent After Sars-CoV-2 Infection

Tonya M. Schmitt, DNP, CPNP, APRN,
Jennifer Devries, DNP, APRN, FNP-C, &
Mary Jean Ohns, DNP, APRN, CPNP-AC/PC, CCRN

This case report describes a 15-year-old female who presented with acute onset of painful genital ulcers. She denied being sexually active and tested positive for severe acute respiratory coronavirus 2 five days prior. Associated symptoms on days 1 to 3 included fatigue, nausea, headaches, and fever. Lipschutz ulcers (LUs), also known as aphthous ulcers, acute genital ulcers, and acquired genital ulcerations; are an uncommon, self-limiting, nonsexually transmitted condition characterized by the rapid onset of painful, necrotic ulcerations of the vulva or lower vagina. The pathogenesis of LUs is unclear, and the diagnosis is one of exclusion. *J Pediatr Health Care.* (2022) XX, 1–4

Tonya M. Schmitt, Assistant Professor and Pediatric Nurse Practitioner, Department of Adult, Family, and Population Health Nursing, College of Nursing, the University of Toledo, Toledo, OH.

Jennifer Devries, Assistant Professor and Pediatric Nurse Practitioner, Department of Adult, Family, and Population Health Nursing, College of Nursing, the University of Toledo, Toledo, OH.

Mary Jean Ohns, Pediatric Nurse Practitioner, Emergency Department, Russel J. Ebeid Children's Hospital, and Associate Professor, College of Nursing, the University of Toledo, Toledo, OH.

Conflicts of interest: None to report.

Correspondence: Tonya M. Schmitt, DNP, APRN, CPNP, Department of Adult, Family, and Population Health Nursing, College of Nursing, the University of Toledo, Collier Bldg., Mail Stop 1026, 3000 Arlington Ave., Toledo, Ohio 43614-2598;; e-mail: tonya.schmitt@utoledo.edu.
J Pediatr Health Care. (2022) 00, 1–4

0891-5245/\$36.00

Copyright © 2022 by the National Association of Pediatric Nurse Practitioners. Published by Elsevier Inc. All rights reserved.

<https://doi.org/10.1016/j.pedhc.2022.09.005>

KEY WORDS

Lipschutz ulcers, Sars-CoV-2, acute genital ulcers, complex aphthous ulcers, adolescent females

CHIEF COMPLAINT AND HISTORY OF PRESENT ILLNESS

A 15-year-old Caucasian female presented to her pediatric primary care office accompanied by her mother with a chief complaint of painful vaginal sores and a headache. The symptoms began 2 days prior with vaginal itching and burning with urination. Her pain score was 5/10 at baseline and 8/10 with urination. She noted a small amount of thin white vaginal discharge. Self-examination revealed several small ulcer-like lesions on the vulva. Five days before the onset of genital ulcers, the patient was diagnosed with severe acute respiratory coronavirus 2 (SARS-CoV-2) via polymerase chain reaction. Symptoms of fatigue, nausea, headaches, and fever of 38.3°C were experienced on days 1–3 of her SARS-CoV-2 infection with persistent headache.

MEDICAL HISTORY

The patient was a healthy and developmentally appropriate 15-year-old female with no significant past medical history. She had no chronic medical conditions and no previous hospitalizations or surgeries. She had no known allergies and did not take any prescription, over-the-counter, or herbal medications. She identified as a heterosexual female and denied current or past sexual activity, sexual abuse, and sexually transmitted infections. Her last menstrual cycle was 3 weeks ago, and she described it as “normal.” She received all recommended immunizations except human papillomavirus, influenza, and SARS-CoV-2. Her psychosocial history was positive for anxiety, and school avoidance was diagnosed 6 months prior. She had recently been reluctant to attend school and attempted to come home several times a week because of anxiety related to contracting COVID-19.

SOCIAL AND DEVELOPMENTAL HISTORY

The patient lived with her mother, father, and three older siblings. She was a sophomore in high school with a 3.8/4.0-grade point average and planned to attend college.

REVIEW OR SYSTEMS

Constitutional symptoms included an alert, developmentally appropriate 15-year-old female who was tearful and anxious. She reported vaginal sores, headaches, and fatigue. She denied urinary frequency, urgency, abdominal or flank pain, and vaginal odor. She stated she was tearful and anxious because of physical and emotional distress caused by the genital ulcers.

PHYSICAL EXAMINATION

Vital signs were appropriate for her age, with no fever and a body mass index of 24.3. Her skin was without rashes, and there were no lesions on her hands or feet. She had clear postnasal drainage with hypertrophic bilateral erythematous nasal turbinates. Her lung sounds were clear to auscultation bilaterally. No cervical or inguinal lymphadenopathy was appreciated. Her heart rate was regular, normal S1 and S2, with no murmurs. Her abdomen was soft and nontender, with active bowel sounds in all quadrants without hepatosplenomegaly or costal vertebral tenderness. She was Tanner Stage V with five painful erosive ulcer-like lesions on the labia minora with a scant amount of thin white vaginal discharge. The lesions ranged from 1.5 to 2.5 mm, and the affected labia were swollen and tender to the touch.

DIFFERENTIAL DIAGNOSES

Differential diagnoses for genital ulcers include sexually transmitted infections (herpes simplex virus [HSV], HIV infection, syphilis) and noninfectious diseases that cause genital ulcerations (Behcet's syndrome, Crohn's disease, complex aphthosis, pyoderma gangrenosum, and childhood vulval pemphigoid; [Moise et al., 2018](#)). Numerous case reports have described genital ulcers following infections, including cytomegalovirus, influenza, mumps virus, salmonella, mycoplasma, and Epstein-Barr virus ([Wojcicki & O'Brien, 2022](#)). Because she was not sexually active and was recently diagnosed with SARS-CoV-2 having symptoms of fatigue, nausea, headaches, and fever, a viral etiology was presumed. [Rosman, Berk, Bayliss, White, and Merritt \(2012\)](#) developed an algorithm for evaluating and treating acute genital ulcers following the exclusion of HSV ([Figure 1](#)).

DIAGNOSTIC STUDIES

Initial testing included a complete blood count with differential and HSV polymerase chain reaction. Shared decision-making was used with the patient and her mother to determine additional testing. They agreed to Epstein-Barr virus titers, cytomegalovirus titers, and a polymerase chain reaction test for influenza A and B. She also agreed to additional testing and a referral to gynecology or dermatology if the ulcers did not significantly improve in 2 weeks or if the ulcers reoccurred.

LIPSCHUTZ ULCERS

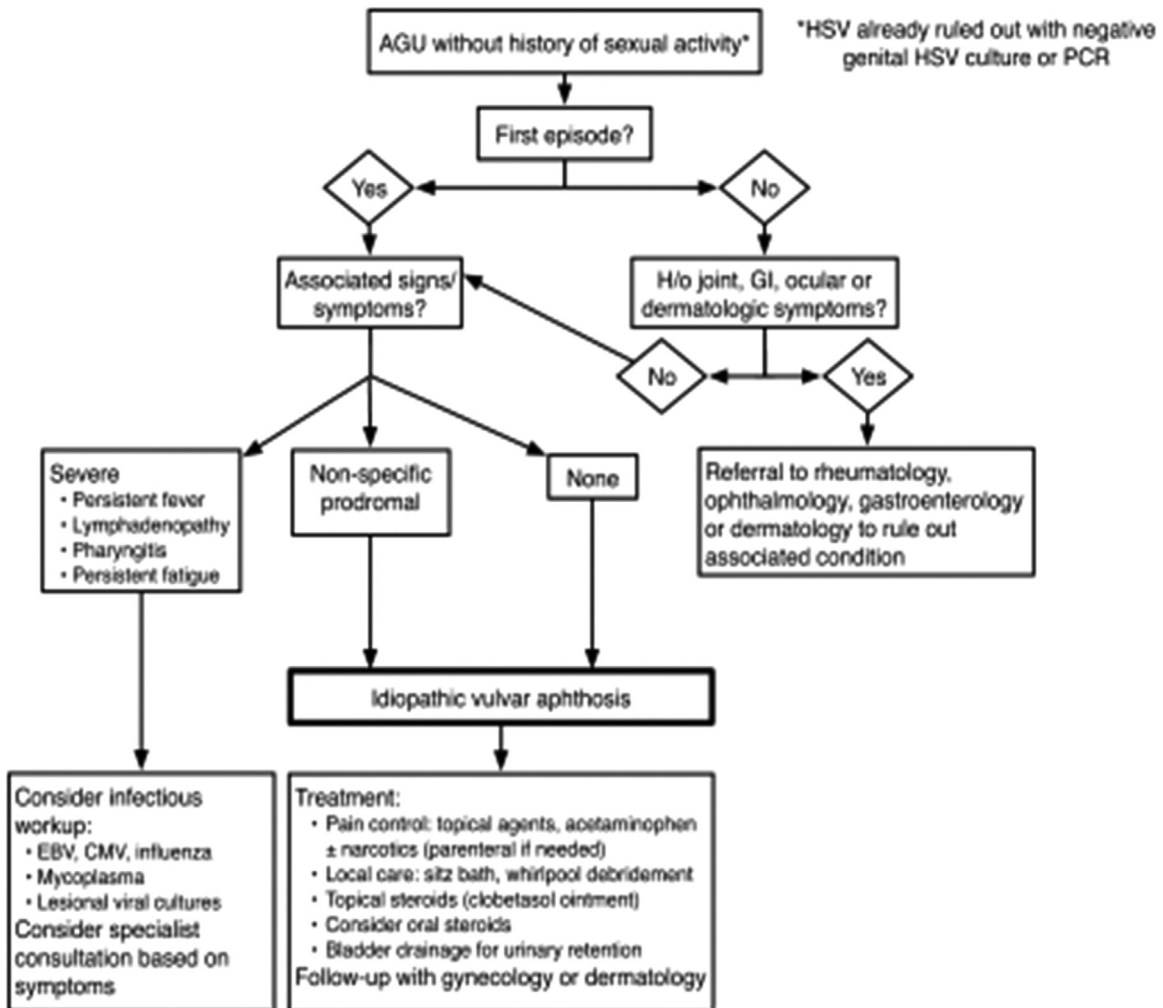
Lipschutz ulcers (LUs), also known as aphthous ulcers, acute genital ulcers, and acquired genital ulcerations, are rare, painful vulvar and vaginal ulcers that occur in nonsexually active adolescent females ([Polito & Morley, 2022](#)). First identified in 1913 by Australian dermatologist Benjamin Lipschutz, this uncommon condition is described by the sudden onset of vulvar ulcers in nonsexually active females with systemic signs of infection ([Christl et al., 2021](#)). These ulcers typically present with a prodromal phase of viral symptoms, including fever, fatigue, and malaise, followed by 0.1 to 2.5 cm single or multiple vulvar ulcerations ([Pereira, Teixeira, Lopes, Sarmiento, & Lopes, 2021](#)). The pathogenesis of LU is thought to be a hypersensitivity immune response to a viral or bacterial illness that results in the formation of immune complexes in the dermal vessels causing microthrombi that eventually lead to painful necrotizing ulcers ([Moise et al., 2018](#)). LUs are a self-limiting condition, with spontaneous healing typically in 2–6 weeks. Treatment is focused on supportive care, including managing pain, mitigating secondary infection, and providing patient reassurance and anticipatory guidance ([Wojcicki & O'Brien, 2022](#); [Wyles, Lehman, Lohse, Bruce, & Torgerson, 2017](#)). Evidence suggests that LUs may be a precursor to certain autoimmune conditions ([Polito & Morley, 2022](#)). Regularly scheduled health supervision visits are encouraged to optimize early diagnosis and treatment of new disease processes. Acute genital ulcers have been reported following Epstein-Barr virus, cytomegalovirus, influenza A and B, adenovirus, Mycoplasma pneumonia, and now SARS-CoV-2 infection and vaccination ([Hsu, Sink, Alaniz, Zheng, & Mancini, 2022](#); [Wojcicki & O'Brien, 2022](#)). The most common cause of genital ulcers in young, sexually active females is either genital herpes or syphilis. LUs are a diagnosis of exclusion, so it is important to rule out other causes of genital ulcers before making the diagnosis. Conversely, it is important to consider the diagnosis of LUs in sexually inactive females to avoid misdiagnosis and emotional distress.

GENITAL ULCERS IN SEXUALLY TRANSMITTED INFECTIONS

Genital herpes, caused by HSV, is a common sexually transmitted infection that is more common in women than men. Herpes lesions typically appear as one or more vesicles on or around the genitals or rectum. The average incubation period for initial herpes infection is 4 days (ranging from 2 to 12) after exposure. The vesicles open, leaving painful ulcers that take 2–4 weeks to heal. Systemic symptoms of an initial herpes outbreak can include fever, body aches, swollen lymph nodes, and headache ([Centers for Disease Control and Prevention \[CDC\], 2021](#)). Syphilis is a sexually transmitted infection that develops in stages (primary, secondary, latent, and tertiary), and each stage has different symptoms. During the primary stage of syphilis, single or multiple lesions develop where syphilis enters the body; in women, this is usually around the vagina or rectum. These

FIGURE 1. Algorithm for Evaluation and Management of AGU in nonsexually active young girls.

AGU, ACUTE GENITAL ULCERS; HSV, HERPES SIMPLEX VIRUS; PCR, POLYMERASE CHAIN REACTION; GI, GASTROINTESTINAL; EBV, EPSTEIN-BARR VIRUS; CMV, CYTOMEGALOVIRUS. SOURCE: ROSMAN ET AL., 2012.



sores are normally firm, round, and painless, lasting 3–6 weeks regardless of treatment (CDC, 2022).

EVIDENCE-BASED MANAGEMENT

The mother and patient were advised that LUs is a clinical diagnosis of exclusion, and other causes must be ruled out before a definitive diagnosis can be made (Moise et al., 2018). Comfort measures were discussed, including alternating acetaminophen and ibuprofen. Additional self-care included the application of cold compresses to the affected genital areas. The patient was instructed to remain well hydrated and to avoid urine retention because of dysuria. She was advised to sit in a shallow bath and urinate at the end if she was reluctant to void because of discomfort. Further comfort care included avoiding perfumed soaps and lotions and wearing restrictive clothing. The patient was reassured that LUs are self-limiting and the treatment is supportive care.

FOLLOW-UP

The patient was discharged home and informed that they would be contacted with the test results. Follow-up phone calls were made to the family in 1 week to inform them that all test results were negative and in 2 weeks to check on the patient's symptoms. At that time, the patient was symptom-free, and the vaginal lesions had resolved.

CASE SUMMARY

SARS-CoV-2 infections have been associated with numerous local and systemic reactions. To date, case reports have highlighted the development of LUs following SARS-CoV-2 vaccination and infection (Christl et al., 2021; Hsu et al., 2022; Wojcicki & O'Brien, 2022). This case report described the development of LUs in an unvaccinated female with a recent SARS-CoV-2 infection. Adding LUs to the list of differential diagnoses in nonsexually active females with genital

ulcers will aid in not missing this uncommon diagnosis. Further research is needed to determine the causal relationship between the development of LU in adolescent females vaccinated against SARS-CoV-2 and those with a recent SARS-CoV-2 infection.

REFERENCES

- Centers for Disease Control and Prevention. (2021). Genital herpes – CDC detailed fact sheet. Retrieved from <https://www.cdc.gov/std/herpes/stdfact-herpes-detailed.htm>
- Centers for Disease Control and Prevention. (2022). Syphilis – CDC detailed fact sheet. Retrieved from <https://www.cdc.gov/std/syphilis/stdfact-syphilis-detailed.htm>
- Christl, J., Alaniz, V., Appiah, L., Buyers, E., Scott, S., & Huguelet, P. (2021). Vulvar aphthous ulcer in an adolescent with COVID-19. *Journal of Pediatric and Adolescent Gynecology*, *34*, 418–420.
- Hsu, T., Sink, J. R., Alaniz, V. I., Zheng, L., & Mancini, A. J. (2022). Acute genital ulceration after severe acute respiratory syndrome coronavirus 2 vaccination and infection. *The Journal of Pediatrics*, *246*, 271–273.
- Moise, A., Nervo, P., Doyen, J., Kridelka, F., Maquet, J., & Vandenbossche, G. (2018). Ulcer of Lipschutz, a rare and unknown cause of genital ulceration. *Facts, Views & Vision in ObGyn*, *10*, 55–57.
- Pereira, D. A. G., Teixeira, E. P. P., Lopes, A. C. M., Sarmiento, R. J. P., & Lopes, A. P. C. (2021). Lipschutz ulcer: An unusual diagnosis that should not be neglected. *Revista Brasileira de Ginecologia e Obstetria*, *43*, 414–416.
- Polito, A., & Morley, C. (2022). Lipschutz ulcers: A rare, but important diagnosis in young females presenting with acute genital ulcerations. *Pediatrics*, *149*, 602.
- Rosman, I., Berk, D., Bayliss, S., White, A., & Merritt, D. (2012). Acute genital ulcers in nonsexually active young girls: Case series, review of the literature, and evaluation and management recommendations. *Pediatric Dermatology*, *29*, 147–153.
- Wojcicki, A. V., & O'Brien, K. L. F. (2022). Vulvar aphthous ulcer in an adolescent after Pfizer-BioNTech (BNT162b2) COVID-19 vaccination. *Journal of Pediatric and Adolescent Gynecology*, *35*, 167–170.
- Wyles, S. P., Lehman, J. S., Lohse, C. M., Bruce, A. J., & Torgerson, R. R. (2017). Recurrence of genital aphthosis in girls: A retrospective analysis. *Journal of the American Academy of Dermatology*, *77*, 982–984.