

Use of a stop-flow programmable shunt valve to maximize CNS chemotherapy delivery in a pediatric patient with acute lymphoblastic leukemia

Sheri K. Palejwala, David A. Stidd, Jesse M. Skoch, Puja Gupta¹, G. Michael Lemole Jr, Martin E. Weinand

Department of Surgery, Division of Neurosurgery, University of Arizona, 1501 N. Campbell Ave., Tucson, Arizona, ¹Department of Pediatrics, Division of Pediatric Oncology, University of Cincinnati, 3333 Burnet Avenue, Cincinnati, Ohio, USA

E-mail: *Sheri K. Palejwala - spalejwala@email.arizona.edu; David A. Stidd - dstidd@email.arizona.edu; Jesse M. Skoch - jskoch@email.arizona.edu; Puja Gupta - Puja.gupta@cchmc.org; G. Michael Lemole Jr - mlemole@surgery.arizona.edu; Martin E. Weinand - mweinand@surgery.arizona.edu
*Corresponding author

Received: 17 February 14 Accepted: 25 June 14 Published: 21 August 14

This article may be cited as:

Palejwala SK, Stidd DA, Skoch JM, Gupta P, Lemole GM, Weinand ME. Use of a stop-flow programmable shunt valve to maximize CNS chemotherapy delivery in a pediatric patient with acute lymphoblastic leukemia. *Surg Neurol Int* 2014;5:S273-7.

Available FREE in open access from: <http://www.surgicalneurologyint.com/text.asp?2014/5/5/273/139381>

Copyright: © 2014 Palejwala KS. This is an open-access article distributed under the terms of the Creative Commons Attribution License, which permits unrestricted use, distribution, and reproduction in any medium, provided the original author and source are credited.

Abstract

Background: The requirement for frequent intraventricular drug delivery in the setting of shunt dependence is particularly challenging in the treatment of central nervous system infection, neoplastic disease, and hemorrhage. This is especially relevant in the pediatric population where both hematogenous malignancy requiring intrathecal drug delivery and shunt-dependent hydrocephalus are more prevalent. Intrathecal and intraventricular chemotherapy agents can be prematurely diverted in these shunt-dependent patients.

Case Description: We report the use of a stop-flow programmable shunt valve to maximize delivery of intraventricular chemotherapy in a child with acute lymphoblastic leukemia and disseminated intravascular coagulation who presented with spontaneous intracerebral and intraventricular hemorrhages. The patient then developed posthemorrhagic hydrocephalus and eventually progressed to shunt dependence but still required frequent intraventricular chemotherapy administration. A ventriculoperitoneal shunt, equipped with a valve that allows for near cessation of cerebrospinal fluid flow (Certas[®], Codman, Raynham, MA), and a contralateral Ommaya reservoir were inserted to maximize intraventricular dissemination of chemotherapy.

Conclusions: To the best of our knowledge, this is the first reported case of the use of a high-resistance programmable valve being used to virtually cease cerebrospinal fluid flow through the distal catheter temporarily in order to maximize intraventricular drug dissemination in a pediatric patient with acute lymphoblastic leukemia.

Key Words: Chemotherapy, hydrocephalus, intracerebral hemorrhage, pediatric neurosurgery, ventriculoperitoneal shunt

Access this article
online

Website:

www.surgicalneurologyint.com

DOI:

10.4103/2152-7806.139381

Quick Response Code:



INTRODUCTION

Acute lymphoblastic leukemia (ALL) is the most common neoplastic disease of childhood, comprising 25% of all childhood malignancies in those aged ≤ 15 years.^[12] The central nervous system (CNS) can serve as a reservoir for disease in ALL and this necessitates CNS directed treatment in the form of neuraxis radiation and/or intrathecal chemotherapy performed either via serial lumbar punctures or through an intraventricular catheter connected to a subcutaneous drug delivery reservoir.^[12] The use of Ommaya reservoirs has become a common practice in the treatment of leukemias and lymphomas that involve the CNS and is believed to be more efficacious and less toxic than serial lumbar delivery.^[1,2]

ALL is also associated with disseminated intravascular coagulopathy (DIC), which occurs in 3.1% of ALL cases and very rarely manifests as spontaneous intracerebral hemorrhage.^[6-8,15,16] Here we describe a rare case of a pediatric patient with disseminated T-cell ALL and DIC presenting with large spontaneous intraparenchymal and intraventricular hemorrhages (IVHs). The patient then developed posthemorrhagic hydrocephalus requiring cerebrospinal fluid (CSF) diversion. An Ommaya drug delivery reservoir was ultimately implanted for intraventricular chemotherapy in addition to a contralateral ventriculoperitoneal (VP) shunt using a programmable valve capable of high resistance, effectively turning the valve off to allow intraventricular CSF dissemination of the chemotherapeutic agents.

CASE REPORT

The patient is a 3-year-old male who initially presented to his pediatrician's office with several weeks history of intermittent epistaxis. The subsequent work-up showed an initial white blood cell count of 515,000 and eventually led to a diagnosis of hematologic malignancy. Flow cytometric immunophenotyping confirmed T-cell ALL, marked by cell surface expression of CD3, CD4, CD8, and TdT. Subsequent bone marrow biopsy confirmed this diagnosis and revealed $>95\%$ blasts. The patient was neurologically intact until day 3 of admission, when he became progressively confused and somnolent. A noncontrast head computed tomography (CT) was performed revealing extensive bifrontal and left temporal intraparenchymal hemorrhages [Figure 1]. Upon initial neurosurgical evaluation, the patient had a Glasgow coma score (GCS) of 9, opening his eyes and moaning in response to noxious stimuli, though moving all of his extremities purposefully. No clinical or historical evidence of trauma was detected, and laboratory studies revealed an International Normalized Ratio (INR) of 3.5 and platelet count of 66,000. The hemorrhages were presumed to be spontaneous and the diagnosis of DIC

was made. The patient was given fresh frozen plasma and platelets to keep the patient's INR ≤ 1.3 and platelet count $\geq 100,000$, respectively.

Although repeat imaging indicated radiographic stability of the intraparenchymal hemorrhages, the patient's exam continued to decline over the subsequent 24 h and a right frontal external ventricular drain (EVD) was placed. Routine CSF studies then showed >5 leukocytes and cytopsin indicative of blasts in the CSF. The standard of care in T-cell ALL with CNS involvement at presentation is intrathecal methotrexate and 18 Gy of craniospinal radiation.^[14] Although traditionally reserved for refractory disease, hydrocortisone and cytarabine were added to the intraventricular methotrexate, due to the patient's extensive disease at presentation. All three of these chemotherapeutic agents were delivered weekly via the EVD. The patient's intracranial pressures were adequately controlled with approximately 50-100 ml of CSF output daily from the EVD (pop-off setting at 20 mmHg). However, within a few days of intraventricular chemotherapy administration, the patient's daily CSF output increased, ranging from 200 to 400 ml, while intracranial pressures remained relatively unchanged, indicating a possible mechanism of decreased CSF reabsorption.

After 21 days of elevated CSF output via external ventricular drainage, the patient was felt to be shunt-dependent, this was confirmed with radiographic evidence of ventriculomegaly and the decision was made to place a right-sided VP shunt. The patient's oncologist expressed the need for weekly chemotherapy delivered to the CSF space for at least 2 months and then every 1-2 months for the next three-and-a-half years, and a contralateral Ommaya reservoir was also placed.

The patient was taken to the operating room where the right-sided EVD was removed and a new antibiotic-impregnated ventricular catheter was placed.

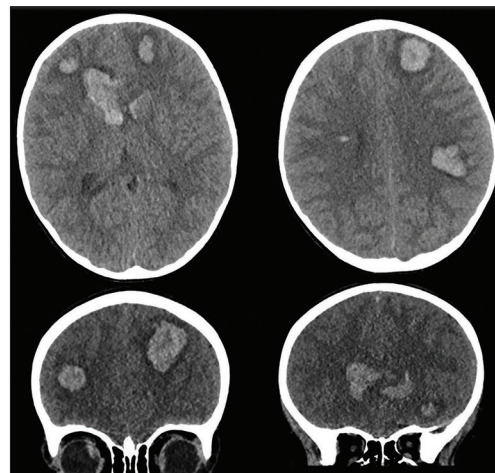


Figure 1: Axial and coronal noncontrast head CT showing extensive intracranial hemorrhage on initial presentation

This was connected to a pediatric Codman Certas valve (DePuy Codman, Raynham, MA), which was set to 3 (approximately 8 mmHg).^[5] The distal catheter was placed in the peritoneal cavity. A contralateral Ommaya reservoir was then placed into the frontal horn of the left lateral ventricle. Postoperative head CT and plain head, thorax, and abdominal radiographs were obtained to confirm adequate placement of both the ventricular catheters and distal shunt tubing [Figure 2].

Weekly intraventricular methotrexate, cytarabine, and hydrocortisone were then administered via the Ommaya reservoir. Simultaneously, the valve was readjusted to approximately 29 mmHg (Certas setting 8) for 4 h, to allow dissemination of the chemotherapeutic agents throughout the CSF.^[5,12] Since the patient's highest ICP reading was 26 mmHg we were assured that the Certas 8 setting would virtually cease CSF flow through the shunt valve. Intraventricular chemotherapy administration and valve reprogramming were performed by the pediatric oncologist in the outpatient setting with on-site neurosurgery readily available. During the 4 h of "off time" the patient was allowed to rest or play quietly in the clinic. He was observed by the clinic staff and tolerated the clamping well without any overt signs of hydrocephalus such as somnolence or headache. The patient was also receiving concurrent systemic chemotherapy and has received whole brain and spinal radiation.^[14]

RESULTS

This is a relatively novel technique using a programmable ventricular shunt and contralateral Ommaya reservoir in a patient who is both shunt dependent and requires frequent intraventricular chemotherapy, never before described in a pediatric

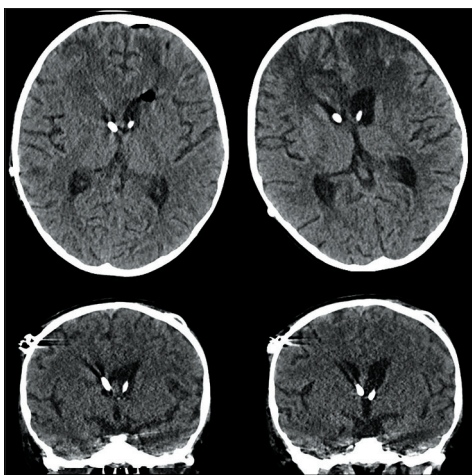


Figure 2: Axial and coronal postoperative noncontrast head CT with right-sided intraventricular shunt catheter and left-sided Ommaya reservoir catheter

population. The goal of this procedure was to provide a convenient method for intraventricular drug delivery and to allow adequate time for drug dissemination by effectively turning off or clamping the ventricular shunt, a feature unique to the Codman Certas valve. The alternative, in this case, would have been weekly lumbar punctures for drug delivery, which would have been suboptimal in a 3-year-old child with a high propensity for hemorrhage.^[1,2] Alternatively, a nonprogrammable valve or one that cannot be nearly completely turned off would neither allow sufficient time for intraventricular drug dissemination nor decrease the peritoneal dose of chemotherapeutic agents.

At the time of this publication, the patient is 12-months after surgery and recently relapsed in the testicle, CNS, and bone marrow. Prior to relapse, he was receiving monthly doses of intraventricular chemotherapy via his drug delivery reservoir and the shunt valve is still being manipulated to improve intraventricular drug delivery. In the interim he has been admitted multiple times for complications and side effects related to chemotherapeutic agents, but has not had any complications related to his VP shunt or drug delivery reservoir to date.

DISCUSSION

ALL is the most common malignancy of childhood, accounting for nearly 25% of all pediatric cancers in those aged less than 15 years.^[12] All cases of ALL require aggressive systemic and CSF therapy to prevent CNS relapse and improve remission and overall outcomes.^[12,13] Intrathecal therapy with methotrexate has become the standard of care in ALL, with patients requiring frequent lumbar punctures or intraventricular drug delivery via a subgaleal reservoir. However, this is more challenging in patients with elevated intracranial pressure and resultant hydrocephalus requiring CSF diversion, as chemotherapeutic agents are being actively removed from the CNS. Several different approaches have been taken to allow for simultaneous intrathecal or intraventricular drug delivery and CSF shunting including the use of inline on/off valves, as well as both ipsilateral and contralateral programmable valves to an Ommaya reservoir.^[4,10,18]

Although coagulopathy in the setting of ALL is rare, T-cell leukemia and CNS involvement were found to be independently associated with coagulation disorders.^[9,12,16] Intracerebral hemorrhage (ICH) in the setting of acute leukemia generally occurs in one of two ways: Leukostasis or coagulopathy.^[6] Leukostasis, the plugging of small cerebral vessels with blast cells, occurs in the minority of cases of intracranial hemorrhage, while hemorrhage secondary to coagulopathy was found in 72.5% of patients with acute leukemia.^[6,7,15] Hemorrhage in this group is more likely to be multifactorial, due to the

high concomitance of neutropenia, leukopenia, and, most profoundly, thrombocytopenia.^[7] Regardless of the mechanism, coagulopathy and hemorrhage has been associated with a poorer prognosis in the setting of leukemia.^[16]

ICH and particularly IVH, regardless of the etiology, often leads to increased intracerebral pressure. The majority of patients are adequately temporized with an EVD, as they likely have a self-limited acute hydrocephalus (40-50%).^[17] Patients with IVH are 24 times more likely to develop acute hydrocephalus; this is hypothesized to occur via blockage of the arachnoid villi, therefore obstructing the reabsorption of CSF.^[11,17] Chronic hydrocephalus, in turn, might occur due to decreased ventricular compliance or permanent scarring of arachnoid villi.^[17] Although the exact pathophysiology still remains unclear, studies have shown that approximately 20-40% of patients who require EVD placement go on to develop dependence necessitating ventricular shunt placement.^[3,17]

Shunt-dependent chronic hydrocephalus then presents a problem in patients who require intraventricular drug delivery, as these medications can be quickly siphoned out of the ventricular device and into the distal cavity. The Codman Certas valve is a newer programmable valve that can be adjusted to a setting of >29 mmHg, the highest setting for a commercially available valve in the US, which permits virtually no flow under normal physiologic conditions. This allows for intraventricular drug delivery, via an appropriate reservoir so as to avoid repeated invasive manipulation of the valve and its associated reservoir, and significantly decreasing flow so as to allow the drug to circulate via the CSF throughout the neuraxis.

To the best of our knowledge, this is the first report of the use of a flow-limiting programmable ventricular shunt valve in a pediatric patient who is both shunt-dependent, and requires drug delivery via the CSF. Although this particular case was performed for a patient with leukemia and intracerebral hemorrhage, it can be applied to a variety of other situations where both shunting and intraventricular drug delivery are required, such as meningitis causing chronic obstructive hydrocephalus requiring intraventricular antibiotics or antifungals.^[4,10,18]

A similar paradigm has been described previously in an adult with hydrocephalus secondary to leptomenigeal disease. Radiographic tracer was injected into a contralateral Ommaya reservoir to elucidate the intraventricular concentration of chemotherapeutic agents with a valve setting of 80 mm H₂O (5.9 mmHg) and 200 mm H₂O (14.7 mmHg).^[18] However, our case highlights the benefits of this in the pediatric setting where hematologic disease requiring intraventricular drug delivery is more prevalent, as is shunt-dependent hydrocephalus. Also, the newer valve allows for pressures

that double those achieved by Zada *et al.* theoretically decreasing the time required for shunt “off” time and CNS dissemination, making frequent outpatient intraventricular drug delivery safer and more efficient.

Another multicenter retrospective review of 24 patients with neoplastic meningitis and subsequent hydrocephalus requiring concomitant CSF diversion and intraventricular chemotherapy evaluated the use of an on/off VP shunt valve placed in series with a programmable shunt valve and a subcutaneous (Ommaya) reservoir.^[10] Although this is certainly feasible, frequent chemotherapy injections increases the risk of shunt failure, due to infection or malfunction, and this in turn increases the likelihood of potential revisions, and, of course, if one system were to fail, all would require replacement. Using a Certas programmable valve, however, negates the need to add an on/off valve in series, thus decreasing the number of devices in line and in turn decreasing the compounded risk of shunt failure and need for operative revision. Placing the Ommaya reservoir contralateral to the shunt also potentially decreases the risk of damage to the shunt and valve keeping in mind that chemotherapy is delivered as an outpatient by an oncologist.

One of the biggest drawbacks of this study is the lack of CSF drug concentrations obtained from the patient. Ideally we would have measured the concentration of chemotherapeutic agents in the intraventricular and/or intrathecal space at various time points to elucidate the ideal “off time.” This information could have also been gleaned through the use of a radiographic tracer delivered with the chemotherapeutic agents that could allow us to better evaluate the CSF dynamics during the “off” period. Furthermore, imaging such as CT scan during the “off” period could have also, better, informed us that the patient was not experiencing any undue increased intracranial pressure due to the lack of CSF diversion. From a practical standpoint, this was deemed unnecessary in a young child with a known propensity toward coagulopathy who tolerated 4 h of shunt clamping without any overt signs of hydrocephalus such as headache.

CONCLUSIONS

This is a case report of the use of a VP shunt using a stop-flow programmable Certas shunt valve and a contralateral Ommaya reservoir in conjunction in a pediatric patient who is both shunt-dependent and requires intraventricular chemotherapy. Although the need for shunting in this particular case arose from spontaneous intraparenchymal and IVH in the setting of DIC, the use of a stop-flow programmable valve can be safely applied with an Ommaya reservoir to any situation requiring both CSF diversion and frequent intraventricular drug delivery.

REFERENCES

1. Bleyer WA, Poplack DG. Intraventricular versus intralumbar methotrexate for central-nervous-system leukemia: Prolonged remission with the Ommaya reservoir. *Med Pediatr Oncol* 1979;6:207-13.
2. Bleyer WA, Poplack DG, Simon RM. "Concentration x time" methotrexate via a subcutaneous reservoir: A less toxic regimen for intraventricular chemotherapy of central nervous system neoplasms. *Blood* 1978;51:835-42.
3. Chan KH, Mann KS. Prolonged therapeutic external ventricular drainage: A prospective study. *Neurosurgery* 1988;23:436-8.
4. Czech T, Reinprecht A, Dietrich W, Hainfellner JA, Slavc I. Reversible occlusion shunt for intraventricular chemotherapy in shunt-dependent brain tumor patients. *Pediatr Hematol Oncol* 1997;14:375-80.
5. Eklund A, Koskinen LO, Williams MA, Luciano MG, Dombrowski SM, Malm J. Hydrodynamics of the Certas programmable valve for the treatment of hydrocephalus. *Fluids Barriers CNS* 2012;9:12.
6. Fritz RD, Forkner CE Jr., Freireich EJ, Frei E 3rd, Thomas LB. The association of fatal intracranial hemorrhage and blastic crisis in patients with acute leukemia. *N Engl J Med* 1959;261:59-64.
7. Graus F, Rogers LR, Posner JB. Cerebrovascular complications in patients with cancer. *Medicine (Baltimore)* 1985;64:16-35.
8. Higuchi T, Toyama D, Hirota Y, Isoyama K, Mori H, Niikura H, et al. Disseminated intravascular coagulation complicating acute lymphoblastic leukemia: A study of childhood and adult cases. *Leuk Lymphoma* 2005;46:1169-76.
9. Lin CL, Loh JK, Kwan AL, Howng SL. Spontaneous intracerebral hemorrhage in children. *Kaohsiung J Med Sci* 1999;15:146-51.
10. Lin N, Dunn IF, Glantz M, Allison DL, Jensen R, Johnson MD, et al. Benefit of ventriculoperitoneal cerebrospinal fluid shunting and intrathecal chemotherapy in neoplastic meningitis: A retrospective, case-controlled study. *J Neurosurg* 2011;115:730-6.
11. Nishikawa T, Ueba T, Kajiwara M, Miyamatsu N, Yamashita K. A priority treatment of the intraventricular hemorrhage (IVH) should be performed in the patients suffering intracerebral hemorrhage with large IVH. *Clin Neurol Neurosurg* 2009;111:450-3.
12. Pui CH. Recent research advances in childhood acute lymphoblastic leukemia. *J Formos Med Assoc* 2010;109:777-87.
13. Pui CH, Howard SC. Current management and challenges of malignant disease in the CNS in paediatric leukaemia. *Lancet Oncol* 2008;9:257-68.
14. Pui CH, Thiel E. Central nervous system disease in hematologic malignancies: Historical perspective and practical applications. *Semin Oncol* 2009;36 (4 Suppl 2):S2-16.
15. Quinones-Hinojosa A, Gulati M, Singh V, Lawton MT. Spontaneous intracerebral hemorrhage due to coagulation disorders. *Neurosurg Focus* 2003;15:E3.
16. Ribeiro RC, Pui CH. The clinical and biological correlates of coagulopathy in children with acute leukemia. *J Clin Oncol* 1986;4:1212-8.
17. Zacharia BE, Vaughan KA, Hickman ZL, Bruce SS, Carpenter AM, Petersen NH, et al. Predictors of long-term shunt-dependent hydrocephalus in patients with intracerebral hemorrhage requiring emergency cerebrospinal fluid diversion. *Neurosurg Focus* 2012;32:E5.
18. Zada G, Chen TC. A novel method for administering intrathecal chemotherapy in patients with leptomeningeal metastases and shunted hydrocephalus: Case report. *Neurosurgery* 2010;67 (3 Suppl Operative):onsE306-307; discussion onsE307.