

Received: 2019.09.07
Accepted: 2019.11.20
Published: 2020.01.25

Spontaneous Rupture of a Huge Splenic Artery Aneurysm: A Case Report

Authors' Contribution:
Study Design A
Data Collection B
Statistical Analysis C
Data Interpretation D
Manuscript Preparation E
Literature Search F
Funds Collection G

ABDE 1 **Nikolaos Pararas**
BCDEF 1 **Saravanan Rajendiran**
DEF 1 **Imad Taha**
BF 1 **Rahul Ramachandra Powar**
CDF 2 **Carlos Holguiera**
DEF 1 **Ezzat Tadros**

1 Department of Surgery, Dr. Sulaiman Al Habib Hospitals, Riyadh, Saudi Arabia
2 Department of Radiology, Dr. Sulaiman Al Habib Hospitals, Riyadh, Saudi Arabia

Corresponding Author: Nikolaos Pararas, e-mail: npararas@gmail.com
Conflict of interest: None declared

Patient: Male, 32-year-old
Final Diagnosis: Splenic artery aneurysm
Symptoms: Acute abdominal pain
Medication: —
Clinical Procedure: Distal pancreatectomy and splenectomy
Specialty: Surgery

Objective: Unknown etiology

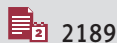
Background: Splenic artery aneurysm is uncommon in a healthy young male patient. With spontaneous rupture, it can quickly become life-threatening. Our aim is to highlight the possibility of splenic artery aneurysm among healthy young patients and its presentation as recurrent abdominal pain, while pending rupture is possible, which can present a diagnostic challenge. The rare occurrence and spontaneous rupture of a splenic artery aneurysm are often fatal outside an inpatient setting.

Case Report: Here, we present the case of a 32-year-old patient who visited the Emergency Department with recurrent epigastric pain. While undergoing inpatient evaluation, had a spontaneous rupture of a splenic artery aneurysm with hypovolemic shock and a double-rupture phenomenon, necessitating emergency surgery.

Conclusions: With advances in modern imaging in recent years, the incidence of splenic aneurysm has increased 7-fold; therefore, being informed and considering it in the differential diagnosis might provide a window of opportunity and save lives.

MeSH Keywords: Aneurysm, Ruptured • Diagnosis, Differential • Splenectomy • Splenic Artery

Full-text PDF: <https://www.amjcaserep.com/abstract/index/idArt/919956>



2189



—



2



34



Background

The abdomen is traversed by the aorta and its branches; when affected by abnormal dilatation, they constitute visceral artery aneurysm (VAA), but this term does not include renal artery aneurysm and pseudoaneurysm that does not include all 3 layers of the blood vessel [1].

True splenic artery aneurysm (SAA) is a common form of visceral artery aneurysm (VAA), being the most common in this group of relatively rare disorders, and it is especially rare among healthy young adults. SAAs are often associated with pregnancy, portal hypertension [2], cirrhosis, connective tissue disorders, and trauma. SAA rupture in a young healthy male is a rare disorder. This rarity, coupled with the chance of rupture, can produce a clinical picture ranging from nonspecific abdominal symptoms (posing a challenge for pre-rupture diagnosis) to a more dramatic intraperitoneal hemorrhage with hypovolemic shock associated with high morbidity and mortality, which often makes it a retrospective diagnosis [1].

Our patient presented with recurrent epigastric pain to the Emergency Department twice on the same day within a time span of fewer than 12 h. His blood laboratory results and preliminary imaging were normal, resulting in the patient initially being treated as a case of gastritis. However, the persistence of the pain and the unusually severe nature of the symptoms led to hospitalization for further evaluation on his second visit.

Case Report

A 32-year-old Middle Eastern male patient, obese, with a BMI of 38.7 and a history of smoking presented to the Emergency Department with complaints of epigastric pain that began 2 h before. He had no other prior medical or surgical illness, no history of alcohol use, and no history of trauma. The abdominal examination was unremarkable apart from epigastric tenderness. Relevant laboratory tests and EKG were performed, and cardiac enzymes were assessed. The patient was managed as a case of acute gastritis and discharged home.

He visited the Emergency Department again the following day, within 12 h after the previous visit, with severe epigastric pain (score 8/10) radiating to the back and associated with diaphoresis. The initial ultrasound scan of the abdomen was normal. The patient was then admitted to the Internal Medicine Department for observation.

A contrast-enhanced CT scan of the abdomen and pelvis revealed a 5-cm splenic artery aneurysm at the splenic hilum (Figure 1) with intramural thrombosis and surrounding soft-tissue density, with minimal free fluid (impending

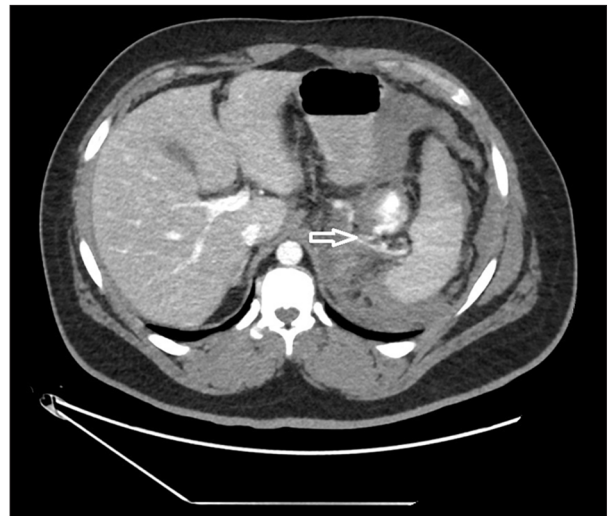

Figure 1. Abdominal CT scan with IV contrast showing a thin neck connecting the splenic artery and the aneurysm.

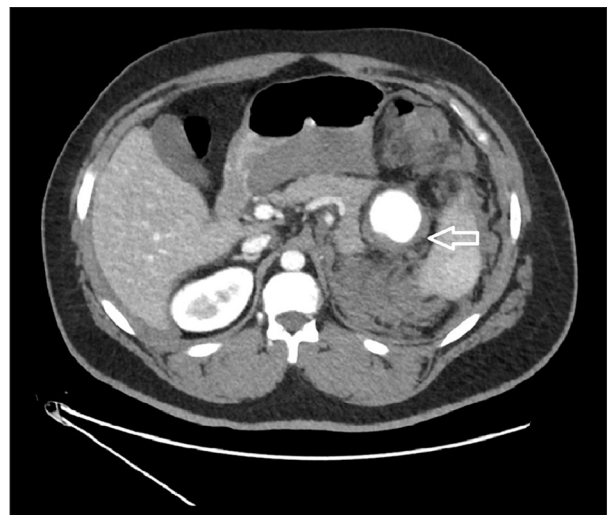


Figure 2. Abdominal CT scan with IV contrast showing the 5-cm splenic artery aneurysm in the splenic hilum displacing the tail of the pancreas, with adjacent retroperitoneal and peri-splenic hemorrhage.

rupture) (Figure 2). The left kidney was noted to be ectopic and rotated in the left lower lumbar region. Shortly afterward, the patient developed tachycardia with hypotension. The Rapid Response Team (RRT) was activated and the patient was resuscitated with IV fluids and stabilized, but soon thereafter he collapsed with hypovolemic shock. A surgical consultation was sought and, following further resuscitation, the patient was immediately taken to the operating room (OR) with the diagnosis of a ruptured splenic artery aneurysm. He underwent emergency exploratory laparotomy, with the finding of a large hemoperitoneum of about 2 L. Upon entering the peritoneal cavity, the patient became significantly hypotensive (60/40 mmHg) and was deteriorating fast. Abdominal aortic cross-clamping

was achieved at the level below the diaphragm until the patient was partially stabilized hemodynamically. The neck of the ruptured splenic artery aneurysm was found and an en block excision of the tail of the pancreas, spleen, and the aneurysm were performed. Peritoneal cavity drains were left in place.

The patient was returned to the ICU for postoperative care in a hemodynamically stable condition. However, 3 h after surgery, he again became hypotensive and tachycardic (BP 70/50 mmHg, HR: 150 bpm). The abdominal drains filled with blood. The patient was returned to the OR for re-laparotomy, and an arterial bleed was found at the site of the ruptured aneurysm, near the border of the resected pancreas. This was then controlled by ligation of the bleeders with vascular clips; the patient stabilized again and was returned to the ICU. He initially had elevated renal and liver function tests, secondary to hypoperfusion. He later recovered well, with an uneventful postoperative course, and was discharged on postoperative day 14. The patient received post-splenectomy vaccinations and was started on penicillin V prophylaxis. He was discharged with 1 remaining abdominal drain near the pancreatectomy site, which was removed on postoperative day 20 in the clinic during the first post-op visit, following the exclusion of a pancreatic fistula.

The patient was reviewed again after 4 weeks, and follow-up and brain CT were negative for aneurysm of the circle of Willis and other sites.

He developed reactive thrombocytosis, which was treated with aspirin.

At 6- and 11-month follow-up visits, the patient was doing well, was fully functional, and had resumed his normal daily activities.

Discussion

Splenic artery aneurysm is a common subtype of visceral artery aneurysm (VAA). It is a rare disorder that was first described in 1770 by Beaussier in autopsies [1], later as the first preoperative diagnosis in 1920 by Hoegler, and the first surgical intervention was in 1940 [2].

The incidence of splenic artery aneurysm ranges from 0.09% in autopsies to 0.78% on arteriography studies [3]; the incidence sharply increases to 10% in older patients [4], which makes our case of a healthy young man a rare occurrence of idiopathic splenic artery aneurysm. With widespread use of advanced imaging, as well as an increase in life expectancy, detection of VAAs has increased 7-fold in recent years, [5] cementing its importance in the coming decades.

The normal splenic artery diameter is 0.46 ± 0.03 cm [6] and focal dilation of the vessel more than 1.5 times this (0.7 cm) qualifies it as an aneurysm. Most aneurysms become detectable at 1 cm or more; 60% of all VAAs occur in the splenic artery [3]. It is more common in females, with a 4: 1 female-to-male ratio [7–9], but men are more likely to have a rupture.[10]

Most SAAs (>90%) remain asymptomatic and are discovered incidentally on imaging studies [11]. SAAs are also more common after the 6th decade of life, with 80% of cases seen in patients above 50 years of age [12], indicating the age/disease-related degeneration that was absent in our case. True splenic artery aneurysm contains all 3 layers of the blood vessel, but is thinned out as opposed to pseudoaneurysms, which are often associated with pancreatitis and iatrogenic instrumentation.

In all this, the risk of rupture is relatively lower for true SAAs, ranging from 2% to 10% [13], and increases with SAA size beyond 2 cm and in the presence of risk factors. In a retrospective study of 100 cases, the average size was 2.1 cm [7] and most did not exceed 3 cm [14]. In our case, the SAA was 5 cm wide, single, solitary, and saccular, and was located at the distal third of the splenic artery, which is the most common location (78%) [7] and presentation [15] reported in the literature.

The etiopathogenesis of SAA is not fully defined, but clear risk factors have emerged. Approximately 30% of all splenic aneurysm ruptures occur in pregnancy; this could be due to: a) the hyper-flow state leading to vascular stress; b) the uterus compressing the aorta, leading to portal congestion, and c) hormonal influences; estrogen and progesterone receptor sites have been demonstrated in the arteries [16]. The risk of pregnancy seems to be cumulative and increases with the degree of parity [3], with 3.5 pregnancies being the mean at the time of rupture [9]. Another common risk factor is portal hypertension, which it is known to cause medial hyperplasia and fragmentation of the elastic lamina of the artery [3,9,17].

Arterial hypertension, atherosclerosis, trauma, fibrodysplasia, and liver transplant [18,19] are other risk factors. A single study found an increased risk with smoking [20], but the main risk factor for pseudoaneurysm is pancreatitis [21]. Our patient gave a history of smoking (1 pack/day for more than 10 years) and was obese (BMI 38.7), but no trauma or any of the other aforementioned risk factors was ever documented.

Patients are predominantly asymptomatic, and when symptoms are present, they are usually vague and variable (17%) [7], making a pre-rupture diagnosis difficult, especially when the aneurysm is small. When the aneurysm ruptures, the presentation can be a dramatic hypotensive shock with high mortality, often leading to death outside the hospital setting or, rarely, a double-rupture phenomenon, which we believe occurred

with our patient. In the case presented, initially, the rupture and bleeding were contained within the lesser sac; this is when the pain is severe and the initial hemodynamic instability is mild to moderate, often rectified by resuscitative measures. The latter and the resulting improvement in the mean arterial pressure (MAP) aggravates the bleeding and overruns the tamponade of the collected blood in the lesser sac, often via the foramen of Winslow or through rupture of the pars flaccida, leading to a second, more severe, hypotensive shock, which is often not responsive to treatment. The time between these 2 episodes can be short as a few to several hours [22–27], thereby offering a window of opportunity for lifesaving intervention. This can confound the clinical picture if SAA rupture is still not considered in the diagnosis. This phenomenon was initially described by Bockerman in 1930 [28]. It is described to occur while the patient is undergoing further imaging to establish diagnosis (e.g., CT or angiogram); these are expected to be done soon after stabilization of the initial bleeding episode. The result is a higher MAP and rebleeding. In 30% of cases, the rupture occurs in adjacent organs such as the stomach, pancreas, or colon [29,30].

Because of the location deep inside the abdominal cavity and the small caliber of the vessels involved, ultrasonography can often miss a SAA before rupture; free fluid in the abdominal cavity is often the only positive finding after rupture, with limited localization value.

Performing CT scanning early in the evaluation often localizes the aneurysm, both before and after rupture. When CT is not able to localize the bleed, angiography is of great value if the patient is stable [31], but arteriography is preferred for diagnosing unruptured aneurysms [32]. MRI can be useful if the patient presents with retroperitoneal bleed in an elective setting. Sometimes the patient's condition necessitates proceeding to the OR without any imaging. Localization and control of the bleeding becomes difficult and precious time and blood are lost by exploring and packing. A dual angiogram performed in the OR is valuable if available.

Being a rare condition, there are no well-established guidelines. Elective repair is preferred in pregnancy, while planning for pregnancy, and in liver transplant candidates, irrespective of symptoms or size. Intervention is recommended in symptomatic aneurysms, irrespective of the size. Other SAAs without symptoms can be monitored effectively with serial imaging [21], and all aneurysms larger than 2 cm, irrespective of symptoms, should undergo intervention [7,20].

Intervention can be in the form of percutaneous catheter-based endovascular repair (either embolization or stent placement), laparoscopic surgery, and open surgery. The former 2 are preferred in a stable setting and the latter in patients with shock,

as in our case. In view of the immunological function of the spleen and overwhelming post-splenectomy infection (OPSI), splenic preservation should be attempted when feasible. In emergency surgery, splenectomy with distal pancreatectomy is necessary to achieve hemodynamic stability, especially when the aneurysmal dilation is embedded in the parenchyma of the tail of the pancreas. Concomitant pancreatectomy carries a risk of pancreatic fistula. Other patients can even develop diabetes mellitus following partial pancreatectomy.

Elective surgery for SAA with spleen preservation leads to ischemia and subsequent splenectomy in about 29% of cases [33]. Despite being less invasive and spleen-preserving, the percutaneous intervention can be followed by post-embolization syndrome: fever, pain, leukocytosis, splenic and bowel infarcts, and intraabdominal abscess. The latter occurs as a result of the migration of embolization material to non-targeted arteries. After preserving the spleen, there is evidence that it may not necessarily be functional [27]. Use of beta-blockers in patients with contraindication to any form of intervention has been found to increase late mortality [34].

Laparoscopic intervention is possible and recommended in an elective setting and in pregnant patients when done by an experienced surgeon. In all cases of complicated splenic aneurysm and in rupture, the classical open surgery is recommended.

The common denominator to all mortality seen with ruptured splenic aneurysm includes delay in diagnosis and not considering it in the differential diagnosis. When it happens in early pregnancy, it is often mistaken for ruptured ectopic gestation, and in later pregnancy as abruption. Sometimes, even after laparotomy, the diagnosis can be elusive, and blood in the lesser sac could be the only clue available.

Conclusions

This case is unique in the literature because of the giant size of the splenic artery aneurysm that spontaneously ruptured in a young, otherwise healthy patient. This was an unusual clinical presentation that eluded diagnosis, requiring multiple visits to the Emergency Department. This rare disorder is becoming more common with the aging population. With an ever-increasing prevalence of risk factors, it is prudent to consider rupture of the splenic aneurysm as a quick second-line differential diagnosis, as this can lead to prompt and appropriate lifesaving intervention.

Conflict of interest

None.

References:

1. Beaussier M: Sur un anévrisme de l'artère splénique: dont les parois se sont ossifiées. *J Med Toulouse*, 1770; 32: 157–62 [in French]
2. Macleod D, Maurice T: Rupture of a branch of the splenic artery: Associated with pregnancy. *Lancet*, 1940; 924–25
3. Stanley JC, Thomas NW, Fry WJ: Splanchnic artery aneurysms. *Arch Surg*, 1970; 101: 689–97
4. Reardon PR, Otah E, Craig ES et al: Laparoscopic resection of splenic artery aneurysms. *Surg Endosc*, 2005; 19(4): 488–93
5. Bizueto-Rosas H, Barajas-Colón JÁ, Delgadillo-de la OI et al: [Multiple aneurysms splenic; surgical exclusion with the conservation of the spleen.] *Cir Cir*, 2016; 84(1): 58–64 [in Spanish]
6. Silveira LA, Silveira FB, Fazan VP: Arterial diameter of the celiac trunk and its branches. Anatomical study. *Acta Cir Bras*, 2009; 24(1): 43–47
7. Trastek VF, Pairolo PC, Joyce JW et al: Splenic artery aneurysms. *Surgery*, 1982; 91: 694–99
8. Pulli R, Dorigo W, Troisi N et al: Surgical treatment of visceral artery aneurysms: A 25-year experience. *J Vasc Surg*, 2008; 48: 334–42
9. Bercei SA: Hepatic and splenic artery aneurysms. *Semin Vasc Surg*, 2005; 18: 196–201
10. Ierardi AM, Petrillo M, Bacuzzi A et al: Endovascular retreatment of a splenic artery aneurysm refilled by collateral branches of the left gastric artery: A case report. *J Med Case Rep*, 2014; 8: 436
11. Tani R, Hori T, Yamamoto H et al: Severely calcified true aneurysm: A thought-provoking case of solitary origin and postoperative management. *Am J Case Rep*, 2020; 21: 620–27
12. Abbas MA, Stone WM, Fowl RJ et al: Splenic artery aneurysms: Two decades experience at Mayo clinic. *Ann Vasc Surg*, 2002; 16(4): 442–49
13. Abdulrahman A, Shabkah A, Hassanain M, Aljiffry M et al: Ruptured spontaneous splenic artery aneurysm: A case report and review of the literature. *Int J Surg Case Rep*, 2014; 5: 754–57
14. Spittel JA et al: Aneurysm of the splenic artery. *JAMA*, 1961; 175: 452–56
15. Karaman K, Onat L, Sirvanci M, Olga R: Endovascular stent-graft treatment in a patient with splenic artery aneurysm. *Diagn Interv Radiol*, 2005; 11: 119–21
16. Hallett JW: Splenic artery aneurysms. *Semin Vasc Surg*, 1995; 8: 321–26
17. Puttini M, Aseni P, Brambilla G, Belli L: Splenic artery aneurysms in portal hypertension. *J Cardiovasc Surg*, 1982; 23: 490–93
18. Mandal S, Das PM, Mandal AK: Caroli's syndrome leading to splenic artery aneurysm: A rare presentation. *Int J Surg Pathol*, 2009; 17: 78–80
19. Annicchiarico BE, Avolio AW, Caracciolo G et al: Late development of splenic artery aneurysm after orthotopic liver transplantation: A case report. *Transplant Proc*, 2009; 41: 1383–85
20. Marmagkiolis K, Gopal F, Mego D et al: Endovascular management of splenic arterial aneurysms. *Int J Cardiol*, 2014; 174: 146–49
21. Tessier DJ, Stone WM, Fowl RJ et al: Clinical features and management of splenic artery pseudoaneurysm: Case series and cumulative review of the literature. *J Vasc Surg*, 2003; 38: 969–74
22. Deshpande AA, Kulkarni VM, Rege S et al: Ruptured true aneurysm of the splenic artery: An unusual cause of haemoperitoneum. *J Postgrad Med*, 2000; 46: 191–92
23. Davis T, Minardi J, Knight J et al: Ruptured splenic artery aneurysm: A rare cause of shock diagnosed with bedside ultrasound. *West J Emerg Med*, 2015; 16: 762–65
24. Oakley E, Ho JD, Johnson V et al: Splenic artery aneurysm: An important cause of hemoperitoneum and shock. *J Emerg Med*, 2014; 46: e65–67
25. Groussolles M, Merveille M, Alacoque X et al: Rupture of a splenic artery aneurysm in the first trimester of pregnancy. *J Emerg Med*, 2011; 41(1): e13–16
26. Popham P, Buettner A: Arterial aneurysms of the lienorenal axis during pregnancy. *Int J Obstet Anesth*, 2003; 12: 117–19
27. Nincheri Kunz M, Pantalone D, Borri A et al: Management of true splenic artery aneurysms. Two case reports and review of the literature. *Minerva Chir*, 2003; 58: 247–56
28. Al-Habbal Y, Christophi C, Muralidharan V: Aneurysms of the splenic artery: A review. *Surgeon*, 2010; 8: 223–31
29. Kaszyński M, Haisiura R: Splenic artery aneurysm: A case report. *Med Sci Monit*, 1999; 5: CS1213–15
30. Ek ET, Moulton CA, Mackay S: Catastrophic rectal bleeding from a ruptured splenic artery aneurysm. *ANZ J Surg*, 2003; 73: 361–64
31. de Perrot M, Bühler L, Deléaval J: Management of true aneurysms of the splenic artery. *Am J Surg*, 1998; 175: 466–68
32. Wagner WH, Allins AD, Treiman RL et al: Ruptured visceral artery aneurysms. *Ann Vasc Surg*, 1997; 11: 342–47
33. Abad C, Montesdeoca-Cabrera D, Sáez-Guzmán T: [Splenic artery aneurysm. Review of two surgically operated cases]. *An Med Interna*, 2006; 23: 130–32 [in Spanish]
34. Hogendoorn W, Lavida A, Hunink MG et al: Open repair, endovascular repair, and conservative management of true splenic artery aneurysms. *J Vasc Surg*, 2014; 60: 1667–76