

RESEARCH ARTICLE


# Outcomes of Bronchial Artery Embolization for Life-Threatening Hemoptysis in Patients with Chronic Pulmonary Aspergillosis

Beomsu Shin<sup>1</sup>✉, Won-Jung Koh<sup>1</sup>✉, Sung Wook Shin<sup>2</sup>, Byeong-Ho Jeong<sup>1</sup>, Hye Yun Park<sup>1</sup>, Gee Young Suh<sup>1,3</sup>, Kyeongman Jeon<sup>1,3\*</sup>

**1** Division of Pulmonary and Critical Care Medicine, Department of Medicine, Samsung Medical Centre, Sungkyunkwan University School of Medicine, Seoul, Republic of Korea, **2** Department of Radiology, Samsung Medical Centre, Sungkyunkwan University School of Medicine, Seoul, Republic of Korea, **3** Department of Critical Care Medicine, Samsung Medical Centre, Sungkyunkwan University School of Medicine, Seoul, Republic of Korea

✉ These authors contributed equally to this work.

\* [kjeon@skku.edu](mailto:kjeon@skku.edu)



**OPEN ACCESS**

**Citation:** Shin B, Koh W-J, Shin SW, Jeong B-H, Park HY, Suh GY, et al. (2016) Outcomes of Bronchial Artery Embolization for Life-Threatening Hemoptysis in Patients with Chronic Pulmonary Aspergillosis. PLoS ONE 11(12): e0168373. doi:10.1371/journal.pone.0168373

**Editor:** Sanjay Haresh Chotirmall, Lee Kong Chian School of Medicine, SINGAPORE

**Received:** July 16, 2016

**Accepted:** November 29, 2016

**Published:** December 22, 2016

**Copyright:** © 2016 Shin et al. This is an open access article distributed under the terms of the [Creative Commons Attribution License](https://creativecommons.org/licenses/by/4.0/), which permits unrestricted use, distribution, and reproduction in any medium, provided the original author and source are credited.

**Data Availability Statement:** All relevant data are within the paper.

**Funding:** The authors received no specific funding for this work.

**Competing Interests:** The authors are employed by Samsung Medical Center. There are no patents, products in development, or marketed products to declare. This does not alter the authors' adherence to all the PLOS ONE policies on sharing data and materials.

## Abstract

### Background

Bronchial artery embolization (BAE) is an important treatment option for short-term control of hemoptysis in patients with simple aspergilloma (SA). However, there are no data on the outcomes of BAE in patients with chronic pulmonary aspergillosis (CPA). In this study, the clinical characteristics and outcomes of BAE were investigated and compared in patients with CPA and SA.

### Methods

We retrospectively analyzed the clinical data of 64 patients (55 [86%] with CPA and 9 [14%] with SA) who underwent BAE for life-threatening hemoptysis. The clinical characteristics and outcomes of BAE in CPA patients were compared to those of patients with SA.

### Results

The most common angiographic abnormality was hypervascularity (n = 60, 94%), followed by contrast extravasation (n = 50, 78%) and systemic-pulmonary shunt (n = 48, 75%), with similar incidence rates in both groups. Immediate success was achieved in 41 (64%) BAE procedures, but it was incomplete in 23 (36%) cases due to difficulty with the approach and/or overuse of contrast medium. Clinical failure of BAE was observed in only one (2%) patient. Complications following BAE were observed in four (6%) patients. Recurrence of hemoptysis was seen in a total of 33 patients (52%) within a median of 2.0 (0.3–10.0) months, and repeat BAE was performed in 25 (76%) of these cases. In comparing the outcomes of patients with CPA and SA, there were no differences in the rates of success of initial BAE, incomplete embolization, or clinical failure in the two groups. However, recurrence of hemoptysis tended to be higher in patients with CPA (55%) than in those with SA (33%).

**Abbreviations:** BAE, bronchial artery embolization; CPA, chronic pulmonary aspergillosis; CT, computed tomography; IQR, interquartile range; SA, simple aspergilloma; TB, pulmonary tuberculosis.

In addition, antifungal medications following BAE were more commonly prescribed in the CPA group (56%) compared to the SA group (0%).

## Conclusions

BAE was a safe and effective procedure for the management of life-threatening hemoptysis in patients with CPA. However, recurrence of hemoptysis was common, especially in patients with CPA. Therefore, definitive treatment for CPA following successful BAE should be considered to ensure the long-term success of the embolization in these patients.

## Introduction

The chronic forms of pulmonary aspergillosis refers to a spectrum of diseases, from simple aspergilloma (SA) to progressive cavitary disease,[1–4] a progressive pulmonary disorder that causes significant respiratory and systemic symptoms.[5] SA can exist for years without causing symptoms, although a minority of patients will experience hemoptysis.[6] In contrast to SA, progressive diseases such as chronic cavitary pulmonary aspergillosis, chronic necrotizing pulmonary aspergillosis, and chronic fibrosing pulmonary aspergillosis have high morbidity rates and are often complicated by subacute or massive hemoptysis.[1–6] SA, chronic cavitary pulmonary aspergillosis, chronic necrotizing pulmonary aspergillosis, and chronic fibrosing pulmonary aspergillosis are now collectively referred to chronic pulmonary aspergillosis (CPA).[7–14]

CPA can be complicated by life-threatening hemoptysis. Bleeding is usually occurs from systemic arteries supplying to the lungs, including bronchial, intercostal, subclavian, or internal mammary arteries.[15–17] Therefore, bronchial artery embolization (BAE) is an important treatment option for short-term control of hemoptysis significant enough to threaten clinical stability in patients with pulmonary aspergillosis.[1–3] Major complications of BAE are rare, and the immediate clinical success rate defined as hemorrhage cessation ranges from 85% to 100%, although recurrence of hemoptysis occurs in 10% to 33% of patients.[17] However, the outcomes of BAE in patients with CPA have never been studied, and there are limited data on BAE outcomes in patients with pulmonary aspergilloma.[18–21] Therefore, we investigated the clinical characteristics and outcomes of BAE in CPA patients with life-threatening hemoptysis compared to those of patients with SA.

## Methods

Data were collected from all patients with a clinical and radiological suspicion of pulmonary aspergillosis who underwent BAE for life-threatening hemoptysis at Samsung Medical Center (a 1,979-bed, university-affiliated, tertiary referral hospital in Seoul, South Korea) between January 2005 and January 2015. During the study period, a total of 530 patients underwent BAE for life-threatening hemoptysis. Of these patients, 92 patients were suspected to have pulmonary aspergillosis based on clinical and radiological findings. The medical records of these patients were reviewed, and a retrospective analysis was conducted. All patients with documented life-threatening hemoptysis preceding the BAE whose outcome could be ascertained for at least 6 months after BAE were included in the study. To qualify as ‘life-threatening’ hemoptysis, at least one of the following three criteria had to be documented in the patients’

case notes: 1) blood loss >200 ml/hour; 2) cumulative blood loss >600 ml/24 hours; or 3) respiratory compromise necessitating intubation and mechanical ventilation.[21]

The institutional review board of the Samsung Medical Center approved this study and waived the requirement for informed consent as we used only de-identified data collected as part of clinical practice.

## Diagnosis of CPA and SA

Diagnoses of CPA and SA were based on clinical, radiologic, microbiologic, and histopathologic findings and were thoroughly reviewed by three of the authors (B.S., W-J.K., and K.J.). Differences in observed findings were resolved by consensus. A diagnosis of CPA was considered accurate when it was associated with the following: (1) compatible chronic pulmonary or systemic symptoms, including at least weight loss, productive cough, or hemoptysis and elevated levels of inflammatory markers (C-reactive protein or erythrocyte sedimentation rate); (2) compatible chest radiological findings, including cavitory pulmonary lesion with or without evidence of paracavitory infiltration, new cavity formation, or expansion of cavity size over time; and (3) a positive serum *Aspergillus* precipitin test or isolation of *Aspergillus* species from a respiratory sample (i.e., sputum, transtracheal aspirate, or bronchial aspiration fluid). [3,8,11,12] *Aspergillus*-precipitating antibody tests were performed using an *Aspergillus fumigatus* IgG ELISA kit (IBL International, Hamburg, Germany). Diagnostic criteria for SA were presence of a fungal ball in a single pulmonary cavity with serological or microbiological evidence implicating *Aspergillus* spp. and no radiological progression over at least 3 months of observation in a non-immunocompromised patient exhibiting no or mild symptoms.[3]

## Embolization procedure and outcomes

The BAE procedure was performed by interventional radiologists. The choice of embolization method and materials was made by each individual physician. A catheter was introduced into the right femoral artery using a 5-French guiding catheter. Agents used for embolization included coils, Gelfoam, polyvinyl alcohol, or a combination of these materials. Immediate success of the BAE was defined as significantly reduced blood flow on angiography and no expectoration of fresh blood,[22] whereas failure was indicated by continued or recurrent hemoptysis within 24 hours after the first BAE. Recurrence was defined as expectoration of fresh blood 24 hours or more after the first BAE.[23]

## Data collection

The following data were collected from the electronic medical records: demographic data, comorbidities, respiratory or systemic symptoms, laboratory measurements, radiological findings including computed tomography (CT), and additional treatments for pulmonary aspergillosis. Angiographic and embolization parameters were extracted from the radiological reports. Finally, we documented the outcomes of patients including recurrence of hemoptysis, additional treatments for recurrence of hemoptysis due to pulmonary aspergillosis, and mortality.

## Statistical analysis

The data are presented as median and interquartile range (IQR) for continuous variables and as number and percentage for categorical variables. The data were compared using the Mann-Whitney *U* test or Kruskal-Wallis test for continuous variables and Pearson's  $\chi^2$  test or Fisher's exact test for categorical variables. The Kaplan-Meier method was used to estimate the cumulative rates of recurrence following BAE, which were subsequently compared using the log-

rank test. All the tests were two-tailed, and a  $P$ -value  $< 0.05$  was considered significant. The data were analyzed using PASW Statistics 22 (SPSS Inc., Chicago, IL).

## Results

During the study period, a total of 92 patients suspected to have pulmonary aspergillosis underwent BAE for life-threatening hemoptysis. Of these patients, 64 (70%) patients with pulmonary aspergillosis (55 [86%] with CPA and 9 [14%] with SA) who underwent BAE for life-threatening hemoptysis were identified based on the eligibility criteria described above and included in the final analysis. The clinical characteristics of these patients are presented in Table 1. Most patients had underlying lung disease, such as previous tuberculosis ( $n = 49$ , 77%), bronchiectasis ( $n = 49$ , 77%), chronic obstructive pulmonary disease ( $n = 14$ , 22%), or

**Table 1. Comparison of characteristics between patients with chronic pulmonary aspergillosis (CPA) and simple aspergilloma (SA) underwent bronchial artery embolization for life-threatening hemoptysis.**

	All patients (N = 64)	CPA (n = 55)	SA (n = 9)	P value
Age, years	59 (50–68)	60 (51–68)	52 (50–66)	0.378
Gender, male	44 (69)	40 (73)	4 (44)	0.124
Body mass index, kg/m <sup>2</sup>	20.0 (15.9–23.5)	19.1 (15.6–23.0)	23.0 (19.4–25.0)	0.095
Comorbidities*				
Underlying lung disease				
Previous history of tuberculosis	49 (77)	43 (78)	6 (67)	0.427
Bronchiectasis	49 (77)	44 (80)	5 (56)	0.196
Chronic obstructive lung disease	14 (22)	13 (24)	1 (11)	0.670
Nontuberculous mycobacterial lung disease	14 (22)	14 (26)	0	0.187
Previous history of thoracic malignancy	5 (8)	5 (9)	0	> 0.999
Interstitial lung disease	4 (6)	4 (7)	0	> 0.999
Other comorbidities				
Diabetes	13 (20)	10 (18)	3 (33)	0.372
Chronic heart disease	9 (14)	8 (15)	1 (11)	> 0.999
Chronic liver disease	5 (8)	5 (9)	0	> 0.999
Previous history of extrathoracic malignancy	4 (6)	4 (7)	0	> 0.999
Chest computed tomographic findings*				
Cavity	61 (95)	53 (96)	8 (89)	0.370
Paracavitary infiltration	49 (77)	49 (89)	0	< 0.001
Mycetoma	45 (70)	37 (67)	8 (89)	0.260
Consolidation	33 (52)	29 (53)	4 (44)	0.729
Bilateral involvement	5 (8)	5 (9)	0	> 0.999
Laboratory findings				
White blood cells/ $\mu$ l	9,005 (7,518–11,710)	9,200 (7,920–11,940)	7,430 (5,325–9,630)	0.027
Erythrocyte sedimentation rate, mm/hr	76 (42–113)	81 (53–116)	27 (20–44)	0.005
C-reactive protein, mg/dl	2.57 (0.66–5.35)	2.62 (1.11–5.75)	0.24 (0.06–2.25)	0.004
Albumin, g/dl	3.8 (3.5–4.2)	3.7 (3.4–4.1)	4.0 (3.8–4.6)	0.046
Microbiological tests*				
Positive serum <i>Aspergillus</i> precipitin antibody test	50 (78)	48 (87)	2 (22)	< 0.001
<i>Aspergillus</i> culture	38 (59)	30 (55)	8 (89)	0.071
Antifungal medications before embolization	18 (28)	18 (33)	0	0.052

\* Cases are duplicated.

The data are presented as median (interquartile range) or number (%).

doi:10.1371/journal.pone.0168373.t001

**Table 2. Angiographic findings and bronchial artery embolization in patients with pulmonary aspergillosis.**

	All patients (N = 64)	CPA (n = 55)	SA (n = 9)	P value
Angiographic findings*				
Hypervascularity	60 (94)	52 (95)	8 (89)	0.463
Systemic-pulmonary shunt	48 (75)	42 (76)	6 (67)	0.679
Extravasation	50 (78)	44 (80)	6 (67)	0.397
Neovascularization	46 (72)	41 (75)	5 (56)	0.255
Embolization*				
Bronchial artery	51 (80)	42 (76)	9 (100)	0.185
Nonbronchial systemic artery	47 (73)	42 (76)	5 (56)	0.230
Number of embolized artery	3 (2–3)	3 (2–3)	2 (1–3)	0.109

\* Cases are duplicated.

The data are presented as median (interquartile range) or number (%).

CPA, chronic pulmonary aspergillosis; SA, simple aspergilloma

doi:10.1371/journal.pone.0168373.t002

non-tuberculous mycobacterial lung disease (n = 14, 22%). All patients presented with at least one of the following chest CT findings: cavitary lesion (n = 61, 95%), paracavitary infiltration (n = 49, 77%), mycetoma (n = 45, 70%), or consolidation (n = 33, 52%).

Compared with SA patients, the CPA patients were more likely to be male and to have low body mass index (Table 1). Inflammatory markers including leukocytosis, erythrocyte sedimentation rate, and C-reactive protein were higher in patients with CPA. In addition, cavity and paracavitary infiltration on chest CT scan were more commonly observed in patients with CPA than in patients with SA. However, there was no difference in comorbidities between the two groups. Eighteen (33%) patients with CPA were on antifungal treatment, while none of the SA patients had received this treatment before the BAE.

Angiographic findings and outcomes of BAE are shown in Table 2. Abnormalities of bronchial or non-bronchial arteries were found in all patients. The most common abnormality was hypervascularity in 60 (94%) patients, followed by contrast extravasation in 50 (78%), systemic-pulmonary shunt in 48 (75%), and neovascularization in 46 (72%) patients. Interestingly, the two groups did not demonstrate any differences in the types of vascular abnormalities. The bronchial arteries were the most frequently embolized vessels (n = 51, 80%), although non-bronchial systemic arteries were simultaneously embolized in 34 (53%) cases. The median number of vessels embolized per procedure was 3 (range 2–3). However, there were no differences between two groups in the type or number of vessels embolized.

The overall clinical outcomes of the patients who underwent BAE are summarized in Table 3. Immediate success was achieved with the first BAE in 41 (64%) patients. In the remaining 23 (36%) patients, the embolization could not be completed due to difficulty with the approach (n = 21) and/or overuse of contrast medium (n = 12). Clinical failure of the first BAE was observed in only one (2%) patient. Complications post-BAE were observed in four (6%) patients. During the median follow-up period of 26.0 (13.0–55.0) months, recurrence of hemoptysis was seen in a total of 33 patients (52%) at a median of 2.0 (0.3–10.0) months after the first BAE. Of these patients, repeat BAE was performed in 25 (25/33, 76%) patients. Additional treatments for pulmonary aspergillosis were necessary in 55 (86%) patients, which consisted of antifungal medication in 31 (48%) and surgical resection in 24 (38%) (Fig 1).

In comparing the outcomes of patients with CPA and SA, there were no significant differences in rates of immediate success, incomplete embolization, or clinical failure of the first BAE (Table 3). The cumulative rates of recurrence following BAE in the two groups are shown

**Table 3. Clinical outcomes of the patients with pulmonary aspergillosis underwent bronchial arterial embolization for life-threatening hemoptysis.**

	All patients (N = 64)	CPA (n = 55)	SA (n = 9)	P value
Outcomes of the first BAE				
Immediate success	41 (64)	35 (64)	6 (67)	> 0.999
Incomplete BAE*	23 (36)	20 (36)	3 (33)	> 0.999
Difficult to approach	21 (33)	18 (33)	3 (33)	
Overuse of contrast medium	12 (19)	10 (18)	2 (22)	
Failure	1 (2)	1 (2)	0	> 0.999
Complications of the first BAE				
Embolitic events	1 (2)	1 (2)	0	
Procedure related discomfort	3 (5)	3 (6)	0	
Recurrence of hemoptysis				
Time to recurrence, months	2.0 (0.3–10.0)	2.0 (0.3–10.0)	2.0 (0.5–NA)	0.296
<1 month (early onset)	12 (19)	11 (20)	1 (11)	> 0.999
1 month– 1 year	14 (22)	12 (22)	2 (22)	> 0.999
>1 year	7 (11)	7 (13)	0	0.580
Repeated BAE after first BAE (n = 33)	25 (76)	22 (73)	3 (100)	0.560
Additional treatments for pulmonary aspergillosis				
No additional treatment	9 (14)	8 (15)	1 (11)	> 0.999
Antifungal medication	31 (48)	31 (56)	0	0.002
Surgical resection	24 (38)	16 (29)	8 (89)	0.001
Mortality	15 (23)	15 (27)	0	0.101

\* Cases are duplicated.

The data are presented as median (interquartile range) or number (%).

BAE, bronchial artery embolization; CPA, chronic pulmonary aspergillosis; SA, simple aspergilloma

doi:10.1371/journal.pone.0168373.t003

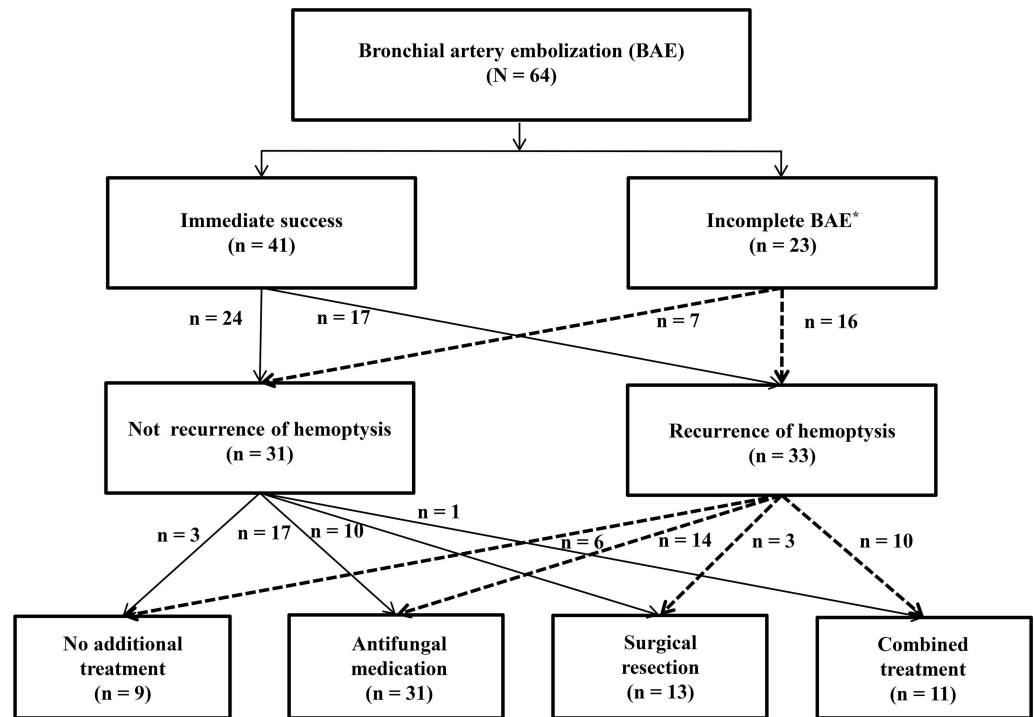
in Fig 2. Recurrence of hemoptysis tended to be more common in patients with CPA (30, 55%) than in patients with SA (3, 33%) ( $P = 0.296$ ).

In addition, antifungal medications following BAE were more commonly prescribed in the CPA group (56%) compared to the SA group (0%) ( $P = 0.002$ ). All but one (89%) patient with SA required surgical resection after the first BAE, in contrast to 16 (29%) patients with CPA ( $P = 0.001$ ). Finally, the overall mortality was 23%, which tended to be higher in patients with CPA (27%) compared to patients with SA (0%,  $P = 0.101$ ).

## Discussion

To our knowledge, this is the first report of the clinical characteristics and outcomes of BAE in CPA patients with life-threatening hemoptysis. Our results demonstrated that BAE was a safe and effective procedure for the management of life-threatening hemoptysis due to CPA. However, recurrence of hemoptysis was common, and repeated BAE and antifungal treatment were required in the majority of patients. When comparing the complication rates of initial BAE, patients with SA and CPA did not show any differences in the rates of immediate success, incomplete embolization, or clinical failure. Despite this, the recurrence of hemoptysis tended to be higher in patients with CPA than in patients with SA.

Although there are many causes of hemoptysis, [24,25] life-threatening hemoptysis requiring intervention most often occurs in the setting of chronic inflammatory lung disease, predominantly in cases of pulmonary tuberculosis (TB) and bronchiectasis. [25] However, CPA, including SA, can also be complicated by mild, moderate, or life-threatening hemoptysis. [2]

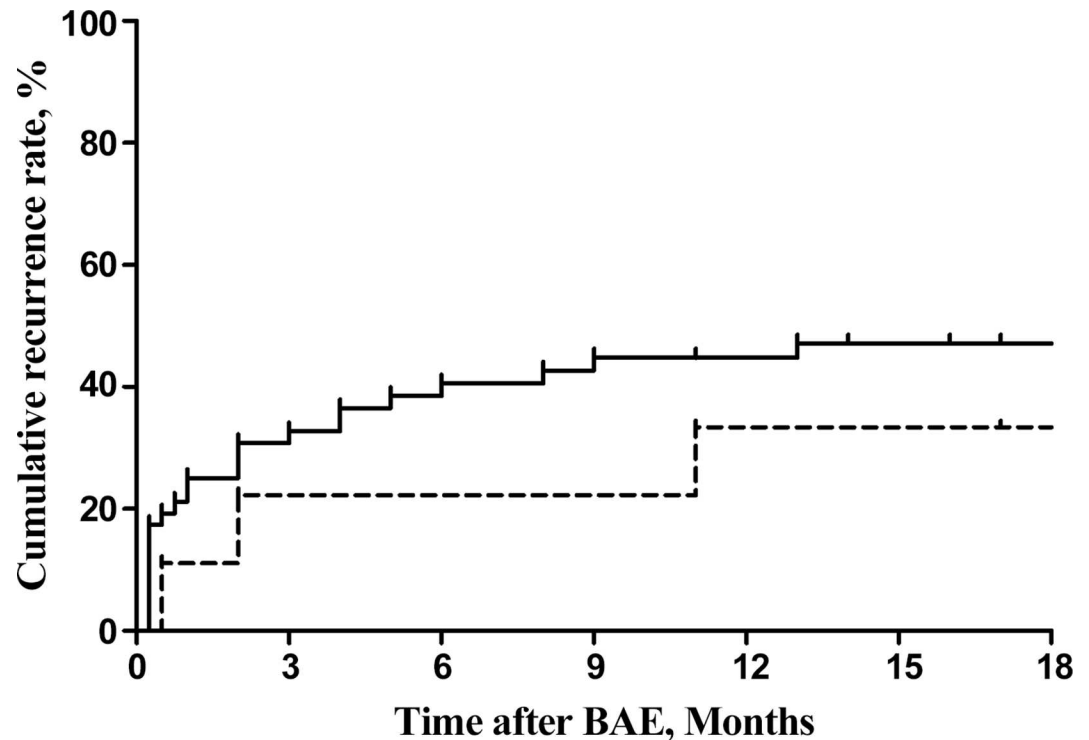


**Fig 1. Flow chart of the study population with CPA who underwent BAE for life-threatening hemoptysis.** CPA, chronic pulmonary aspergillosis; BAE, bronchial artery embolization. \* One case of clinical failure of the first BAE is included.

doi:10.1371/journal.pone.0168373.g001

Although mild or moderate hemoptysis is frequently controlled with the use of conservative therapy, BAE has become a mainstay in the treatment of hemoptysis, especially in case of both life-threatening and recurring hemoptysis.[26] Numerous studies have demonstrated the effectiveness and success of BAE, especially in TB patients.[23,27–29] However, the recurrence of hemoptysis following successful BAE remains common and is associated with aspergilloma. [22,27,29] In the present study, the recurrence rate in patients with CPA was 55%, which is approximately two times higher than that of TB patients.[23,27–29] In addition, the majority of patients with recurrence of hemoptysis required repeat BAE. Therefore, additional treatments after a successful BAE are recommended to ensure the long-term success of the embolization in CPA patients.[1,4,30]

The chronic forms of pulmonary aspergillosis are SA, chronic cavitary pulmonary aspergillosis, and chronic necrotizing pulmonary aspergillosis,[1] although recent guidelines from the European Society for Clinical Microbiology and Infectious Diseases and the European Respiratory Society suggest new a classification of CPA to include aspergillus nodules and subacute invasive aspergillosis, which were previously termed chronic necrotizing pulmonary aspergillosis.[3] Although few data on BAE outcomes in patients with SA have been reported,[18–20] there have been no reports on clinical outcomes and complications of BAE in patients with other CPA subtypes. In this study, the outcome of BAE in patients with SA was consistent with previous reports.[18,20] All of the angiographic findings and embolization were similar in the SA and CPA subtype groups; however, hemoptysis recurrence tended to be higher in patients with other CPA subtypes. Recurrent hemoptysis within the first month of embolization is caused by incomplete embolization of the abnormal vessels,[26] which might be associated with the widespread tissue involvement found in other CPA subtypes. In addition, progression



**Fig 2. Cumulative recurrence rates following BAE in patients with CPA (solid line) and patients with SA (dotted line) ( $P = 0.061$ , log-rank test).** BAE, bronchial artery embolization; CPA, chronic pulmonary aspergillosis.

doi:10.1371/journal.pone.0168373.g002

of CPA might cause recanalization of previously embolized vessels or revascularization of collateral circulation and result in late rebleeding following BAE.[22] For this reason, additional treatment including antifungal medication and surgical resection were required in the majority of the patients we studied.

Although this study provides new information on the clinical characteristics and outcomes of BAE in CPA patients, it is limited by its retrospective, observational design and the acquisition of data from a single center. Furthermore, there may have been insufficient statistical power to identify some significant findings due to the small sample size. Finally, the evaluation and therapeutic decision-making following BAE were not based on a pre-set protocol, but rather on the clinical experience of each attending physician. Therefore, the number of patients having antifungal medications before embolization was low.

## Conclusions

In conclusion, BAE was a safe and effective procedure for the management of life-threatening hemoptysis in patients with pulmonary aspergillosis. However, recurrence of hemoptysis was common, especially in patients with CPA. Therefore, definitive treatment for CPA following successful BAE should be considered to ensure the long-term success of the embolization in these patients.

## Author Contributions

**Conceptualization:** BS WJK KJ.

**Formal analysis:** BS WJK KJ.



**Investigation:** BS WJK SWS BHJ HYP GYS KJ.

**Methodology:** BS WJK SWS BHJ HYP GYS KJ.

**Project administration:** KJ.

**Writing – original draft:** BS WJK KJ.

**Writing – review & editing:** BS WJK SWS BHJ HYP GYS KJ.

## References

- Walsh TJ, Anaissie EJ, Denning DW, Herbrecht R, Kontoyiannis DP, Marr KA, et al. Treatment of aspergillosis: clinical practice guidelines of the Infectious Diseases Society of America. *Clinical infectious diseases: an official publication of the Infectious Diseases Society of America*. 2008; 46(3):327–60. Epub 2008/01/08.
- Patterson KC, Streck ME. Diagnosis and treatment of pulmonary aspergillosis syndromes. *Chest*. 2014; 146(5):1358–68. Epub 2014/11/05. doi: [10.1378/chest.14-0917](https://doi.org/10.1378/chest.14-0917) PMID: [25367472](https://pubmed.ncbi.nlm.nih.gov/25367472/)
- Denning DW, Cadranel J, Beigelman-Aubry C, Ader F, Chakrabarti A, Blot S, et al. Chronic pulmonary aspergillosis: rationale and clinical guidelines for diagnosis and management. *The European respiratory journal*. 2016; 47(1):45–68. doi: [10.1183/13993003.00583-2015](https://doi.org/10.1183/13993003.00583-2015) PMID: [26699723](https://pubmed.ncbi.nlm.nih.gov/26699723/)
- Patterson TF, Thompson GR 3rd, Denning DW, Fishman JA, Hadley S, Herbrecht R, et al. Practice Guidelines for the Diagnosis and Management of Aspergillosis: 2016 Update by the Infectious Diseases Society of America. *Clinical infectious diseases: an official publication of the Infectious Diseases Society of America*. 2016; 63(4):e1–e60. Epub 2016/07/02. PubMed Central PMCID: [PMCPmc4967602](https://pubmed.ncbi.nlm.nih.gov/PMC4967602/).
- Denning DW, Riniotis K, Dobrashian R, Sambatakou H. Chronic cavitary and fibrosing pulmonary and pleural aspergillosis: case series, proposed nomenclature change, and review. *Clinical infectious diseases: an official publication of the Infectious Diseases Society of America*. 2003; 37 Suppl 3:S265–80. Epub 2003/09/17.
- Soubani AO, Chandrasekar PH. The clinical spectrum of pulmonary aspergillosis. *Chest*. 2002; 121(6):1988–99. PMID: [12065367](https://pubmed.ncbi.nlm.nih.gov/12065367/)
- Camuset J, Nunes H, Dombret MC, Bergeron A, Henno P, Philippe B, et al. Treatment of chronic pulmonary aspergillosis by voriconazole in nonimmunocompromised patients. *Chest*. 2007; 131(5):1435–41. Epub 2007/04/03. doi: [10.1378/chest.06-2441](https://doi.org/10.1378/chest.06-2441) PMID: [17400661](https://pubmed.ncbi.nlm.nih.gov/17400661/)
- Nam HS, Jeon K, Um SW, Suh GY, Chung MP, Kim H, et al. Clinical characteristics and treatment outcomes of chronic necrotizing pulmonary aspergillosis: a review of 43 cases. *Int J Infect Dis*. 2010; 14(6):e479–82. doi: [10.1016/j.ijid.2009.07.011](https://doi.org/10.1016/j.ijid.2009.07.011) PMID: [19910234](https://pubmed.ncbi.nlm.nih.gov/19910234/)
- Ohba H, Miwa S, Shirai M, Kanai M, Eifuku T, Suda T, et al. Clinical characteristics and prognosis of chronic pulmonary aspergillosis. *Respiratory medicine*. 2012; 106(5):724–9. Epub 2012/02/22. doi: [10.1016/j.rmed.2012.01.014](https://doi.org/10.1016/j.rmed.2012.01.014) PMID: [22349065](https://pubmed.ncbi.nlm.nih.gov/22349065/)
- Cadranel J, Philippe B, Hennequin C, Bergeron A, Bergot E, Bourdin A, et al. Voriconazole for chronic pulmonary aspergillosis: a prospective multicenter trial. *European journal of clinical microbiology & infectious diseases: official publication of the European Society of Clinical Microbiology*. 2012; 31(11):3231–9. Epub 2012/07/12. PubMed Central PMCID: [PMC3479377](https://pubmed.ncbi.nlm.nih.gov/PMC3479377/).
- Jhun BW, Jeon K, Eom JS, Lee JH, Suh GY, Kwon OJ, et al. Clinical characteristics and treatment outcomes of chronic pulmonary aspergillosis. *Med Mycol*. 2013; 51(8):811–7. doi: [10.3109/13693786.2013.806826](https://doi.org/10.3109/13693786.2013.806826) PMID: [23834282](https://pubmed.ncbi.nlm.nih.gov/23834282/)
- Shin B, Koh WJ, Jeong BH, Yoo H, Park HY, Suh GY, et al. Serum galactomannan antigen test for the diagnosis of chronic pulmonary aspergillosis. *The Journal of infection*. 2014; 68(5):494–9. doi: [10.1016/j.jinf.2014.01.005](https://doi.org/10.1016/j.jinf.2014.01.005) PMID: [24462563](https://pubmed.ncbi.nlm.nih.gov/24462563/)
- Kosmidis C, Denning DW. The clinical spectrum of pulmonary aspergillosis. *Thorax*. 2015; 70(3):270–7. doi: [10.1136/thoraxjnl-2014-206291](https://doi.org/10.1136/thoraxjnl-2014-206291) PMID: [25354514](https://pubmed.ncbi.nlm.nih.gov/25354514/)
- Izumikawa K. Recent advances in chronic pulmonary aspergillosis. *Respiratory investigation*. 2016; 54(2):85–91. doi: [10.1016/j.resinv.2015.10.003](https://doi.org/10.1016/j.resinv.2015.10.003) PMID: [26879477](https://pubmed.ncbi.nlm.nih.gov/26879477/)
- Brinson GM, Noone PG, Mauro MA, Knowles MR, Yankaskas JR, Sandhu JS, et al. Bronchial artery embolization for the treatment of hemoptysis in patients with cystic fibrosis. *American journal of respiratory and critical care medicine*. 1998; 157(6 Pt 1):1951–8.
- McDonald DM. Angiogenesis and remodeling of airway vasculature in chronic inflammation. *American journal of respiratory and critical care medicine*. 2001; 164(10 Pt 2):S39–45.

17. Sopko DR, Smith TP. Bronchial artery embolization for hemoptysis. *Seminars in interventional radiology*. 2011; 28(1):48–62. PubMed Central PMCID: PMC3140255. doi: [10.1055/s-0031-1273940](https://doi.org/10.1055/s-0031-1273940) PMID: [22379276](https://pubmed.ncbi.nlm.nih.gov/22379276/)
18. Uflacker R, Kaemmerer A, Picon PD, Rizzon CF, Neves CM, Oliveira ES, et al. Bronchial artery embolization in the management of hemoptysis: technical aspects and long-term results. *Radiology*. 1985; 157(3):637–44. doi: [10.1148/radiology.157.3.4059552](https://doi.org/10.1148/radiology.157.3.4059552) PMID: [4059552](https://pubmed.ncbi.nlm.nih.gov/4059552/)
19. Otani Y, Yoshida I, Ohki S, Kano M, Kawashima O, Suzuki M, et al. Arterial embolization as preoperative treatment for pulmonary aspergillosis with hemoptysis. *Surg Today*. 1997; 27(9):812–5. PMID: [9306603](https://pubmed.ncbi.nlm.nih.gov/9306603/)
20. Corr P. Management of severe hemoptysis from pulmonary aspergilloma using endovascular embolization. *Cardiovascular and interventional radiology*. 2006; 29(5):807–10. Epub 2006/07/01. doi: [10.1007/s00270-005-0329-0](https://doi.org/10.1007/s00270-005-0329-0) PMID: [16810459](https://pubmed.ncbi.nlm.nih.gov/16810459/)
21. van den Heuvel MM, Els Z, Koegelenberg CF, Naidu KM, Bolliger CT, Diacon AH. Risk factors for recurrence of haemoptysis following bronchial artery embolisation for life-threatening haemoptysis. *The international journal of tuberculosis and lung disease: the official journal of the International Union against Tuberculosis and Lung Disease*. 2007; 11(8):909–14. Epub 2007/08/21.
22. Chun JY, Belli AM. Immediate and long-term outcomes of bronchial and non-bronchial systemic artery embolisation for the management of haemoptysis. *European radiology*. 2010; 20(3):558–65. doi: [10.1007/s00330-009-1591-3](https://doi.org/10.1007/s00330-009-1591-3) PMID: [19727742](https://pubmed.ncbi.nlm.nih.gov/19727742/)
23. Pei R, Zhou Y, Wang G, Wang H, Huang X, Yan X, et al. Outcomes of bronchial artery embolization for life-threatening hemoptysis secondary to tuberculosis. *PLoS One*. 2014; 9(12):e115956. PubMed Central PMCID: PMC4277402. doi: [10.1371/journal.pone.0115956](https://doi.org/10.1371/journal.pone.0115956) PMID: [25541693](https://pubmed.ncbi.nlm.nih.gov/25541693/)
24. Abdulmalak C, Cottenet J, Beltramo G, Georges M, Camus P, Bonniaud P, et al. Haemoptysis in adults: a 5-year study using the French nationwide hospital administrative database. *The European respiratory journal*. 2015; 46(2):503–11. doi: [10.1183/09031936.00218214](https://doi.org/10.1183/09031936.00218214) PMID: [26022949](https://pubmed.ncbi.nlm.nih.gov/26022949/)
25. Chan VL, So LK, Lam JY, Lau KY, Chan CS, Lin AW, et al. Major haemoptysis in Hong Kong: aetiologies, angiographic findings and outcomes of bronchial artery embolisation. *The international journal of tuberculosis and lung disease: the official journal of the International Union against Tuberculosis and Lung Disease*. 2009; 13(9):1167–73.
26. Chun JY, Morgan R, Belli AM. Radiological management of hemoptysis: a comprehensive review of diagnostic imaging and bronchial arterial embolization. *Cardiovascular and interventional radiology*. 2010; 33(2):240–50. doi: [10.1007/s00270-009-9788-z](https://doi.org/10.1007/s00270-009-9788-z) PMID: [20058006](https://pubmed.ncbi.nlm.nih.gov/20058006/)
27. Kim SW, Lee SJ, Ryu YJ, Lee JH, Chang JH, Shim SS, et al. Prognosis and Predictors of Rebleeding After Bronchial Artery Embolization in Patients with Active or Inactive Pulmonary Tuberculosis. *Lung*. 2015; 193(4):575–81. Epub 2015/04/12. doi: [10.1007/s00408-015-9728-4](https://doi.org/10.1007/s00408-015-9728-4) PMID: [25862253](https://pubmed.ncbi.nlm.nih.gov/25862253/)
28. Lee JH, Kwon SY, Yoon HI, Yoon CJ, Lee KW, Kang SG, et al. Haemoptysis due to chronic tuberculosis vs. bronchiectasis: comparison of long-term outcome of arterial embolisation. *The international journal of tuberculosis and lung disease: the official journal of the International Union against Tuberculosis and Lung Disease*. 2007; 11(7):781–7.
29. Shin BS, Jeon GS, Lee SA, Park MH. Bronchial artery embolisation for the management of haemoptysis in patients with pulmonary tuberculosis. *The international journal of tuberculosis and lung disease: the official journal of the International Union against Tuberculosis and Lung Disease*. 2011; 15(8):1093–8.
30. Agarwal R, Vishwanath G, Aggarwal AN, Garg M, Gupta D, Chakrabarti A. Itraconazole in chronic cavitary pulmonary aspergillosis: a randomised controlled trial and systematic review of literature. *Mycoses*. 2013; 56(5):559–70. Epub 2013/03/19. doi: [10.1111/myc.12075](https://doi.org/10.1111/myc.12075) PMID: [23496375](https://pubmed.ncbi.nlm.nih.gov/23496375/)